represent the resistant immunological pole of infection, they also increased more 30 cases came from III, 47 from SRI, two from SOI, and one from SI (=AVL) profiles; thus, providing to AI profile a final evolution rate of infection of 78.3% (238 cases).

In summary, the AI profile was the unique profile which was benefited with the dynamics evolution of infection, evolving from 51.6% in the accumulated prevalence to 78.3% in the final evolution of infection. The other profiles have only decreased their frequency rates following the evolution of infection, as follows: SI (=AVL) from 1.6% to 0.3%, SOI from 4.3% to 1%, SRI from 20.1% to 15.1%, and principally, III from 22.4% to 5.3% (Tables 1 and 2).

At last, it is important to emphasize that throughout the study period there was not detected none case of cutaneous leishmaniasis amongst the individuals reacting either by LST and/or by IFAT, which reinforced the specificity of these immunological tests for diagnosing human *L. (L.) i. chagasi* infection. At the same time, there was no recorded none case of "HIV" infection amongst the individuals resident in this community.

## Discussion

Initially, it should be highlighted the importance of AI profile in the context of this clinical-immunological spectrum of human *L. (L.) i. chagasi* infection once these results have clearly demonstrated that AI profile was the most frequent in all surveys analyzed, specially in the accumulated prevalence where it had 51.6% of infection, followed by III (22.4%), SRI (20.1%), SOI (4.3%) and, SI=AVL (1.6%) profiles. Thus, it is reasonable to assume that its high frequency might be the result of the small period of time developing between the initial stage of infection (III profile) and its final stage (AI profile), indicating that most III cases present a brief IgG antibody response (IFAT+/++) followed by rapid positive LST conversion (SRI profile), and finally, negative IFAT conversion (AI profile). This finding had prior been studied in AVL endemic area in Barcarena municipality, Pará state, at about 150 km distant from this study area in Cametá municipality, where AI profile corresponded to 73.2% of cases in the accumulated prevalence of infection (Silveira et al. 2009b). In this way, as T-cell hypersensitivity has been considered a genetic expression of T-cell immune response against human *L. (L.) i. chagasi* infection (Jeronimo et al. 2007), the present results have confirmed that the great majority of infected individuals in endemic area (final evolution of AI profile was 78.3%) are immune-genetic resistant against to infection. In addition, regarding that SRI profile (final evolution 15.1%) seems to represent a developing stage towards to the resistant AI profile, this rate can reach to 90% of all infection in endemic area.

With regards to SRI profile, which has been recognized as a new stage of infection in this diagnostic approach, its performance was similar to that found in previous study (Silveira et al. 2009b), with 23% in the prevalence and 15.4% in the final evolution of infection, suggesting to be more frequent amongst older cases of infection and with high possibility for developing towards to the resistant immunological pole of infection (AI profile). In this way, it was shown in the present study that 47 (77%) amongst 61 SRI cases have negatively converted the IFAT− and kept their T-cell hypersensitivity (LST+/++++ and IFAT−), assuming then the status of AI profile. Thus, as T-cell hypersensitivity expression is genetic controlled, it might be expected that just following a new case of infection (III profile) had converted its T-cell hypersensitivity (SRI profile), it will certainly develop to the resistant immunological pole of infection (AI profile). This is the reason we have not regarded SRI cases as a major target to follow-up in AVL control programs.

In relation to III profile, which has been regarded as the earliest stage of infection in this diagnostic approach, it was interesting to record its regular distribution in all surveys of

**Table 2** Age distribution of clinical-immunological profiles of human *L. (L.) i. chagasi*-infection in the prevalence and incidence surveys in Cametá municipality, Pará state, Amazonian Brazil

| Surveys | Number (%) | Clinical-immunological profiles | | | | |
|---|---|---|---|---|---|---|
| | | Number (%) | | | | |
| | | AI | SI | SOI | SRI | III |
| Prevalence ($n$=187 cases) | | | | | | |
| 1–10[a] | 43 (23.0) | 13 (30.2) | 4 (9.3) | 2 (4.7) | 13 (30.2) | 11 (25.6) |
| 11–20 | 44 (23.5) | 21 (47.7) | – | 2 (4.6) | 6 (13.6) | 15 (34.1) |
| ≥21 | 100 (53.5) | 56 (56.0) | – | 5 (5.0) | 24 (24.0) | 15 (15.0) |
| Incidence ($n$=117 cases) | | | | | | |
| 1–10 | 51 (43.6) | 30 (58.8) | 1 (1.9) | 3 (5.9) | 3 (5.9) | 14 (27.5) |
| 11–20 | 44 (37.6) | 30 (68.2) | – | – | 8 (18.2) | 6 (13.6) |
| ≥21 | 22 (18.8) | 7 (31.8) | – | 1 (4.6) | 7 (31.8) | 7 (31.8) |

*AI* asymptomatic infection, *SI* symptomatic infection (AVL), SOI sub-clinical oligosymptomatic infection, *SRI* sub-clinical resistant infection, and *III* indeterminate initial infection

[a] Age groups (years old)

the present study, with 22% in the prevalence, 26.6% in the first incidence (12 months), 18.9% in the second incidence (24 months), 22.4% in the accumulated prevalence and, 23.1% in the final incidence, which might be reflecting an expressive regularity of the infection transmission in the endemic area of Cametá municipality, where the prevalence of infection (17%) was, coincidently, higher than that (12.6%) in prior study in Barcarena municipality (Silveira et al. 2009a). Besides this, regarding that final incidence of III profile was 23.1%, it is expected that about 2–3% of cases should require clinical follow-up in the endemic area once they have high potential for developing to the susceptible clinical forms of infection, i.e., SOI or SI (=AVL) profiles. Thus, these findings should be taking into account when developing AVL control programs.

The SOI and SI (=AVL) profiles have presented the smallest frequencies in all time-point surveys of this study, although SOI has shown an accumulated prevalence (4.3%) almost three times higher than that (1.6%) of SI. However, as similar to that found in the first study in Barcarena municipality (Silveira et al. 2009b), both profiles have shown an accumulated prevalence of only 5.9% of total cases of infection in endemic area of Amazonian Brazil, which differs from the northeaster region of this country; i.e., in Bahia state, for example, the sub-clinical oligo-symptomatic form (=SOI profile) was recorded in 60% of 86 infected children below fifteen years old (Badaró et al. 1986b) and, in Maranhão state, the same clinical form was diagnosed in 17.4% of 189 children into the same age group (Gama et al. 2004). It should be highlighted, however, that in these two studies the diagnosis of disease was realized in children below fifteen years old, which might be providing to these children a greater susceptibility to develop symptomatic infection.

When distribution of clinical-immunological profiles was regarded by age, it was again demonstrated that AI profile was the most frequent in almost all age groups analyzed (1–10, 11–20, and ≥21 years age groups), either in the prevalence or in the incidence, with exception in case of the 1–10 years age group in the prevalence whose frequency (30.2%) was the same to that of SRI profile and, also, in case of the ≥21 years age group in the incidence whose frequency (31.8%) was also the same to those of SRI and III profiles. Thus, these results have provided to AI profile the status of the most frequent in all different age groups in both prevalence and incidence surveys.

On the other hand, when the frequency of infection was compared within the same clinical-immunological profile, the following findings deserve to be commented: (1) while in the prevalence there was an accumulative effect of AI profile with age, which may be interpreted as clear evidence that T-cell hypersensitivity increases with age (Pampiglione et al. 1975; Badaró et al. 1986a; Ali and Ashford 1993; Davies and Mazloumi Gavgani 1999), this, in fact, only reflects that older individuals (≥21 years old) have had a more exposure time to infection than younger people (1–10 and 11–20 years old); in the incidence, however, there was a decreasing effect of AI profile with age, which showed an important reduction of infection from the smallest age groups (1–10 and 11–20 years old with 30/44.8% cases each age group) towards to the older age group (≥21 years old with 7/10.4% cases), indicating that amongst the new cases of infection AI profile was principally represented by young children and adolescents; (2) all four AVL cases (SI profile) were recorded within the smallest age group (1–10 years old), confirming that AVL is typical of young children; (3) in SOI profile was found a similar distribution of cases amongst the different age groups, with 53.8% in the smallest age groups (1–10 and 11–20 years old) and 46.2% in the older age group (≥21 years old), which differs from the results found in prior study in Barcarena municipality where the mean age of SOI cases was 33 years old (Silveira et al. 2009b); (4) in SRI profile was observed in the prevalence a higher concentration of cases within the ≥21 years age group (55.8%) in relation to that found within the 1–10 and 11–20 years age groups (44.2% both), suggesting a higher presence of SRI profile amongst the individuals with older infection; however, in the incidence it was observed, in contrary, a higher concentration of cases within the 1–10 and 11–20 age groups (61.1%) in relation to that found within the ≥21-year age group (38.9%), which might be indicating a higher transmission of infection amongst younger individuals; (5) at last, it was shown in the incidence that III profile have had a higher concentration of cases within the 1–10 and 11–20 years age groups (74%) over that recorded within the ≥21 years age group (26%), suggesting again that transmission of *L. (L.) i. chagasi* to man is principally intra-domiciliary or peridomestic, where children and adolescents are particularly vulnerable (Lainson and Rangel 2003, 2005; Lainson and Shaw 2005; Silveira et al. 1997).

Regarding the dynamics evolution of infection, it should be emphasized the relevance of III profile in the context of this diagnostic approach due to its pivotal role in supplying other profiles of infection. In this way, it was shown that amongst 68 III cases recorded during this study 30 (44.1%) have evolved to AI and 21 (30.8%) to SRI profiles, which means almost 75% (74.9%) of III cases with evolution to the resistant immunological pole of infection strongly characterized by T-cell hypersensitivity. Besides these, one case (1.5%) had evolution to the susceptible immunological pole of infection (SI profile=AVL) and, 16 (23.5%) had not changed their original profile till the end of study. Thus, these results seem greatly to be in according with the proposal of this diagnostic approach (Silveira et al. 2009b), which has prior demonstrated that III cases may evolve,

depending on the genetic background of T-cell immune response (Blackwell et al. 2004; Jamieson et al. 2007), to either the resistant, SRI and AI, or the susceptible profiles, SOI and SI (Fig. 2).

Regarding the above prediction, we have also considered priority the evolution of the susceptible immunological profiles SOI and SI (=AVL) which, although have been identified with the same immune response (LST− and IFAT +++/++++), could be distinguished due, principally, to the fact that SOI cases had spontaneously developed to clinical cure in 10 (77%) amongst 13 cases recorded (eight have evolved to SRI and two to AI profiles; the last three have kept their original profile till the end of study), while typical AVL cases had required antimony therapy for developing to clinical cure (three cases have evolved to SRI, one to AI and, one had retained its original immune response but clinically asymptomatic). These observations are also in according with clinical evolution of SOI cases in Maranhão (Gama et al. 2004) and Ceará states (Holaday et al. 1993), where 33 cases in Maranhão and 12 in Ceará states have spontaneously healed. In addition, other study in Bahia state has demonstrated the capacity of SOI patients to product higher levels of IFN-γ in vitro culture of peripheral blood mononuclear cells (PBMC) than that of AVL (SI profile) patients (Bacellar et al. 1991), which might help to better understand the pathogenesis of these symptomatic forms of human *L. (L.) i. chagasi* infection.

Concerning the clinical-immunological profiles which have shown resistance against to infection, SRI and AI profiles, the impression left was that SRI seems to represent a development stage towards to AI profile once most SRI cases (77%) had negatively converted IFAT, assuming then the status of AI profile; this observation might help to explain the high frequency of AI profile which has been found in this and in prior study (Silveira et al. 2009b). On the other hand, a few AI profile cases from the prevalence showed transitory IFAT-conversion, which was interpreted as a result of a short-lived antigenic impulse produced by an abortive re-infection controlled by T-cell response. This possibility was based on the well-known ability of IL-10 to inhibit the production of INF-γ and macrophage activation, leading the infection towards to the Th2-type immune response (Bacellar et al. 2000; Blackwell et al. 2004). This might help to explain the low, transitory IFAT response found in a few AI cases. However, the clinical-immunological status of the great majority of AI cases remained unaltered, suggesting that AI profile is the end of line of infection (Fig. 2).

At last, the dynamics evolution of infection showed that only AI profile was benefited with this process, increasing its frequency from 51.6% in the accumulated prevalence to 78.3% in the final evolution of infection, whereas other profiles have had significant loss with this evolution process, such as: SI (=AVL) from 1.6% to 0.3%, SOI from

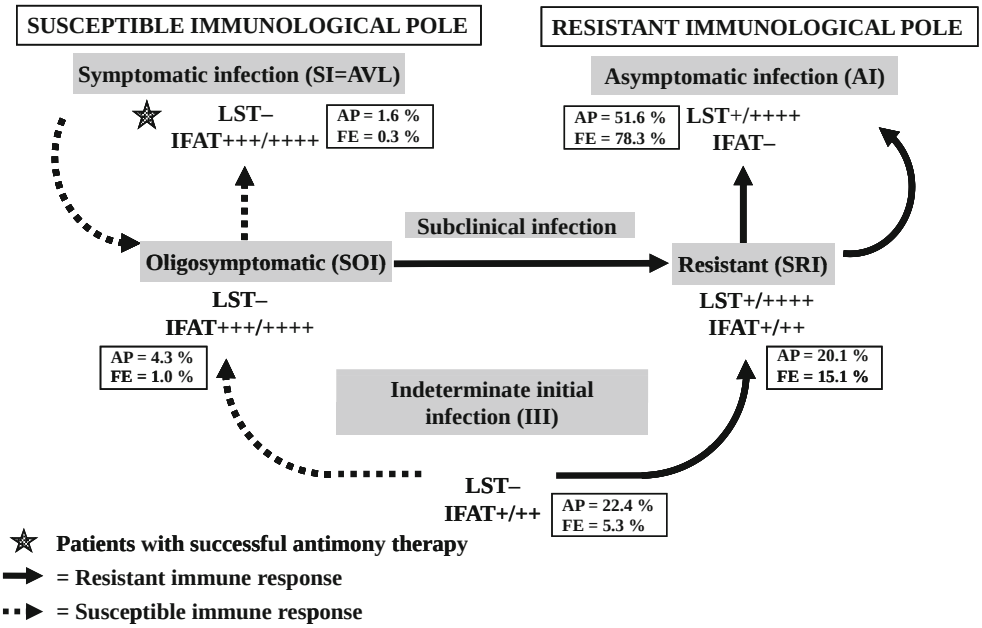


**Fig. 2** Dynamics evolution of clinical-immunological profiles of human *Leishmania (L.) infantum chagasi*-infection in Amazonian Brazil. *IFAT* indirect fluorescent antibody test (IgG). *IFAT*++++ 5,120–10,240 (IgG). *IFAT*+++ 1,280–2,560 (IgG). *IFAT*++ 320–640 (IgG). *IFAT*+ 80–160 (IgG). *IFAT*– negative reaction. *LST* leishmanin skin test. *LST*++++ exacerbate reaction (≥16 mm). *LST*+++ strong reaction (13–15 mm). *LST*++ moderate reaction (9–12 mm). *LST*+ weak reaction (5–8 mm). *LST*– negative reaction. *AI* asymptomatic infection. *SI* symptomatic infection (=*AVL*). *SOI* sub-clinical oligo-symptomatic infection. *SRI* sub-clinical resistant infection. *III* indeterminate initial infection. *AP* accumulated prevalence. *FE* final evolution of infection

4.3% to 1.0%, SRI from 20.1% to 15.1%, and principally, III profile from 22.4% to 5.3%. Thus, it seems undoubted the relevance of these new clinical-immunological profiles (SRI and III) in promoting the evolution of infection, principally III which might help to prevent the high morbidity of severe AVL cases in endemic area.

**Acknowledgements** We are grateful for the research technician team of the leishmaniasis laboratory of Evandro Chagas Institute (Health Ministry, Brazil).

**Founding** This research was supported by Evandro Chagas Institute (Health Ministry, Brazil); Tropical Medicine Institute (Federal University of Pará state, Brazil); Wellcome Trust (London); Laboratório de Investigação Médica (LIM)-50 (Hospital de Clínicas (HC)-Faculdade de Medicina (FM)-Universidade de São Paulo (USP, Brazil), and Fundação de Amparo à Pesquisa do estado de São Paulo (FAPESP: 06/56319-1, Brazil).

**Ethical approval** This study was approved by the Ethics Committee in human research of Evandro Chagas Institute (Health Ministry, Brazil), protocol number 16/2003, and the Ethics Committee of research programs, Medicine School of São Paulo University, São Paulo state, Brazil, protocol number 0255/07.

**Conflicts of interest statement** The authors have no conflicts of interest concerning the work reported in this paper.

## References

Ali A, Ashford RW (1993) Visceral leishmaniasis in Ethiopia. I. Cross-sectional leishmanin skin test in an endemic locality. Ann Trop Med Parasitol 87:157–161

Awasthi A, Mathur RK, Saha B (2004) Immune response to *Leishmania* infection. Indian J Med Res 119:238–258

Ayres M, Ayres M Jr, Ayres D, Santos AS (2004) Bioestat 4.0: Aplicações estatísticas nas áreas das Ciências Biológicas e Médicas. Sociedade Civil Mamirauá-Brasília CNPq. Belém, Pará, Brasil

Bacellar O, Barral-Neto M, Badaró R, Carvalho EM (1991) Gamma interferon production by lymphocytes from children infected with *L. chagasi*. Braz J Med Biol Res 24:791–795

Bacellar O, D'Oliveira A Jr, Jerônimo S, Carvalho EM (2000) IL-10 and IL-12 are the main regulatory cytokines in visceral leishmaniasis. Cytokine 12:1228–1231

Badaró R, Jones TC, Lorenço R, Cerf BJ, Sampaio D, Carvalho EM, Rocha H, Teixeira R, Johnson WD Jr (1986a) A prospective study of visceral leishmaniasis in an endemic area of Brazil. J Infect Dis 154:639–649

Badaró R, Jones TC, Carvalho EM, Sampaio D, Reed SG, Barral A, Teixeira R, Johnson WD Jr (1986b) New perspectives on a subclinical form of visceral leishmaniasis. J Infect Dis 154:1003–1012

Blackwell JM, Mohamed HS, Ibrahim ME (2004) Genetics and visceral leishmaniasis in the Sudan: seeking a link. Trend Parasitol 6:268–274

Brasil (2003) Ministério da Saúde. Secretaria de Vigilância em Saúde. Departamento de Vigilância Epidemiológica. Manual de Vigilância e Controle da Leishmaniose Visceral. Brasília-DF, Ministério da Saúde, pp 1–120

Costa SR, D'Oliveira A Jr, Bacellar O, Carvalho EM (1999) T cell response of asymptomatic *Leishmania chagasi* infected subjects to recombinant leishmania antigens. Mem Inst Oswaldo Cruz 94:367–370

Crescente JAB, Silveira FT, Lainson R, Gomes CMC, Laurenti MD, Corbett CEP (2009) A cross-sectional study on the clinical and immunological spectrum of human *Leishmania (L.) infantum chagasi* infection in the Brazilian Amazon region. Trans Roy Soc Trop Med Hyg. doi:10.1016/j.trstmh.2009.06.010

Davies CR, Mazloumi Gavgani AS (1999) Age, acquired immunity and the risk of visceral leishmaniasis: a prospective study in Iran. Parasitol 119:247–257

Gama MEA, Costa JML, Gomes CMC, Corbett CEP (2004) Subclinical form of the American visceral leishmaniasis. Mem Inst Oswaldo Cruz 99:889–893

Holaday BJ, Pompeu MM, Evans T, Braga DN, Texeira MJ, Sousa AQ, Sadick MD, Vasconcelos AW, Abrams JS, Pearson RD (1993) Correlates of *Leishmania*-specific immunity in the clinical spectrum of infection with *Leishmania chagasi*. J Infect Dis 167:411–417

Instituto Brasileiro de Geografia e Estatística (2004) Contagem nacional de populações. Superintendência de estudos geográficos e sócio-econômicos. Rio de Janeiro, RJ, Brasil

Jamieson SE, Miller EM, Peacock CS, Fakiola M, Wilson ME, Bales-Holst A, Shaw MA, Silveira F, Shaw JJ, Jerônimo SM, Blackwell JM (2007) Geome-wide scan for visceral leishmaniasis susceptibility genes in Brazil. Genes Immun 8:84–90

Jeronimo SMB, Teixeira MV, de Queiroz Sousa A, Thielking P, Pearson RD, Evans TG (2000) Natural history of *Leishmania (Leishmania) chagasi* infection in Northeastern Brazil: Long-term follow-up. Clin Infec Dis 30:608–609

Jeronimo SMB, Holst AK, Jamieson SE, Francis R, Bezerra FL, Ettinger NA, Nascimento ET, Monteiro GR, Lacerda HG, Miller EN, Cordell HJ, Duggal P, Beaty TH, Blackwell JM, Wilson ME (2007) Genes at human chromosome 5q31.1 regulate delayed-type hypersensitivity responses associated with *Leishmania chagasi* infection. Genes Immun 8:539–551

Lainson R, Rangel EF (2003) Ecologia das leishmanioses: *Lutzomyia longipalpis* e a eco-epidemiologia da leishmaniose visceral americana (LVA) no Brasil. In: Rangel EF, Lainson R (eds) Flebotomíneos no Brasil. Fiocruz, Rio de Janeiro, pp 311–336

Lainson R, Rangel EF (2005) *Lutzomyia longipalpis* and the eco-epidemiology of American visceral leishmaniasis, with particular reference to Brazil—a review. Mem Inst Oswaldo Cruz 100:811–827

Lainson R, Shaw JJ (2005) Leishmaniasis in the New World. In: Collier L, Balows A, Sussman M (eds) Topley & Wilson's microbiology and microbial infections, vol 5, Parasitology, 10th edn. Arnold, London, pp 313–349

Lima LVR, de Souza AAA, Jennings YL, Corrêa Z, de Jesus R, Everdosa D, Ayres M, Silveira FT (2003) Comparison of the reactivity between antigens of *Leishmania (L.) chagasi*, *L. (L.) amazonensis* e *Leishmania sp.* (Bio-Manguinhos) in the sero-diagnosis of visceral leishmaniasis by the indirect fluorescent antibody test (IFAT). Rev Inst Med Trop São Paulo 45(Supl 13):147

Pampiglione S, Manson-Bahr PEC, La Placa M, Borgatti MA, Musumeci S (1975) Studies in Mediterranean leishmaniasis: 3. The leishmanin in skin test kala-azar. Trans Roy Soc Trop Med Hyg 69:60–68

Pearson RD, Souza AQ (1996) Clinical spectrum of leishmaniasis. Clin Inf Dis 22:1–13

Silveira FT, Lainson R, Shaw JJ, de Souza AA, Ishikawa EAI, Braga RR (1991) Cutaneous leishmaniasis due to *Leishmania (Leishmania) amazonensis* in Amazonian Brazil, and the significance of a negative Montenegro skin-test in human infections. Trans R Soc Trop Med Hyg 85:735–738

Silveira FT, Shaw JJ, Bichara CNC, Costa JML (1997) Leishmaniose visceral americana. In RNG Leão, Doenças Infecciosas e Parasitárias: Enfoque Amazônico, Belém, PA, CEJUP, pp 631–644

Silveira FT, Blackwell JM, Ishikawa EA, Braga RR, Shaw JJ, Quinnell RJ, Soong L, Kima P, McMahon-Pratt D, Black GF, Shaw M-A (1998) T cell responses to crude and defined leishmanial antigens in patients from the lower Amazon region of Brazil infected with different species of *Leishmania* of the subgenera *Leishmania* and *Viannia*. Parasite Immunol 20:19–26

Silveira FT, Lainson R, Pereira EA, de Souza AAA, Campos MB, Chagas EJ, Gomes CMC, Laurenti MD, Corbett CEP (2009a) A longitudinal study on the transmission dynamics of human *Leishmania (L.) infantum chagasi*-infection in Amazonian Brazil, with special reference to its prevalence and incidence. Parasitol Res 20:19–26

Silveira FT, Lainson R, de Souza AAA, Crescente JAB, Campos MB, Gomes CMC, Laurenti MD, Corbett CEP (2009b) A prospective study on the dynamics of clinical and immunological evolution of human *Leishmania (L.) infantum chagasi*-infection in the Brazilian Amazon region. Trans Roy Soc Trop Med Hyg 104(1)

Vinhas V, Freire M, Bacellar O, Cunha S, Rocha H, Carvalho EM (1994) Characterization of T cell responses to purified leishmania antigens in subjects infected with *Leishmania chagasi*. Braz J Med Biol Res 27:1199–1205

Zijlstra EE, El-Hassan AM, Ismael A, Ghalib HW (1994) Endemic kala-azar in eastern Sudan: a longitudinal study on the incidence of clinical and subclinical infection and post-kala-azar dermal leishmaniasis. Am J Trop Med Hyg 51:826–836

**ANEXO-16**

---

Comparative study of biological behavior of two isolates of *Leishmania* characterized as *L. major-like* and *L. donovani*

Duarte, M.I.S.; **Laurenti, M.D.;** Andrade Junior, H.; Corbett, C.E.P.

Revista do Instituto de Medicina Tropical de São Paulo 1988; 30(1): 21-27

anexo 16

*Rev. Inst. Med. trop. São Paulo*
30 *(1): 21-27, janeiro-fevereiro, 1988*

# COMPARATIVE STUDY OF THE BIOLOGICAL BEHAVIOUR IN HAMSTER OF TWO ISOLATES OF LEISHMANIA CHARACTERIZED RESPECTIVELY AS L. major-like AND L. donovani.

M. I. S. DUARTE (1), M. D. LAURENTI (1), H. F. ANDRADE JR. (1, 2) & C. E. P. CORBETT (1)

## SUMMARY

Hamster inoculated intraperitoneally with 1 x $10^7$ parasites of **L. donovani** and **L. major**-like of the New World were studied in groups of 15, 30, 60 and 90 days of infection. The parasite load and density showed progressive increase with the evolution of the infection and was higher in the **L. donovani** groups than in the **L. major**-like groups. The **L. major**-like groups showed parasite density higher in the spleen than in the liver and was similar in both organs in **L. donovani** groups. The histopathology showed a diffuse marked hyperplasia and hypertrophy of the reticuloendothelial system with high parasitism in the **L. donovani** groups while there was focal involvement of these organs in **L. major**-like groups, forming nodules of macrophages that were scantly parasitised.

The biological behaviour could be useful in the preliminary studies of **Leishmania** strain in regional laboratories and understanding the histopathology of lesions caused by different leishmania species.

**KEY WORDS:** Leishmania; **L. donovani; L. major**-like; Experimental infection.

## INTRODUCTION

The leishmanias are intracellular parasites whose tissue tropism vary from species to species. The infection caused by **L. donovani** shows visceral involvement with predilection for organs rich in reticuloendothelial tissue such as spleen, liver and bone marrow (ADLER, 1963; BRAY, 1974; BRADLEY & KIRKLEY, 1977 and MELENEY, 1925). The cutaneous leishmaniasis, such as those caused by the **L. tropica** and **L. major** in the Old World and **L. brasiliensis** and **L. mexicana** in the New World, show a parasite preference for skin in spite of the detection of cryptic infections in other organs of experimental animals (COUTINHO & COELHO, 1972; SCHNUR, ZUCKERMAN & MONTILO, 1973).

Previous studies on **L. donovani** in hamsters showed an inverse correlation between the mean lifetime and the number of parasites in the inoculum and a direct correlation with the final parasitism of the spleen and liver (STAUBER, 1958). The inoculation route is also important in the development of the disease (BRADLEY & KIRKLEY, 1977; OTT, HANSON & STAUBER, 1967 and STAUBER, 1958). The differentiation of species of leishmanias using biological beha-

(1) Departamento de Patologia da Faculdade de Medicina da Universidade de São Paulo.
(2) Instituto de Medicina Tropical de São Paulo — Laboratório de Protozoologia.
**Address for correspondence:** Dra. Maria Irma Seixas Duarte. Faculdade de Medicina da Universidade de São Paulo, Departamento de Patologia — Av. Dr. Arnaldo, 455 — 1º andar — sala 26 — CEP 01246 São Paulo, SP, Brasil.

viour in hamsters has revealed many problems. We do not know of any quantitative studies comparing visceral involvement of different species, but we think, that this could be useful for initial studies using the analysis of the biological behaviour of new isolates for differention of the leshmania species.

The histopathological study of experimental visceral leishmaniasis has been carried out by many authors (GELLHORN, et al., 1946; GUTIERREZ, MAKSEN & REINER, 1984; MELENEY, 1925; RITTERSON, 1955; ZUCKERMAN & LAINSON, 1977). We have been studying the histopathology of various organs from experimental visceral leishmaniasis in hamster and have previously described the visceral changes which occur (DUARTE & CORBERTT, 1984; DUARTE, SESSO & BRITO, 1978).

In our laboratory working with a strain of **Leishmania**, isolated from the liver of a dog from an endemic area of human visceral leishmaniasis, we found, in hamster, parasite proliferation in liver and spleen with no evident involvement of the skin. This strain was earlier characterized as **L. donovani** but a new identification using biochemical and immunological methods (MOMEN et al., 1984; PACHECO, 1985 and SHAW, 1985 — personal communication) established as being a **L. major**-like. However, the visceral involvement was much more benign than that found in visceral leishmaniasis caused by a well characterized strain of **L. donovani chagasi.**

In this work we have carried out a comparative study of the parasitism and the histopathology of the spleen and liver of infected hamsters looking for a possible differentiation between the **L. donovani** and **L. major**-like isolated in the New World.

## MATERIAL AND METHODS

**Animals**: male, outbread, hamsters, age 45-60 days old, from the University of São Paulo Medical School General Colony and kept in our laboratory were used (VAN JOOST & SLUTERS, 1972).

**Parasites: L. donovani** (MHOM/BR/72/LD 46) was isolated by Dr. W. Mayrink, Federal University of Minas Gerais, Brazil, in October, 1972, from an human case of visceral leishmaniasis comming from Mantena (MG). The parasite was isolated using bone marrow aspirate and inoculated into hamsters. We have maintained this parasite by inoculation every three months. It was characterized at the Wellcome Parasitology Unit, Instituto Evandro Chagas, Belém, PA, using monoclonal antibodies and by isoenzyme methods, in 1985 (SHAW — personal communication).

**L. major**-like (MCAN/BR/73/LD 70) isolated by Dr. Magno Dias, Federal University of Minas Gerais, from liver of a dog from Conselheiro Pena (MG) in 1973. It was maintained in the laboratory by sub-inoculations every three months (PACHECO, 1985; SHAW, 1985 — personal communication).

Eight experimental groups of hamsters infected with either **L. donovani** or with **L. major**-like with at least four survining animals. Each animal was inoculated intraperitoneally with 1 x $10^7$ amastigotes, determined by the Stauber method (STAUBER, 1958) at intervals of 15, 30, 60 and 90 days after inoculation. Fragments from the liver and spleen were processed for light microscopy and for parasite load determination. Fragments from spleen and liver were fixed in buffered 10% formalin solution (pH 7.2) and processed by usual histopathological techniques and stained with haematoxylin-eosin.

The spleen and liver smears were fixed in methanol and stained by Giemsa's method. The parasite load of the spleen and liver were calculate by determining the number of amastigotes found per 1000 nuclei of the organs cells x 2 x $10^5$ (STAUBER, 1958). The parasite density was obtained by dividing the parasite load of the organ by its weight in milligrams (STAUBER, 1958). Statistical analysis was performed using Students "t" test, with 0,05 significance levels.

## RESULTS

The distribution of the spleen and liver parasite load can be seen in table 1. There was a progressive increase of parasite in both species. The increase was bigger in animals infected with **L. donovani** than in those inoculated with **L.**

DUARTE, M. I. S.; LAURENTI, M. D.; ANDRADE Jr., H. F. & CORBETT, C. E. P. — Comparative study of the biological behaviour in hamster of two isolates of **Leishmania** characterized respectively as **L. major**-like and **L. donovani**. **Rev. Inst. Med. trop. São Paulo, 30 (1)**: 21-27, 1988.

TABLE 1

Parasite load and density of **L. donovani** and **L. major**-like in the spleen and liver of hamster.

| | | | | Spleen | | | Liver | | |
|---|---|---|---|---|---|---|---|---|---|
| Experimental group | Number of animals | Time of infection (days) | Strain | Weight (mg) ± standard error (S.E.) | Parasite load § ($10^6$) ± S.E. | Parasite density & ($10^3$) ± S.E. | Weight (mg) ± S.E. | Parasite load ($10^6$) ± S.E. | Parasite density ($10^3$) ± S.E. |
| I | 9 | 15 | L. donovani | 143,33 ± (31,89) | 2,39 ± (1,59) | 10,60 ± (5,03) | 4413,33 ± (387,67) | 54,63 ± (24,24) | 12,73 ± (5,92) |
| II | 10 | 30 | L. donovani | 244,00 ± (20,23) | 13,02 ± (4,14) | 46,60 ± (12,95) | 4118,00 ± (205,54) | 177,66 ± (66,67) | 47,99 ± (16,90) |
| III | 6 | 60 | L. donovani | 366,67 ± (37,21) | 496,66 ± (150,50) | 1422,91 ± (521,00) | 5175,00 ± (198,42) | 4383,00 ± (1198,17) | 842,60 ± (226,00) |
| IV | 4* | 90 | L. donovani | 530,00 ± (82,86) | 700,70 ± (438,46) | 2017,00 ± (1541,00) | 4757,00 ± (650,00) | 1897,47 ± (1260,70) | 498,00 ± (373,00) |
| V | 6 | 15 | L. major-like | 253,33 ± (92,00) | 0,42 ± (0,11) | 2,10 ± (0,60) | 3783,00 ± (152,00) | 8,43 ± (2,76) | 2,21 ± (0,75) |
| VI | 7 | 30 | L. major-like | 324,33 ± (31,00) | 1,73 ± (0,69) | 6,10 ± (2,67) | 5184,00 ± (213,00) | 10,58 ± (3,00) | 2,14 ± (0,64) |
| VII | 5 | 60 | L. major-like | 220,00 ± (20,98) | 3,97 ± (1,51) | 18,90 ± (8,37) | 3606,00 ± (477,05) | 22,48 ± (13,05) | 7,75 ± (5,60) |
| VIII | 5 | 90 | L. major-like | 284,00 ± (15,03) | 9,90 ± (5,34) | 37,20 ± (21,80) | 4578,00 ± (156,76) | 57,40 ± (30,66) | 16,70 ± (6,69) |

* 6 died before the 90th day. — § Number of amastigotes per 1000 nuclei of tissue cells x $2x10^5$
& Number of amastigotes per milligram of the organ.

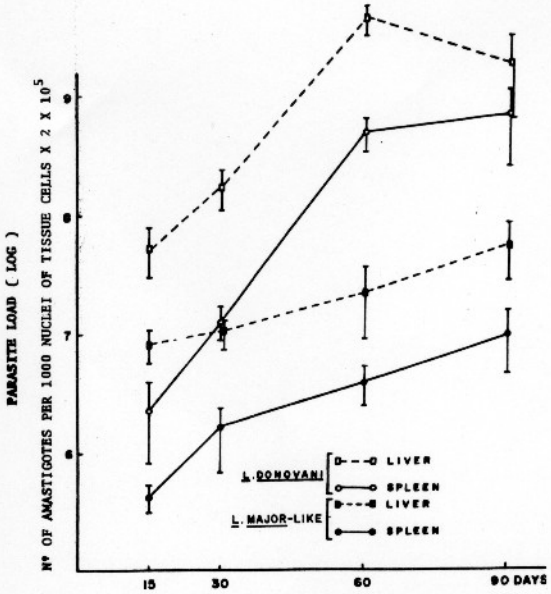


Fig. 1 — Evolution of the parasite load in liver and spleen of hamster inoculated with **L. donovani** and **L. major**-like.

**major**-like and the difference was significant ($p < 0,05$) from the 15th day of infection onwards (Fig. 1).

The parasite density, i. e., the number of parasites per milligram of the organ (Fig. 2) showed clear differences in the behaviour of these two strains.

The **L. donovani** groups showed a faster proliferation of parasites than the **L. major**-like groups ($p < 0,05$). The parasite density in the spleen and liver in all **L. donovani** groups was similar. Nevertheless in the **L. major**-like group this density was significantly higher in the spleen than in the liver with a ($p < 0.10$ and $p > 0.05$, respectively). The 90 day **L. donovani** group had only 4 animals because the other 6 had died before this time. These animals showed high parasitism of the spleen and liver and marked typical histopathological lesions of the disease.

DUARTE, M. I. S.; LAURENTI, M. D.; ANDRADE Jr., H. F. & CORBETT, C. E. P. — Comparative study of the biological behaviour in hamster of two isolates of **Leishmania** characterized respectively as **L. major**-like and **L. donovani**. **Rev. Inst. Med. trop. São Paulo, 30 (1)**: 21-27, 1988.

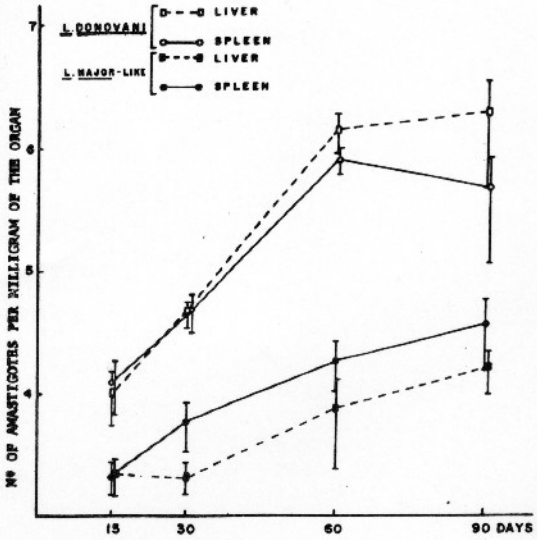


Fig. 2 — Evolution of the parasite density in liver and spleen of hamsters inoculated with **L. donovani** and **L. major**-like.

The histopathological analysis of the lesions in all groups gradually increased with time and a difference between the **L. donovani** and **L. major**-like involvement was noticed. In spite of all groups showing histopathological lesions increasing with the time there was a different pattern of involvement in the **L. donovani** group and in **L. major**-like group. The changes were more diffuse in the **L. donovani** group and nodular in the **L. major**-like group. In each parasite species group the type of histopathological involvement was similar varying only in intensity with the time of infection.

The spleen and liver reticuloendothelial system was highly parasitized from the begining in **L. donovani** infected animals. The early liver changes (15 days infection) were moderate diffuse hyperplasia and hypertrophy of the Küpffer cells with discreet parasitism. Intralobular aggregates of the phagocytic cells with high parasitism were irregulary distributed within the hepatic lobules, with no preference for any particular zone. The portal spaces showed mild infiltration by lymphocytes, plasma cells and macrophages, some of them containing leishmanias. After 30 days of infection there was an increase in the hypertrophy and hyperplasia of the Küpffer cells and also higher parasitism. At the same time there was a decrease of the intralobular macrophage aggregates and portal mononuclear cells began to infiltrate the lesions (Fig. 3).

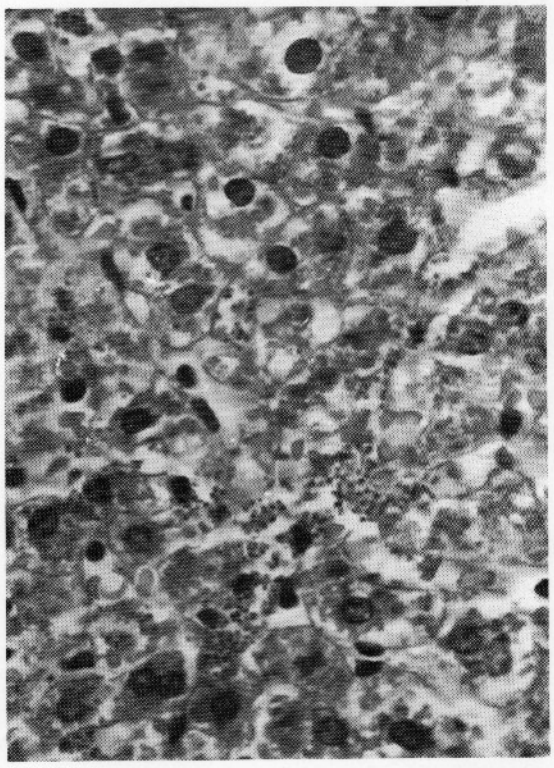

Fig. 3 — Liver from **L. donovani** group 60 days after infection: diffuse hypertrophy and hyperplasia of the Küpffer cells with severe parasitism (x 506,9).

The parasite density in the liver was lower with **L. major**-like than with **L. donovani**. The histopathology of the **L. major**-like group showed multi-focal lesions with no diffuse reticuloendothelial system hyperplasia as seen in **L. donovani** group. The most frequent histopathological changes found were intralobular inflammatory nodules scattered throughout the parenchyma. These nodules were made up of macrophages together with lymphocytes forming small aggregates where the leishmanias were either few or absent. There was also mild hyperplasia of the Küpffer cells which did not show any parasitism. The portal spaces presented discreet infiltration by lymphocytes and macrophages up to 30 days of infection groups and moderate in the others two which showed also an increase of plasma cells (Fig. 4).

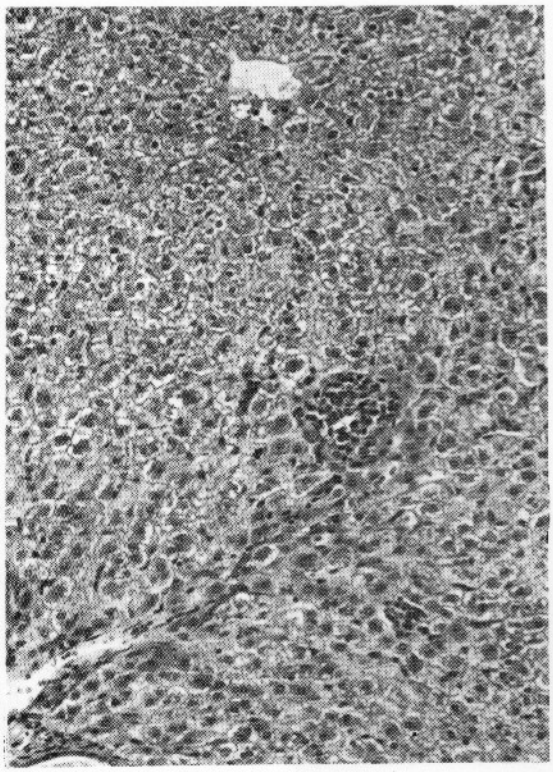

Fig. 4 — Liver from **L. major**-like group 60 days after infection: intralobular nodules of macrophages, lymphocytes and plasma cells. There was scanty parasitism. (x 126,7).

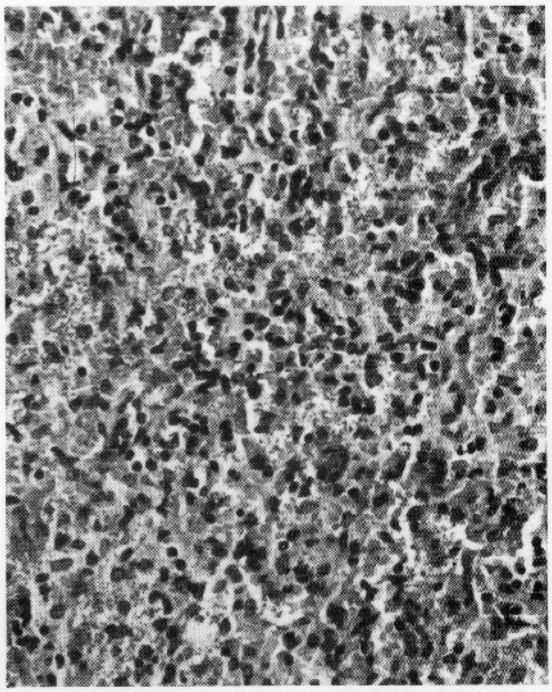

Fig. 5 — Spleen from **L. donovani** group 60 days after infection: diffuse hypertrophy and hyperplasia of the reticuloendothelial system with high parasitism. (x 253,4).

In the spleen the most prominent changes found in the **L. donovani** groups were diffuse hyperplasia and hypertrophy of the reticuloendothelial system within the sinusoids increasing in intensity in the other groups accompanied by marked parasitism (Fig. 5). On the other hand the **L. major**-like groups showed mainly nodules made up of macrophages with either mild or moderate parasitism scattered in the red pulp of the spleen (Fig. 6). In the oldest group there was also mild diffuse hyperplasia of the reticuloendothelial system. The lymphoid follicles of the white pulp moderately increased in volume with hyperplasia and parasitism of the macrophagic cells in the **L. donovani** group. In the **L. major**-like groups there were discreet increase in the germinative centers with mild hyperplasia of the macrophages and occasional parasites were seen. The T-lymphocytes density in the lymphoid follicles was decreased only in the 90 days old **L. donovani** groups.

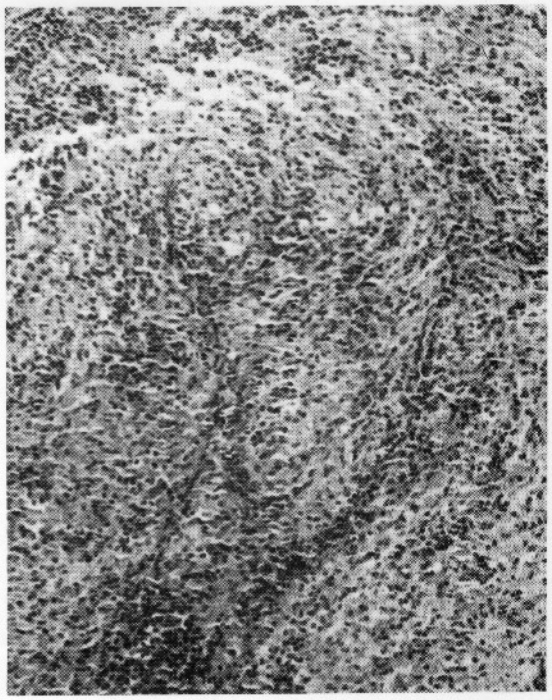

Fig. 6 — Spleen from **L. major**-like group 60 days after infection: hypertrophy and hyperplasia of the mononuclear phagocitic cells arranged in nodules with rare parasites. (x 126,7).

There was no change in the lymphocyte density either in the B or T dependent zone, in any the **L. major**-like groups.

## DISCUSSION

The **L. donovani** group presented a parasite load and density higher than the **L. major**-like group in spleen and liver. However, the **L. major**-like group showed higher concentration in the spleen than in the liver while the **L. donovani** groups showed no difference in these organs. The histopathology also showed significant differences between there two groups. The **L. donovani** groups had a more diffuse involvement with severe reactivity of the reticuloendothelial system and high parasitism. The **L. major**-like groups showed focal involvement with intralobular macrophages nodules scaterred, throughout the organs, with few or no leishmania found into these nodules. There was low reactivity of the reticuloendothelial system where no parasite was seen. These differences seem to be determined by the two species studied (HOMMEL, 1978; MAUEL & BEHIN, 1982). Even with the outstanding taxonomic problems related to the leishmanias species of the New World (GARDENER, 1977; HOMMEL, 1978) it is accepted that the **L. donovani** has a tropism for the viscera (ADLER, 1963; BRAY, 1974; BRADLEY & KIRKLEY, 1977) and the **L. major**-like for the skin (BRAY, 1974; ZUCKERMAN & LAINSON, 1977). Using biochemical methods and monoclonal antibodies (MOMEN et al., 1984; PACHECO, 1985; SHAW, 1985 — personal communication) this strains of a neotropical **leishmania** have recently been identified as **L. major**-like. However, the strain used in the present studied is different from the **L. major**, reference strain, in relation to the KDNA restriction enzymes analysis (MOMEN et al., 1985; PACHECO, 1985).

Strain MCAN/BR/73/LD70 was originally, isolated from dog liver and has not showed cutaneous tropism when inoculated intraperitoneally in hamsters.

Others strains in the New World have been identified as **L. major**-like but there have been considered in some cases as result of laboratory "mix-ups" (SHAW, personal communication). The exact nature of **L. major**-like strains from Brazil must be investigated in greater detail. Epidemiological studies and identifications of new isolates must now be performed.

In conclusion we feel that it is very important to investigate the biological behaviour of new isolates for initial studies of different leishmania species which together with clinical and epidemiological observations will be useful for the understanding of the pathological changes causes by each species. Both studied species showed significant biological behaviour differences between them indicating that, such differences can be detectedusing quantitative and histopathological methods.

## ACKNOWLEDGEMENTS

This work was supported by FINEP — 43/86/0361/00.

We thank Maria Lúcia G. B. Barits for the technical assistance.

## RESUMO

**Estudo comparativo do comportamento biológico de dois isolados de** Leishmania **caracterizados respectivamente como** L. major-**like e** L. donovani, **em hamster.**

Experimentos utilizando-se hamsters inoculados intraperitonealmente com 1 x $10^7$ parasitas de 2 cepas, **L. donovani** (MHOM/BR/72/LD 46) e **L. major**-like (MCAN/BR/73/LD 70) isoladas no Novo Mundo foram realizados e estudados em grupos de 15, 30, 60 e 90 dias de infecção. A carga e a densidade parasitária mostraram progressivo aumento com a evolução da infecção e foi maior nos grupos inoculados com **L. donovani** do que nos grupos inoculados com **L. major**-like. Os grupos inoculados com **L. major**-like mostraram densidade parasitária maior no baço que no fígado e foram semelhantes em ambos os órgãos nos grupos inoculados com **L. donovani**. A histopatologia mostrou intensa e difusa hiperplasia e hipertrofia do sistema reticuloendotelial com alto parasitismo nos grupos inoculados com **L. donovani**, enquanto foi encontrado envolvimento focal nestes órgãos nos grupos inoculados

com **L. major**-like, formando nódulos de macrófagos discretamente parasitados.

O comportamento biológico seria útil em estudos preliminares de identificação de cepas de **Leishmania** em laboratórios regionais e na compreensão da histopatologia das lesões causadas por diferentes espécimes de leishmanias.

## REFERENCES


1. ADLER, S. — Immunity to protozoa. Oxford, Blackwell Scientific Publication, 1963. p. 235.

2. BRAY, R. S. — Leishmania. **Ann. Rev. Microbiol., 28**: 189-217, 1974.

3. BRADLEY, D. J. & KIRKLEY, J. — Regulation of Leishmania populations within the host. I. The variable course of **L. donovani** infections in mice. **Exp. Immunol., 30**: 119-129, 1977.

4. COUTINHO, E. & COELHO, M. V. — Leishmaniose tegumentar experimental. III. Patologia comparada da infecção de amostras de **L. braziliensis, L. mexicana** e **L. tropica**, em animais de laboratório. **Rev. Inst. Med. trop. S. Paulo, 14**: 12-29, 1972.

5. DUARTE, M. I. S. & CORBETT, C. E. P. — Histopathological and ultra-estructural aspects of interstitial pneumonitis of experimental visceral leishmaniasis. **Trans. roy. Soc. trop. Med. Hyg., 78**: 683-688, 1984.

6. DUARTE, M. I. S.; SESSO, A. & BRITO, T. — Relationship between glomerular mesangial cell proliferation and amiloid deposition as seen by ultrastructural and morphometric analysis in experimental Kala-azar of the hamster. **Amer. J. Path., 92**: 157-173, 1978.

7. GARDENER, P. J. — Taxonomy of the genus Leishmania. A review of nomenclature and classification. **Trop. Dis. Bull., 74**: 1069-1088, 1977.

8. GELLHORN, A.; VAN DYKE, D. B.; PYLES, W. J. & TUPIKOVA, N. A. — Amyloidosis in hamster with leishmaniasis. **Proc. Soc. exp. Biol. (N. Y.), 61**: 254, 1946.

9. GUTIERREZ, Y.; MAKSEN, J. A. & REINER, N. E. — Pathologic changes in murine Leishmaniasis (**L. donovani**) with special reference to the dynamics of granuloma formation in the liver. **Amer. J. Path., 144**: 222-230, 1984.

10. HOMMEL, M. — The genus Leishmania: biology of the parasites and clinical aspects. **Bull. Inst. Pasteur, 76**: 5-112, 1978.

11. MAUEL, J. & BEHIN, R. — Leishmaniasis: immunity, immunopathology and immunodiagnosis. In: COHEN, S. & WARREN, K. W., ed. — **Immunology of parasitic infections.** 2nd. ed. London, Blackwell Scientific Publication, 1982. p. 300-355.

12. MELENEY, H. E. — The histopathology of Kala-azar in the hamster, monkey and man. **Amer. J. Path., 1**: 147, 1925.

13. MOMEN, H.; GRIMALDI Jr., G.; PACHECO, R. S.; JAFFE, C. L.; McMAHON-PRATT, D. & MARZOCHI, M. C. A. — Brazilian Leishmania stocks phenotypically similar to **L. major. Amer. J. trop. Med. Hyg., 34**: 1076-1084, 1985.

14. OTT, K. J.; HANSON, W. L. & STAUBER, L. A. — Course of infection of **L. donovani** in hamsters inoculated by the intraperitoneal route. **J. Parasit., 53**: 641-645, 1967.

15. PACHECO, R. S. — Caracterização de cepas e clones de Leishmania pela análise do DNA do cinetoplasto por enzimas de restrição e por hibridização molecular. Rio de Janeiro, 1985. (Tese de Mestrado — Instituto Oswaldo Cruz (FIOCRUZ).

16. RITTERSON, A. L. — Leishmaniasis in golden hamster. **J. Parasit. 41**: 603-612, 1955.

17. SCHNUR, L.; ZUCKERMAN, A. & MONTILO, B. — Dissemination of leishmanias to the organs of Syrian Hamsters following intra-splenic inoculation of promastigotes. **Exp. Parasit., 34**: 432-447, 1973.

18. SHAW, J. J. — Personal communication, 1985.

19. STAUBER, L. A. — Host resistence to the klartoun strain of **L. donovani. Rince Institut Pamphect, 45**: 80-96, 1958.

20. VAN JOOST, K. S. & SLUTERS, J. F. — Appearance of **L. donovani** (Kenya strain) in the blood of experimentaly infected golden hamsters **(Mesocricetus auratus). Trop. geogr. Med., 24**: 292-297, 1972.

21. ZUCKERMAN, A. & LAINSON, R. — 3. Leishmania. In: KREIER, J. P., ed. **Parasitic protozoa.** London, Academic Press, 1977. v. 1, p. 57-133.


Recebido para publicação em 31/03/1987.

**ANEXO-17**

---

Experimental visceral leishmaniasis: sequential events of granuloma formation at subcutaneous inoculation site

**Laurenti, M.D.;** Sotto, M.N.; Corbett, C.E.P.; da Matta, V.L.R.; Duarte, M.I.S.

International Journal of Experimental Pathology 1990; 71(6): 791-797

*Int. J. Exp. Path.* (1990), **71**, 791–797

# Experimental visceral leishmaniasis: sequential events of granuloma formation at subcutaneous inoculation site

Márcia Dalastra Laurenti, Mírian Nacagami Sotto, Carlos Eduardo Pereira Corbett, Vânia Lúcia Ribeiro da Matta and Maria Irma Seixas Duarte

*Infectious Disease Pathology Laboratory, Department of Pathology, University of São Paulo Medical School, São Paulo, SP, Brazil*

Received for publication 13 October 1989
Accepted for publication 20 June 1990

**Summary.** Hamsters were inoculated with $10^7$ *Leishmania (Leishmania) chagasi* amastigotes in the hind footpads and killed at 7, 15, 30, 45, 60, 75 and 90 days after infection. We observed mononuclear inflammatory infiltrates with many parasites on the 7th and 15th days of infection. On the 30th day there was early granuloma formation. After 45 days the lesion was characterized by well defined epithelioid granuloma with multinuclear giant cells whose cytoplasm showed Schaumann bodies. Non-particulate antigenic material was present in the macrophage cytoplasm and between the lamellae of the Schaumann bodies. Granuloma formation has an important role for the control of infection at the inoculation site. The results indicate that dissemination of the infection must occur in the first 45 days, before granuloma formation has taken place.

Keywords: visceral leishmaniasis, *Leishmania (Leishmania) chagasi*, pathology, granuloma, immunoperoxidase

The histopathology of different organs involved in visceral leishmaniasis has been described by many authors (Ritterson 1955; Duarte *et al.* 1983; Duarte & Corbett 1984, 1987; Gutiérrez *et al.* 1984) but very little is known about the cutaneous changes which occur after parasite inoculation by mosquito bites.

Manson-Bahr (1955) and Sen Gupta and Das Gupta (1951) described a leishmania-induced granuloma at the site of subcutaneous inoculation with promastigotes in human volunteers. It was histologically characterized by a granulomatous reaction with round cells, lymphocytes, plasma cells and large macrophages with parasites and late giant and epithelioid cell formation. This reaction persisted even when well defined visceral leishmaniasis lesions developed (Manson-Bahr 1959; Manson-Bahr *et al.* 1963).

The early histopathological changes after subcutaneous inoculation of promastigotes of *Leishmania donovani* in hamsters (Wilson *et al.* 1987), started with an infiltrate of mainly polymorphonuclear neutrophils and some macrophages with phagocytosis of parasites. After 24 h the infiltrate was composed

Correspondence: Márcia Dalastra Laurenti, Faculdade de Medicina da USP, Depto. de Patologia, Av. Dr. Arnaldo, 455, 1º andar, sala 26, CEP: 01246, São Paulo, SP, Brasil.

mainly of mononuclear cells with posterior granuloma formation. Dissemination of the infection was detected after 8 weeks by the presence of parasites in the mononuclear phagocytic cells of the liver and spleen.

This study was designed to investigate the histopathological changes which develop at the site of subcutaneous inoculation of *Leishmania (Leishmania) chagasi* in the hind footpads of the hamster with special attention to parasite antigen kinetics and to granuloma formation.

## Material and methods

### *Animals*

Male 45–60 days old outbred hamsters (*Mesocricetus auratus*) were used, obtained from University of São Paulo Medical School General Colony.

### *Parasites*

*Leishmania (Leishmania) chagasi* (MHOM/BR/72/strain 46). A hamster with approximately 3 months infection was killed and the spleen removed and weighed. The parasites in spleen smears stained by Giemsa's method were counted. The spleen parasite load was calculated by determining the number of amastigotes found per 1000 spleen cell nuclei × spleen weight (mg) × $2 \times 10^5$ (Stauber 1958). The spleen was homogenized in a glass-tissue grinder and adjusted with saline to give a concentration of $1 \times 10^7$ amastigotes/0.1 ml.

### *Infection*

Seven experimental groups, each with five animals, were inoculated s.c. with *L. (L.) chagasi* in the hind footpads with $10^7$ amastigotes. There were two control animals in

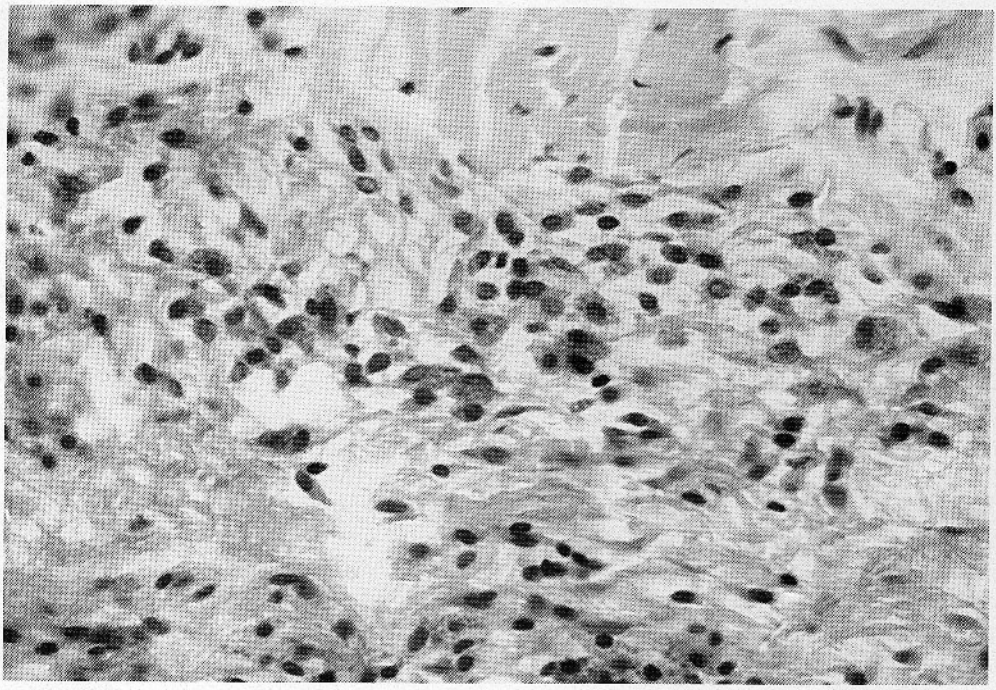

**Fig. 1.** Lymphocyte and macrophage infiltrate in the deep dermis. Many leishmania are present. H&E × 586.

each experimental group, inoculated with 0.1 ml of normal spleen homogenate.

The animals were killed at 7, 15, 30, 45, 60, 75 and 90 days after infection. Fragments from the hind footpads, spleen and liver were fixed in buffered 10% formalin solution, pH 7.2, and processed by usual histopathological techniques and stained with haematoxylin–eosin.

Imprints from liver and spleen were fixed with methanol and stained by Giemsa's method.

Fragments from the hind footpads were stained by the immunoenzymatic peroxidase–antiperoxidase (PAP) method using polyclonal anti-leishmania serum produced in rabbit for the detection of parasite antigens. The same fragments were also reacted with anti-leishmania serum absorbed with a pellet of both amastigotes and promastigotes parasites to confirm the specificity of the method (Sotto *et al.* 1989).

Livers from experimentally infected hamsters were used as positive controls.

## Results

Histopathological changes at the inoculation site, hind footpads, on the 7th day were characterized by a mild inflammatory infiltrate of macrophages, plasma cells and lymphocytes and intra and extra-cellular parasites into the deep dermis (Fig. 1). From the 15th day there was spread of infection to the muscular layer with many parasites. On the 30th day there was a diffuse mononuclear inflammatory infiltrate and an initial granuloma formation and reduction in the number of parasites. At the 45th day the lesion was characterized by well defined epithelioid granulomas, a few polymorphonuclear neutrophils among the macrophages and very few remaining parasites (Fig. 2). At this time the multinuclear giant cell cytoplasm contained

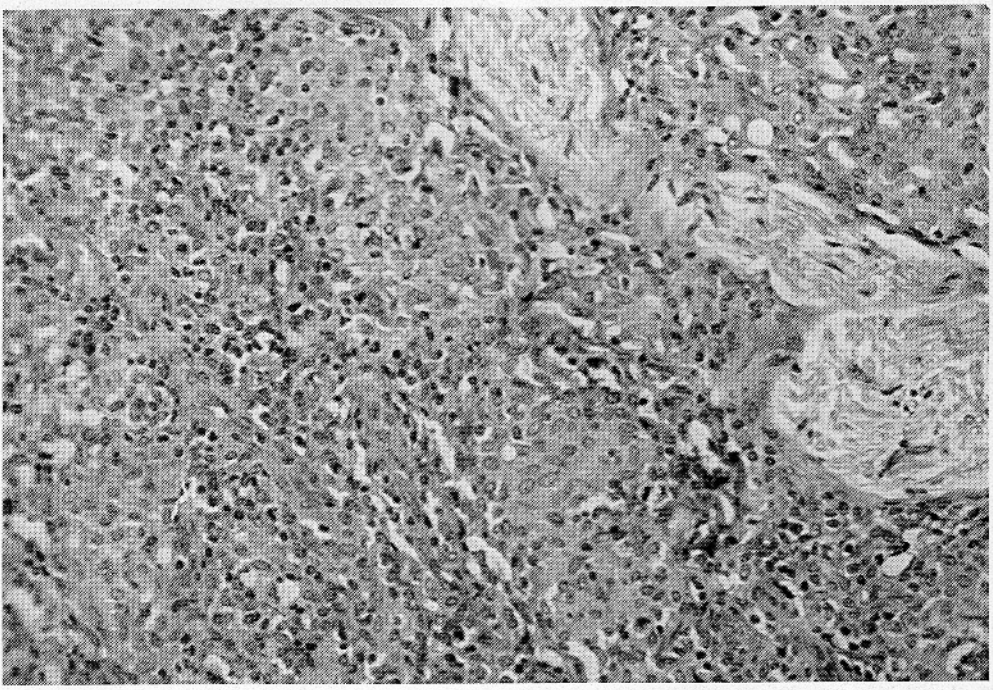

**Fig. 2.** Epithelioid granulomas near to a nerve. H&E × 293.

round, lamellar, concentric and basophilic structures known as Schaumann bodies (Fig. 3). Similar structures were also seen as small aggregates within macrophages. This pattern, seen at the 45th day, was also present in the 60-, 75- and 90-day infection groups.

Visceral leishmania were demonstrated 45 days after infection. Amastigotes of *L. (L.) chagasi* were found in the mononuclear phagocytic system in the liver and spleen by histopathological and imprint observations (Fig. 4a, b).

Leishmania antigen was detected with specific antibodies using the peroxidase–antiperoxidase immunoenzymatic method (PAP). Numerous amastigotes were identified after 7, 15, and 30 days infection but were uncommon at later times after infection.

Non-particulate antigenic material was also present in the cytoplasm of macrophages and multinuclear giant cells within granulomas (Fig. 5) after 45, 60, 75 and 90 days of infection. The same antigenic material was seen between the lamellae of the Schaumann bodies within giant cell cytoplasm (Fig. 6a).

Fusiform subepidermal cells with non-particulate antigenic material within the cytoplasm were found 90 days after infection (Fig. 6b).

The PAP reaction, using antiserum previously absorbed with parasites, did not reveal leishmania antigen in any group.

## Discussion

Inoculation of *L. (L.) chagasi* in the hind footpads of hamsters produced an inflammatory infiltrate, mainly mononuclear, rich in parasites 7 and 15 days after infection. Macrophages at the 30th day had a tendency

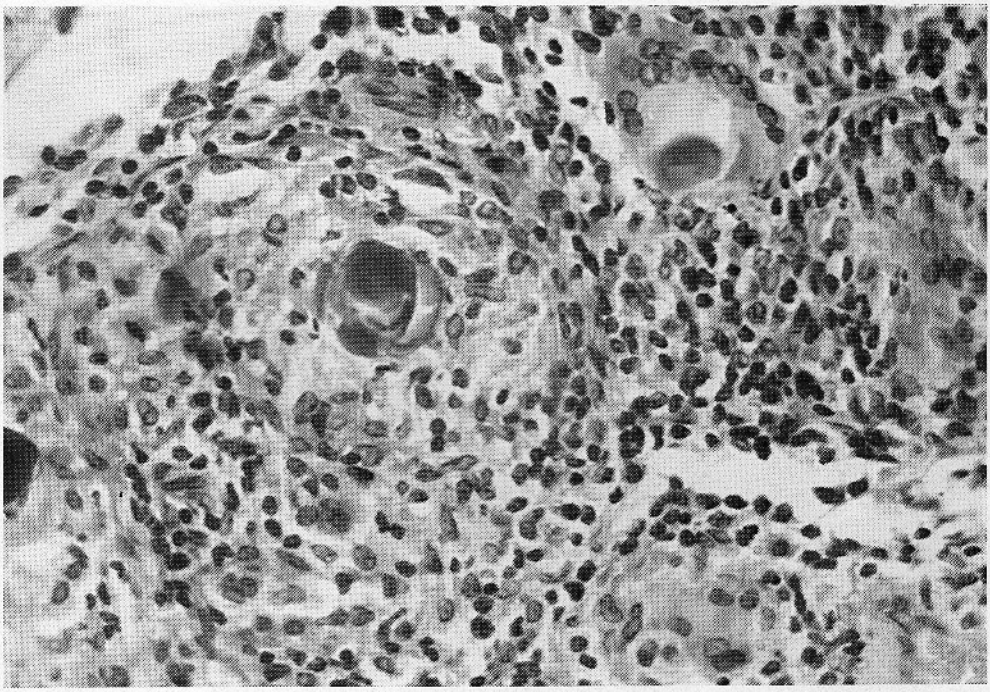

Fig. 3. Schaumann bodies within a multinuclear giant cell and in the centre of a small granuloma. H&E × 586.

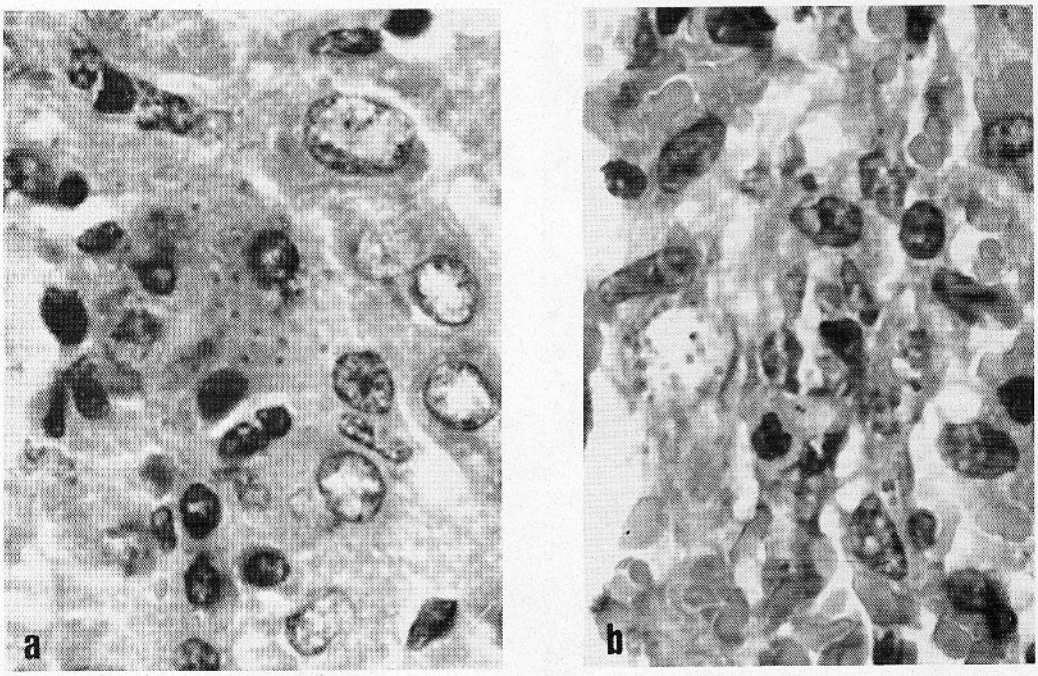


**Fig. 4.** Parasitized macrophages in a, the liver and b, the spleen. H&E × 1465.

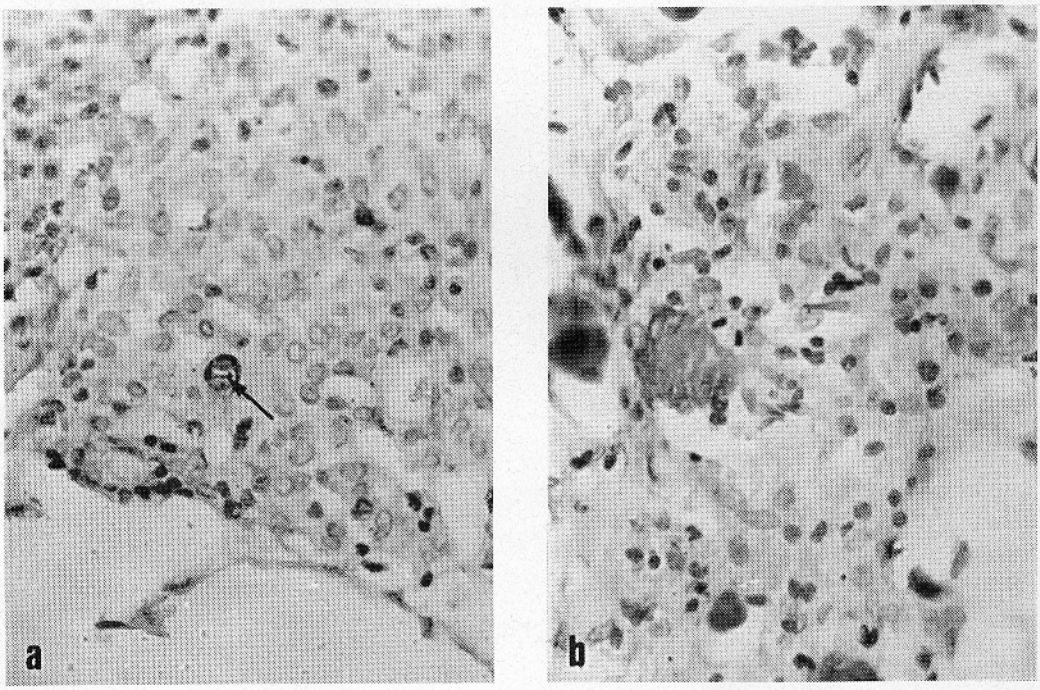


**Fig. 5.** Leishmania antigen within a, macrophage cytoplasm (arrow) and b, in multinuclear giant cell. PAP × 586.

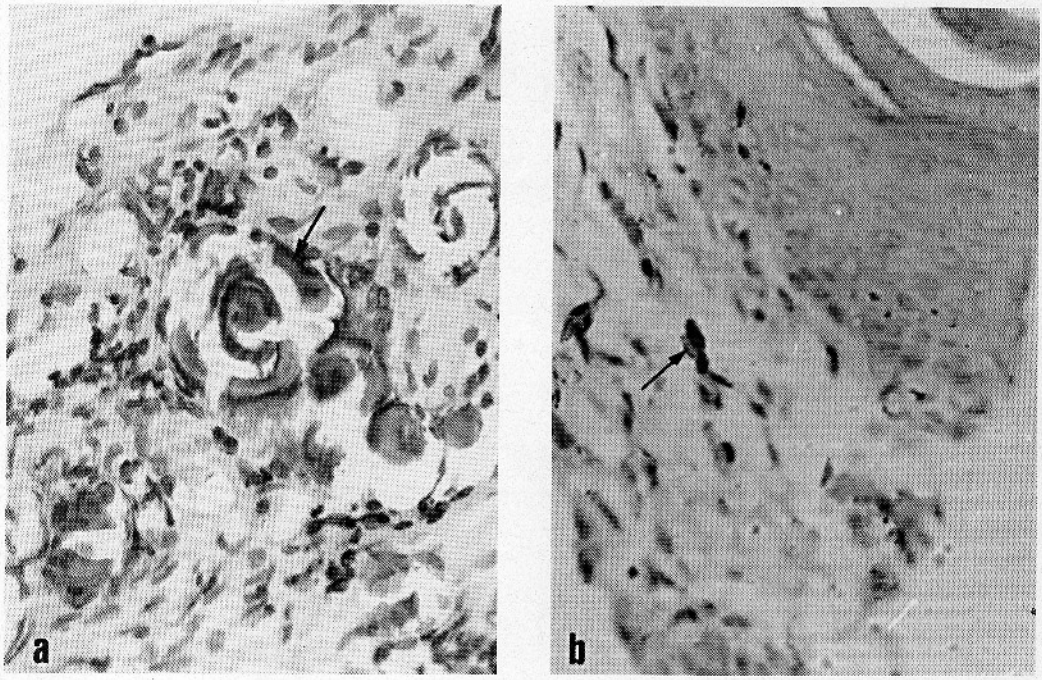


**Fig. 6.** Non-particulate antigenic material a, between the lamellae of Schaumann bodies (arrow) and b, within the cytoplasm of a fusiform subepidermal cell (arrow). PAP × 586.

to develop a nodular arrangement, as if trying to circumscribe the parasites. From the 45th day onward, well defined epithelioid granulomas were present, containing giant cells with lamellated, concentric and basophilic structures known as Schaumann bodies (Williams 1960). When granuloma formation was present, few parasites could be detected by PAP but non-particulate antigenic material was present within macrophages, giant cells and between the lamellae of the Schaumann bodies.

The Schaumann bodies were frequently seen in hamster macrophages and are considered in these animals to be indicative of a fragile mononuclear phagocytic system (Dumont & Sheldon 1965). Schaumann bodies originate from residual bodies, which are end-products of activated lysosomes (Williams & Williams 1968).

Granulomas observed at the 45th day of infection were characterized by numerous Schaumann bodies such as are seen in experimental tuberculosis in the hamster (Dumont & Sheldon 1965). In this model, these structures were observed around mycobacteria or their antigens, which were surrounded by activated macrophages which help to confine the infection. In experimental visceral leishmaniasis, there was a comparable development of Schaumann bodies at the site of inoculation; at this site the numbers of parasites decrease but antigenic material persists in the macrophage cytoplasm as residual material which is revealed by PAP staining.

Ridley and Ridley (1986) have already suggested that granuloma formation with macrophage activation is a mechanism for lysis and destruction of the parasite.

The finding of degraded antigen within macrophages and giant cells both in the granuloma and in subepidermal fusiform cells (Langerhans cells) at the 90th day

indicates the existence of a mechanism of parasite killing and control of infection at the inoculation site. However, degraded antigens are not completely destroyed and will persist for a long time at this site thus providing a persistent stimulation for granuloma formation even after the parasite is destroyed. It also indicates that the disseminated parasites, found in viscera, must have left the inoculation site before granuloma formation, that is, the parasite could spread only in the first 45 days of infection while the defence mechanism was still non-specific. It is not clear why granuloma formation takes so much time to develop after infection of *Leishmania* when after other infections, such as tuberculosis, it takes only 2–3 weeks.

## Acknowledgements

This work was supported by FINEP and LIM-72/HC-FMUSP. We thank Roselaine A.P. Cardoso for technical assistance, Márcio C. Baptista for photographic technical assistance, and Maria Daisi Moraes for secretarial help.

## References

Duarte M.I.S., Silva M.R.R., Goto H., Nicodemo E.L. & Amato Neto, V. (1983) Interstitial nephritis in human Kala-azar. *Trans. R. Soc. Trop. Med. Hyg.* **77**, 531–537.

Duarte M.I.S. & Corbett C.E.P. (1984) Histopathological and ultrastructural aspects of interstitial pneumonitis of experimental visceral leishmaniasis. *Trans. R. Soc. Trop. Med. Hyg.* **78**, 683–688.

Duarte M.I.S. & Corbett C.E.P. (1987) Histopathological patterns of the liver involvement in visceral leishmaniasis. *Rev. Inst. Med. Trop. S. Paulo* **29**, 131–136.

Dumont A. & Sheldon H. (1965) Changes in the fine structure of macrophages in experimentally produced tuberculosis granuloma in hamster. *Lab. Invest.* **14**, 2034–2055.

Gutiérrez Y., Maksen J.A. & Reiner N.E. (1984) Pathologic changes in murine leishmaniasis (*L. donovani*) with special reference to the dynamics of granuloma formation in the liver. *Am. J. Path.* **114**, 222–230.

Manson-Bahr P.E.C. (1955) A primary skin lesion in visceral leishmaniasis. *Nature* **175**, 433–434.

Manson-Bahr P.E.C. (1959) East African Kala-azar with special reference to the pathology, prophylaxis and treatment. *Trans. R. Soc. Trop. Med. Hyg.* **53**, 123–137.

Manson-Bahr P.E.C., Southgate B.A. & Harvey A.E.C. (1963) Development of Kala-azar in man after inoculation with a *Leishmania* from a Kenya sandfly. *Br. Med. J.* **5339**, 1208–1210.

Ridley M.J. & Ridley D.S. (1986) Monocyte recruitment, antigen degradation and localization in cutaneous leishmaniasis. *Br. J. Exp. Path.* **67**, 209–218.

Ritterson A.L. (1955) Leishmaniasis in golden hamster. *J. Parasitol.* **41**, 603–612.

Sen Gupta P.C. & Das Gupta C.R. (1951) Cutaneous lesions following inoculation of live culture of *Leishmania donovani* in man. *Indian Med. Gaz.* **86**, 6.

Sotto M.N., Yamashiro-Kanashiro E.H., Matta V.L.R. & Brito T. (1989) Cutaneous leishmaniasis of the New World: diagnostic immunopathology and antigen pathway in skin and mucosa. *Acta Trop.* **46**, 121–130.

Stauber L.A. (1958) Host resistance to the klartoun strain of *L. donovani*. *Rince Inst. Pamph.* **45**, 80–96.

Williams W.J. (1960) The nature and origin of Schaumann bodies. *J. Pathol. Bacteriol.* **79**, 193–201.

Williams W.J. & Williams D. (1968) The properties and development of conchoidal bodies in sarcoid and sarcoid-like granulomas. *J. Pathol. Bacteriol.* **96**, 491–496.

Wilson M.E., Innes D.J., Souzo A.Q. & Pearson R.D. (1987) Early histopathology of experimental infection with *Leishmania donovani* in hamster. *J. Parasitol.* **73**, 55–63.

**ANEXO-18**

---

Immunopathogenic competences of *Leishmania (V.) braziliensis* and *L. (L.) amazonensis* in American cutaneous leishmaniasis

Silveira, F.T.; Lainson, R.; Gomes, C.M.C.; **Laurenti, M.D.;** Corbett, C.E.P.

Parasite Immunology 2009; 31: 423-431

*Parasite Immunology,* 2009, **31**, 423–431 DOI: 10.1111/j.1365-3024.2009.01116.x

**Review Article**

# Immunopathogenic competences of *Leishmania* (*V.*) *braziliensis* and *L.* (*L.*) *amazonensis* in American cutaneous leishmaniasis

F. T. SILVEIRA,[1,2] R. LAINSON,[1] C. M. DE CASTRO GOMES,[3] M. D. LAURENTI[3] & C. E. P. CORBETT[3]

[1]Parasitology Department, Evandro Chagas Institute (Surveillance Secretary of Health, Ministry of Health), Belém, Pará State, Brazil, [2]Tropical Medicine Institute, Federal University of Pará, Belém, Pará State, Brazil, [3]Pathology Department, Medical School of São Paulo University, São Paulo, São Paulo State, Brazil

## SUMMARY

*The immunopathogenic competences of* Leishmania (V.) braziliensis *and* L. (L.) amazonensis *were reviewed in the light of more recent features found in the clinical and immunopathological spectrum of American cutaneous leishmaniasis. It was shown a dichotomy in the interaction between these* Leishmania *species and human T-cell immune response; while* L. (V.) braziliensis *shows a clear tendency to lead infection from the localized cutaneous leishmaniasis (LCL), a moderate T-cell hypersensitivity form at the centre of the spectrum, toward to the mucocutaneous leishmaniasis (MCL) at the T-cell hypersensitivity pole and with a prominent Th1-type immune response,* L. (L.) amazonensis *shows an opposite tendency, leading infection to the anergic diffuse cutaneous leishmaniasis (ADCL) at the T-cell hyposensitivity pole and with a marked Th2-type immune response. Between the central LCL and the two polar MCL and ADCL, the infection can present an intermediary form known as borderline disseminated cutaneous leishmaniasis, characterized by an incomplete inhibition of T-cell hypersensitivity but with a evident supremacy of Th1 over Th2 immune response (Th1 ≥ Th2). These are probably the main immunopathogenic competences of* L. (V.) braziliensis *and* L. (L.) amazonensis *regarding the immune response dichotomy that modulates human infection outcome by these* Leishmania *parasites.*

***Keywords*** *American cutaneous leishmaniasis, immunopathogenic competences,* Leishmania (V.) braziliensis*,* L. (L.) amazonensis

*Correspondence:* Fernando Tobias Silveira, Evandro Chagas Institute, Parasitology Department, Av. Almirante Barroso, 492, 66090-000, Belém, Pará State, Brazil (e-mail: silveiraft@lim50.fm.usp.br).
*Received: 18 November 2008*
*Accepted for publication: 15 March 2009*

## INTRODUCTION

The immunopathogenesis of American cutaneous leishmaniasis (ACL) has been regarded one of most interesting features concerning this parasitic protozoal disease in viewing of the complex interaction process between the variety of *Leishmania* species causing the disease and the human immune response. Actually, there are, at least, fourteen recognized *Leishmania* parasites within the subgenera *Viannia* and *Leishmania* which can give rise to clinical ACL (1–3). Recently, following new findings on the clinical and immunopathological spectrum of the disease caused by *Leishmania* (*V.*) *braziliensis* and *Leishmania* (*L.*) *amazonensis* there has been increased the interest on the immunopathogenic competences of these two *Leishmania* species; i.e. they are implicated not only with the localized cutaneous leishmaniasis (LCL), the most common ACL form placed at the centre of the clinical spectrum and supported by a moderate T-cell hypersensitivity, but also with the mucocutaneous leishmaniasis (MCL) and anergic diffuse cutaneous leishmaniasis (ADCL), the more severe ACL forms respectively. In this regard, while MCL represents the extreme expression of T-cell hypersensitivity pole, linked to a strong species-specific T-cell immune response against to *L.* (*V.*) *braziliensis* (Figure 1), ADCL means, in contrast, the extreme expression of T-cell hyposensitivity pole, associated to a high *Leishmania*-specific inhibition of T-cell response (4). Moreover, these *Leishmania* parasites can also induce an intermediary form between the central LCL and the two polar MCL and ADCL, the borderline disseminated cutaneous leishmaniasis (BDCL), which is distinguished by a partial inhibition of T-cell response (5). Furthermore, as BDCL can be caused by parasites belong to both subgenus of *Leishmania*, *Viannia* and *Leishmania*, as well as there are some clinical and immunological characteristics that differ between *Viannia* and *Leishmania* cases, then BDCL can

 

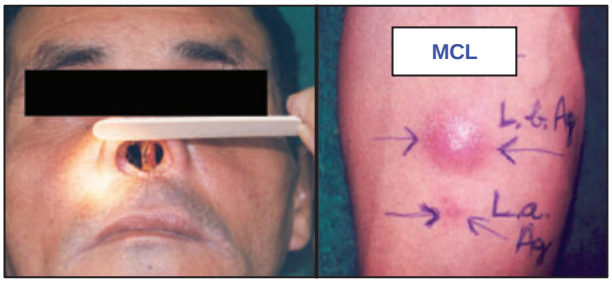


**Figure 1** A strong species-specific DTH skin reaction against to homologous *L.* (*V.*) *braziliensis*-antigen compared with a weak reaction against to heterologous *L.* (*L.*) *amazonensis*-antigen in an American mucocutaneous leishmaniasis (MCL) case from Pará state, Amazonian Brazil.

occupy the two places between the centre (LCL) and the two polar forms (MCL and ADCL) in the clinical spectrum of disease (Figure 2).

Thus, taking these features into account we considered of interest to review the immunopathogenic competences (the ability of parasite to deviate T-cell immune response from the LCL toward to one of the two polar forms, MCL or ADCL) of *L.* (*V.*) *braziliensis* and *L.* (*L.*) *amazonensis* regarding the immune response dichotomy that modulates the clinical and immunopathological spectrum of disease, aiming to a better understanding on the immunopathogenesis of MCL and ADCL, the more severe ACL forms; this might help to prevent and/or to reduce the morbidity of disease.

## EVENTS WHICH PRECEDE ACL MANIFESTATIONS

Before, however, the development of ACL manifestations there is a series of events of crucial importance for *Leishmania*-infection successful; (i) events responsible for *Leishmania*-infection establishment (=*Leishmania*-macrophage interaction or *Leishmania*-neutrophil-sand fly saliva-macrophage interaction) and, (ii) events responsible for infection outcome [=*Leishmania*-dendritic cells/Langerhans cells-T-cell interaction].

### *Leishmania*-macrophage interaction or *Leishmania*-neutrophil-sand fly saliva-macrophage interaction

Human infection by *Leishmania* species starts just following the inoculation of promastigotes forms into the skin

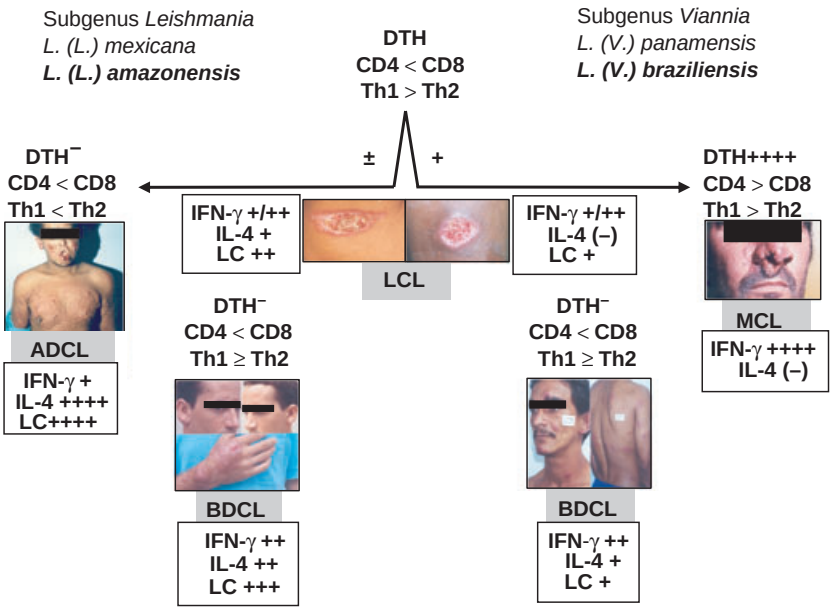


**Figure 2** Clinical and immunopathological spectrum of American cutaneous leishmaniasis modulated by immunopathogenic competences of *Leishmania* species within the subgenera *Viannia* and *Leishmania*, with emphasis to *L.* (*V.*) *braziliensis* and *L.* (*L.*) *amazonensis* respectively. ADCL, anergic diffuse cutaneous leishmaniasis; nodular and infiltrated cutaneous lesions on the thorax, face and ears; LCL, localized cutaneous leishmaniasis [±*L.* (*L.*) *amazonensis*]: ulcerated skin lesion with large infiltration at the edge; [+*L.* (*V.*) *braziliensis*]: ulcerated skin lesion, exhibiting slight infiltration at the edge; MCL, mucocutaneous leishmaniasis; ulcer-infiltrated lesion of the nose, on the dorsal face and into the mucosa of the nasal septum; BDCL, borderline disseminated cutaneous leishmaniasis [±*L.* (*L.*) *amazonensis*]; infiltrated skin lesion on the dorsal face of hand (primary lesion) and on the ears and frontal region of head (secondary lesions); [+*L.* (*V.*) *braziliensis*]: papule-ulcerated skin lesions disseminated on the face, ears, trunk and arms. DTH, delayed type hypersensitivity; CD4 = $CD4^+$ T-cell; CD8 = $CD8^+$ T-cell; Th1 = Th1-type immune response; Th2 = Th2-type immune response; IFN-γ = gamma-interferon; IL-4 = interleukin-4; LC = Langerhans cell.

  

by the bite of naturally infected species of phlebotomine sand flies (Diptera: Psychodidae) (6). After that, a parasite escaping process in response to host defenses takes place into the skin which, whether suppressed by the parasite, will result in its entry into a phagocyte cell, mainly the macrophage or, as more recently evidenced, the neutrophil (7–9). Thus, in the case of the *Leishmania*-macrophage interaction model, it has been suggested that some of inoculated promastigotes forms known as infective metacyclic promastigotes forms (10) which were capable of escaping from the complement-mediated lysis (11) are directly phagocytosed by macrophage (12), in which the promastigote forms will then transform in amastigotes forms into the parasitophorous vacuoles of macrophage; into this new microenvironment the amastigotes will now multiply by binary fission. In the case, however, of the *Leishmania*-neutrophil-sand fly saliva-macrophage interaction model, it has been evidenced, through the experimental *Leishmania major*-infection in B57BL/6 mice following the sand fly vector (*Phlebotomus duboscqi*) or needle inoculation of metacyclic promastigotes forms of parasite, that the first cells coming to around of the infection site are the neutrophils, which would function as 'Trojan horses' or as a bridge between the parasite and the final host cell, the macrophage. Thus, just after the genetic-apoptosis death of infected-neutrophils (short-lived cells), the released parasite-amastigotes forms are prompted phagocytosed by macrophage cells. Following this stage, the infection outcome will depend on (i) the immune-genetic background, associated to the T-cell immune response (13–16) and, principally, (ii) the antigen-specificity of *Leishmania sp.*, associated to its ability to interact with the DCs, including the epidermal LCs (17,18).

### *Leishmania*-dendritic cells (Langerhans cells)-T-cell interaction

Differently from the macrophages, which are the main host cells for *Leishmania* replication, DCs represent a mononuclear phagocyte cells group, derived from the bone marrow, which are capable to phagocyte and transport *Leishmania*-antigens toward to the closest draining lymph node, where following a fast maturation phase, they process and present parasite-antigens to naïve T-cells (Th0) which will then proliferate into the effectors $CD4^+$ (Th1 and Th2) T-cells. Thus, they are the major antigen-presenting cells, $MHCII^+$, with capacity to stimulate the innate immune response and modulate the T-cell (adaptive) immune response (19,20). In this regard, DCs seem to have a pivotal role in ACL immunopathogenesis once they represent the vehicle which will provide the first contact of *Leishmania*-antigen with the T-cell immune response, leading to a preferential stimulation of $CD4^+$ T-cells (21,22). In the case of Th1-type stimulation, the main produced cytokines (IL-2, IL-12, INF-$\gamma$ and TNF-$\alpha$) will promote macrophage activation and, consequently, the elimination of the parasite. Nevertheless, in the case of Th2-type stimulation, the major produced cytokines (IL-4, IL-5, IL-10 and IL-13) will inhibit macrophage activation and, then, contribute to the parasite survival (23,24). Therefore, the macrophage activation will provide high production of nitric oxide, which together with oxidative stress, represents an important mechanism of parasite elimination (25,26).

For some time, however, there was a controversy regarding to which migratory DCs type is responsible for the initiation of a protective immune response in cutaneous leishmaniasis. Thus, two DCs subsets have been the target for this function, the $CD11c^+CD8\alpha^-Langerin^-$ dermal DC or $CD11c^+CD8\alpha^+Langerin^+$ epidermal LC. With regards to the epidermal LC, it has been postulated that it functions primarily by monitoring the environment for candidate danger signals and capturing, processing and translating them. When a certain threshold is reached, LC becomes mature cell, acquiring the ability to migrate from the epidermis to regional lymph nodes, where it is thought to initiate adaptive immune response and stimulates T cells (27,28). Recently, however, following studies on the role of LC in the immunopathogenesis of experimental cutaneous leishmaniasis in BALB/c mice infected with *L.* (*L.*) *major*, it has been found that DC capable of stimulating antigen-specific T-cell proliferation was Langerin-negative (LC is Langerin-positive), thus, indicating that dermal DC is really crucial for initiation of a specific T-cell response (29), and not LC as it was prior postulated (27,28). Furthermore, it was also demonstrated that contact hypersensitivity was found exacerbated rather than abrogated in mice presenting absence of LC, suggesting that as few as LC at the infection site will help to develop a well-defined hypersensitivity reaction (30). In addition, it was also evidenced that LC was able to process and present parasite-antigen through the MHC class II receptor for $CD4^+$ T cells, which might likely differentiate into regulatory T cells (Treg cells), suggesting that LC would be responsible for suppression of inflammatory events against *L.* (*L.*) *major* infection *in vivo* (31). In conclusion, these studies have suggested that LC represents, indeed, a *Leishmania* evasion mechanism in order to avoid T-cell response and induce immune suppression.

More recently, this *Leishmania* evasion mechanism credited to LC function was analysed within the clinical-immunological ACL spectrum due to *L.* (*V.*) *braziliensis* and *L.* (*L.*) *amazonensis*, comparing LC epidermal density

amongst the different clinical forms of disease. As a result, it was evidenced a progressive increase in LC density from the reactive ($DTH^+$) LCL-central form caused by *L.* (*V.*) *braziliensis* toward to the nonreactive ($DHT^-$) extreme forms, BDCL and ADCL, caused by *L.* (*L.*) *amazonensis.* Thus, these findings indicated a strong and species-specific negative association between LC density and prior $CD4^+$ and $CD8^+$ T-cell profiles (4); i.e. along the clinical-immunological ACL spectrum linked to *L.* (*L.*) *amazonensis* it seems that LC performs a pivotal role in modulating T-cell immune suppression, from the nonreactive ($DTH^-$) LCL patients toward to the more immune suppressed (Th2-type immune stimulation) BDCL and ADCL ones (18).

## ACL MANIFESTATIONS WHICH ARE MODULATED BY IMMUNOPATHOGENIC COMPETENCES OF *LEISHMANIA* (*V.*) *BRAZILIENSIS* AND *L. (L.) AMAZONENSIS*

As above cited, the ACL immunopathogenesis is strongly influenced by the human immune-genetic profile and, principally, by the antigen-specificity of *Leishmania sp.*, which has been shown to be able to modulate the parasite-DCs interactions with the T-cell immune response (20); thus, as a result of the complex interaction process between *L.* (*V.*) *braziliensis* and *L.* (*L.*) *amazonensis* with the T-cell immune mechanisms there will develop a clinical and immunopathological spectrum of ACL manifestations (Figure 2), as follows:

### Clinical spectrum

Following infection by these *Leishmania* species, some naturally resistant individuals (asymptomatic) presenting an efficient innate immune response will emerge, along with others showing different degrees of susceptibility to infection (symptomatic). Thus, depending upon the species of infecting *Leishmania* and the infected individual's T-cell immune response, a spectrum of clinical forms of disease develops: LCL, BDCL, MCL and ADCL (3,4).

However, it should be clear that this spectrum was not based in a clinical classification alone, once these clinical forms have also resulted from an immunological context of infection due to *Leishmania sp.* and the human T-cell immune response. In this way, at the centre of the clinical-immunological spectrum, the LCL is the most frequent form of ACL and may be caused by both leishmanial parasites. It consists of one or more ulcerated skin lesions supported by an efficient T-cell immune response, which generally favours a well response to traditional antimony therapy (32). Moreover, in some *L.* (*L.*) *amazonensis* LCL patients the clinical nature of their lesions may give a clue as to the causative parasite, namely the large infiltration at the edge of lesions (4,5); this feature differs from that in *L.* (*V.*) *braziliensis* LCL patients, which present a slight infiltration at the edge of lesions.

From the centre of ACL spectrum, some infections not entirely under the control of T-cell immune mechanisms may develop to one of the two polar forms of disease; either to the T-cell hypersensitivity pole represented by MCL, having *L.* (*V.*) *braziliensis* and *L.* (*V.*) *panamensis* as the main causative agents, or to the T-cell hyposensitivity pole consisting of ADCL, mainly caused by *L.* (*L.*) *amazonensis* or *L.* (*L.*) *mexicana* in the New World (1,2). Until now, it has been evidenced that this dichotomy of T-cell response is highly influenced by *Leishmania sp.* which is stimulating the host immune response; i.e. only infections due to *Viannia* subgenus parasites, like *L.* (*V.*) *braziliensis* or *L.* (*V.*) *panamensis*, are able to develop to the T-cell hypersensitivity pole (MCL), whereas only infections due to *Leishmania* subgenus parasites, like *L.* (*L.*) *amazonensis* or *L.* (*L.*) *mexicana*, are able to develop to the T-cell hyposensitivity pole (ADCL). Thus, these are then the major immunopathogenic competences of the principal ACL agents; while *L.* (*V.*) *braziliensis* or *L.* (*V.*) *panamensis* show clear tendency to lead infection to the T-cell hypersensitivity pole strongly linked to Th1-type immune response, *L.* (*L.*) *amazonensis* or *L.* (*L.*) *mexicana* show the opposite, leading infection to the T-cell hyposensitivity pole markedly associated with Th2-type immune response (4,18). Therefore, while in MCL the necrosis of nasopharyngeal mucosal tissues is strongly associated with high serum production of IFN-$\gamma$ and TNF-$\alpha$ (33,34), in ADCL the nodular skin lesions disseminated all over the body are markedly linked to a high production of IL-4, resulting in a very weak T-cell immune control of infection and a poor response to traditional antimony treatment (35,36).

Between the central LCL and the two extreme pathogenic poles MCL and ADCL, both *Leishmania* species may cause an intermediary form known as BDCL, which also presents certain clinical-specific differences: i.e. in BDCL due to *L.* (*V.*) *braziliensis*, the infection dissemination is relatively rapid, requiring only 2–3 months to produce around a hundred ulcerated skin lesions. In contrast, in BDCL due to *L.* (*L.*) *amazonensis*, the infection dissemination is slower, requiring 1–2 years to produce some 5–10 infiltrated skin lesions. The term borderline was then introduced to characterize clinical evidence of incomplete T-cell immune suppression found in these patients, principally in those infected with *L.* (*L.*) *amazonensis* ($DTH^-$) who present greater inhibition of T-cell response than those infected with *L.* (*V.*) *braziliensis* ($DTH^{+/-}$) (5). Despite this fact, sufficient observations have been

  

reported allowing conclusion that T-cell response functions well enough to facilitate recovery of BDCL patients following successful treatment with two to three LCL-therapeutic antimony regimens (37–39).

**Immunopathological spectrum**

The ACL immunopathological response has mainly been studied with basis on the $CD4^+$ and $CD8^+$ T-cell subsets profiles and some cytokines produced by these cells in skin and mucosal lesions of patients. A special interest has been given to INF-γ and IL-4 once it is believed that these cytokines play a crucial role in determining either the resistance (Th1-type immune response) or the susceptibility (Th2-type immune response) against to leishmanial infection (40,41). More recently, however, it has also been claimed attention to the role of Treg cells and their major secreted cytokines, IL-10 and TGF-β, in modulating the T-cell immune response against *Leishmania* infection. Nevertheless, there is until now only one study in Brazil (42) which investigated the role of Treg cells in *L.* (*V.*) *braziliensis*-LCL cases, providing the conclusion that these cells might contribute to the well-balanced T-cell immune response found in these cases. Furthermore, considering LCL as the most frequent ACL form (≥95%), it has been evidenced a moderate T-cell hypersensitivity and a prominent Th1-type immune response, which results in high production of IFN-γ in skin lesions with subsequent macrophage activation and elimination of the parasite (43,44). This T-cell mechanism has provided a high resistance against infection and favourable result for antimony therapy.

In addition, it has been shown that modulation of T-cell immune response can be strongly influenced by the infective *Leishmania* species. For instance, LCL patients due to *L.* (*V.*) *braziliensis* have revealed higher ($P < 0{\cdot}05$) DTH and lymphocyte proliferation reactivity than those due to *L.* (*L.*) *amazonensis.* Moreover, most (>50%) LCL patients due to *L.* (*L.*) *amazonensis* have not presented DTH and lymphocyte proliferation reactivity, suggesting that *L.* (*L.*) *amazonensis* has greater ability than has *L.* (*V.*) *braziliensis* to escape from the T-cell immune response (45,46). Moreover, it has also been found by a semi-quantitative reverse transcription-polymerase chain reaction analysis a significant increase of IFN-γ mRNA expression in skin lesions of LCL patients due to *L.* (*V.*) *braziliensis*, whereas no expression for IL-4 mRNA was evidenced in the same patients. In contrast, however, in LCL patients due to *L.* (*L.*) *amazonensis* a significant increase of IL-4 mRNA expression was shown, although there was no evidenced a decrease of IFN-γ mRNA expression in the same patients, suggesting that IL-4 expression might be down-regulating IFN-γ activity and then inhibiting T-cell hypersensitivity in these patients (4). In this regard, it would be reasonable to speculate that, unlike to *L.* (*V.*) *braziliensis*-LCL patients, a higher concentration of Treg cells should exist in these *L.* (*L.*) *amazonensis*-LCL cases, in which IL-10 might also be corroborating to the inhibition of their T-cell hypersensitivity. This mechanism has similarly been shown in the experimental infection of CBA and BALB/c mice with *L.* (*L.*) *amazonensis* respectively (47,48).

In MCL which is strongly associated to high hypersensitivity and lymphocyte proliferation assays (45,46), the $CD4^+$ T-cell subset profile from mucosal lesions of patients has shown a higher predominance over the $CD8^+$ T-cell subset (49), which has also been found in Amazonian Brazil, thus, suggesting that $CD4^+$ T-cell subset plays a crucial role in MCL pathogenesis (4). Therefore, it has also been found a higher $CD4^+$ T-cell profile than those in the other ACL forms (LCL, BDCL and ADCL), which justify the high levels of IFN-γ and TNF-α in this extreme hypersensitivity form. This immune response profile has similarly been observed in MCL from the north-eastern region of Brazil, principally in Bahia state, where there has been found that $CD4^+$ T cells represented the majority of IFN-γ producing cells than the counterpart $CD8^+$ T cells (50). Moreover, MCL has been defined with a marked decreased production of IL-10 and TGF-β and, conversely, with an increased of IFN-γ and TNF-α production (34), thus, suggesting a discrete presence of Treg cells in the immunopathogenesis of disease. However, a mixed Th1/Th2 immune response profile has been found in MCL from Venezuela (43) and the south-eastern region of Brazil (44), conflicting with findings from Amazonian Brazil where a clear Th1-type immune response has been evidenced; i.e. high levels of IFN-γ mRNA expression in mucosal lesions, contrasting with no expression for IL-4 mRNA in the same samples (4). Thus, it seems likely that exacerbation of T-cell immune response in MCL might be the result of a long-lasting immunopathogenic stimulus by *L.* (*V.*) *braziliensis*, once the beginning of mucosal symptoms generally appears following a 5-year period after the primary skin lesion. This represents, without doubt, a relatively long time for T-cell sensitization, resulting in high IFN-γ and TNF-α levels, which are considered the major cytokines in the pathogenesis of MCL (15). However, it has recently been evidenced that a host genetic factor, the IL-6-174 G/C promoter polymorphism, might also be influencing the pathogenesis of MCL (16).

In ADCL, however, both DTH and lymphocyte proliferation assays have always been negative, indicating a strong T-cell immune response inhibition in this form,

which has brought difficulty for the control of infection (35,36). In according to this evidence, there have been found the lowest densities of $CD4^+$ and $CD8^+$ T-cell subsets in the cellular infiltration of skin lesions in ADCL from Amazonian Brazil, as well as the lowest IFN-γ mRNA expression. In contrast, there has been found the highest IL-4 mRNA expression in the same samples, indicating that in ADCL there is a clear Th2-type immune response, which justify the frequent recrudescence of disease following conventional therapy (4,51). In addition, regarding the high concentration of LC in ADCL (17) and the ability of LC to process and present the parasite-antigen through the MHC class II receptor for $CD4^+$ T-cells with functional activity of Treg cells (31), it is possible to speculate on the existence of high IL-10 and TGF-β levels in the cutaneous lesions of ADCL patients, which might collaborate to the strong inhibition of their T-cell immune response (52).

With regards to BDCL, it should be emphasized that during the parasite dissemination, which means a critical stage of infection, both DTH and lymphocyte proliferation assays have also been negative, reflecting some degree of T-cell immune response inhibition in this ACL form. However, this partial T-cell immune suppression found in BDCL, principally in patients infected with *L.* (*L.*) *amazonensis* whom present greater T-cell inhibition than those infected with *L.* (*V.*) *braziliensis*, has been restored following successful treatment with two to three LCL-therapeutic antimony regimens, which suggested an evident supremacy of Th1 over Th2 immune response (5).

## CONCLUDING REMARKS

Until recently, it was believed that host immune response played alone the major factor influencing the human leishmanial infection outcome (53–57). Actually, however, there are some clear evidences on the contrary, principally those concerning the ACL pathogenesis, once a number of *Leishmania* species have been shown to be responsible for different clinical forms of disease in man (2–4). In this respect, it should also be highlighted the importance of the taxonomic classification of parasites belong to the genus *Leishmania* (6) which, although has mainly been based on the behaviour of parasites within the alimentary tract of the phlebotomine sandfly vectors (Diptera: Psychodidade), is now reflecting important differences regarding the immunopathogenic competences of *Leishmania* species between the *Viannia* and *Leishmania* subgenera. For instance, all information considered in this review represents unequivocal evidence on the role of *Leishmania* species in determining the human infection outcome; i.e. it was strongly demonstrated the ability of *L.* (*V.*) *braziliensis* or *L.* (*L.*) *amazonensis* in directing the immune response dichotomy of human infection by these *Leishmania* parasites. Clearly, these considerations can also be applied to other neotropical *Leishmania* species closely related to the mentioned species; *L.* (*V.*) *panamensis* and *L.* (*L.*) *mexicana*, principally, in view of their immunopathogenic competences to be similar to those of *L.* (*V.*) *braziliensis* and *L.* (*L.*) *amazonensis*, respectively (58–61).

In addition, it was also showed that both parasites, *L.* (*V.*) *braziliensis* and *L.* (*L.*) *amazonensis*, can induce a wide spectrum of clinical and immunopathological manifestations which, as many will be better understood, will be able to provide new perspectives for improving the disease treatment or a vaccine development. Thus, in spite of ACL treatment has not been the priority in the present review, it is obvious that a well-defined treatment for LCL form, with a prior identification of *Leishmania* involved, principally in the case of *L.* (*V.*) *braziliensis* or *L.* (*L.*) *amazonensis*, might be of major importance for preventing future sequel related to these *Leishmania* infections. As it was discussed, both species have demonstrated high capacity of escaping from the T-cell immune response mechanisms and then deviate infection to one of the two clinical-immunological poles of the clinical spectrum; i.e. *L.* (*V.*) *braziliensis* is capable to direct infection to the extreme T-cell hypersensitivity pole represented by MCL, whereas *L.* (*L.*) *amazonensis*, in contrast, has the ability to direct infection to the extreme T-cell hyposensitivity pole consisted by ADCL. Thus, this deviation of T-cell immune response by these *Leishmania* species can lead to deleterious effects on the human immune response, which may result in a state of exacerbated hypersensitivity (MCL) by *L.* (*V.*) *braziliensis* or, in contrast, in high hyposensitivity (ADCL) by *L.* (*L.*) *amazonensis* respectively. Unfortunately, as a result of this T-cell immune response deviation there are a number of MCL and ADCL patients which have been developing for long-lasting time (some with more than 20 years-period) without successful therapy (Silveira, personal observation).

Regarding the above comments, it should be emphasized that amongst more than thousand LCL patients due to *L.* (*V.*) *braziliensis* or *L.* (*L.*) *amazonensis* which have received antimony therapy in the leishmaniasis programme of Evandro Chagas Institute (Ministry of Health, Belém, Pará State, Brazil) neither MCL nor ADCL have ever been developed following this antimony treatment (Silveira, personal observation). Thus, this finding not only represents strong favourable evidence regarding the immunopathogenic competences of *Leishmania* species considered in this review, as well as reflects the importance

  

of early LCL treatment in decreasing the prevalence and/or morbidity of MCL and ADCL.

In conclusion, taken this information together it seems important for a better understanding on the immunopathogenic competences of *L.* (*V.*) *braziliensis* and *L.* (*L.*) *amazonensis* with their T-cell immune response interactions, principally regarding the role of *Leishmania*-DCs (dermal DCs and epidermal LCs) interactions with the immune response dichotomy that modulates infection outcome by these *Leishmania* parasites; i.e. while *L.* (*V.*) *braziliensis*-antigen shows high ability to interact with DCs for modulating a preferential $CD4^+$ Th1-type immune response (62–64), *L.* (*L.*) *amazonensis*-antigen, in contrast, presents clear competence to interact with DCs for modulating a prominent $CD4^+$ Th2-type immune response (18,65,66). Thus, these are, likely, the main immunopathogenic competences of these two *Leishmania* species.

## FUNDING

This work was supported by Instituto Evandro Chagas (Secretaria de Vigilância em Saúde, Ministério da Saúde, Brazil); Instituto de Medicina Tropical (Universidade Federal do Pará, Brazil); Wellcome Trust (London, UK); Laboratório de Investigação Médica (LIM)-50 [Hospital de Clínicas (HC)-Faculdade de Medicina (FM)-Universidade de São Paulo (USP), Brazil] and Fundação de Amparo a Pesquisa do Estado de São Paulo (FAPESP: 06/56319-1, Brazil).

## REFERENCES

1 Lainson R & Shaw JJ. New World leishmaniasis – the neotropical *Leishmania* species. In Cox FEG, Kreier JP & Wakelin D (eds): *Topley & Wilson's Microbiology and Microbial Infections*, 9th edn. London, Parasitology, Arnold, Vol. 5, 1998: 242–266.

2 Lainson R & Shaw JJ. Leishmaniasis in the New World. In Collier L, Balows A & Sussman M (eds): *Topley & Wilson's Microbiology and Microbial Infections*, 10th edn. London, Parasitology, Arnold, Vol. 5, 2005: 313–349.

3 Silveira FT, Lainson R, De Brito AC, *et al.* Leishmaniose tegumentar americana. In Leão RNG (ed): *Doenças Infecciosas e Parasitárias: Enfoque Amazônico*, Belém, PA, CEJUP, 1997: 619–630.

4 Silveira FT, Lainson R & Corbett CEP. Clinical and immunopathological spectrum of American cutaneous leishmaniasis with special reference to the disease in Amazonian Brazil. *Mem Inst Oswaldo Cruz* 2004; **99**: 239–251.

5 Silveira FT, Lainson R & Corbett CEP. Further observations on clinical, histopathological and immunological features of borderline disseminated cutaneous leishmaniasis caused by *Leishmania* (*Leishmania*) *amazonensis*. *Mem Inst Oswaldo Cruz* 2005; **100**: 525–534.

6 Lainson R & Shaw JJ. Evolution, classification and geographical distribution. In Peters W & Killick-Kendrick R (eds): *The Leishmaniases in Biology and Medicine*. London, Academic Press, Vol. 1, 1987: 1–120.

7 Peters NC, Egen JG, Secundino N, *et al.* In vivo imaging reveals an essential role for neutrophil in leishmaniasis transmitted by sand flies. *Science* 2008; **321**: 970–974.

8 John B & Hunter CA. Neutrophil soldiers or Trojan horses? *Science* 2008; **321**: 917–918.

9 Laskay T, Van Zandbergem G & Solbach W. Neutrophil granulocytes as host cells and transport vehicles for intracellular pathogens: Apoptosis as infection-promoting factor. *Immunobiology* 2008; **213**: 183–191.

10 Sacks DL & Perkins PV. Identification of an infective stage of *Leishmania* promastigotes. *Science* 1984; **223**: 1417.

11 Sacks DL & da Silva RP. The generation of infective stage *Leishmania major* promastigotes is associated with the cell-surface expression and release of a developmentally regulated glycolipid. *J Immunol* 1987; **139**: 3099.

12 Vannier-Santos MA, Martiny A & De Souza W. Cell biology of *Leishmania* spp.: invading and evading. *Curr Pharm Des* 2002; **8**: 297–318.

13 Petzl-Erler ML, Belich MP & Queiroz-Telles F. Association of mucosal leishmaniasis with HLA. *Hum Immunol* 1991; **32**: 254–260.

14 Lara ML, Layrisse Z, Scorsa JV, *et al.* Immunogenetics of human American cutaneous leishmaniasis. Study of HLA haplotypes in 24 families from Venezuela. *Hum Immunol* 1991; **30**: 129–135.

15 Blackwell JM. Tumour necrosis factor alpha and mucocutaneous leishmaniasis. *Parasitol Today* 1999; **15**: 73–76.

16 Castellucci L, Menezes E, Oliveira J, *et al.* IL6-174 G/C promoter polymorphism influences susceptibility to mucosal but not localized cutaneous leishmaniasis in Brazil. *J Inf Dis* 2007; **194**: 519–527.

17 Campos MB, Gomes CMC, De Souza AAA, Lainson R, Corbett CEP & Silveira FT. In vitro infectivity of species of *Leishmania* (*Viannia*) responsible for American cutaneous leishmaniasis. *Parasitol Res* 2008; **108**: 771–776.

18 Silveira FT, Lainson R, Gomes CMC, Laurenti MD & Corbett CEP. Reviewing the role of the dendritic Langerhans cell in the immunopathogenesis of American cutaneous leishmaniasis. *Trans R Soc Trop Med Hyg* 2008; **102**: 1075–1080.

19 Garg H, Trudel N & Trembley MJ. Consequences of the natural propensity of *Leishmania* and HIV-1 to target dendritic cells. *Trends Parasitol* 2007; **23**: 317–324.

20 Soong L. Modulation of dendritic cell function by *Leishmania* parasites. *J Immunol* 2008; **180**: 4355–4360.

21 Von Stebut E, Belkaid Y, Jacob T, Sacks DL & Udey MC. Uptake of Leishmania major amastigotes results in activation and IL-12 release from murine skin-derived dendritic cells: implications for the initiation of anti-*Leishmania* immunity. *J Exp Med* 1998; **188**: 1547–1552.

22 Lemos MP, Esquivel F, Scott P & Laufer TM. MHC class II expression restricted to $CD8\alpha^+$ and $CD11b^+$ dendritic cells is sufficient for control of *Leishmania major*. *J Exp Med* 2004; **199**: 725–730.

23 Locksley RM, Heinzel FP, Holaday BJ, *et al.* Induction of Th1 and Th2 $CD4^+$ subsets during murine *Leishmania major* infection. *Res Immunol* 1991; **142**: 28–32.

24 Sacks D & Noben-Trauth N. The immunology of susceptibility and resistance to *Leishmania major* in mice. *Nat Rev Immunol* 2002; **2**: 845–858.

25 Weinberg JB. Nitric oxide production and nitric oxide synthase type 2 expression by human mononuclear phagocytes: a review. *Mol Med* 1998; **4**: 557–591.

26 Bogdan C, Donhauser N, Döring R, Röllinghoff M, Diefenbach A & Rittig MG. Fibroblasts as host cells in latent leishmaniosis. *J Exp Med* 2000; **191**: 2121–2129.

27 Moll H, Flohé S & Rollinghoff M. Dendritic cells in *Leishmania major*-immune mice harbor persistent parasites and mediate an antigen-specific T-cell immune response. *Eur J Immunol* 1995; **25**: 693–699.

28 Girolomoni G, Caux C, Lebecque S, Dezutter-Dambuyant C & Ricciardi-Castagnoli P. Langerhans cells: still a fundamental paradigm for studying the immunobiology of dendritic cells. *Trends Immunol* 2002; **23**: 6–8.

29 Ritter U, Meissner A, Scheidig C & Körner H. CD8α- and Langerin-negative dendritic cells, but not Langerhans cells, act as principal antigen-presenting cells in leishmaniasis. *Eur J Immunol* 2004; **34**: 1542–1550.

30 Kaplan DH, Jenison MC, Saeland S, Shlomchik WD & Shlomchik MJ. Epidermal Langerhans cell-deficient mice develop enhanced contact hypersensitivity. *Immunity* 2005; **23**: 611–620.

31 Ritter U & Osterloh A. A new view on cutaneous dendritic cell subsets in experimental leishmaniasis. *Med Microbiol Immunol* 2007; **196**: 51–59.

32 Carvalho EM, Correia-Filho D, Baccelar O, Lessa H & Rocha H. Characterization of the immune response in subjects with self healing cutaneous leishmaniasis. *Am J Trop Med Hyg* 1995; **53**: 273–277.

33 Da-Cruz A, De Oliveira MP, De-Luca PM, Mendonça SC & Coutinho SG. Tumor necrosis factor-alpha in human American tegumentary leishmaniasis. *Mem Inst Oswaldo Cruz* 1996; **91**: 225–229.

34 Bacellar O, Lessa H, Schriefer A, *et al.* Up-regulation of Th1-type responses in mucosal leishmaniasis patients. *Infect Immun* 2002; **70**: 6734–6740.

35 Petersen EA, Neva FA, Oster CN & Diaz HB. Specific inhibition of lymphocyte proliferation response by adherent suppressor cells in diffuse cutaneous leishmaniasis. *N Engl J Med* 1982; **306**: 387–391.

36 Barral A, Costa JML, Bittencourt AL, Barral-Neto M & Carvalho EM. Polar and subpolar diffuse cutaneous leishmaniasis in Brazil: clinical and immunopathologic aspects. *Int J Dermatol* 1995; **34**: 474–479.

37 Costa JML, Marsden PD, Llanos-Cuentas EA, *et al.* Disseminated cutaneous leishmaniasis in a field clinic in Bahia, Brazil: a report of eight cases. *J Trop Med Hyg* 1986; **89**: 319–321.

38 Carvalho EM, Barral A, Costa JML, Bittencourt A & Marsden PD. Clinical and immunopathological aspects of disseminated cutaneous leishmaniasis. *Acta Trop* 1994; **56**: 315–325.

39 Turetz ML, Machado PR, Ko AI, *et al.* Disseminated leishmaniasis: a new and emerging form of leishmaniasis observed in northeastern Brazil. *J Infect Dis* 2002; **186**: 1829–1834.

40 Ribeiro-de-Jesus A, Almeida RP, Lessa H, Baccelar O & Carvalho EM. Cytokine profile and pathology in human leishmaniasis. *Braz J Med Biol Res* 1998; **31**: 143–148.

41 Barral-Netto M, Brodskyn C, Carvalho EM & Barral A. Human-leishmaniasis@cytokines.bahia.br. *Braz J Med Biol Res* 1998; **31**: 149–155.

42 Campanelli AP, Roselino AM, Cavassani KA, *et al.* $CD4^+$ $CD25^+$ T cells in skin lesions of patients with cutaneous leishmaniasis exhibit phenotypic and functional characteristics of regulatory T cells. *J Infect Dis* 2006; **193**: 1313–1322.

43 Cáceres-Dittmar G, Tapia FJ, Sanchez MA, *et al.* Determination of the cytokine profile in American cutaneous leishmaniasis using the polymerase chain reaction. *Clin Exp Immunol* 1993; **91**: 500–505.

44 Pirmez C, Yamamura M, Uyemura K, Paes-Oliveira M, Conceição-Silva F & Modlin RL. Cytokine patterns in the pathogenesis of human leishmaniasis. *J Clin Invest* 1993; **91**: 1390–1395.

45 Silveira FT, Lainson R, Shaw JJ, De Souza AAA, Ishikawa EA & Braga RR. Cutaneous leishmaniasis due to *Leishmania* (*Leishmania*) *amazonensis* in Amazonian Brazil, and the significance of a negative Montenegro skin-test in human infections. *Trans R Soc Trop Med Hyg* 1991; **85**: 735–738.

46 Silveira FT, Blackwell JM, Ishikawa EA, *et al.* T-cell responses to crude and defined leishmanial antigens in patients from the lower Amazon region of Brazil infected with different species of *Leishmania* of the subgenera *Leishmania* and *Viannia*. *Parasite Immunol* 1998; **20**: 19–26.

47 Lemos de Souza V, Ascenção Souza J, Correia Silva TM, Sampaio Tavares Veras P & Rodrigues de Freitas LA. Different *Leishmania* species determine distinct profiles of immune and histopathological responses in CBA mice. *Microbes Infect* 2000; **2**: 1807–1815.

48 Guimarães ET, Santos LA, Ribeiro dos Santos R, Teixeira MM, Dos Santos WL & Soares MB. Role of interluekin-4 and prostagladin E2 in *Leishmania amazonensis* infection of BALB/c mice. *Mic Infect* 2006; **8**: 1219–1226.

49 Martinez-Arends A, Tapia FJ, Caceres-Dittmar G, Mosca W, Valecil L & Convit J. Immunocytochemical characterization of immune cells in lesions of American cutaneous leishmaniasis using novel T cell markers. *Acta Trop* 1991; **49**: 271–280.

50 Faria DR, Gollob KJ, Barbosa J Jr, *et al.* Decrease in situ expression of interleukin-10 receptor is correlated with the exacerbated inflammatory and cytotoxic responses observed in mucosal leishmaniasis. *Infect Immun* 2005; **73**: 7853–7859.

51 Bonfim G, Nascimento C, Costa JML, Carvalho EM, Barral-Neto M & Barral A. Variation of cytokine patterns related to therapeutic response in diffuse cutaneous leishmaniasis. *Exp Parasitol* 1996; **84**: 188–194.

52 Peters N & Sacks D. Immune privilege in sites of chronic infection: *Leishmania* and regulatory T cells. *Immunol Rev* 2006; **213**: 159–179.

53 Convit J, Pinardi ME & Rondon AJ. Diffuse cutaneous leishmaniasis: a disease due to an immunological defect of the host. *Trans R Soc Trop Med Hyg* 1972; **66**: 603–610.

54 Barral-Netto M, Cardoso SA & Barral A. Different patterns of disease in two inbred mouse strains infected with a clone of *Leishmania mexicana amazonensis*. *Acta Trop* 1987; **44**: 5–11.

55 Barral A, Pedral-Sampaio D, Grimaldi G Jr, *et al.* Leishmaniasis in Bahia, Brazil: evidence that *Leishmania amazonensis* produces a wide spectrum of clinical disease. *Ame J Trop Med Hyg* 1991; **44**: 536–546.

56 Viana da Costa A, Huerre M, Delacre M, Aurialt C, Correia Costa JM & Verwaerde C. IL-10 leads to a high parasite per-


 

sistence in a resistant mouse model of *Leishmania major* infection. *Parasitol Int* 2002; **51**: 367–379.

57 Villaseñor-Cardoso MI, Salaiza N, Delgado J, Gutierrez-Kobeh L, Perez-Torrez A & Becker I. Mast cells are activated by *Leishmania mexicana* LPG and regulate disease outcome depending on the genetic background of the host. *Parasite Immunol* 2008; **30**: epub ahead of print.

58 Trujillo CM, Robledo SM, Franco JL, Velez ID, Erb KJ & Patinõ PJ. Endemically exposed asymptomatic individuals show no increase in the specific Leishmania (Viannia) panamensis-Th1 immune response in comparison to patients with localized cutaneous leishmaniasis. *Parasite Immunol* 2002; **24**: 455–462.

59 Delgado G, Parra-López CA, Vargas LE, *et al.* Characterizing cellular immune response to kinetoplastid membrane protein-11 (KMP-11) during *Leishmania* (*Viannia*) *panamensis* infection using dendritic cells (DCs) as antigen presenting cells (APCs). *Parasite Immunol* 2003; **25**: 199–209.

60 Calvopina M, Gomez EA, Sindermann H, Cooper PJ & Hashiguchi Y. Relapse of New World diffuse cutaneous leishmaniasis caused by *Leishmania* (*Leishmania*) *mexicana* after miltefosine treatment. *Am J Trop Med Hyg* 2006; **75**: 1074–1077.

61 Hsu AC & Scott P. *Leishmania mexicana* infection induces impaired lymph node expansion and Th1 cell differentiation despite normal T cell proliferation. *J Immunol* 2007; **179**: 8200–8207.

62 Xavier MB, Silveira FT, Demachki S, Ferrreira MMR & Nascimento JL. American tegumentary leishmaniasis: A quantitative analysis of Langerhans cells presents important differences between *L.* (*L.*) *amazonensis* and *Viannia* subgenus. *Acta Trop* 2005; **95**: 67–73.

63 Carvalho LP, Pearce EJ & Scott P. Functional dichotomy of dendritic cells following interaction with *Leishmania* (*V.*) *braziliensis*: Infected cells produce high levels of TNF-α, whereas bystander dendritic cells are activated to promote T cell responses. *J Immunol* 2008; **181**: 6473–6480.

64 Vargas-Inchaustegui DA, Xin L & Soong L. *Leishmania braziliensis* infection induces dendritic cell activation, ISG15 transcription, and the generation of protective immune responses. *J Immunol* 2008; **180**: 7537–7545.

65 Favali C, Tavares N, Clarêncio J, Barral A, Barral-Neto M & Brodskyn C. Leishmania amazonensis *infection impairs differentiation and function of human dendritic cells. J Leuk Biol* 2007; **82**: 1–6.

66 Vasquez RE, Xin L & Sonng L. Effects of CXCL10 on dendritic cell and $CD4^+$ T-cell functions during Leishmania amazonensis infection. *Infect Immun* 2008; **76**: 161–169.

**ANEXO-19**

---

The role of phlebotomine saliva on the enhancement and control of *Leishmania* infection

**Laurenti, M.D.;** da Matta, V.L.R.; Corbett, C.E.P.

Revista do Instituto Adolfo Lutz 2009; submetido

**THE ROLE OF PHLEBOTOMINE SALIVA ON THE ENHANCEMENT AND CONTROL OF *Leishmania* INFECTION.**

**O PAPEL DA SALIVA DE FLEBOTOMÍNEOS NA EXACERBAÇÃO E CONTROLE DA INFECÇÃO POR *Leishmania.***

Márcia Dalastra Laurenti*, Vânia Lúcia Ribeiro da Matta, Carlos Eduardo Pereira Corbett

[1]Laboratório de Patologia de Moléstias Infecciosas (LIM-50) da Faculdade de Medicina da Universidade de São Paulo, São Paulo (SP), Brasil.

Correspondência:

Márcia Dalastra Laurenti

Av. Dr. Arnaldo, 455 – 1º andar – sala 1152

CEP: 01246-903 – Cerqueira César – São Paulo (SP), Brasil

Fone: 55 11 3061-7426

Fax: 55 11 3081-7799

e-mail: mdlauren@usp.br

**O PAPEL DA SALIVA DE FLEBOTOMÍNEOS NA EXACERBAÇÃO E CONTROLE DA INFECÇÃO POR *Leishmania.***


**RESUMO**

A leishmaniose é uma enfermidade infecciosa causada por parasitos do gênero *Leishmania* que são transmitidos por insetos vetores. A infecção no hospedeiro vertebrado se estabelece no momento em que a fêmea do flebotomíneo infectada, ao realizar o repasto sanguíneo, regurgita na pele do mamífero as formas promastigotas metacíclicas do parasito juntamente com parte do conteúdo da glândula salivar do vetor. Tem sido descrito que componentes do conteúdo da saliva do vetor tem propriedades imunomodulatórias facilitando o estabelecimento da infecção no hospedeiro. Por outro lado, outros estudos mostram que a pré-sensibilização do hospedeiro vertebrado com saliva de flebotomíneo leva a proteção da infecção por *Leishmania*. Esta revisão teve como principal objetivo, revisar o papel da saliva na evolução da infecção por *Leishmania*, quer seja na exacerbação ou na proteção.



Palavras-chaves: Leishmaniose, *Leishmania*, Phlebotomíneo, Saliva.

**THE ROLE OF PHLEBOTOMINE SALIVA ON THE ENHANCEMENT AND CONTROL OF *Leishmania* INFECTION.**


## ABSTRACT

Leishmaniasis is an infectious infirmity caused by parasites of the genus *Leishmania*, which are transmitted by sand fly vectors. Infection of the vertebrate host is established when an infected female phlebotomine regurgitates the metacyclic promastigotes of the parasite into the mammalian skin during blood feed, together with part of the vector salivary gland contents. It has been reported that components of vector saliva content possess immunomodulatory properties that facilitate the establishment of infection in the host. On the other hand, other studies show that presensitization of the vertebrate host to phlebotomine saliva leads to protect against *Leishmania* infection. The main aim of this report was to review the role of saliva in the evolution of *Leishmania* infection, with regard to exacerbation and protection.



Keywords: Leishmaniasis, *Leishmania*, Phlebotomine, Saliva.

## INTRODUCTION

Leishmaniases are a group of noncontagious infectious diseases, with chronic evolution, caused by different species of parasitic protozoans of the genus *Leishmania*. Visceral leishmaniasis principally affects cells of the mononuclear phagocyte system of the bone marrow, lymph nodes, spleen and liver[1,2]. Cutaneous leishmaniasis is mainly characterized by skin tissue compromise and secondarily, by mucosa tissue lesions, depending on the parasite species and host immunogenetic factors[3,4].

Leishmaniases are amply distributed worldwide, occurring in numerous countries in the Americas and Europe. The disease has also been reported in regions in Africa, in Middle Eastern countries and China. In the Americas, leishmaniases are widely distributed from southern United States, through Central America to northern Argentina. In the American continent, Brazil represents the largest territorial extension with endemic areas and one of the countries with the highest rates of notification for this infection[5,6].

In the Americas, leishmaniases are considered primary zoonoses of wild mammals, such as rodents, marsupials, edentates and primates, among which different species of *Leishmania* are transmitted by the bite of phlebotomine insect vectors. Humans acquire the infection when they enter in contact with forest areas where the wild enzootic cycle of different parasite species occurs. Thus, the disease assumes an occupational character, occurring in professional categories that expose humans to intimate contact with the forest. Moreover, in regions that undergo expressive environmental changes, domestic animals can exert an important role in the biological cycle of the parasites; as reservoirs that maintains the parasites in the natural environment. In these regions, environmental changes also exert a major influence on the biological behavior of species of phlebotomine vectors, as the most resistant species

are capable of adapting to the environmental transformations, establishing new ecological niches for their survival in peridomestic settings[7].

Leishmaniasis agents are protozoan parasites of different species belonging to the genus *Leishmania*. Currently, approximately 30 *Leishmania* species are known worldwide, of which 22 are considered agents of human leishmaniases. Species of the genus *Leishmania* are classified into two subgenera according to the evolutionary behavior of the parasite in the digestive tract of the phlebotomine vector: *Viannia*, which develops from the posterior to the anterior midgut; and *Leishmania*, which develops from the middle to the anterior midgut[7]. It should be noted that all the species of the subgenus *Viannia* are autochthones of the Americas, while species of the subgenus *Leishmania* are found in the Americas, Europe and Asia.

Infection of the vertebrate host is established when an infected phlebotomine female regurgitates the metacyclic promastigotes of the parasite into the mammalian skin during blood feeding, together with part of the vector salivary gland contents. At this time, the current understanding is that the majority of the parasites are eliminated by the lithic action of the complement system and by neutrophils and eosinophils present in the host blood that flow to the site of the skin punctured by the vector proboscis[8]. However, promastigote forms that escape the nonspecific host defense mechanisms are phagocytized by skin macrophages, housed within the parasitophorous vacuoles, where they transform into the amastigote forms. After successive binary divisions, the mass of parasites provokes increased intracytoplasmic pressure inside the macrophage, disrupting the host cell and the free amastigotes are phagocytized by other macrophages, establishing the infectious cycle in the host[7].

## THE ROLE OF SALIVA ON THE EXACERBATION OF EXPERIMENTAL *Leishmania* INFECTIONS

Not so far, hematophagous vectors were regarded as simple delivery tools of pathogens they carry. However, they all share one important feature: during probing and feeding, they salivate at the injured site facilitating blood sucking, and the establishment of the infecting pathogen by the action of active components found in saliva[9,10,11,12].

The first report concerning the effect of vector saliva on *Leishmania* infection dates from 1988, when Titus & Ribeiro[13] showed a markedly enhancement of the cutaneous lesions and parasite load in mice infected with *L. major* in the presence of salivary gland lysate (SGL) of *Lutzomyia longipalpis* compared to animals inoculated only with parasites. Also, they further observed that infection could be established with only 10 to 100 parasites using SGL in the inoculum[14]. Together, these two studies resulted in the establishment of experimental models of *Leishmania* infection under closer conditions to the natural transmission.

Later studies showed that the effect of *Lu. longipalpis* SGL on the evolution of experimental infection was not dependant on the mice lineage used, since both resistant and susceptible mice to *L. major* produced larger lesions in the presence of saliva compounds[15].

Other reports corroborated the effect of *Lu. longipalpis* SGL on the increased severity of infections caused by *L. major*[16], as well as by other species of the parasite. *L. (V.) braziliensis*, which produces spontaneously regressing lesions even in BALB/c mice that are highly susceptible to other species of *Leishmania*, induced larger and longer-lasting lesions with intense parasitism if co-injected with *Lu. longipalpis* SGL[17,18,19]. Lesion severity and the number of parasites also increased in infections with *L. amazonensis*[15,20,21].

One important issue was still required to be checked: the effect of saliva in the natural vector/parasite combination. Only recently, *Lu. longipalpis* SGL was tested in *L. chagasi* infections. Surprisingly, the addition of SGL in the inoculum did not alter the evolution of infection in dogs, did not lead to early amastigote detection and did not increase the parasite load in the organs compared to control animals[22]. Similar results were obtained for experimental infection in hamsters[23]. In another natural vector/parasite combination, *Lu. whitmani* SGL promoted larger cutaneous lesions in mice infected with *L. braziliensis*[24]. Nonetheless, *in vitro* experiments showed that pretreatment of human monocytes with *Lu. intermedia* SGL did not change the parasite burden, as determined by the number of monocytes infected by *L. braziliensis* or by the number of amastigotes per infected cell, compared to monocytes not exposed to SGL[25]. However, it should be highlighted that the exacerbation of cutaneous lesions and increased parasitism have been consistently verified in *L. major* infections in the presence of SGL from *Phlebotomus papatasi*, the natural parasite vector in the Old World[15,26].

As a whole, vector saliva is accepted as a crucial element for the establishment of *Leishmania* sp based on evidences that it : a- minimizes host hemostatic processes by vasodilatory and antiplatelet actions[10,27,28],b- modulates the host immune response, and c- enhances parasite infectivity. Concerning this issue, Charlab and collaborators[29,30] verified cytostatic effect of *Lu. longipalpis* SGL on *Leishmania*, indicating a role in the generation of infective parasites .

Regarding both the suppressive and immunogenic modulatory effects, *in vitro* experiments show that mice macrophages pretreated with *Lu. longipalpis* SGL are incapable of presenting antigens, which compromises the activation of specific T lymphocytes, are refractory to IFN-γ activation, and drastically reduce the production of

hydrogen peroxide and nitric oxide, the main molecules responsible for lysing the parasite[14,31,32].

Similar data have also been observed concerning SGL of Old World vectors, as human mononuclear cells when exposed to *P. papatasi* SGL produce lower levels of IFN-γ and higher levels of IL-6[33]. Moreover, SGL of *Phlebotomus duboscqi*, the vector of *L. major* in Kenya, is chemotatic for monocytes and this attraction could represent one of the mechanisms by which the saliva ensures the successful parasitism of macrophages in susceptible hosts[34].

The *in vivo* effects of *Lu. longipalpis* or *P. papatasi* SGL on the immune response in experimental infections show a much more complex picture and heterogenous results, which are dependent on the parasite species and the genetic background of the animals used. Resistance of C57BL/6, CBA and C3H mice to *L. major* infection is a result of the production of cytokines associated with Th1, especially IFN-γ and TNF-α, while those associated with Th2, particularly IL-4, determine disease progression in BALB/c mice[35].

The presence of *P. papatasi* SGL in the *L. major* inoculum promotes increased levels of IL-4, but not of IL-10 and TNF-α, and a reduction in IFN-γ, IL-12 and nitric oxide synthase production, a profile associated with the enhanced severity of cutaneous lesions induced by saliva[26,36]. In contrast, *Lu. longipalpis* SGL determines increased IL-10 production in BALB/c when inoculated with *L. major*[37].

Spontaneous control of experimental *L. braziliensis* infection is determined by IFN-γ and IL-12 generation and low production of IL-4[38,39]. *Lu. longipalpis* SGL promotes an increase of two to three-fold more IL-4 levels in BALB/c infected with *L. braziliensis* and lesions which persist for the lifetime of the mice[18].

Infection with *Leishmania amazonensis*, on the other hand, causes progressive cutaneous lesions in most inbred lineages of mice, with no evidence of a polarized Th1/Th2 response as observed in that caused by *L. major*[40]. Among others, IL-10, but not IL-4, has an important role in compromising the host immune response[41]. Addition of *Lu. longipalpis* SGL to the inoculum promotes a significant rise in IL-10 levels that is associated with increased parasite infectivity and larger lesions[20].

Questions have been raised regarding which saliva components could be related to the effects above mentioned, since a complex network of biologically and pharmacologically active molecules have been detected in the salivary secretion, although investigations are still ongoing to better characterize these compounds (to review see Kamhawi, 2000 and Andrade et al., 2007)[42,43]. The most studied saliva is that of *Lu. longipalpis* whose principal component is maxadilan (MAX), a potent vasodilator that also modulates cytokines production of human and mice macrophages by up-regulating those associated with Th2, (IL-10, IL-6 and TGF-β) and down-regulating cytokines associated with Th1 (IL-12 and TNF-α) and nitric oxide production[33,44]. As a consequence, the parasite load of peritoneal macrophages of mice infected with *L. major* is drastically increased in the presence of MAX[44]. *In vivo* experiments show that MAX can also exacerbate infection with *L. major* to the same degree as whole salivary gland[16,45]; nonetheless, another study reports dissociation between the vasodilator effect of MAX and lesion enhancement in infections caused by *L. major* or *L. braziliensis*[46].

Maxadilan has not been identified in the saliva of other phlebotomines. However, other components as adenosine and its precursor 5'-AMP are detected in *P. papatasi* saliva[28] and both present vasodilatory and antiplatelet-aggregation properties. In addition, they enhance the production of Th2 cytokines (IL-10, IL-6), but down-regulate

those of Th1 (IL-2 and IFN-γ) and nitric oxide synthesis[47,48]. Adenosine and AMP have also been detected in *Lu. Longipalpis*, but their *in vivo* effects on *Leishmania* infection have not been performed yet.

Currently, the mechanisms by which salivary compounds act and which of them are involved in the modulation of host response and on parasite survival remain an unsolved question. Given the complexity of these molecules and their possible interactions, it seems unlikely that full comprehension of these mechanisms will be elucidated soon.

Despite the fact that the parasites are transmitted exclusively by sand flies, the establishment of infection in experimental models via sand fly bites is unusual and the scarce reports in literature have not addressed the host response to infective bites[49,50]. However, Kamhawi and collaborators[51] recently described a murine model of *L. major* infection transmitted by laboratory-reared *P. papatasi* that made it possible to compare the effects of real sand fly saliva with salivary glands used in all experiments concerning saliva effects. Surprisingly, the infection of C57BL/6 mice transmitted by vector bites always resolved over time, similarly to mice inoculated with parasite alone and in strong contrast to the results obtained when SGL is inoculated together with *L. major*[26]. In addition, the bites of infected *P. papatasi* did not elicit a potent IL-4 response at the inoculation site observed in studies involving needle inoculation of SGL, which was again more comparable to the inoculation with only parasites[26]. These data highlight a probable bias when using salivary glands instead of real saliva.

To the best of our knowledge, all experiments concerning vector saliva effects were performed with lab-colonized sand flies, which raised the question of whether SGL from lab-colonized vectors and that from sand flies recently captured in the field could exert different effects on host and parasite survival. Our first study using SDS-

PAGE gel electrophoresis indicated diversity in the expression and concentration of proteins between *Lu. longipalpis* SGL from these distinct sources, which prompted us to investigate their effects on *Leishmania* infection. We verified that wild-caught *Lu. longipalpis* SGL induced smaller sized lesions and lower tissue parasitism, less inflammatory cells at the inoculation site and lower production of cytokines associated with a susceptible response, compared to that obtained from laboratory-reared vectors[52]. The results address another probable bias caused by the use of SGL from lab-colonized sand flies instead of wild-caught vector SGL in experiments concerning saliva effects.

## THE ROLE OF SALIVA IN PROTECTION FROM INFECTIONS BY *Leishmania*

Recent studies have shown that components of insect vector saliva could be candidates for vaccines against leishmaniases[53,54,55]. Belkaid and collaborators[26] were the first group to demonstrate that preexposure to the saliva could result in protection. In their work, the exacerbation effect of infection by *L. major* in mice in the presence of *P. papatasi* SGL was abolished when the mice were preexposed to vector saliva. In experiments involving the transmission of *L. major* by *P. papatasi* bite, observation determined a significant reduction in pathology in mice previously exposed to uninfected phlebotomine bite and in the transmission of parasites by other phlebotomines[51]. The protection conferred by presensitization with vector saliva appears to be associated with the delayed hypersensitivity (DTH) response, since inhabitants from endemic areas exhibit a strong DTH response to vector bites[42,56]. This diverse and intense dermatological reaction has also been observed in volunteers exposed several times to *Lu. Longipalpis* vector bites[57]. In mice preexposed to SGL, protection is also

associated with reactive antibody generation that neutralizes the enhancing effect of the saliva in *Leishmania* infections[26].

Studies in endemic areas suggest that natural exposure to uninfected phlebotomine bite could influence the epidemiology of the disease. In residents from an endemic area for visceral leishmaniasis, the presence of class IgG antibodies against the saliva of *Lu. Longipalpis* was detected[58]. High levels of IgG1, IgG4 and IgE were detected in the sera of volunteers exposed to *Lu. Longipalpis* bites[57]. Simultaneous to the development of humoral immune response to saliva, immunity mediated by cells against *Leishmania* is also observed in residents from endemic areas[59]. Individual response to phlebotomine saliva can vary depending on genetic factors. In this way, individuals that develop positive DTH for *Leishmania* antigens together with anti-saliva IgG antibodies could be protected against visceral leishmaniasis; whereas individuals showing low anti-saliva antibody titers and negative DTH would not be[43].

The protective response triggered by components of insect vector saliva appears to be parasite/vector specific, since the exposure of BALB/c mice to bites from Old World vectors *P. papatasi* and *P. sergenti* and New World vector *Lu. longipalpis*, led to the production of specific antibodies against the different saliva sources used. Moreover, challenge with an infection specific to the New World, *L. amazonensis*, led to partial protection of mice preexposed to *Lu. longipalpis* bites and the absence of protection for the other two phlebotomine species used[21].

A recent study showed that the immunization of hamsters with *Lu. longipalpis* salivary protein conferred protection against the fatal evolution of experimental visceral leishmaniasis, such that the low parasite load was correlated with an increase in the IFN-γ/TGF-β ratio and an increase in iNOS expression in the spleen and liver; thus reinforcing the concept of using phlebotomine saliva components in vaccine strategies[23].

In contrast, immunization of BALB/c mice with *Lu. intermedia* salivary gland sonicate followed by challenge with an inoculum containing *L. braziliensis* promastigotes or *L. braziliensis* with added *Lu. intermedia* salivary gland sonicate, did not lead to protection, rather to a prolonged infection evolution[60]. Immunization with *Lu. longipalpis* followed by the same challenge, showed infection evolution similar to controls, with increase in lesion size up to six weeks postinfection, followed by spontaneous cure around 10 weeks postinfection. Besides vector/parasite specificity in the development of an effective immunity against leishmaniasis, the different proteins that exist in phlebotomine saliva must also be considered, since distinct proteins, such as PpSP15 and PpSP44 from *P. papatasi*, induce different immunological profiles that are correlated with resistance and susceptibility, respectively[61].

**CONCLUDING REMARKS:**

- Insect vector saliva contains pharmacologically active components that block vertebrate host hemostatic processes, facilitating blood feeding and the establishment of *Leishmania* infection.
- Extracts or lysates of *Lu. longipalpis* salivary gland lead to the exacerbation of infection caused by different *Leishmania* species in different mice strains.
- Insect vector saliva plays a crucial role in establishing infection by helping the generation of infective metacyclic promastigote forms in the vector gut and by modulating the host immune response, compromising the presentation of antigens by macrophages, as well as by down-regulating Th1 and up-regulating Th2 responses.
- Regarding parasite/vector specificity, *P. papatasi* salivary gland extract promotes the exacerbation of infection by *L. major*; whereas *Lu. longipalpis* and

*Lu. intermedia* salivary gland extracts do not lead to the exacerbation of infection by *L. (L.) chagasi* and *L. (V.) braziliensis*, respectively.

- *Leishmania* infection in the presence of wild-captured *Lu. longipalpis* salivary gland extract induces smaller sized lesions, less inflammatory response in the skin lesion site and lower levels of cytokines associated with susceptibility compared to infection in the presence of lab-colonized vector salivary gland extract.
- Presensitization of vertebrate host with salivary gland extract or by vector bite protects the host against infection caused by coinoculation of parasites and vector saliva. Such protection is related to delayed hypersensitivity response and appears to be species-specific, although contradictory results can be found in the literature.
- Different proteic fractions of vector saliva used in host presensitization may or may not induce protection.

Taking all together, discrepancies were verified while comparing the available data regarding the effects of vector saliva, which clearly demonstrate the need for further studies to fully understand the high complexity of the vector- parasite- host interactions and the need to carefully investigate the role of saliva in the context of actual transmission in nature.

## REFERENCES

1. Corbett CEP, Duarte MIS. Histopathological patterns of the liver involvement in visceral leishmaniasis. Rev. Inst. Med. Trop. São Paulo 1987; 29: 131-136.

2. Corbett CEP, Paes RA, Laurenti MD, Andrade Junior HF, Duarte MI. Histopathology of lymphoid organs in experimental leishmaniasis. Int. J. Exp. Pathol. 1992; 73: 417-433.

3. Silveira FT, Lainson R, Corbett CEP. Clinical and immunopathological spectrum of American cutaneous leishmaniasis with special reference to the disease in Amazon Brazil: Review. Mem. Inst. Oswaldo Cruz 2004; 99: 239-251.

4. Silveira FT, Lainson R, Corbett CEP. Further observations on clinical, histopathological and immunological features of borderline disseminated cutaneous leishmaniasis caused by *Leishmania (Leishmania) amazonensis*. Mem. Inst. Oswaldo Cruz 2005; 100: 525-534.

5. WHO. Control of the Leishmaniasis. Geneva, 1990. v. 158. (Technical Report Series; 793).

6. FUNASA – Fundação Nacional de Saúde. Manual de Controle da Leishmaniose Tegumentar Americana. Brasília, 2000. 62 p.

7. Lainson R, Shaw JJ. Evolution, classification and geographic distribution. In: Peters, W.; Killick- Kendrick, R. (Ed.) The leishmaniasis in biology and medicine. London: Academic Press, 1987, v. 1, p.1- 20.

8. Laurenti MD, Corbett CEP, Sotto MN, Sinhorini IL, Goto H. The role of complement in the acute inflammatory process in the skin and in host-parasite interation in hamsters inoculated with *Leishmania (Leishmania) chagasi*. Int. J. Exp. Pathol. 1996; 77: 15- 24.

9. Ribeiro JM. Role of saliva in blood-feeding by arthropods. Ann. Rev. Entomol. 1987; 32: 463-478.

10. Ribeiro JM. Vector saliva and its role in parasite transmission. Review. Exp. Parasitol. 1989; 69: 104–106.

11. Champagne D. The role of salivary vasodilators in bloodfeeding and parasite transmission. Parasitol. Today 1994; 10: 430–433.

12. Ribeiro JM. Blood-feeding arthropods: live syringes or invertebrate pharmacologists? Infect Agents Dis. 1995; 4: 143-152.

13. Titus RG, Ribeiro JM. Salivary gland lysates from the sand fly *Lutzomyia longipalpis* enhance *Leishmania* infectivity. Science 1988; 239(4845): 1306-8.

14. Titus RG, Ribeiro JM. The role of vector saliva in transmission of arthropod-borne diseases. Parasitol. Today 1990; 6: 157-160.

15. Theodos CM, Ribeiro JM, Titus RG. Analysis of enhancing effect of sand fly saliva on *Leishmania* infection in mice. Infect. Immun. 1991; 59: 1592-8.

16. Morris RV, Shoemaker CB, David JR, Lanzaro GC, Titus RG. Sandfly maxadilan exacerbates infection with *Leishmania major* and vaccinating against it protects against *L. major* infection. J. Immunol. 2001; 167: 5226-30.

17. Samuelson E, Lerner R, Tesh, Titus R. A mouse model of *Leishmania braziliensis braziliensis* infection produced by coinjection with sand fly saliva. J. Exp. Med. 1991; 173: 49–54.

18. Lima HC, Titus RG. Effects of sand fly vector saliva on development of cutaneous lesions and the immune response to *Leishmania braziliensis* in BALB/c mice. Infect. Immun. 1996; 64: 5442–5445.

19. Donnelly KB, Lima HC Titus RG. Histologic characterization of experimental cutaneous Leishmaniasis in mice infected with *Leishmania braziliensis* in the presence or absence of sand fly vector salivary gland lysate. J. Parasitol. 1998; 84: 97–103.

20. Norsworthy NB, Sun J, Elnaiem D, Lanzaro G, Soong L. Sand fly saliva enhances *Leishmania amazonensis* infection by modulating interleukin-10 production. Infect. Immun. 2004; 72: 1240-7.

21. Thiakaki M, Rohousova I, Volfova V, Volf P, Chang KP, Soteriadou K. Sand fly specificity of saliva-mediated protective immunity in *Leishmania amazonensis*-BALB/c mouse model. Microbes Infect. 2005; 7: 760-766.

22. Paranhos-Silva M, Oliveira GG, Reis EA, de Menezes RM, Fernandes O, Sherlock I, et al. A follow-up of Beagle dogs intradermally infected with *Leishmania chagasi* in the presence or absence of sand fly saliva. Vet. Parasitol. 2003; 114: 97-111

23. Gomes R, Teixeira C, Teixeira MJ, Oliveira F, Menezes MJ, Silva C, et al. Immunity to a salivary protein of a sand fly vector protects against the fatal outcome of visceral leishmaniasis in a hamster model. Proc. Natl. Acad. Sci. USA 2008; 105: 7845-50.

24. Bezerra HS, Teixeira MJ. Effect of *Lutzomyia whitmani* (Diptera: Psychodidae) salivary gland lysates on *Leishmania (Viannia) braziliensis* infection in BALB/c mice. Mem. Inst. Oswaldo Cruz. 2001; 96:349-51

25. Menezes MJ, Costa DJ, Clarêncio J, Miranda JC, Barral A, Barral-Netto M, et al. Immunomodulation of human monocytes following exposure to *Lutzomyia intermedia* saliva. BMC Immunol. 2008; 9: 12.

26. Belkaid Y, Kamhawi S, Modi G, Valenzuela J, Noben-Trauth N, Rowton E, et al. Development of a natural model of cutaneous Leishmaniasis: Powerful effects of vector saliva and saliva preexposure on the long-term outcome of *Leishmania major* infection in the mouse ear dermis. J. Exp. Med. 1998; 10: 1941-1953.

27. Ribeiro JM, Modi GB, Tesh RB. Salivary apyrase activity of some Old World phlebotomine sand flies. Insect Biochem. 1989; 19: 409–412.

28. Ribeiro JM, Katz O, Pannell LK, Waitumbi J, Warburg A. Salivary glands of the sand fly *Phlebotomus papatasi* contain pharmacologically active amounts of adenosine and 5'-AMP. J. Exp. Biol. 1999; 202: 1551–1559.

29. Charlab R, Ribeiro JM. Cytostatic effect of *Lutzomyia longipalpis* salivary gland homogenates on *Leishmania* parasites. Am. J. Trop. Med. Hyg. 1993; 48: 831-838.

30. Charlab R, Tesh RB, Rowton ED, Ribeiro JM. *Leishmania amazonensis*: sensitivity of different promastigote morphotypes to salivary gland homogenates of the sand fly *Lutzomyia longipalpis*. Exp. Parasitol. 1995; 80: 167–175.

31. Theodos CM, Titus RG. Salivary gland material from the sand fly *Lutzomyia longipalpis* has an inhibitory effect on macrophage function in vitro. Parasite Immunol. 1993; 15: 481–487.

32. Hall LR, Titus RG. Sand fly vector saliva selectively modulates macrophage functions that inhibit killing of *Leishmania major* and nitric oxide production. J. Immunol. 1995; 155: 3501–3506.

33. Rogers KA, Titus RG. Immunomodulatory effects of Maxadilan and *Phlebotomus papatasi* sand fly salivary gland lysates on human primary in vitro immune responses. Parasite Immunol. 2003; 25:127-34.

34. Anjili CO, Mbati PA, Mwangi RW, Githure JI, Olobo JO, Robert LL, et al. The chemotactic effect of *Phlebotomus duboscqi* (Diptera: Psychodidae) salivary gland lysates to murine monocytes. Acta Trop. 1995; 60: 97–100.

35. Locksley RM, Heinzel FP, Holaday BJ, Mutha SS, Reiner SL, Sadick MD. Induction of Th1 and Th2 CD4+ subsets during murine *Leishmania major* infection. Review. Res. Immunol. 1991; 142: 28-32.

36. Mbow ML, Bleyenberg JA, Hall LR, Titus RG. *Phlebotomus papatasi* sand fly salivary gland lysate down-regulates a Th1, but up-regulates a Th2, response in mice infected with *Leishmania major*. J. Immunol. 1998; 161: 5571-7

37. Monteiro MC, Lima HC, Souza AA, Titus RG, Romão PR, Cunha FQ. Effect of *Lutzomyia longipalpis* salivary gland extracts on leukocyte migration induced by *Leishmania major.* Am. J. Trop. Med. Hyg. 2007; 76: 88-94.

38. DeKrey GK, Lima HC, Titus RG. Analysis of the immune responses of mice to infection with *Leishmania braziliensis*. Infect. Immun. 1998; 66: 827–829.

39. Rocha FJ, Schleicher U, Mattner J, Alber G, Bogdan C. Cytokines, signaling pathways, and effector molecules required for the control of *Leishmania (Viannia) braziliensis* in mice. Infect. Immun. 2007; 75: 3823-32.

40. Ji J, Sun J, Qi H, Soong L. Analysis of T helper cell responses during infection with *Leishmania amazonensis.* Am. J. Trop. Med. Hyg. 2002; 66: 338–345.

41. Ji J, Sun J, Soong L. Impaired expression of inflammatory cytokines and chemokines at early stages of infection with *Leishmania amazonensis*. Infect. Immun. 2003; 71: 4278–4288

42. Kamhawi S. The biological and immunomodulatory properties of sand fly saliva and its role in the establishment of *Leishmania* infections. Microbes Infect. 2000; 2:1765-73.

43. Andrade BB, de Oliveira CI, Brodskyn CI, Barral A, Barral-Neto M. Role of sand fly in human and experimental leishmaniasis. Review. Scan. J. Immunol. 2007; 66: 122-127.

44. Brodie TM, Smith MC, Morris RV, Titus RG. Immunomodulatory Effects of the *Lutzomyia longipalpis* Salivary Gland Protein Maxadilan on Mouse Macrophages. Infect. Immun. 2007; 75: 2359–2365.

45. Titus R, Mbow M. The vasodilator of *Lutzomyia longipalpis* sand fly salivary glands exacerbates infection with *Leishmania major* in mice. FASEB J. 1991; (2 Suppl S): A970.

46. Castro-Sousa F, Paranhos-Silva M, Sherlock I, Paixão MS, Pontes de Carvalho LC, dos Santos WL. Dissociation between vasodilation and *Leishmania* infection-enhancing effects of sand fly saliva and maxadilan. Mem. Inst. Oswaldo Cruz 2001; 96: 997-999.

47. Zidek Z. Adenosine–cyclic AMP pathways and cytokine expression. Eur. Cytokine Netw. 1999; 10: 319–328.

48. Katz O, Waitumbi JN, Zer R, Warburg A. Adenosine, AMP, and protein phosphatase activity in sandfly saliva. Am. J. Trop. Med. Hyg. 2000; 62:145-50.

49. Lainson R, Ward RD, Shaw JJ. Experimental transmission of *Leishmania chagasi*, causative agent of neotropical visceral leishmaniasis, by the sandfly *Lutzomyia longipalpis*. Nature 1977; 266(5603): 628-30.

50. Lawyer PG, Githure JI, Anjili CO, Olobo JO, Koech DK, Reid GD. Experimental transmission of *Leishmania major* to vervet monkeys (Cercopithecus aethiops) by bites of *Phlebotomus duboscqi* (Diptera: Psychodidae). Trans. R. Soc. Trop. Med. Hyg. 1990; 84: 229-32.

51. Kamhawi S, Belkaid Y, Modi G, Rowton E, Sacks D. Protection against cutaneous leishmaniasis resulting from bites of uninfected sand flies. Science 2000; 290: 1351-1354.

52. Laurenti MD, Silveira VMS, Secundino NFC, Corbett CEP, Pimenta PFP. Saliva of laboratory-rared *Lutzomyia longipalpis* exacerbates *Leishmania (Leishmania) amazonensis* more potently than saliva of wild-caught *Lutzomyia longipalpis*. Parasitol. Int. 2009; doi: 10.1016/j.paraint.2009.05.005.

53. Valenzuela JG, Belkaid Y, Garfield MK, Mendez S, Kamhawi S, Rowton ED, et al. Toward a defined anti-*Leishmania* vaccine targeting vector antigens: characterization of a protective salivary protein. J. Exp. Med. 2001; 194: 331-342.

54. Requena JM, Iborra S, Carrion J, Alonso C, Soto M. Recent advances in vaccines for leishmaniasis. Expert Opin. Biol. Ther. 2004; 4: 1505-1517.

55. Brodskyn C, de Oliveira CI, Barral A, Barral-Netto M. Vaccines in leishmaniasis: advances in the last five years. Expert Rev. Vaccines 2007; 2: 705-717.

56. Theodor, O. A study of the reaction to *Phlebotomus* bites with some remarks on harara. Trans. R. Soc. Trop. Med. Hyg. 1935; 29: 273- 284.

57. Vinhas V, Andrade BB, Paes F, Bomura A, Clarêncio J, Miranda JC, et al. Human anti-saliva immune response following experimental exposure to the visceral leishmaniasis vector, *Lutzomyia longipalpis*. Eur. J. Immunol. 2007; 37: 3111-3121.

58. Barral A, Honda E, Caldas A, Costa J, Vinhas V, Rowton ED, et al. Human immune response to sand fly salivary gland antigens: a useful epidemiological marker? Am. J. Trop. Med. Hyg. 2000; 62: 740-745.

59. Gomes RB, Brodskyn C, de Oliveira CI, Costa J, Miranda JC, et al. Seroconversion against *Lutzomyia longipalpis* saliva concurrent with the development of anti-*Leishmania chagasi* delayed-type hypersensitivity. J. Infec. Dis. 2002; 186:1530-1534.

60. de Moura TR, Oliveira F, Novais FO, Miranda JC, Clarêncio J, Follador I, et al. Enhanced *Leishmania braziliensis* infection following pre-exposure to sandfly saliva. PLOS Neg. Trop. Dis. 2007; 1(2 e84): 1-10.

61. Oliveira F, Lawyer PG, Kamhawi S, Valenzuela JG. Immunity to distinct sand fly salivary proteins primes the anti-*Leishmania* immune response towards protection or exacerbation of disease. PLOS Neg. Trop. Dis. 2008; 2(4 e226): 1-9.

**ANEXO-20**

---

Saliva of laboratory-reared *Lutzomyia longipalpis* exacerbates *Leishmania (Leishmania) amazonensis* infection more potently than saliva of wild-caught *Lutzomyia longipalpis*

**Laurenti, M.D.;** Silveira, V.M.S.; Secundino, N.F.C.; Corbett, C.E.P.; Pimenta, P.P.F.

Parasitology International 2009; 58: 220-226

Parasitology International 58 (2009) 220–226

Contents lists available at ScienceDirect

Parasitology International

journal homepage: www.elsevier.com/locate/parint

# Saliva of laboratory-reared *Lutzomyia longipalpis* exacerbates *Leishmania (Leishmania) amazonensis* infection more potently than saliva of wild-caught *Lutzomyia longipalpis*

Márcia Dalastra Laurenti [a,*], Veruska Marques dos Santos Silveira [a], Nágila Francinete Costa Secundino [b], Carlos Eduardo Pereira Corbett [a], Paulo Paulocci Filemon Pimenta [b]

[a] *Laboratory of Pathology of Infectious Diseases (LIM-50), Department of Pathology, Medical School, University of São Paulo, Av. Dr. Arnaldo 455, CEP: 01246-903, São Paulo (SP), Brazil*
[b] *Laboratory of Medical Entomology, Centro de Pesquisas René Rachou, Fundação Oswaldo Cruz-FIOCRUZ, Av. Augusto de Lima, 1715, CEP: 30190-002, Belo Horizonte (MG), Brazil*

ARTICLE INFO

*Article history:*
Received 12 December 2008
Received in revised form 6 May 2009
Accepted 9 May 2009
Available online 18 May 2009

*Keywords:*
*Leishmania (Leishmania) amazonensis*
*Lutzomyia longipalpis*
Saliva
Infectivity
Pathology

ABSTRACT

In order to compare the saliva effect from wild-caught and lab-reared *L. longipalpis* on the development of experimental cutaneous leishmaniasis, C57BL/6 mice were inoculated subcutaneously into the hind footpads with promastigotes of *L. (L.) amazonensis* plus salivary gland lysate from wild-caught (SGL-W) and lab-colonized (SGL-C) vectors. Lesion sizes were significantly larger in the mice infected with both saliva compared to mice infected with parasites alone; moreover, the lesions caused by parasite + SGL-C were significantly larger than the lesions caused by parasite + SGL-W. Histopathological morphometric studies regarding the acute phase of infections showed lower numbers of polymorphonuclear cells, greater numbers of mononuclear cells and parasites in SGL-C infected mice compared to SGL-W infected mice. In the chronic phase of infection, the number of mononuclear cells was lower and the number of parasites was greater in SGL-C infected mice than SGL-W infected mice. *In vitro* studies showed increased infection index of macrophages infected with parasites plus saliva compared to infection with parasites alone, with no difference between the saliva infection indices. SDS-PAGE gel for SGL-C and SGL-W showed differences in the composition and quantity of protein bands, determined by densitometry. These results call attention to the experimental saliva model, which shows exacerbation of infection caused by sandfly saliva.



## 1. Introduction

Leishmaniasis is an important tropical disease transmitted by sandflies. The parasites are transmitted by the female vector bite during blood feeding on the vertebrate host, which includes humans. Sandfly vector saliva plays an important role in *Leishmania* transmission [1,2]. The capacity of vector saliva to increase *Leishmania* infectivity is restricted to sandfly saliva since the saliva obtained from other bloodsucking arthropods cannot mediate the same phenomenon under experimental conditions [3,4]. Saliva of *L. longipalpis* and *P. papatasi*, the two most widely colonized sandflies and vectors of *Leishmania* in the New and Old World, respectively, is known to possess immunomodulatory activities [5,6].

The increase in *Leishmania* infectivity coinoculated with saliva has been demonstrated using inbred mouse models infected with *L. major* [3], *L. braziliensis* [7] and *L. amazonesis* [8]. Both parasite- and sandfly-derived factors contribute to the increase in infectivity [9]. Lesion sizes and parasite numbers dramatically increase when salivary gland lysate of *L. longipalpis* is added to the inoculum [3]. Increased infectivity has also been shown in susceptible and resistant mice inoculated with *L. major* in the presence *P. papatasi* saliva [10,11]. Sandfly saliva also has the capacity to inhibit macrophage activities during parasite antigen presentation to T lymphocytes [12]. Moreover, *P. papatasi* saliva is chemotactic to mouse peritoneal macrophages [13,14]. During natural infections, this activity could be one of the mechanisms that assist parasite phagocytosis by host macrophages, reducing extracellular parasite exposure to natural immunity components in the inoculation site.

In addition to the exacerbation effect of sandfly saliva in naive mice, protection against *L. major* infection has been shown in mouse models when they are preexposed to noninfected sandfly bites, or preimmunized with saliva [10,15]. Host antibody responses to sandfly saliva are potential markers of the risk of *Leishmania* transmission in endemic areas [16–18]. Furthermore, salivary gland proteins or their cDNAs are also being considered as viable vaccine targets against leishmaniasis [19–21].

All the reports concerning the effects of saliva exacerbation or protection against *Leishmania* infection have been developed using saliva from lab-colonized vectors, likely due to the difficulty of working with wild-caught sandflies. To this date, no consideration has been given

* Corresponding author. Laboratory of Pathology of Infectious Diseases (LIM-50), Medical School, University of São Paulo, Av. Dr. Arnaldo, 455, 1° andar, sala 1152-CEP 01246-903, São Paulo (SP), Brazil. Tel./fax: +55 11 30817799.
*E-mail address:* mdlauren@usp.br (M.D. Laurenti).

1383-5769/$ – see front matter © 2009 Elsevier Ireland Ltd. All rights reserved.
doi:10.1016/j.parint.2009.05.005

to the fact that individuals at risk of exposure to *Leishmania*-harboring sandflies are actually bitten by wild sandfly vectors originating from their endemic areas. Thus, the main objective of this study was to compare the effect of saliva from wild-caught and lab-colonized vectors on the development of cutaneous leishmaniasis.

## 2. Materials and methods

### 2.1. Mice

Female C57BL/6 mice 6 to 8 weeks-old from the General Colony of São Paulo University Medical School were kept in our laboratory during the experiments, according to the methods approved by the Animal Care and Use Committee of São Paulo Medical School.

### 2.2. Parasites

*Leishmania (Leishmania) amazonensis*, MHOM/BR/73/M2269 strain, recently recovered from chronically infected BALB/c mice were cultivated as promastigotes in supplemented RPMI 1640 medium (10% fetal calf serum, 5 mM HEPES, 50 μg/ml gentamicin and 100 U/ml penicillin). Stationary-phase promastigotes were harvested and washed three times in sterile PBS for use.

### 2.3. Sandflies

Wild-caught and lab-colonized *L. longipalpis* sandflies were used. The wild-caught sandflies were collected in Lapinha Cave located in Minas Gerais State, Brazil (longitude 43°57′W and latitude 19°03′S) over a period of 3 days, although those caught in the first collection were not used in order to work with newly released sandflies of similar age. These sandflies were maintained in the insectary for two days until the time of the experiments. The wild-caught sandflies were checked for the absence of blood meal in their guts and egg development in their ovaries in order to confirm that they had no previous blood intake. The lab-colonized sandflies were from a colony initiated with insects collected in the same place and they were reared at least for ten generations before being used in the experiments. Three to five day-old sandfly females from the colony were used in the experiments and were considered of similar age to the wild-caught sandflies. All the sandflies received 5% sugar solution *ad libitum* until the time of the experiments. They were maintained in the insectary of the Laboratory of Medical Entomology at Institute René Rachou (FIOCRUZ-MG) according to the conditions described by Killick-Kendrick et al. [22].

### 2.4. Salivary gland lysates

Salivary gland lysates were obtained from wild-caught (SGL-W) and lab-colonized (SGL-C) sandfly females. At the moment of the dissection, all the sandfly midguts were verified regarding the absence of blood meal. The dissected salivary glands were collected in phosphate buffered saline (PBS), pH 7.2, and stored at −70 °C. At the time of the experiments, the salivary glands were disrupted by freeze-thawing, vortex and rapid centrifugation to discharge possible tissues. Half of a pair of salivary glands was used for each inoculation point for both SGL-C and SGL-W.

### 2.5. SDS-PAGE of salivary gland lysates

SDS-PAGE gel electrophoresis was used to separate and characterize the molecular weights of the SGL-C and SGL-W proteins. After determining the protein concentrations by the Lowry method, 10 μg of the total protein was applied in each line in 12% acrylamide gel under denaturing conditions. Molecular weight standards from 205 kDa to 29 kDa (Sigma Chemical Co. USA) were used. After electrophoresis, the gel was stained with silver nitrate. Densitometric analysis of band intensity for all visible bands was measured by the Eagle Eye gel documentation system (Stratagene, USA).

### 2.6. Effect of SGL on ex vivo Leishmania-infected macrophages

Mouse resident peritoneal macrophages ($1\times10^5$) were allowed to attach to sterile round coverslips (13 mm) and were then placed in 24-well plates in complete RPMI medium. Stationary-phase *L. (L.) amazonensis* promastigotes were added to the macrophage monolayers (5:1) in the presence and absence of half of a pair of salivary glands, for both SGL-C and SGL-W. The cultures were maintained in a 5% $CO_2$ incubator at 35 °C and the infection index was evaluated 24 h after the interaction. The infection index (percentage of infected macrophages × average number of amastigotes per macrophage) was determined in the coverslips stained by Giemsa under bright-field illumination using immersion objective lens.

### 2.7. Effect of SGL on in vivo Leishmania-infected mice

#### 2.7.1. Mouse infection

Promastigotes ($1\times10^6$ in 50 μl) with or without SGLs were inoculated subcutaneously into one of the mouse hind footpads, using a total of three experimental groups of mice infected as follows: parasites (P group), SGL-W plus parasites (SGL-W + P group) and SGL-C plus parasites (SGL-C + P group). The control groups were mice inoculated with PBS, SGL-W and SGL-C.

#### 2.7.2. Lesion measurement

The hind-footpad swelling in each infected mouse was monitored weekly by measuring the thickness of infected footpad with a metric caliper and subtracting the thickness of the noninfected, contra-lateral footpad.

#### 2.7.3. Histopathological study

Five mice from each experimental group were euthanized at 3, 24, 72 h, 7 and 60 days postinfection. Hind-footpad fragments were collected and fixed in 10% formaldehyde solution in PBS and routinely processed for paraffin embedding. The sections were stained with hematoxylin-eosin for analysis by light microscopy.

#### 2.7.4. Quantitative morphometric analysis

Morphometric analysis was performed on three different levels of skin section per mouse using an eyepiece graticule in an area of 0.01 $mm^2$ adapted to an Olympus planapochromatic immersion objective lens (100×). Three types of analysis were performed: quantification of cell types, polymorphonuclear (PMN) and mononuclear (MONO), by counting 900 cells, where each cell type constituted of at least 10% of the total, in order to keep the relative standard error below

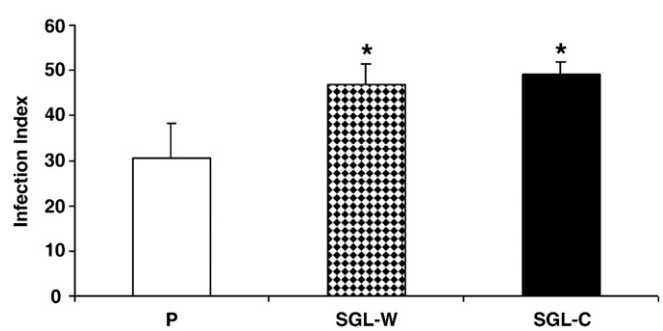


**Fig. 1.** Infection index of macrophages infected with *Leishmania* parasites (P group), SGL-W plus parasites (SGL-W + P group) and SGL-C plus parasites (SGL-C + P group). (*) $p<0.05$ between P and W-SGH + P and C-SGH + P. Data are from one representative experiment performed in triplicate.

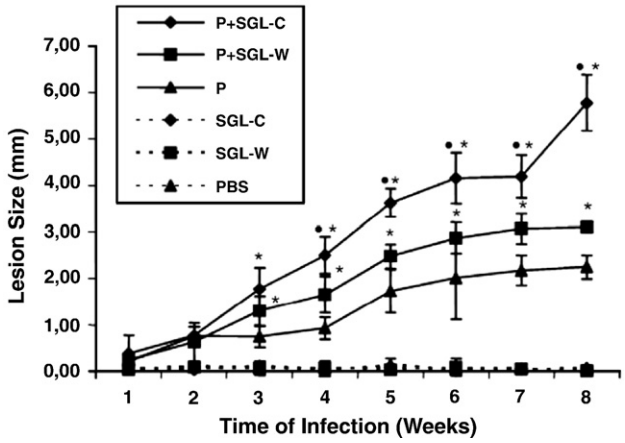


**Fig. 2.** Evolution of lesion size (mm) produced in mouse hind footpads infected with parasites plus lab-colonized (SGL-C + P) and wild-caught (SGL-W + P) salivary gland homogenates and parasites alone (P) and their respective controls (SGL-C, SGL-W and PBS). (*) $p<0.05$ between P and SGL-W + P or SGL-C + P and (•) $p<0.05$ between SGL-W + P and SGL-C + P. Data are from one representative experiment showing the mean and standard deviation of 5 mice per group.

0.1% [23]; quantification of parasitized cells and the infection index (percentage of infected macrophages × average number of amastigotes per macrophage) in the chronic phase of the infection.

### 2.8. Statistical analysis

The SigmaStat 2.0 (1997) computer program was used to analyze each event in block. The difference between the groups was evaluated by the paired *t* test method, considering $p<0.05$ as statistically significant.

## 3. Results

### 3.1. Effect of SGL on ex vivo Leishmania-infected macrophages

The infection index of the macrophages infected with promastigotes together with either SGL-C or SGL-W showed a significant increase when compared to the control group (P), in which the saliva lysates were not added. However, no significant difference was observed between macrophages infected in the presence of SGL-C or SGL-W (Fig. 1).

### 3.2. Effect of SGL on in vivo Leishmania-infected mice

#### 3.2.1. Hind-footpad lesion size evolution

No significant difference in lesion sizes occurred between the experimental infected groups during the first two weeks of infection. However, from week 3 up to week 8, the end of the observational period, lesion sizes progressively increased and differentiated in all

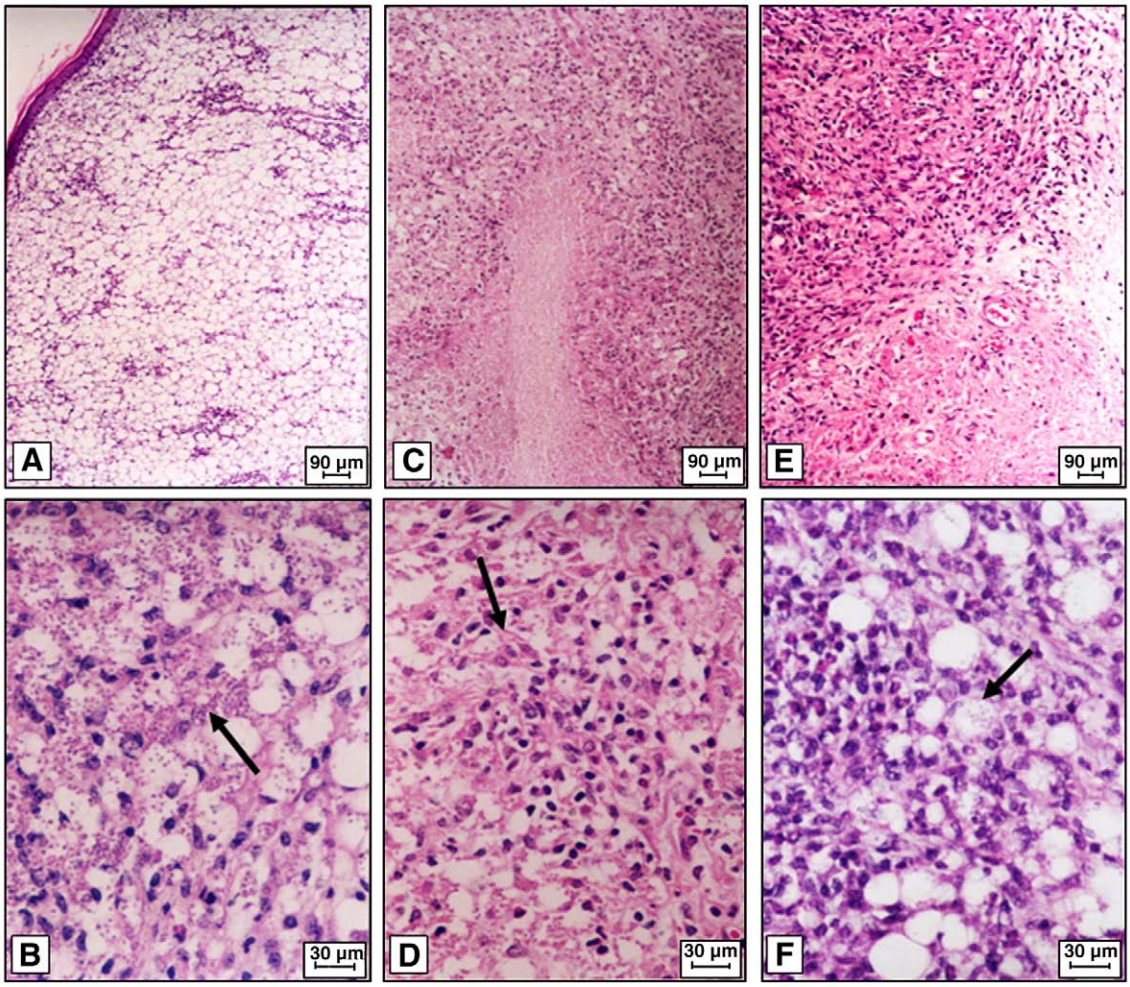


**Fig. 3.** Histological sections of chronic phase infection (day 60 postinfection) in mouse hind footpads infected with parasites plus lab-colonized (SGL-C + P) (A and B) and wild-caught (SGL-W + P) (C and D) salivary gland homogenates and parasites alone (P) (E and F) (HE staining). Large magnification views showing that SGL-C + P (B) is characterized by the presence of heavily parasitized large vacuolated macrophages (arrows), distinct from the SGL-W + P (D) and P (F) groups that show less infected macrophages (arrows), together with nodular macrophages mononuclear infiltrates and focal areas of necrosis (A, C and E).

the infected groups. By week 3, two groups, those inoculated with saliva plus parasites (SGL-W + P and SGL-C + P groups), exhibited large lesion sizes ($p<0.05$) compared with the control group inoculated with only parasites (P group). However, from week 4 onwards, lesion sizes of the infected mice from the SGL-C + P group were larger than those from the SGL-W + P group ($p<0.05$). At the end of experimental observation, mice from the SGL-C + P group presented lesions twice the size of the SGL-W + P group and three times larger than the P group. Mice from the noninfected control groups presented no hind-footpad swellings during the period of this study (Fig. 2).

### 3.2.2. Histopathology of skin lesions

At the onset of infection, the histopathological analysis of the three infected groups showed similar cellular types in the inflammatory infiltrate. The samples collected at 3 and 24 h exhibited intense exudation of PMN leucocytes with moderate presence of parasites. The biopsies examined at 72 h presented MONO and PMN cells in similar ratios, characterizing a mixed infiltrate with few parasites. However, by day 7 of infection, the MONO cells were predominant in the inflammatory sites of all groups, observed in greater numbers in the SGL-C + P group, and showing greater tissue parasitism (data not shown). During the chronic phase of the infection (day 60), the inflammatory infiltrates were characterized mainly by mononuclear cells with intracellular parasites inside the macrophages in all three infected groups (Fig. 3). However, the SGL-C + P group was characterized by the presence of heavily parasitized large vacuolated macrophages, distinct from the SGL-W + P and P groups, which showed fewer infected macrophages, together with nodular mononuclear infiltrates and focal areas of necrosis (Fig. 3). The noninfected control groups exhibited no inflammatory reaction (not shown).

### 3.2.3. Quantitative morphometric analysis

Significant differences occurred in the inflammatory response dynamics between the three experimental infected groups.

At the onset of observation, 3 h after infection, the inflammatory focus of all the infected groups contained large quantities of PMN cells that decreased gradually over time. Comparatively, the SGL-C + P group showed the lowest number of PMN cells at all the periods observed. The inflammatory foci of the SGL-W + P and P groups were similar, except at 24 h, when the former contained a lower number of PMN cells (Fig. 4A). In contrast to PMN cells, the inflammatory foci of all the infected groups contained small quantities of MONO cells that gradually increased according to the time of infection (Fig. 4B). Typically, the SGL-C + P group showed the greatest number of MONO cells at all the observation periods. Considering the two other groups, the SGL-W + P group presented with lower numbers of MONO cells than the P group, but only for the periods 24 and 72 h. In all infected groups, the inflammatory infiltrates contained infected PMN and MONO cells. The kinetics of PMN infection was similar between the groups, except at 3 h, when the SGL-C + P exhibited the lowest number (Fig. 4C). Significantly, the SGL-C + P group contained the greatest number of MONO cells with intracellular parasites, which increased over time (Fig. 4D). By the chronic phase, day 60 of the infection, few PMN cells and large quantities of MONO cells were observed in the inflammatory focus in all the infected groups. The highest number of cells, for PMN or MONO, was observed in infected

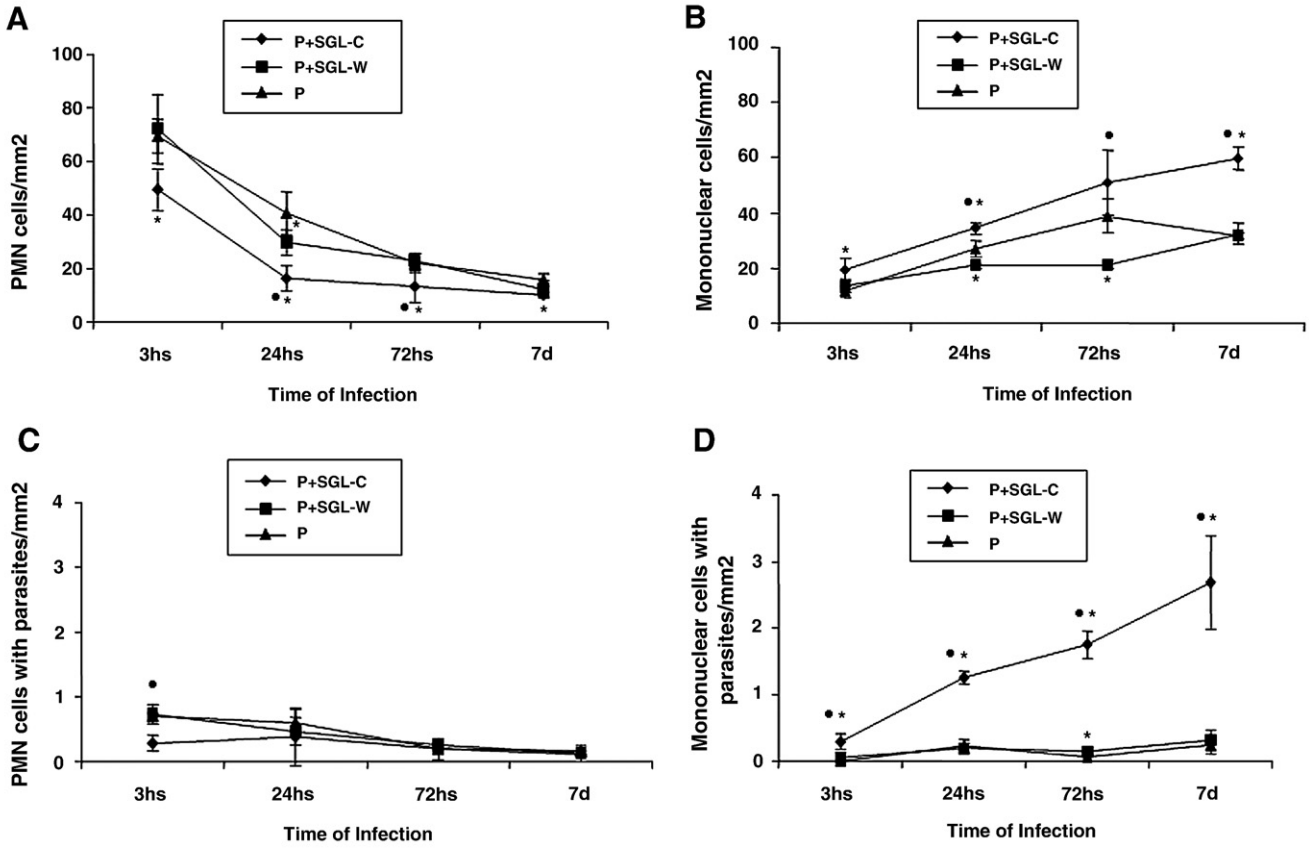


**Fig. 4.** Morphometric quantitative analysis of the acute inflammatory reaction produced in mouse hind footpads infected with parasite (P) alone and with wild-caught (SGL-W + P) and lab-colonized (SGL-C + P) *L. longipalpis* salivary gland lysate, showing the number of polymorphonuclear cells (A), mononuclear cells (B), infected polymorphonuclear cells containing intracellular parasites (C) and infected mononuclear cells (D) per area of 1 $mm^2$. (*) $p<0.05$ between P and SGL-W + P or SGL-C + P and (•) $p<0.05$ between SGL-W + P and SGL-C + P. Data are from one representative experiment showing the mean and standard deviation of 5 mice per group.

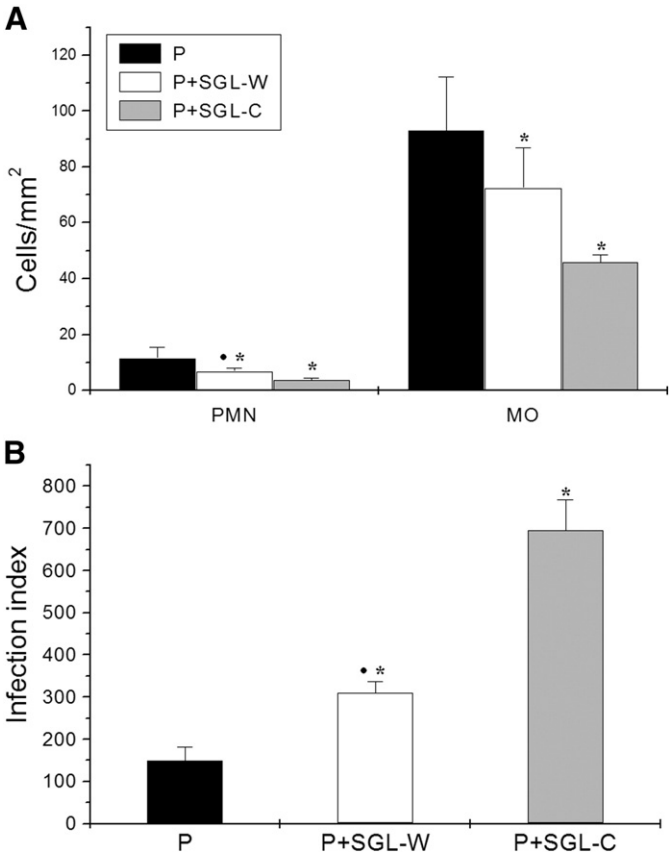


**Fig. 5.** Morphometric quantitative analysis of the chronic inflammatory reaction produced in mouse hind footpads infected with parasite (P) alone and with wild-caught (SGL-W + P) and lab-colonized (SGL-C + P) *L. longipalpis* salivary gland lysate at day 60 postinfection, showing the number of polymorphonuclear cells (PMN) and mononuclear cells (MONO) per area of 1 $mm^2$ (A); and the infection index of mononuclear cells in cutaneous lesions of mice infected with parasite (P) alone and with parasite plus wild-caught (SGL-W + P) and lab-colonized (SGL-C + P) *L. longopalpis* salivary gland (B). (*) $p<0.05$ between P and SGL-W + P or SGL-C + P and (•) $p<0.05$ between SGL-W + P and SGL-C + P. Data are from one representative experiment showing the mean and standard deviation of 5 mice per group.

mice from the P group, followed by SGL-W + P and SGL-C + P (Fig. 5A). However, the infection index, which reflects the percentage of infected macrophage and the number of parasites present in the lesions, was higher in SGL-C + P than in SGL-W + P and both these groups presented a higher index than mice inoculated with parasites alone (Fig. 5B). The control groups were not analyzed since they showed no histopathological changes.

### 3.3. Protein analysis profile of the SGLs

The SDS-PAGE silver stained gel of SGL-C and SGL-W showed differences in the composition and quantity of protein bands, as determined by densitometry with the Eagle eye system (Fig. 6). Even so proteins below 24 kDa had not been observed neither in SGL-C nor SGL-W, SGL-C showed a higher number of protein bands between 27 kDa and 36 kDa that were not expressed in SGL-W. The 99 kDa protein band was over expressed in SGL-C and the 32 kDa protein band was the only one expressed in large quantities by SGL-W when comparing the two saliva homogenates.

## 4. Discussion

All published reports concerning the effects of vector saliva exacerbation or protection against *Leishmania* infection have been developed using saliva from lab-colonized vectors. In fact, these studies, developed with either *Lutzomyia* or *Phlebotomus* sandfly vectors, from the New or Old World, respectively, demonstrated that the saliva from these two sandfly genera presents immunomodulatory effects against the host immune response, thus causing exacerbation of the infection [10,12,24–26]. However, the present study, using a methodology similar to described by other authors while testing and comparing the effects of saliva lysates from lab-reared and wild-caught sandflies, showed significant differences in the exacerbation effect.

In this study, mice were coinoculated with salivary gland lysate (SGL) of *L. longipalpis*. Although unnatural, the sandfly–*Leishmania* combination used has long been accepted for such studies [8,24], since it is hard and laborious to rear *L. flaviscutellata*, the natural vector for the parasite. Moreover, the main aim of this study was to compare wild-caught and laboratory-colonized sandflies using the same protocol and the same saliva source, from *L. longipalpis*, as used in other studies. It is known that *L. longipalpis* is a natural vector of *L. (L.) chagasi*, which causes visceral leishmaniasis, a different pathology than that seen in *L. (L.) amazonensis* infection; and the lack of studies involving this vector–parasite pair shows that the role of the saliva still requires improvement in the visceral leishmaniasis model. The present results demonstrated that *L. longipalpis* saliva from either SGL-W or SGL-C similarly exacerbated the lesion sizes of infected mice during the onset of infection, up to week three of infection. However, the experiments revealed that after week four, the exacerbation effect progressed distinctly in mice coinoculated with SGL-C. At the end of the observational period, week eight, the infected mice presented lesion sizes twice those of mice coinoculated with SGL-W and three times larger compared with mice only infected with parasites without added saliva. These data clearly indicated that the saliva collected from lab-colonized sandflies presents a much stronger exacerbation effect in *Leishmania*-infected mice than the saliva obtained from wild-caught sandflies.

Histopathology and quantitative morphometric analysis also showed differences in the dynamics of the inflammatory process in the cutaneous lesions between *Leishmania* mice coinoculated with SGL-W or SGL-C. It is well known that during the first few hours after *Leishmania* inoculation a leukocyte afflux occurs, with a predominance of PMN cells, mainly neutrophils, in several distinct models. However, once the infection is established, MONO cells move *en masse* to the infected areas and neutrophil inflammation diminishes gradually [27]. This fact results in established mononuclear infiltrates in the skin lesions by day 7 after parasite inoculation [23]. The presence of MONO cells assists in establishing the infection as they are the host cells for the development of *Leishmania* [28,29], distinct from PMN cells, which can kill the parasites by an effective oxidative burst killing mechanism [27,30].

As previously described by other authors [8], inflammatory dynamics were modified by the inclusion of saliva (SGL-C) in the initial inoculum, showing fewer PMN cells and greater numbers of MONO cells in the lesions compared to infected mice only inoculated with parasites without saliva. The immunomodulatory effects of saliva are well documented [31]. Clearly, saliva from lab-colonized *L. longipalpis* and *P. papatasi* sandflies possesses chemotactic factors for macrophages resulting in increased parasite uptake by the cells [13,14]. Moreover, sandfly saliva has the capacity to inhibit the presentation of parasite antigens by macrophages to specific T lymphocytes [12] and facilitates the parasite evasion of the host immune response system by modulating IL-10 production [8].

In contrast to previous works, the present results suggest that saliva from wild-caught sandflies does not possess the chemotactic factors verified in the saliva from lab-colonized sandflies, since the number of MONO cells in lesions was similar to the mice inoculated with parasites without saliva during the acute phase of the infection. Moreover, in the chronic phase, the lab-colonized saliva resulted in the presence of heavily parasitized large vacuolated macrophages, distinct from the wild-caught saliva, which induced nodular mononuclear infiltrates

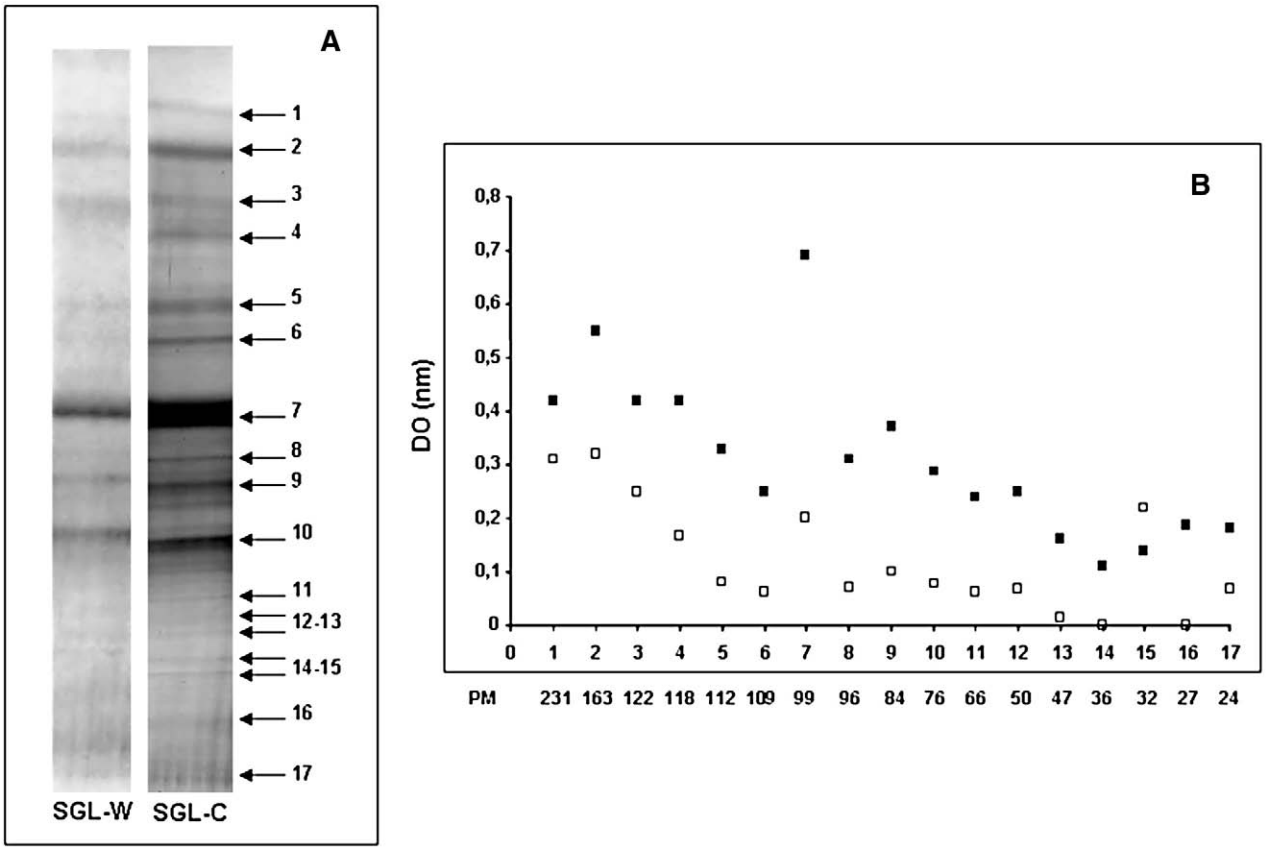


**Fig. 6.** Silver staining of SDS-PAGE gels (A) of *L. longipalpis* SGLs and comparative densitometry analysis of band intensities (B), where an open square represents SGL-W and a closed square represents SGL-C. 10 µg of total protein was applied to each line and after electrophoresis and staining, the visible bands were measured by densitometry using the Eagle Eye gel documentation system (Stratagene, USA). A greater number of protein bands showing overexpression of the 99 kDa protein band can be observed in SGL-C. The 27 kDa and 36 kDa bands are not expressed in SGL-W and the 32 kDa protein band is the only one expressed in large quantities. Data are representative of three separate experiments with similar results.

and focal areas of necrosis together with parasitized macrophages. These data indicate that SGL-C possesses macrophage chemotactic factors not observed in SGL-W. Indeed the composition and quantities of proteins between SGL-C and SGL-W are substantially different.

According to these results, it is possible to speculate that the marked lesion enhancement caused by sandfly saliva is not as dramatic under natural conditions, since the infection is transmitted by wild and not by laboratory-colonized vectors. It is also important to mention that an important role of sandfly saliva has been attributed to the protection of individuals living in endemic area of leishmaniasis and constantly exposed to sandfly bites, since they develop humoral immunity against the saliva [16]. Experimental evidence also indicates that preexposure to sandfly saliva leads to resistance [10,19] or delayed lesion development.

## Acknowledgments

Mary Ann McDowell, Assistant Professor of the Department of Biological Science, University of Notre Dame, Notre Dame, IN, USA for the critical revision, which certainly, improved the final format of the manuscript. This project was supported by the FAPESP, TDR-WHO and LIM50 HC-FMUSP. This study was a part of M.D. Laurenti's Post-Doctorate Program supervised by P.F.P. Pimenta.

## References

[1] Sacks DL, Perkins PV. Development of infective stage *Leishmania* promastigotes within phlebotomine sand flies. Am J Trop Med Hyg 1985;34:456–9.
[2] Ribeiro JMC. Role of saliva in blood-feeding arthropods. Annu Rev Entomol 1987;32:463–78.
[3] Titus RG, Ribeiro JMC. Salivary gland lysates from the sandfly *Lutzomyia longipalpis* enhance *Leishmania* infectivity. Science 1988;239:1306–8.
[4] Titus RG, Bishop JV, Mejia JS. The immunomodulatory factors of arthropod saliva and the potential for these factors to serve as vaccine targets to prevent pathogen transmission. Rev Parasite Immunol 2006;28:131–41.
[5] Kamhawi S. The biological and immunomodulatory properties of sand fly saliva and its role in the establishment of *Leishmania* infections. Microbes Infect 2000;2:1765–77.
[6] Andrade BB, de Oliveira CI, Brodskyn CI, Barral A, Barral-Netto M. Role of sand fly saliva in human and experimental leishmaniasis: current insights. Rev Scand J Immunol 2007;66:122–7.
[7] Donnelly KB, Lima CL, Titus RG. Histologic characterization of experimental cutaneous leishmaniasis in mice infected with *Leishmania brasiliensis* in the presence or absence of sandfly vector salivary gland lysate. J Parasitol 1998;84:97–103.
[8] Norsworthy NB, Sun J, Elmaiem D, Lanzaro G, Soong L. Sand fly saliva enhances *Leishmania amazonensis* infection by modulating interleukin-10 production. Infect Immun 2004;72:1240–7.
[9] Rogers ME, Ilg T, Nokolaev AV, Ferguson NA, Bates PA. Transmission of cutaneous leishmaniasis by sand flies is enhanced by regurgitation of fPPG. Nature 2004;430:463–7.
[10] Belkaid Y, Kamhawi S, Modi G, Valenzuela J, Noben-Trauth N, Rowton E, et al. Development of a natural model of cutaneous leishmaniasis: powerful effects of a vector saliva and saliva preexposure on the long-term outcome of *Leishmania major* infection in the mouse ear dermis. J Exp Med 1998;188:1941–53.
[11] Mbow ML, Bleyendenberg JA, Hall LR, Titus RG. *Phlebotomus papatasi* sand fly salivary gland lysate down-regulates a Th1, but up-regulates a Th2, response in mice infected with *Leishmania major*. J Immunol 1998;161:5571–7.
[12] Theodos CM, Titus RG. Salivary gland material from the sand fly *Lutzomyia longipalpis* has an inhibitory effect on macrophage function *in vitro*. Parasite Immunol 1993;15:481–7.
[13] Anjili CO, Mbati PA, Mwangi RW, Githure JI, Olobo JO, Robert LL, et al. The chemotactic effect of *Phlebotomus duboscqi* (Diptera: Psychodidae) salivary gland lysates to murine monocytes. Acta Trop 1995;60:97–100.
[14] Zer R, Yaroslavski I, Rosen L, Warburg A. Effect of sand fly saliva *Leishmania* uptake by murine macrophages. Int J Parasitol 2001;31:810–4.
[15] Kamhawi S, Belkaid Y, Modi G, Rowton E, Sacks D. Protection against cutaneous leishmaniasis resulting from bites of uninfected sand flies. Science 2000;290:1351–4.
[16] Barral A, Honda E, Caldas A, Costa J, Vinhas V, Rowton ED, et al. Human immune response to sand fly salivary gland antigens: a useful epidemiological marker? Am J Trop Med Hyg 2000;62:740–5.

[17] Moura TR, Oliveira F, Novais FO, Miranda JC, Clarêncio J, Follador I, et al. Enhanced *Leishmania braziliensis* infection following pre-exposure to sandfly saliva. PLoS Negl Trop Dis 2007;1:e84.
[18] Vinhas V, Andrade BB, Paes F, Bomura A, Clarencio J, Miranda JC, et al. Human anti-saliva immune response following experimental exposure to the visceral leishmaniasis vector *Lutzomyia longipalpis*. Eur J Immunol 2007;37:3111–21.
[19] Valenzuela JG, Belkaid Y, Garfield MK, Mendez S, Kamhawi S, Rowton ED, et al. Toward a defined anti-*Leishmania* vaccine targeting vector antigens: characterization of a protective salivary protein. J Exp Med 2001;194:331–42.
[20] Requena JM, Iborra S, Carrion J, Alonso C, Soto M. Recent advances in vaccines for leishmaniasis. Expert Opin Biol Ther 2004;4:1505–17.
[21] Brodskyn C, de Oliveira CI, Barral A, Barral–Netto M. Vaccines in leishmaniasis: advances in the last five years. Expert Rev Vaccines 2007;2:705–17.
[22] Killick-Kendrick RA, Leaney J, Ready PD. A laboratory culture of *Lutzomyia longipalpis*. Trans R Soc Trop Med Hyg 1973;67:434.
[23] Laurenti MD, Corbett CEP, Sotto MN, Sinhorini IL, Goto H. The role of complement in the acute inflammatory process in the skin and in host–parasite interaction in hamsters inoculated with *Leishmania (Leishmania) chagasi*. Int J Exp Pathol 1996;77:15–24.
[24] Theodos CM, Povinelli L, Molina R, Sherry B, Titus RG. Role of tumor necrosis factor in macrophage leishmanicidal activity *in vitro* and resistance of cutaneous leishmaniasis *in vivo*. Infect Immun 1991;59:2839–42.
[25] Bezerra HS, Teixeira MJ. Effect of *Lutzomyia whitmani* (Díptera: Psychodidae) salivary gland lysates on *Leishmania (Viannia) braziliensis* infection in BALB/c mice. Mem Inst Oswaldo Cruz Rio de Janeiro 2001;96:349–51.
[26] Sacks D, Kamhawi S. Molecular aspects of parasite–vector and vector–host interactions in leishmaniasis. Annu Rev Microbiol 2001;55:453–83.
[27] Almeida MC, Vilhena V, Barral B, Barral-Neto M. Leishmanial infection: analysis of its first steps: a review. Mem Inst Oswaldo Cruz Rio de Janeiro 2003;98:61–870.
[28] Solback W, Bogdan C, Moll H, Lohoff M, Rollinghoff M. Parasitic evasion mechanisms: *Leishmania* as an example. Immun Infekt 1989;17:129–40.
[29] Ritting MG, Bogdan C. *Leishmania*–host–cell interaction: complexities and alternatives views. Parasitol Today 2000;16:292–7.
[30] Chang KP. Antibody-mediated inhibition of phagocytosis in *Leishmania donovani*–human phagocyte interactions *in vitro*. Am J Trop Med Hyg 1981;30:334–9.
[31] Qureshi AA, Asahina A, Ohnuma M, Tajima M, Granstein RD, Lerner EA. Immunomodulatory properties of maxadilan, the vasodilator peptide from sand fly salivary gland extracts. Am J Trop Med Hyg 1996;54:665–71.

**ANEXO-21**

---

Effects of salivary gland homogenates forma wild-caught and laboratory-reared Lutzomyia longipalpis on the evolution and immunomodulation of *Leishmania (Leishmania) amazonensis* infection

**Laurenti, M.D.;** da Matta, V.L.R.; Pernichelli, T.; Secundino, N.C.F.; Pinto, L.C.; Corbett, C.E.P.; Pimenta, P.P.F.

Scandinavian Journal of Immunology 2009; 70: 389-395

doi: 10.1111/j.1365-3083.2009.02310.x

# Effects of Salivary Gland Homogenate from Wild-Caught and Laboratory-Reared *Lutzomyia longipalpis* on the Evolution and Immunomodulation of *Leishmania (Leishmania) amazonensis* Infection

M. D. Laurenti*, V. L. R. da Matta*, T. Pernichelli*, N. F. C. Secundino†, L. C. Pinto†, C. E. P. Corbett* & P. P. F. Pimenta†

*Laboratory of Pathology of Infectious Diseases (LIM-50), Department of Pathology, Medical School, University of São Paulo, São Paulo (SP), Brazil; and †Laboratory of Medical Entomology, Instituto de Pesquisas René Rachou, Fundação Oswaldo Cruz – FIOCRUZ, Belo Horizonte (MG), Brazil

*Received 26 May 2009; Accepted in revised form 11 August 2009*

*Correspondence to*: M. D. Laurenti, Faculdade de Medicina da USP, Depto. Patologia, Av. Dr. Arnaldo, 455 – 1º andar – sala 1152, CEP: 01246-903, Cerqueira César, São Paulo (SP), Brazil.
E-mail: mdlauren@usp.br

## Abstract

We investigated the effects of *Lutzomyia longipalpis* salivary glands homogenate of wild-caught and laboratory-reared vectors on the lesion evolution and immunomodulation of the infection caused by *Leishmania* (*Leishmania*) *amazonensis*. To compare the effect of both salivary glands homogenate (SGH), C57BL/6 mice were inoculated subcutaneously into the hind footpads or into the ear dermis with $10^6$ promastigotes in the presence or not of SGH from wild-caught and laboratory-colonized sand flies. Comparing SGH groups, the lesion size was lower in mice co-inoculated with wild-caught SGH, as the parasitism and the infiltration of macrophages at the inoculation site. Wild-caught SGH also determined lower production of IL-4 and IL-10 but higher IL-12 levels compared with laboratory-reared SGH. Our findings address a probable bias by using SGH from laboratory-colonized sand flies instead of wild-caught vector SGH in studies concerning saliva effects. A possible mild influence of sand fly saliva in natural infections caused by *Leishmania* is also speculated, as infection is transmitted by wild and not by laboratory-reared vectors.

## Introduction

Leishmaniases represent a group of diseases that affect millions of people in vast areas of the world. The infection is acquired by infected phlebotomine sand fly bites and can result in a wide spectrum of clinical manifestations, depending on the involved parasite species and the host immune status [1]. During the natural transmission, *Leishmania* promastigotes are injected into the host's skin together with the vector saliva [2], which is a potent pharmacologically active fluid that directly affects the haemostatic, inflammatory and immune response of vertebrate hosts [3].

In experimental models, when vector's salivary gland lysates are mixed with *Leishmania* sp., the resulting cutaneous lesions are significantly larger than those seen in mice inoculated only with the parasite [4–6]. Different mechanisms can contribute to this phenomenon, including inhibition of T-cell proliferation, reduction in nitric oxide production by infected macrophages, and enhancement of cytokines associated with susceptibility [5, 7, 8]. On the other hand, mice pre-immunized with whole saliva or its components develop both intense humoral and delayed-type hypersensitivity reactions that control *Leishmania* infection when the animals are further challenged with the parasite plus saliva [9]

Most of the studies on the saliva effects are performed with *L. major*, and some with *Phlebotomus* sp. glands [4, 10], parasite species and sand fly genus that are found only in the Old World. In Central and South America, the phlebotomines belong to the genus *Lutzomyia*. Respective of the New World, salivary glands of *Lutzomyia longipalpis* is the most studied in infections caused by a number of *Leishmania* species, including *L.* (*L.*) *amazonensis* [5, 6, 11], an important causative agent of a broad spectrum of cutaneous manifestations in the Americas [12].




SCANDINAVIAN JOURNAL OF Immunology AN INTERNATIONAL MONTHLY JOURNAL

As far as we know, all preceding studies respecting saliva effects made use of laboratory-reared sand fly saliva and not from phlebotomines just captured in the field, except for our recently report that showed a weaker effect on lesion size by salivary glands of wild-caught *Lu. longipalpis* and different expression and amount of proteins in relation to those from laboratory-colonized vectors [13].

In the present study, we compared the influence of wild-caught and laboratory-colonized *Lu. longipalpis* salivary gland homogenate (SGH) on the lesion evolution and host immune response of C57BL/6 mice infected with *Leishmania* (*L.*) *amazonensis*.

## Material and methods

*Mice.* Female of C57BL/6 aged 6 to 8 weeks from the General Colony of São Paulo University Medical School were kept in our laboratory during the experiments according to the methods approved by the Animal Care and Use Committee of Medical School.

*Parasites. Leishmania* (*Leishmania*) *amazonensis*, MHOM/BR/73/M2269 strain, recently isolated from chronically infected BALB/*c* mice were cultivated as promastigotes in supplemented RPMI 1640 medium (10% fetal calf serum, 5mM HEPES, 50$\mu$g/ml gentamicin and 100 U/ml penicilin). Stationary-phase promastigotes were harvested and washed three times in sterile phosphate buffered saline, pH 7.2 (PBS) to prepare the inoculum.

*Sand flies and salivary gland homogenate.* Wild-caught (W) and laboratory-colonized (C) *Lu. longipalpis* sand flies were used. The wild-caught sand flies were collected in Lapinha Cave located at Minas Gerais State, Brazil, over a period of 3 days, although those caught in the first collection were not used in order to work with newly released sand flies of similar age. They were maintained in the insectary for 2 days until the time of the experiments. The colony started from sand flies collected in the same place and they were reared at least for 10 generations in the insectary of the Laboratory of Medical Entomology at Institute René Rachou (FIOCRUZ-MG), according to the conditions described by Killick-Kendrick *et al.* [14]. Three- to five-day-old females from the colony were used and they were considered of similar age to the wild-caught sand flies. All the flies received 5% sugar solution *ad libitum* until the time of the experiments. The wild-caught sand flies were checked for the absence of blood meal and egg development to confirm that they had no previous blood intake before salivary gland collection. Both salivary glands were collected in cold PBS and stored at −70 °C. At the time of the experiments, they were disrupted by freeze-thawed, vortexed and quickly centrifuged to discharge possible tissues. Half pair of salivary gland, for both wild-caught and labarotory-colonized sand flies was used for each inoculation point.

*Mice infection:* Stationary promastigotes ($1 \times 10^6$ in 50 $\mu$l) without or with SGH were inoculated subcutaneously into the mouse hind footpads totalizing three experimental groups of 10 mice each infected with: (1) parasites (P group), (2) parasites plus wild-caught-SGH (P+W-SGH group) and (3) parasites plus colonized-SGH (P+C-SGH group) to evaluate the lesion size and the cytokine profile in draining lymph nodes. Another group of animals were inoculated with the same inoculum ($1 \times 10^6$ in 20 $\mu$l) without or with SGH into the ear dermis composing the same three experimental groups to numbering and typing the cells involved in the inflammatory reaction at the inoculation site.

*Lesion size:* The evolution of the lesion size in each experimental group was determined at each 15 days up to 60 days post-infection by measuring the thickness of infected footpads minus the non-infected footpads using a metric calliper.

*Parasitism:* The number of parasites was determined at 60 days post-infection by morphometric analysis, using a microscope with immersion objective lens (100×) and a graticule eyepiece of 0.01 $mm^2$ area. Three different levels of a paraffin-embedded biopsy from the hind footpad inoculation site stained with haematoxylin–eosin were considered.

*Analysis of the inflammatory dermal site:* The cells in the inflammatory ear dermis were recovered as described by Belkaid *et al.* [15]. Briefly, at 1, 7 and 60 days after intradermal inoculation, the ears of different groups of animals were collected, rinsed in 70% ethanol with shaking, and allowed to dry at room temperature. Using a pair of fine forceps, the ventral and dorsal dermal sheets were separated and immediately transferred (dermal side down) to 2 ml of supplemented RPMI 1640 medium into polypropylene flasks that were incubated at 37 °C, 5% $CO_2$ for 6 h. After, all the cells of each experimental group were pooled and filtered through a 70-$\mu$m nylon cells strainer and washed twice in PBS to determine the cell population by light microscopy and flow cytometry.

*Immunolabelling and flow cytometry:* Each labelling was carried out with $10^5$ cells for 30 min at room temperature in a 100-$\mu$l volume. The dermal cells were incubated with 10% normal mouse serum in PBS containing 0.1% BSA and 0.01% $NaN_3$ and the inflammatory cells were identified by one-colour analysis in total cellular population. The neutrophils were identified by FITC anti-Ly-6G (RB6-8C5; Pharmingen, San Diego, CA, USA), mononuclear phagocytes by PE anti-F4/80 (A3-1; Serotec, Oxford, UK) and T cells by FITC anti-CD3e (CD3 chain; Pharmingen), PerCP anti-CD4 (L3T4; Pharmingen) and PerCP anti-CD8a (Ly-2; Pharmingen) antibodies. The isotype controls were rat IgG2a and IgG2b (Pharmingen). After staining, the cells were fixed with 1% paraformaldehyde. For each sample, $10^3$ cells were analysed (Facs Scalibur – CellQuest software). Each sample was cytospun in parallel and stained with Giemsa solution and the percentage of polymorphonuclear and

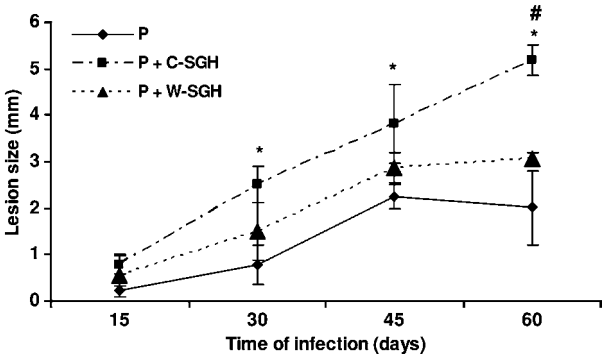


**Figure 1** Evolution of the lesion size of C57BL/6 mice infected with $10^6$ promastigotes of *Leishmania* (*Leishmania*) *amazonensis* without (P group) and with salivary gland homogenate from laboratory-colonized (P+C-SGH group) and wild-caught (P+W-SGH group) *Lutzomyia longipalpis* (*$P < 0.05$ between P and P+C-SGH or between P and P+W-SGH groups, and #$P < 0.05$ between P+C-SGH and P+W-SGH groups). The data are representative of two independent experiments with similar results.

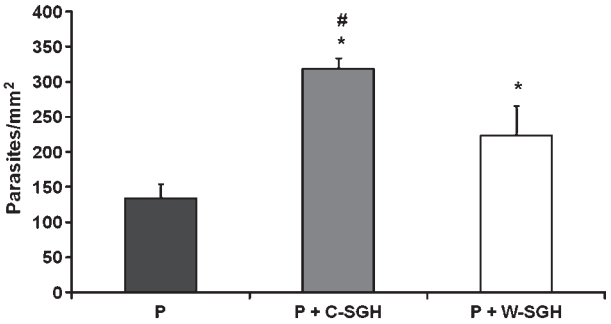


**Figure 2** Number of parasites/mm$^2$ at 60 days post-infection of the inoculation site of mice infected with *Leishmania* (*Leishmania*) *amazonensis* without (P group) and with salivary gland homogenate from laboratory-colonized (P+C-SGH group) and wild-caught (P+W-SGH group) *Lutzomyia longipalpis* (*$P < 0.05$ between P and P+C-SGH or between P and P+W-SGH groups; and #$P < 0.05$ between P+C-SGH and P+W-SGH groups). The data are representative of two independent experiments with similar results.

mononuclear cells were estimated by light microscope examination.

*Lymphocytes culture and cytokine assays:* For measurement of cytokine production, popliteal lymph nodes draining the infected footpads were aseptically dissociated into a single cell suspension at 1, 7 and 60 days post-infection. The pooled cells of each experimental group were adjusted to $5 \times 10^6$cells/ml in supplemented RPMI 1640, and 100 $\mu$l/well was dispensed into 96-well plate with soluble *L.* (*L.*) *amazonensis* antigen (1 $\mu$g/well). Cultures were incubated at 37 °C in 5% $CO_2$. Supernatant was harvested at 48 h and assayed for IL-2, IL-4, IL-10, IL-12 and IFN-$\gamma$ in triplicates by enzyme-linked immunosorbent assay (ELISA) using commercial kits (BD Biosciences, San Diego, CA, USA).

*Statistical analysis.* Analyses of variance (ANOVA) with two factors (group and time) were performed to evaluate at each time point of infection whether there were differences in the average value of lesion sizes (Fig. 1) or cytokine levels (Table 2) among groups. To determine which means among the set of means differ from the rest, Tukey multiple comparison test was performed. ANOVA was also used to verify differences in the average value of parasites/mm$^2$ among experimental groups (Fig. 2). Bonferroni multiple comparison test was applied to determine which mean was different from the rest. Significant differences were considered for $P < 0.05$.

## Results

### Evolution of the lesion size

The hind footpad lesions were significantly bigger in P+C-SGH than P group from day 30 onward and in relation to P+W-SGH only at 60th day of infection ($P < 0.05$). In opposition, no significant differences were observed in lesion sizes between P+W-SGH and control group (Fig. 1). The evolution of lesions was similar when the animals were infected in the ear dermis (data not shown).

### Parasitism

The number of parasites in the hind footpad lesion at the chronic phase of the infection (60 days) was higher ($P < 0.05$) in SGH groups compared with controls. Between them, P+C-SGH animals showed greater parasitism ($P < 0.05$) (Fig. 2).

### Cells recovered from the ear lesion

At the first day of infection, a higher number of cells was recovered from the dermis tissue of the ear lesion from the animals infected with parasites in the presence of saliva. At 7 days of infection, the number of dermal cells decreased in all groups. At 60th day, the inflammatory cells enhanced pronouncedly and higher number in the dermis tissue were found in the animals co-inoculated with C-SGH compared with the other groups (Table 1).

### Flow cytometry

To characterize the cells recovered from the lesion, they were immunolabeled and analysed by flow cytometry. At the first day of infection, neutrophils were the cells found in higher amount in the infiltrate, especially in P and P+W-SGH. At this time, expressive percentage of macrophages (around 40%) could be observed in P+C-SGH. Low percentage of lymphocytes was present in all groups without difference among them (Fig. 3A). At 7 days of infection, the percentage of neutrophils decreased and

**Table 1** Number of cells recovered from the dermis tissue of the ear inoculation site of C57BL/6 mice infected with promastigotes of *Leishmania* (*Leishmania*) *amazonensis* in the absence (P group) and in the presence of salivary gland homogenate from laboratory colonized (P+C-SGH group) and wild caught (P+W-SGH group) by sedimentation in culture medium. The cells were stained with Giemsa solution and examined at light microscopy. The data are representative of two independent experiments with similar results.

| | Groups | | |
|---|---|---|---|
| Time of infection (days) | P | P+C-SGH | P+W-SGH |
| 1 | $17 \times 10^5$ | $28.8 \times 10^5$ | $23.4 \times 10^5$ |
| 7 | $7 \times 10^5$ | $4.2 \times 10^5$ | $3.2 \times 10^5$ |
| 60 | $38.5 \times 10^7$ | $85.5 \times 10^7$ | $44.5 \times 10^7$ |

macrophages increased in the infiltrate of the ear dermis and, once more, the highest number of macrophages was recovered from lesions of mice co-inoculated with C-SGH. At this time, the number of lymphocytes also augmented in the inoculation site, especially in the control group (Fig. 3B). At the chronic phase, macrophages were the main cells recovered from the lesions and the highest percentage was observed in P+C-SGH followed by P+W-SGH. Concerning to T CD4+ cells, the highest percentage was observed in the controls followed by P+W-SGH group. Low amount of CD8+ cells was observed during all the study with no difference among the experimental groups, except at 7th day when mice inoculated only with parasites showed higher number of cells (Fig. 3C).

### Cytokine profiles

The cytokines produced by lymph nodes cells of C57BL/6 mice infected with *L.* (*L.*) *amazonensis* promastigotes without (P group) and with salivary gland homogenate of laboratory-colonized (P+C-SGH group) and wild-caught (P+W-SGH group) *Lu. longipalpis* stimulated *in vitro* with specific antigen are shown in the Table 2. A markedly production of IL-12 was observed in all groups in the early stage of infection when compared with all other cytokines. At this period, both SGH groups produced less IL-12 than controls ($P < 0.05$). INF-$\gamma$ was detected in reasonable amount in all groups only at 60th day of infection. IL-2 and IL-4 levels were persistently low during all the period studied, although higher IL-4 was found in both groups co-inoculated with SGH ($P < 0.05$) at 7th day of infection. The SGH animals produced more IL-10 than the controls ($P < 0.05$) from day 7 onward, and between them, P+C-SGH group showed higher levels than P+W-SGH ($P < 0.05$).

## Discussion

To determine the role of vector's saliva on the evolution of *Leishmania* (*L.*) *amazonensis* infection, C57BL/6 mice were co-inoculated with salivary gland homogenate (SGH) of *Lu. longipalpis*, a permissive vector [16] that can be found naturally infected with *L. amazonensis* in endemic areas of mixed cutaneous and visceral leishmaniasis [17]. Also, the used sand fly–*Leishmania* combination has long been accepted for such studies [5, 6], since it is hard and laborious to rear *Lu. flaviscutellata*, the natural vector for the parasite.

Besides the investigation of the SGH from laboratory-colonized sand flies on the infection evolution, we also tested the SGH of wild-caught vectors, a rational approach to get a closer scenario of the natural transmission, as infection is transmitted by wild and not by laboratory-colonized flies. In fact, except for a recent study of our group [13], all the reports concerning the saliva effects on the exacerbation or protection against *Leishmania* sp. infection have been developed using SGH or saliva from laboratory-reared vectors, probably due to

**Table 2** Cytokines concentration in the supernatant of cultured draining lymph nodes cellular suspensions of C57BL/6 mice infected with $10^6$ promastigotes of *Leishmania* (*Leishmania*) *amazonensis* without (P group) and with salivary gland homogenate from laboratory-colonized (P+C-SGH group) and wild-caught (P+W-SGH group) *Lutzomyia longipalpis* (*$P < 0.05$ between P and P+C-SGH or between P and P+W-SGH groups, and †$P < 0.05$ between P+C-SGH and P+W-SGH groups). The average and standard deviation (SD) of cytokines were obtained from triplicates of the same experiment. The data are representative of two independent experiments with similar results.

| | | Cytokines pg/ml (SD) | | | | |
|---|---|---|---|---|---|---|
| Time of infection | Experimental groups | IL-4 | IL-10 | IL-12 | IFN-$\gamma$ | IL-2 |
| 1 day | Parasite (P) | 14.1 (0.6) | 46.5 (3.6) | 1088.3 (59.0) | 3.3 (0.3) | 3.4 (0.1) |
| | P+ C-SGH | 8.0 (0.8)* | 28.5 (4.9)* | 359.5 (2.6)* | 3.0 (0.7) | 4.8 (0.2)* |
| | P+W-SGH | 9.1 (0.3)* | 40.6 (5.1)† | 429.9 (75.0)* | 3.7 (0.7) | 6.0 (0.2)*† |
| 7 days | Parasite (P) | 14.6 (0.1) | 42.1 (16.5) | 1902.3 (71.7) | 5.3 (0.3) | 10.6 (4.5) |
| | P+ C-SGH | 34.5 (0.1)* | 117 (3.1)* | 140.1 (24.0)* | 5.4 (0.5) | 8.3 (2.1) |
| | P+W-SGH | 37.1 (2.2)*† | 88.9 (20.0)* | 874.0 (41.0)*† | 6.2 (0.6) | 8.3 (0.1) |
| 60 days | Parasite (P) | 12.0 (2.1) | 493.0 (1.6) | 271.5 (4.0) | 364.7 (7.9) | 34.4 (12.5) |
| | P+ C-SGH | 40.1 (17.2)* | 967.0 (14.5)* | 161.7 (56.7)* | 355.8 (2.7) | 27.0 (3.0) |
| | P+W-SGH | 23.4 (10.1) | 593.0 (1.4)*† | 219.0 (15.5) | 353.1 (14.1) | 25.0 (1.7) |

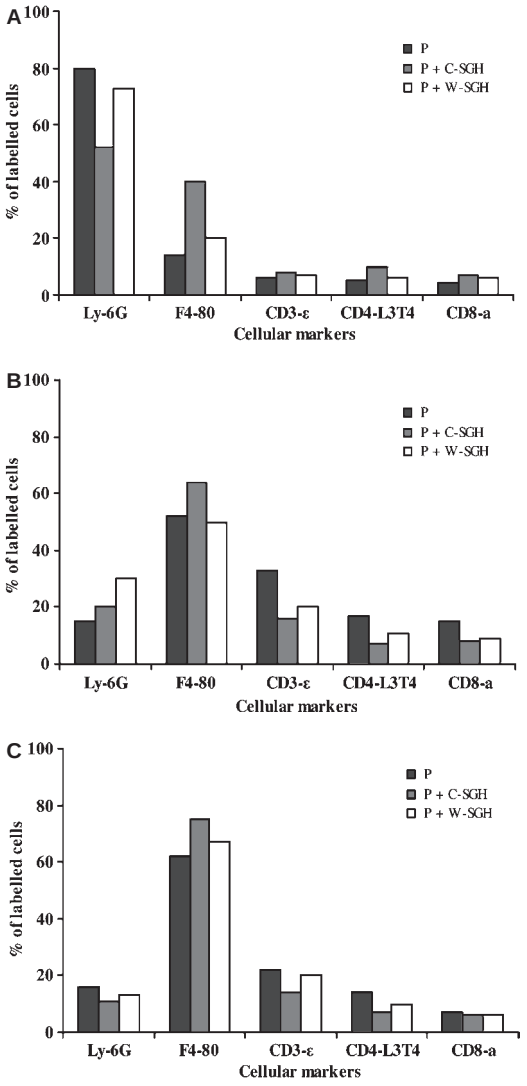


**Figure 3** Percentage of inflammatory cells labelled by different monoclonal antibodies recovered from de ear of C57BL/6 mice infected with $10^6$ promastigotes of *Leishmania* (*Leishmania*) *amazonensis* without (P group) and with salivary gland homogenate from laboratory-colonized (P+C-SGH group) and wild-caught (P+W-SGH group) *Lutzomyia longipalpis*, at 1 (A), 7 (B) and 60 (C) days post-infection. The data are representative of two independent experiments with similar results.

the complexity of working with vectors just captured in the field.

This present study has indicated that *Lu. longipalpis* SGH from wild-caught sand flies can enhance the lesions caused by *L.* (*L.*) *amazonensis* in C57BL/6 mice but in a lesser extension compared with those determined by SGH from laboratory-colonized vectors and closer to those observed in the animals inoculated only with parasites (Fig. 1).

The recruitment of inflammatory cells could partially account for differences in the observed lesion sizes among the experimental and control groups. At the onset of the infection, the number of recovered inflammatory cells at the inoculation site in the P+C-SGH group was 1.2 times higher than in the P+W-SGH group, and 1.7 times higher than the controls (Table 1). Moreover, the animals inoculated only with parasites showed the highest percentage of neutrophils in the lesions (Fig. 3), cells that are known to have a critical role in the early protective response against *Leishmania*, both as effector cells involved in the killing of the parasites and as significant players influencing the development of a protective Th1 immune response [18]. On the other hand, macrophages were more prominent in the inflammatory infiltrate of SGH animals, particularly in those inoculated with laboratory-colonized SGH, in the acute phase and even in the chronic phase (Fig. 3), probably because *Lu. longipalpis* saliva elicits the recruitment of this cell type [19]. Vector's saliva could also be responsible by the lesion enhancement through other proprieties as it can downregulates the production of potent leishmanicidal molecules in macrophages and their ability to present antigens [7, 20], important events for the establishment of *Leishmania* sp., favouring parasite growth inside host immune cells. In fact, we detected higher parasitism in mice infected in the presence of SGH, especially when co-inoculated with laboratory-colonized SGH (Fig. 2)

*Lu. longipalpis* saliva can also inhibits T proliferative response [8]. Our findings showed that, at 7th and 60th day of infection, T CD3+ and CD4+ cells were detected in a lower percentage in the animals co-inoculated with reared SGH followed by those with wild-caught SGH when compared with controls (Fig. 3). The percentage of T CD8+ was similar among the groups, except at the 7th day of infection when it was slightly higher in the control animals (Fig. 3).

SGH also modulated the production of cytokines and this effect could be clearly seen only after day 7, excepting IL-12 that was regulated sooner. In general, salivary glands fostered an upregulation of IL-4 and IL-10, cytokines associated with susceptibility, and a downregulation of IL-12 that is associated with resistance, especially those from reared vectors. We could not detect a clear effect of SGH on the IFN-$\gamma$ as it was produced by all experimental groups in similar amount (Table 2). Here, IFN-$\gamma$ was almost undetectable in the acute phase and an expressive production was only seen in the late course of the infection (Table 2), in accordance with data described by others [5, 21, 22].

Of note is that the lesions achieved the maximum size exactly at the peak of IFN-$\gamma$. In fact, this cytokine may play a bidirectional role on the *L. amazonensis*–macrophage interactions. When optimally joined with some factors, it has a protective effect against infection, and without such synergy IFN-$\gamma$ promotes parasite replication, which reveals an unexpected ability of *L. amazonensis* in using host defense mechanisms in its own benefit [23].

In opposite direction, IL-12 was the main cytokine produced in the acute phase, decaying drastically in the latest stage of the infection. Control mice produced higher levels of IL-12 than both SGH groups ($P < 0.05$). Between those, wild-caught SGH co-inoculation determined a more elevated level of this cytokine ($P < 0.05$) at day 7 (Table 2). IL-12 is synthesized by antigen-presenting cells and drives a Th1 response for optimum production of macrophage-activating IFN-$\gamma$ and is associated with the development of resistance [2, 24]; however, *Lu. longipalpis* saliva downregulates the IL-12 production, as we observed, fostering a Th2 response [7]. Surprisingly, the IL-12 detected in the onset of the infection did not correlate with IFN-$\gamma$ production. Recently, it was seen that *L. amazonensis* dictate the inhibition of IL-12 responsiveness during the infection rather than the host, contributing with the disease progression [25].

Despite SGH of *Lu. longipalpis* has enhanced the IL-4 production from the 7th day onward (Table 2), a robust IL-4 production was not observed during all the experiment. The low level associated with the transitory production seen in our study reinforces the yet described observations that IL-4 can be a coadjutant but not the main modulator of the disease evolution in *L. amazonensis* infection, in the presence of saliva or not [5, 26].

On the other hand, IL-10, a multifunctional cytokine, has been implicated in disease progression and long-term persistence of *Leishmania* sp. in both human and experimental models [5, 27, 28]. IL-10 plays a role: (1) in limiting IFN-$\gamma$ production by T cells via downregulation of IL-12 production by macrophages and dendritic cells, (2) in inhibiting IFN-$\gamma$-mediated parasite killing [28], and (3) in directly promoting parasite growth inside macrophages [29]. It is also known to be synthesized by a variety of other cells than T lymphocytes, including macrophages, monocytes, keratinocytes, dendritic cells and mast cells [30]. Here, we could observe substantial amounts of IL-10 during *L.* (*L.*) *amazonensis* infection (Table 2). As observed by others [5, 7], *Lu. longipalpis* SGH promoted a significant increasing in IL-10 production, clearly detected from the 7th day onward. An important point is that wild-caught SGH induced lower levels of IL-10 ($P < 0.05$) than laboratory-colonized SGH at the chronic phase of the infection, which correlated with the lower number of parasites observed in the cutaneous lesions (Fig. 2).

In summary, despite the high production of IL-12 in the acute phase and of IFN-$\gamma$ in the later course, C57BL/6 mice infected with *L.* (*L.*) *amazonensis* do not healed and developed chronic lesions. The parasite itself contributed to this picture as it is known that *L. amazonensis* dictates the inhibition of IL-12 responsiveness and uses IFN-$\gamma$ to replicate. In addition, the lesions evolved in the presence of low levels of IL-4, indicating that susceptibility to this parasite is not a direct result of the IL-4 production but essentially of IL-10 that contributed to the observed disease outcome, probably through their effects on the downregulation of IL-12 and on parasite growth. Colonized vector's SGH enhanced this susceptible scenario downregulating IL-12 and upregulating IL-10 and IL-4. Here we underline that wild-caught *Lu. longipalpis* SGH regulated both cytokines associated with susceptibility and resistance but in a lesser extent, which determined significant smaller lesions and lower parasitism than SGH from laboratory-reared sand flies at the final course of the infection. In fact, lesion sizes in mice co-inoculated with wild-caught SGH were closer to those observed in control group. Perhaps the differences showed in the composition and in the amount of proteins between these distinct sources of salivary glands [13] could account for the lower effects seen on the modulation of *Leishmania* infection by the wild-caught SGH. Of note are the surprising results obtained by Kamhawi *et al.* [31] trying to mimic the natural transmission through bites of *P. papatasi* experimentally infected with *L. major*. The infection of C57BL/6 mice always resolved over time, similarly if mice were inoculated with parasite alone, showing that vector saliva did not markedly influence the infection outcome.

Finally, our findings address a probable bias by using SGH from laboratory-colonized sand flies instead of wild-caught vector SGH and the need to investigate the effects of vector saliva as close as possible to natural transmission to better understand its actual role in the establishment of *Leishmania* infections.

## Acknowledgment

This project was supported by the FAPESP, TDR-WHO and LIM50 HC-FMUSP. This study is part of M.D. Laurenti's Post-Doctorate Program supervised by PhD P.F.P. Pimenta.

## References

1 WHO. World Health Organization . [online]. http://www.who.int/leishmaniasis/disease_epidemiology/en/index.html. (last accessed May 2009).

2 Roberts MT. Current understandings on the immunology of leishmaniasis and recent developments in prevention and treatment. *Br Med Bull* 2006; 75 and 76: 115–30. Review.

3 Kamhawi S. The biological and immunomodulatory properties of sand fly saliva and its role in the establishment of *Leishmania* infections. *Microbes Infect* 2000;2:1765–73.

4 Mbow ML, Bleyenberg JA, Hall LR, Titus RG. *Plebotomus papatasi* sand fly gland lysate down-regulates a Th1, but up-regulates a Th2, response in mice infected with *Leishmania major*. *J Immunol* 1998;161:5571–7.

5 Norsworthy NB, Sun J, Elnaiem D, Lanzaro G, Soong L. Sandy fly saliva enhances *Leishmania amazonensis* infection by modulating interlukin-10 production. *Infect Immun* 2004;72:1240–7.

6 Theodos CM, Ribeiro JM, Titus RG. Analysis of enhancing effect of sand fly saliva on *Leishmania* infection in mice. *Infect Immun* 1991;59:1592–8.

7 Brodie TM, Smith MC, Morries RV, Titus RG. Immunomudulatory Effects of the *Lutzomyia longipalpis* salivary gland protein maxadilan on mouse macrophages. *Infect Immun* 2007;75: 2359–65.

8 Rohousová I, Volf P, Lipoldová M. Modulation of murine cellular immune response and cytokine production by salivary gland lysate of three sand fly species. *Parasite Immunol* 2005;27:469–73.

9 Valenzuela JG, Belkaid Y, Garfield MK *et al.* Toward a defined anti-*Leishmania* vaccine targeting vector antigens: characterization of a protective salivary protein. *J Exp Med* 2001;194:331–42.

10 Belkaid Y, Kamhawi S, Modi G *et al.* Development of a natural model of cutaneous leishmaniasis: powerful effects of vector saliva and saliva preexposure on the long-term outcome of *Leishmania* major infection in the mouse ear dermis. *J Exp Med* 1998;188:1941–53.

11 Thiakaki M, Rohousova I, Volfova V, Volf P, Chang KP, Soteriadou K. Sand fly specificity of saliva-mediated protective immunity in *Leishmania amazonensis*-BALB/c mouse model. *Microbes Infect* 2005;7:760–6.

12 Silveira FT, Laison R, Corbett CE. Clinical and immunopathological spectrum of American cutaneous leishmaniasis with special reference to the disease in Amazonian Brazil: a review. *Mem Inst Osvaldo Cruz* 2004;99:239–51.

13 Laurenti MD, Dos Santos Silveira VM, Costa Secundino NF, Corbett CE, Pimenta PP. Saliva of laboratory-reared *Lutzomyia longipalpis* exacerbates *Leishmania (Leishmania) amazonensis* infection more potently than saliva of wild-caught *Lutzomyia longipalpis*. *Parasitol Int* 2009; 58:220–6.

14 Killick-Kendrick R, Leaney AJ, Ready PD. A laboratory culture of *Lutzomyia longipalpis*. *Trans R Soc Trop Med Hyg* 1973;67:434.

15 Belkaid Y, Jouin H, Milon G. A method to recover, enumerate and identify lymphomyeloid cells present in an inflammatory dermal site: a study in laboratory mice. *J Immunol Methods* 1996; 199:5–25.

16 Volf P, Myskova J. Sand flies and *Leishmania*: specific versus permissive vectors. *Trends Parasitol* 2007;23:91–2.

17 Savani ES, Nunes VL, Galati EA, Castilho TM, Zampieri RA, Floeter-Winter LM. The finding of *Lutzomyia almerioi* and *Lutzomyia longipalpis* naturally infected by *Leishmania* spp. in a cutaneous and canine visceral leishmaniases focus in Serra da Bodoquena, Brazil. *Vet Parasitol* 2009;160:18–24.

18 McFarlane E, Perez C, Charmoy M *et al.* Neutrophilis contribute to development of a protective immune response during onset of infection with *Leishmania donovani*. *Infect Immun* 2008;76:532–41.

19 Teixeira CR, Teixeira MJ, Gomes RB *et al.* Saliva from *Lutzomyia longipalpis* induces CC chemokine ligand 2/monocyte chemoattractant protein-1 expression and macrophage recruitment. *J Immunol* 2005;175:8346–53.

20 Soares PP, Turco SJ. *Lutzomia longipalpis* (Díptera: Psychodidae: Phlebotominae): a review. *An Acad Bras Cienc* 2003;75:301–30.

21 Afonso LC, Scott P. Immune responses associated with susceptibility of C57BL/10 mice to *Leishmania amazonensis*. *Infect Immun* 1993;61:2952–9.

22 Maioli TU, Takane E, Arantes RM, Fietto JL, Afonso LC. Immune response induced by New World *Leishmania* species in C57BL/6 mice. *Parasitol Res* 2004;94:207–12.

23 Qi H, Ji J, Wanasen N, Soong L. Enhanced replication of *Leishmania amazonensis* amastigotes in gamma interferon-stimulated murine macrophages: implications for the pathogenesis of cutaneous leishmaniasis. *Infect Immun* 2004;72:988–95.

24 Awasthi A, Mathur RK, Saha B. Immune response to *Leishmania* infection. *Indian J Med Res* 2004;119:238–58. Review.

25 Jones DE, Buxbaum LU, Scott P. IL-4-independent inhibition of IL-12 responsiveness during *Leishmania amazonensis* infection. *J Immunol* 2000;165:364–72.

26 Ji J, Sun J, Soong L. Impaired expression of inflammatory cytokines and chemokines at early stages of infection with *Leishmania amazonensis*. *Infect Immun* 2003;71:4278–88.

27 Bourreau E, Prevot G, Gardon J, Pradinaud R, Launois P. High intralesional interleukin-10 messenger RNA expression in localized cutaneous leishmaniasis is associated with unresponsiveness to treatment. *J Infect Dis* 2001;184:1628–30.

28 Kane MM, Mosser DM. The role of IL-10 in promoting disease progression in leishmaniasis. *J Immunol* 2001;166:1141–7.

29 Iniesta V, Gómez-Nieto LC, Molano I *et al.* Arginase I induction in macrophages, triggered by Th2-type cytokines, supports the growth of intracellular *Leishmania* parasites. *Parasite Immunol* 2002;24:113–8.

30 Moore KW, de Waal MR, Coffman RL, O'Garra A. Interleukin -10 and the interleukin-10 receptor. *Annu Rev Immunol* 2001;19:683–765.

31 Kamhawi S, Belkaid Y, Modi G, Rowton E, Sacks D. Protection against cutaneous leishmaniasis resulting from bites of uninfected sand flies. *Science* 2000;17:290.

**ANEXO-22**

---

Histopathology of lymphoid organs in experimental leishmaniasis

Corbett C.E.P.; Paes, R.A.; **Laurenti, M.D.**; Andrade Junior, H.; Duarte, M.I.S.

International Journal of Experimental Pathology 1992; 73(4): 417-433

*Int. J. Exp. Path.* (1992) 73, 417–433

# Histopathology of lymphoid organs in experimental leishmaniasis

C.E.P. Corbett*, R.A. Pinto Paes, M.D. Laurenti*, H.F. Andrade Jr* and M.I.S. Duarte*

**Department of Pathology of University of São Paulo Medical School and Department of Pathology, Santa Casa Medical School, São Paulo, SP, Brazil*

Received for publication
Accepted for publication

**Summary.** Hamsters *(Mesocricetus auratus)* were inoculated with *L. (L.) chagasi* and killed on days 7, 15, 30, 45 and 60 after infection.

The lymphoid organs developed initial proliferation of the B lymphocyte zone with recovery by the 60th day group when pyroninophilic cells were prominent. The T lymphocyte area showed a progressive selective decrease of lymphocytes and cellular density with cellular pleomorphism including macrophages, plasma cells and reticular cells. The mean volume of the white pulp increased with the lymphoid follicle hyperplasia but returned to its initial level by day 60.

The main red pulp change was marked hyperplasia of the phagocytic mononuclear cells containing parasites from the 30th day of infection onward.

These changes are compatible with the humoral and cellular immunoresponse found in patients with visceral leishmaniasis (VL).

Keywords: *L. (L.) chagasi*, experimental visceral leishmaniasis, pathology, lymphoid organs

The histopathology of the lymphoid organs in visceral leishmaniasis in hamster and man has been reported as due to reticuloendothelial system hyperplasia and hypertrophy with parasitism of the cells (Meleney 1925). Andrade and Andrade (1966) describing 13 cases of human visceral leishmaniasis considered three main changes to be characteristic of the visceral leishmaniasis: (1) reticuloendothelial system cell proliferation with high parasitism, lymphocyte infiltrate and plasmocytosis; (2) interstitial deposits of hyalin substance similar to secondary amyloidosis, and (3) proliferation and swelling of endothelial cells. Veress *et al.* (1974, 1977) also noted the occurrence of extracellular eosinophilic material deposits in the spleen, lymphoid atrophy of the white pulp of the spleen and a decrease in the numbers of small lymphocytes in the paracortical zone of the lymph nodes. There was also necrosis and fibrosis of the T lymphocyte dependent zone together with histiocytic hyperplasia with parasites and plasmocytosis. These changes were considered to be due to immunosuppression associated with excess antigen. Gutierrez *et al.* (1984) reported that in liver, spleen and bone marrow of mice infected with *L. donovani*, the development of granulomas was the main histopathological

Correspondence: Professor Dr Carlos Eduardo Pereira Corbett, Faculdade de Medicina da USP, Depto. de Patologia, Av. Dr Arnaldo 455, 1° andar, sala 26, 01246 São Paulo (SP), Brasil.