UNIVERSIDADE DE SÃO PAULO
HOSPITAL DE REABILITAÇÃO DE ANOMALIAS CRANIOFACIAIS

GABRIELA LETICIA CLAVISIO SIQUEIRA MACHADO

Comportamento longitudinal do crescimento facial e mandibular em pacientes com Sequência de Pierre Robin isolada

Longitudinal behavior of facial and mandibular growth in patients with isolated Pierre Robin sequence

BAURU
2017

GABRIELA LETICIA CLAVISIO SIQUEIRA MACHADO

Longitudinal behavior of facial and mandibular growth in patients with isolated Pierre Robin sequence

Comportamento longitudinal do crescimento facial e mandibular de pacientes com Sequência de Pierre Robin isolada

Dissertação constituída por artigo apresentada ao Hospital de Reabilitação de Anomalias Craniofaciais da Universidade de São Paulo para obtenção do título de Mestre em Ciências da Reabilitação, área de concentração Fissuras Orofaciais e Anomalias relacionadas.

Orientadora: Profª. Drª. Terumi Okada Ozawa

BAURU

2017

UNIVERSIDADE DE SÃO PAULO
HOSPITAL DE REABILITAÇÃO DE ANOMALIAS CRANIOFACIAIS

R. Silvio Marchione, 3-20
17012-900 - Bauru – SP – Brasil
Telefone: (14) 3235-8000

Machado, Gabriela Leticia Clavisio Siqueira

M18l Longitudinal behavior of the jaw and facial growth in patients with isolated Pierre Robin Sequence / Gabriela Leticia Clavisio Siqueira Machado – Bauru, 2017.

76 p. : il. ; 30 cm.

Dissertação (Mestrado) – Hospital de Reabilitação de Anomalias Craniofaciais

Orientadora: Profª. Drª. Terumi Okada Ozawa
Descritores: 1. Pierre Robin sequence 2. growth 3. photography

FOLHA DE APROVAÇÃO

Gabriela Leticia Clavisio Siqueira Machado

Dissertação apresentada ao Hospital de Reabilitação de Anomalias Craniofaciais da Universidade de São Paulo para a obtenção do título de Mestre.
Área de Concentração: Fissuras Orofaciais e Anomalias Relacionadas

Aprovado em:

Banca Examinadora

Prof. Dr. _____

Instituição _____

Prof. Dr. _____

Instituição _____

_____

Profª Drª Terumi Okada Ozawa

Instituição (Orientador)

_____

Profª Drª Daniela Gamba Garib Carreira

Presidente da Comissão de Pós-Graduação do HRAC-USP

Data de depósito da dissertação junto à SPG: ___/___/ ____

DEDICATÓRIA

A Deus e a minha família,

dedico este trabalho!

AGRADECIMENTOS

Em primeiro lugar, a ***Deus****, que me protege e guia os meus passos todos os dias de minha vida. Obrigada Senhor, por preparar tudo da melhor forma possível, ser sempre fiel e colocar pessoas tão especiais ao meu redor.*

Em especial, à minha orientadora ***Profª Drª Terumi Okada Ozawa****, por abrir as portas e me receber de uma forma tão especial. Sempre com uma palavra calma e de ânimo nos meus momentos de angústia. É gratificante ter um exemplo de sabedoria e Inteligência assim por perto, mas acima de tudo, seus exemplos de amor e preocupação com o próximo ficarão marcados sem mim. Foi um prazer poder desenvolver esse trabalho ao seu lado!*

Aos meus pais, ***Vivian e Vitor Hugo****, os responsáveis por tudo que sou! Amaram e cuidaram de mim desde o meu nascimento, muitas vezes abrindo mão das coisas para que eu e minha irmã tivéssemos a melhor educação e as melhores oportunidades. Tenho muitas lembranças felizes ao lado de vocês que jamais sairão do meu coração. Serei eternamente grata por tudo! Pai, o seu exemplo de superação, dedicação, perseverança me inspiram. Mãe, obrigada por estar sempre presente em minha vida, ser minha amiga fiel e a mulher mais forte que eu conheço. Amo vocês!*

Aos meus avós, ***Carmen e Paulo****, por todo amor e carinho dispendidos a mim sempre. Por todo cuidado e preocupação desde a minha infância até os dias de hoje. Gostaria de poder estar mais presente. Amo vocês, obrigada por tudo!!*

Ao meu marido, companheiro e melhor amigo ***Ricardo****, que esteve ao meu lado em todos os momentos nos últimos 8 anos da minha vida. Sempre me incentivando, dando forças e me apoiando nos momentos em que mais precisei. Essa conquista não é só minha e sem o seu apoio, compreensão e dedicação a nós nada disso seria possível. Obrigada por tudo! Eu te amo e agradeço a Deus todos os dias por ter me preparado um amor como o seu!*

À *minha irmã* ***Giovana****, por ser a minha companheira de vida, ser eu em outro formato/personalidade. Tenho muitas lembranças felizes em minha vida e você está presente em todas elas. Nada teria sido igual sem você. Gostaria de estar mais presente em seu dia-a-dia, mas eu sei que apesar da distância, nada muda! Obrigada por tudo, amo você!!*

À minha companheirinha fiel ***Kyra****, que fez o meu dia-a-dia ser mais leve com a sua presença alegre. O seu carinho e amor incondicional foram muito importantes para mim, principalmente neste último semestre em que fomos apenas nós duas em casa. Obrigada, minha filhinha de 4 patas!!*

Aos meus cunhados/irmãos ***Bruna e Rodrigo*** *pela companhia ao longo dos últimos anos e em especial nos últimos meses, sempre mostrando preocupação e fazendo de tudo para deixar os meus dias mais felizes. Vocês foram uma grata surpresa que a vida me deu! Amo vocês.*

Aos orientadores e ortodontistas do Setor de Ortodontia do HRAC/USP ***Adriano, Aiello, Araci, Arlete, Gleisieli, Rita, Renata, Rogério, Silvia e Thiago,*** *por sempre estarem dispostos a ensinar e transmitir tudo que sabem a todos alunos que passam pelo setor. Obrigada pela dedicação e pelos anos de convivência agradável!*

*À querida **Profª Drª Daniela Garib**, pela simpatia e carinho com que sempre me recebeu durante esses anos de convivência. A admiro desde a minha graduação e a conhecendo mais de perto, essa admiração só cresceu, não apenas por todo conhecimento científico que tem, mas pelo lado humano e amigo que possui! Obrigada pelo exemplo, profª!!*

*Aos meus **colegas de pós-graduação**, obrigada por dividirem comigo todos os momentos de pesquisa, disciplinas, clínicas e me auxiliarem nos momentos de dúvidas.*

*À minha amiga **Rayane**, que me acompanha desde a graduação, residência e agora no mestrado. Passamos por tantas coisas juntas nesses últimos anos e sua amizade e companhia foram fundamentais! Somos tão diferentes, respeitamos essas diferenças e talvez isso seja o que faz essa amizade ser tão especial! Obrigada pela sua alegria e convivência!*

*Às auxiliares do setor de Ortodontia do HRAC/USP **Celina, Denise, Leila, Rosângela, Solange, Sônia** e **Susana** por toda disposição em ajudar e por serem prestativas e alegres, facilitando o dia-a-dia do setor!*

*A todos os **Residentes** e **Ex-residentes** do Setor de Ortodontia do HRAC/USP com quem tive a oportunidade de trocar experiências e dividir o meu dia-a-dia! Obrigada pela agradável convivência!*

*Às secretárias da pós-graduação do HRAC/USP, **Zezé, Tati, Ana Regina** e **Lucy** pela simpatia e ajuda em todos os momentos em que precisei. Obrigada!*

*Aos **funcionários da biblioteca** do HRAC/USP pela prestatividade em ajudar nos momentos necessários.*

Às minhas amigas, ***Giovana Weckwerth, Mariana Fantoni, Brunna Ferrairo, Michele Garcia, Gabriela Chicrala, Felicia Miranda*** *e* ***Janaína Maciel*** *por todo companheirismo e amizade! Vocês fizeram meus anos de graduação e pós-graduação mais felizes, pois sempre estiveram presentes de alguma forma! Obrigada pelos encontros e risadas e que nossa amizade só se fortaleça a cada dia.*

Ao ***Hospital de Reabilitação de Anomalias Craniofaciais (HRAC/USP)*** *por toda formação ortodôntica e principalmente humana que recebi durante esses 3 anos em que tenho a oportunidade de fazer parte da sua história. Com certeza, não tem como sair da mesma forma que entrei Obrigada Centrinho, você é um exemplo a ser seguido!*

A ***Faculdade de Odontologia de Bauru (FOB/USP)*** *por ter me acolhido em 2010 e me ensinado tudo que sei sobre a Odontologia. Os anos que passei nessa casa foram muito especiais e estarão sempre em minha memória! Orgulho de ser FOB/USP!!*

À ***Coordenação de Aperfeiçoamento de Pessoal de Nível Superior (CAPES)*** *pela bolsa de Mestrado, auxílio indispensável para a realização deste trabalho.*

Aos ***Pacientes do Centrinho****, por toda paciência e disponibilidade em ajudar. Toda essa nossa busca por conhecimento é por vocês!!*

Aos ***Professores integrantes da banca examinadora*** *por terem aceito prontamente o convite para colaborarem com este trabalho.*

A todos que de uma forma ou de outra colaboraram para o desenvolvimento deste trabalho, muito obrigada!!

“Conhecimento não é aquilo que você sabe, mas o que você faz com aquilo que você sabe.”

Aldous Huxley

Abstract

ABSTRACT

Longitudinal behavior of facial and mandibular growth in patients with isolated Pierre Robin sequence

The Pierre Robin sequence (PRS) is a congenital anomalie characterized by the occurrence of micrognathia, glossoptosis and cleft palate. Clinically is observed upper airway obstruction with consequent breathing and feeding difficulties. Individuals with PRS usually show retrognathia and a significantly convex facial profile in adulthood. The aim of this study was to assess the longitudinal behavior of facial growth of individuals with isolated PRS using photographs. Photographs of the right facial profile of 100 individuals were used (50 individuals with isolated PRS and 50 individuals without any craniofacial anomaly). The individuals with PRS were evaluated at 3 different times (T1: baby, T2: mixed dentition, T3: permanent dentition) measuring the facial convexity angle (G.Sn.Pog´). A comparison between T3 and control group (C), individuals without craniofacial anomalies and in permanent dentition, were also performed, checking the facial convexity, nasolabial (Ls.Sn.Cm), mentolabial (Li.Si.Pog´), facial inferior third (Sn.Gn´.C) angles and the ratio between medium anterior facial height and lower anterior facial height (MAFH/LAFH). The T3 group showed a facial convexity angle increased in relation to C group as well as the facial inferior third angle and the MAFH/LAFH ratio. In the longitudinal evaluation of individuals with isolated PRS, the significant difference occurred between T1 and T2 groups and T1 and T3 groups showing that facial convexity was higher in the baby phase and didn´t have a significant variation between the phases of mixed and permanent dentition. Individuals with isolated Pierre Robin sequence showed increased facial convexity in all phases evaluated but it decreased with their growth. When compared to individuals without anomalies, the PRS individuals continue with retrognathism in the permanent dentition. The facial inferior third angle and the MAFH/LAFH ratio increased suggest a lack of a chin projection to the maxilla, leading to a considerable number of orthognathic surgeries for the correction of discrepancies.

Keywords: Pierre Robin sequence, growth, photography

Resumo

RESUMO

Comportamento longitudinal do crescimento facial e mandibular em pacientes com Sequência de Pierre Robin isolada

A Sequência de Pierre Robin (SPR) é uma anomalia congênita caracterizada pela ocorrência de micrognatia, glossoptose e fissura de palato. Clinicamente observa-se a obstrução das vias aéreas superiores e uma consequente dificuldade na respiração e alimentação. Normalmente os indivíduos com SPR apresentam retrognatia e um perfil facial significativamente convexo na idade adulta. O objetivo do estudo foi avaliar o comportamento longitudinal do crescimento facial de indivíduos com SPRi, por meio de fotografias faciais. Foram utilizadas fotografias do perfil facial direito de 100 indivíduos (50 indivíduos com SPRi e 50 indivíduos sem anomalia craniofacial). Os indivíduos com SPRi foram avaliados em 3 tempos diferentes (T1: bebê, T2: dentadura mista, T3: dentadura permanente), mensurando o ângulo de convexidade facial (G.Sn.Pog´). Também foi realizada uma comparação entre o grupo T3 e o grupo controle (C), indivíduos sem anomalias craniofaciais em fase de dentadura permanente, verificando os ângulos de convexidade facial, nasolabial (Ls.Sn.Cm), mentolabial (Li.Si.Pog´), do terço inferior da face (Sn.Gn´.C) e a proporção entre altura facial anterior média e altura facial anterior inferior (AFAM/AFAI). O grupo T3 apresentou uma convexidade facial aumentada em relação ao grupo C, assim como o ângulo do terço inferior e a proporção AFAM/AFAI. Na comparação longitudinal entre T1, T2 e T3, o grupo T1 apresentou uma convexidade facial significativamente maior que a convexidade encontrada em T2 e T3. Na avaliação longitudinal dos indivíduos com SPRi a diferença significante se deu entre os grupos T1 e T2 e também entre T1 e T3, demonstrando que a convexidade facial apresentou-se maior na fase bebê e não teve uma variação significativa entre as fases de dentadura mista e permanente. Conclui-se que indivíduos com SPRi apresentam convexidade facial aumentada, em todas as fases avaliadas, mas que diminui ao longo do crescimento. Quando comparados a indivíduos sem anomalias, os pacientes SPRi continuam retrognatas na dentadura permanente. O ângulo do terço inferior da face e AFAM/AFAI aumentados sugerem falta de projeção do mento em relação à maxila, levando a um número considerável de cirurgias ortognática para a correção das discrepâncias.

Palavras-chave: Sequência de Pierre Robin, crescimento, fotografia

LIST OF ILLUSTRATIONS

LIST OF TABLES

TABLE OF CONTENTS

1 Introduction

1 INTRODUCTION

The Pierre Robin sequence (PRS) is a congenital anomalie characterized by the occurrence of micrognathia, glossoptosis and cleft palate (ELLIOT, 1994), which is present in 90% of cases (CAOUETTE-LABERGE; BAYET; LAROCQUE, 1994). This condition was first described, in 1923, by the French stomatologist Pierre Robin, who associated glossoptosis with mandibular atresy in 1934.

Pashayan and Lewis, in 1984, suggested the name Pierre Robin sequence because they believed that it was a sequential pathogenesis and not a syndrome as it had been denominated for many years (Pierre Robin syndrome) and thus the terms syndrome and anomaly aren´t longer used.

It has been reported a prevalence for PRS between 1:8500 and 1:20000 births worldwide (GENTHER et al., 2015) and it may manifest isolated, be a component of a syndrome or be associated with other developmental defects that don´t represent a specific syndrome (COHEN JR, 1976).

Clinically it is observed upper airway obstruction with consequent breathing and feeding difficulties (PRUZANSKY; RICHMOND, 1954; PRUZANSKY, 1969). Its clinical expression is very heterogeneous ranging from a slight respiratory difficulty to severe asphyxia episodes, being more frequent in the first months of life (FREEMAN; MANNERS, 1980). This condition makes difficult the newborn weight gain because the necessary calories are spent on respiratory effort (SINGER; SIDOTI, 1992).

The upper airway obstruction in Pierre Robin sequence isn´t always caused by glossoptosis and may be associated with other factors. Nasopharyngoscopies performed in patients with craniofacial anomalies and obstructive apnoea, including Pierre Robin sequence, demonstrated four different types of obstruction (MARQUES et al., 2005).

Depending on the severity of airway obstruction, several interventions may be necessary in the treatment of a newborn infant with PRS (MYER et al., 1996; WAGENER et al., 2003), ranging from more conservative interventions such as prone position (PASYAYAN; LEWIS, 1984) and the nasopharyngeal intubation (HEAF et al., 1982; ANDERSON et al., 2007) to more aggressive interventions such as glossopexy (ARGAMASO, 1992; COZZI et al., 2008), mandibular distraction

(MONASTERIO et al., 2002; DENNY; AMM, 2005) and tracheostomy (BATH; BULL, 1997).

The etiopathogenesis of the PRS has been discussed by several researches. The PRS triad was achieved in an experiment with animals through mandibular constriction (COCKE JR, 1966; POSWILLO, 1968). In 1966 Latham proposed that the explanation for PRS was based on structural changes due to a mandibular defect. Still in 1966, Becker and Palm considered that an embryonic defect in tongue is the primary pathogenic event in the Pierre Robin Sequence. Rintala, Ranta and Stegars (1984) and Edwards and Newall (1985) believe that genetic disorders in the growth of the mandible and maxilla result in cleft palate and micrognathia. Cohen Jr (1976) and Carey (1982) proposed that the various conditions in wich the PRS triad appears suggest the heterogeneity of etiopathogenic factors. Diewert (1979) and Schubert, Jahn and Berginski (2005) proposed that the mandibular retroposition is considered the primary factor for the subsequent development of others changes present in the PRS. Currently, the accepted theory is that mandibular micrognathia is the primary pathogenic event then the tongue, due to the restricted space, interferes in the fusion of the palatal processes, causing the cleft palate and also obstructs the upper airways in the immediate postnatal and neonatal periods (VIG, 1990; JONES, 2013).

Although the exact etiopathogenesis of isolated PRS is still unknown, several factors suggest a genetic basis for the anomaly. Findings demonstrate the isolated PRS can be caused by dysregulation in the SOX9 and KCNJ2 genes, evidenced by the reduction of the expression of these genes in the carriers (JAKOBSEN et al., 2007; SELVI; MUKUNDA PRIYANKA, 2013)

Previously, it was thought that mandibular micrognathia observed in individuals with Pierre Robin sequence should be an effect of intrauterine constriction and that the mandibular growth should be resumed after birth, but the researches performed didn´t demonstrate a significant catch-up growth (PRUZANSKY; RICHMOND, 1954; POSWILLO, 1968; PRUZANSKY, 1969, HOTZ; GNOINSKY, 1982; POSWILLO, 1988; OLNEY et al., 1997). The current view is that the mandible is small at birth and remains small in all active facial growth (MARCOVIC, 1972; DASKALOGIANNAKIS; ROSS; TOMPSON, 2001; OZAWA et al., 2012, SHEN et al, 2012), being that catch-up growth only partial (FIGUEROA et al., 1991). Thus, individuals with PRS usually demonstrate retrognathia and a significantly convex

facial profile in adulthood (LAITINEN; HELIOVAARA; RANTA, 1997; ERIKSEN et al., 2006).

To assess the growth of individuals with isolated PRS, transversal and longitudinal studies have been carried out using profile photograph (OZAWA et al., 2012), lateral cephalogram (PRUZANSKY; RICHMOND, 1954; PRUZANSKY, 1969; MARKOVIC, 1972; HOTZ; GNOINSKY, 1982; FIGUEROA et al.,1991; LAITINEN; RANTA, 1992; LAITINEN; HELIOVAARA; RANTA, 1997; VEGTER; HAGE; MULDER, 1999; DAKALOGIANNAKIS; ROSS; TOMPSON, 2001; HERMANN et al., 2003a, 2003b; SURI; ROSS; TOMPSON, 2006, 2010; ERIKSEN et al., 2006; LU et al., 2007, SHEN et al., 2012) and computed tomography (CHUNG et al., 2012), which are analyzed through cephalometric measurements, but there was a great need for more longitudinal studies approaching this topic . Ozawa et al. (2012) observed that in the mixed dentition phase the patients with isolated PRS had an increased facial convexity (77%), mandibular micrognathia with predominant Class II occlusal relationship (82%) and anteroinferior crowding (81%).

2 Proposition

2 PROPOSITION

The aim of the present study was to assess the longitudinal evolution of mandibular and facial growth of individuals with isolated PRS, using facial profile photographs by means of angular and proportional measures, verifying the percentage of individuals with isolated PRS who had the mandibular catch-up growth and those who evolved with severe mandibular deficiency requiring orthognathic surgery to correct the skeletal discrepancy of the facial profile and compare these individuals with isolated PRS to a group of individuals without the anomaly, the control group.

3 Article

3 ARTICLE

The article presented in this Dissertation was written according to Journal of Dental Research instructions and guidelines for article submission (Annex A).

LONGITUDINAL BEHAVIOR OF FACIAL GROWTH IN ISOLATED PIERRE ROBIN SEQUENCE

ABSTRACT

The Pierre Robin sequence (PRS) is a congenital anomalie characterized by the occurrence of micrognathia, glossoptosis and cleft palate. Clinically is observed upper airway obstruction with consequent breathing and feeding difficulties. Individuals with PRS usually show retrognathia and a significantly convex facial profile in adulthood. The aim of this study was to assess the longitudinal behavior of facial growth of individuals with isolated PRS using photographs. Photographs of the right facial profile of 100 individuals were used (50 individuals with isolated PRS and 50 individuals without craniofacial anomaly). The individuals with PRS were evaluated at 3 different times (T1: baby, T2: mixed dentition, T3: permanent dentition) measuring the facial convexity angle (G.Sn.Pog´). A comparison between T3 and control group (C), individuals without craniofacial anomalies and in permanent dentition, were also performed, checking the facial convexity, nasolabial (Ls.Sn.Cm), mentolabial (Li.Si.Pog´), facial inferior third (Sn.Gn´.C) angles and the ratio between medium anterior facial height and lower anterior facial height (MAFH/LAFH). The T3 group showed a facial convexity angle increased in relation to C group as well as the facial inferior third angle and the MAFH/LAFH ratio. In the longitudinal evaluation of individuals with isolated PRS, the significant difference occurred between T1 and T2 groups and T1 and T3 groups showing that facial convexity was higher in the baby phase and didn´t have a significant variation between the phases of mixed and permanent dentition. Individuals with isolated Pierre Robin sequence showed increased facial convexity in all phases evaluated but it decreased with their growth. When compared to individuals without anomalies, the PRS individuals continue with retrognathism in the permanent dentition. The facial inferior third angle and the MAFH/LAFH ratio increased suggest a lack of a chin projection to the maxilla, leading to a considerable number of orthognathic surgeries for the correction of discrepancies.

Keywords: glossoptosis, micrognathism, cleft palate, photography, mandible, profile

INTRODUCTION

The Pierre Robin sequence (PRS) is a congenital anomalie characterized by the occurrence of micrognathia, glossoptosis and cleft palate (Elliott, 1994), which is present in 90% of cases (Caouette-Laberge et al., 1994).

It has been reported a prevalence for PRS between 1:8500 and 1:20000 births worldwide (Genther et al., 2015) and it may manifest isolated, be a component of a syndrome or be associated with other developmental defects that don´t represent a specific syndrome (Cohen Jr, 1976).

Clinically it is observed upper airway obstruction with consequent breathing and feeding difficulties (Pruzansky, Richmond, 1954; Pruzansky, 1969). Its clinical expression is very heterogeneous ranging from a slight respiratory difficulty to severe asphyxia episodes, being more frequent in the first months of life (Freeman; Manners, 1980). Depending on the severity of airway obstruction, several interventions may be necessary in the treatment of a newborn infant with PRS (Myer et al., 1998; Wagener et al., 2003), ranging from more conservative interventions such as prone position (Pasyayan; Lewis, 1984) and the nasopharyngeal intubation (Heaf et al., 1982; Anderson et al., 2007) to more aggressive interventions such as glossopexy (Argamaso, 1992; Cozzi et al., 2008), mandibular distraction (Monasterio et al., 2002; Denny; Amm, 2005) and tracheostomy (Bath; Bull, 1997).

The etiopathogenesis of the PRS has been discussed by several researchers and there isn´t consensus in the literature regarding it and the most diverse factors are indicated as a primary event for its occurrence such as structural changes due to mandibular defect (Latham, 1966), embryonic defects in the tongue (Becker e Palm, 1966), genetic disorders in growth of the maxilla and mandible (Rintala et al, 1984; Edwards e Newall, 1985), mandibular retroposition (Diewert, 1979; Schubert et al, 2005), heterogeneity of etiopathogenic factors (Cohen, 1979) and mandibular micrognathia (Vig, 1988 ; Jones, 2013), which is the line of thought most accepted until then.

Previously, it was thought that mandibular micrognathia observed in individuals with Pierre Robin sequence would be an effect of intrauterine constriction and that the mandibular growth would be resumed after birth, but the researches performed didn’t demonstrate a significant catch-up growth (Pruzansky, Richmond, 1954; Poswillo, 1968; Pruzansky, 1969, Hotz, Gnoinski, 1982; Poswillo, 1988; Olney

et al., 1997). The current view is that the mandible is small at birth and remains small in all active facial growth (Marcovic, 1972; Daskalogiannakis, 2001), being the catch-up growth only partial (Figueroa et al., 1991). Thus, patients with PRS usually demonstrate retrognathia and a significantly convex facial profile in adulthood (Laitinen, Ranta, 1997; Eriksen et al., 2006).

To assess the growth of individuals with isolated PRS, transversal and longitudinal studies have been carried out using profile photograph (Ozawa et al., 2012), lateral cephalogram (Pruzansky and Richmond, 1954; Pruzansky, 1969; Markovic, 1972; Hotz and Gnoinski, 1982; Figueroa et al.,1991; Laitinen and Ranta, 1992; Laitinen et al., 1997; Vegter et al., 1999; Daskalogiannakis et al., 2001; Hermann, 2003a, 2003b; Suri et al., 2006, 2010; Eriksen et al., 2006; Lu, 2007, Shen et al., 2012) and computed tomography (Chung et al., 2012), which are analyzed through cephalometric measurements, but there was a great need for more longitudinal studies approaching this topic . Ozawa et al. (2010, 2012) observed that in the mixed dentition phase the patients with isolated PRS had an increased facial convexity (77%), mandibular micrognathia with predominant Class II occlusal relationship (82%) and anteroinferior crowding (81%).

The aim of the present study was to assess the longitudinal evolution of mandibular and facial growth of individuals with isolated PRS, using facial profile photographs by means of angular and proportional measures verifying the percentage of individuals with isolated PRS who had the mandibular catch-up growth and those who evolved with severe mandibular deficiency requiring orthognathic surgery to correct the skeletal discrepancy of the facial profile and compare these individuals with isolated PRS to a group of individuals without the anomaly, the control group.

MATERIALS AND METHODS

This Study was approved by the Ethical Committee in Research of Hospital for Rehabilitation of Craniofacial Anomalies (Protocol 53785816.4.0000.5441).

Sample

To obtain the sample, we started with a list of approximately 800 individuals with isolated PRS using the following exclusion criteria: possessing complete longitudinal photographic documentation (baby, mixed and permanent dentition) with sufficient quality and standardization and having not undergone previous orthopedic treatment. From these criteria we reached the number of 50 individuals. The control group was selected in a paired form with the study group having compatible age and gender.

Were used 200 right facial profile photographs of 100 individuals (50 with isolated PRS and 50 without any craniofacial anomaly). The most recent photographs were obtained using a digital camera (Nikon D70S, Nikon Inc., New York, NY) and a macro lens of 100mm (Sigma Corporation of America, New York, NY). Older photographs were taken with the analog camera of the same brand and later scanned. At the photographs time the individuals were oriented to look ahead in a colored mark positioned at eye level with a neutral facial expression and the head in natural position. The sample was divided into the following groups:

- T1 group: 50 profile photographs of individuals with isolated PRS, with mean age of 5.3 months, with diagnosis confirmed by the pediatrics and genetics teams of HRAC/USP and regularly registered at the institution.
- T2 group: 50 profile photographs of individuals with isolated PRS, the same as the precious group, with mean age of 9.6 years and in mixed dentition.
- T3 group: 50 profile photographs of individuals with isolated PRS, the same as the previous groups, with mean age of 14.6 years and in permanent dentition.
- C group: 50 photographs of individuals without any craniofacial anomaly, with dental Class I and balanced facial pattern without accentuated maxillomandibular discrepancy, with mean age of 14.8 years in permanent dentition, regularly registered in the PROFIS Interceptive Orthodontics course, an entity associated with HRAC/USP, representing the control group.

Comparison betweeen T3 and C groups

At first, the 100 photographs of both groups (50 of each) were analyzed using the Dolphin Imaging® software and had the following tegumentary points were marked to obtain the measurements, according to Legan and Burstone (1980).

- G (tegument glabella): the most anterior tegumentary point of the glabella contour.
- Cm (columella): the most anterior point of the nasal columella
- Sn (subnasal): intersection of the columella contour with the labial philtrum.
- Ls (labrale superius): the mucocutaneous rim of the upper lip.
- Li (labrale inferius): the mucocutaneous rim of the lower lip.
- Pog´ (soft pogonion): the most anterior point of the soft chin
- Si (mentolabial sulcus): the deepest point in the mentolabial sulcus, approximately at midway between Li and Pog´
- Me´ (soft menton): the lowest point of the soft chin contour
- C (cervical): the intersection of the submental contour and neck areas
- Gn´ (soft gnathion): the intersection between Sn-Pog´and C-Me´ lines.

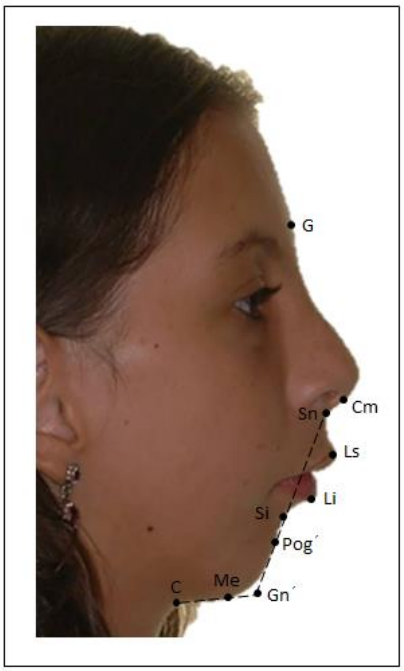

Figure 1. Tegumentary points marked on the photographs

The quantities used in the numerical facial analysis of the profile were described and used by Burstone (1958), Legan e Burstone (1980), Scheideman et al. (1980), Wolford and Hilliard, (1981), Lehman Jr (1987), Arnett e Bergman (1993a), Arnett e Bergman (1993b), Fernandez-Riveiro et al. (2003), Sforza et al. (2007) e Ozawa (2012). Some were adapted from the cephalometric analysis of the soft profile in lateral cephalogram for the analysis in tegumentary profile photographs. The quantities used in this study are below:

- Facial convexity angle (FCA): supplement of the angle formed by G.Sn.Pog´ points
- Nasolabial angle (NLA): formed by Ls.Sn.Cm points
- Mentolabial angle (MLA): formed by Li.Si.Pog´points
- Facial inferior third angle (FITA): formed by Sn.Gn´.C points
- Ratio between medium anterior facial height and lower anterior facial height (MAFH/LAFH), given by the ratio between the distances G-Sn and Sn-Me projected in a true vertical line

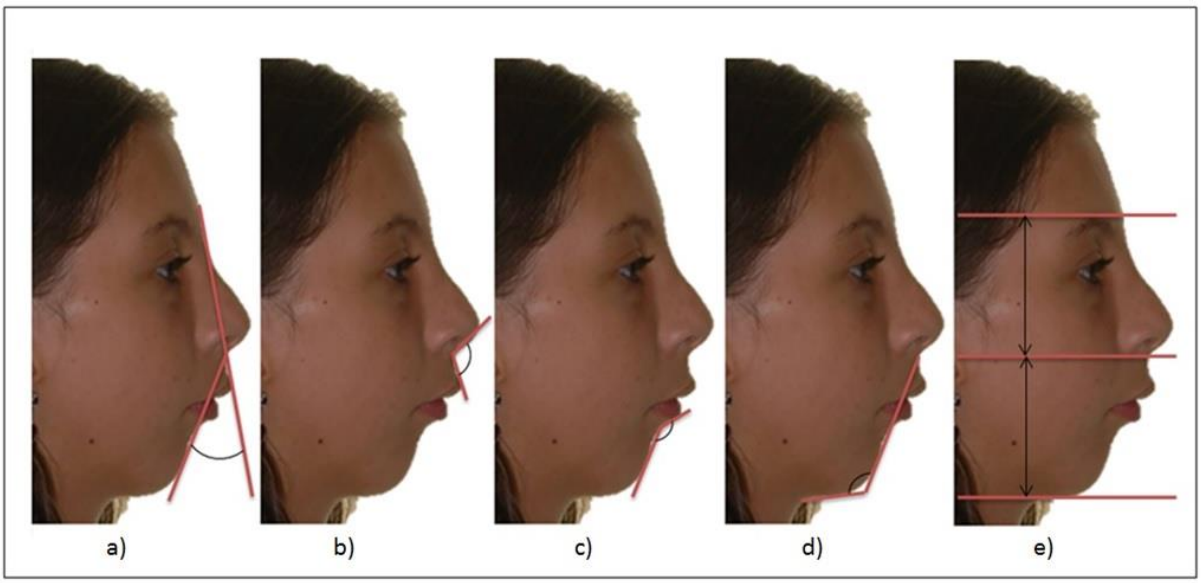

Figure 2. The quantities used: a) facial convexity angle; b) nasolabial angle; c) mentolabial angle; d) facial inferior third angle; e) MAFH/LAFH ratio

After the measurements had been taken and the data obtained, the percentage of individuals who had orthodontic-surgical treatment was verified through the medical records.

Comparison among T1, T2 and T3 groups

Subsequently for a longitudinal evaluation of the individuals with isolated PRS, 3 tegumentary points (Gl, Sn and Pog´) were scored in the 150 photographs of the T1, T2 and T3 groups (50 of each) so that the convexity facial angle was obtained and the comparison could be made, also using the Dolphin Imaging® software.

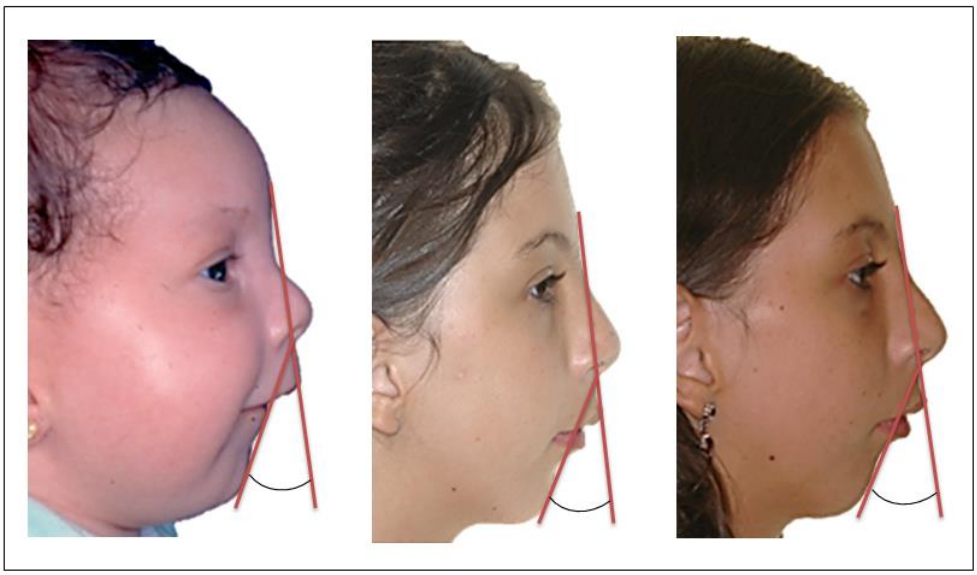

Figure 3. Facial convexity angle longitudinally evaluated

Method error

All measurements were performed by a single examiner previously calibrated to perform the procedure, twice with a 30-day interval between measurements to evaluate the error of the method through the Intraclass Correlation Coefficient (ICC). The mean value between the two evaluations was adopted by this study, for all quantities.

Statical analysis

The Mann-Whitney test was used to compare the T3 and C groups. For the comparison among T1, T2 and T3 groups, the Friedman test was applied followed by Tukey´s test (significance level of 5%).

RESULTS

The Intraclass Correlation Coefficient (ICC) obtained showed excellent reproducibility among the measurements, ranging from 0.93 to 1.

Table 1 shows the comparison results between T3 and C groups, that is individuals in the permanent dentition but one group with isolated PRS and the other without the anomaly for the variables: facial convexity angle, nasolabial angle, mentolabial angle, facial inferior third angle and MAFH/LAFH ratio. The results were statically significant for facial convexity angle, where the T3 group presented an increased facial convexity in relation to C group. The facial inferior third angle was also significantly increased in the T3 group in relation to C group as well as the ratio between MAFH and LAFH.

Table 1. Comparison between T3 and C groups (Mann-Whitney test)

Variable	Groups	Mean (SD)	Minimum	Maximum	P
Facial convexity angle (°)	T3	17,07 (±7,39)	1,75	32,10	<0,001 *
	C	10,76 (±3,46)	1,05	17,00	
Nasolabial angle (°)	T3	104,11 (±13,20)	66,85	132,95	0,178
	C	101,87 (±10,44)	80,85	121,40	
Mentolabial angle (°)	T3	122,42 (±21,98)	67,25	162,20	0,669
	C	121,26 (±11,46)	95,75	145,80	
Facial inferior third angle (°)	T3	115,09 (±11,67)	97,15	144,45	<0,001 *
	C	101,05 (±8,49)	84,6	118,40	
MAFH/LAFH ratio	T3	1,07 (±0,11)	0,78	1,45	0,006 *
	C	1,01 (±0,09)	0,84	1,24	

*statistically significant difference

Table 2 shows the comparison among T1, T2 and T3 groups, demonstrating the longitudinal behavior of the facial convexity of individuals with isolated Pierre Robin Sequence at different stages of development. The statically significant difference occurred between T1 and T2 groups and also between T1 and T3, demonstrating that facial convexity was higher in the baby phase and there wasn’t a significant variation between the phases of mixed and permanent dentition.

Table 2. Comparison among T1, T2 and T3 groups (Friedman and Tukey´s test)

Variable	**T1** (n=50)	**T2** (n=50)	**T3** (n=50)	**P**
Facial convexity angle (°)	26,77 (±6,81)^{A}	18,27 (±6,46)^{B}	17,07 (±7,39)^{B}	<0,001*

*statistically significant difference
A,B: different letters represent a significant difference between groups

The medical records of all individuals with isolated PRS from this study were analyzed and the percentage of individuals who had orthognathic surgery planned for the rehabilitation treatment was verified. It was verified that of the 50 individuals in the study, 11 performed or will perform orthognathic surgery to correct the facial profile and occlusion.

DISCUSSION

One of the most important components of orthodontic diagnosis and rehabilitation treatment plan is the evaluation of the soft tissues of the patients face (Moshkelgosha, 2015). Several methods have been used to evaluate the facial characteristics such as antropometry (Farkas, 1981), cephalometry (Garner, 1974; Roos, 1977) and the use of photographs (Gavan, 1952; Neger, 1959, Ozawa, 2012). The sagittal analysis of soft tissues from photographs allows professionals to quantify the sagittal size and condition of facial soft tissues. These tissues maintain close anatomical relationships with the underlying bone bases and dental arches (Diouf et al., 2015). The advantages of using photography for facial analysis include: low costs, requiring few equipment and being a non-invasive technique (Sforza et al., 2007). In addition, significant correlations were observed between skeletal and soft tissue evaluations (Ferrario et al., 1996; Dimaggio et al., 2007).

Previous studies have also been proposed to evaluate the morphology and facial growth of patients with Pierre Robin sequence. Most of them performed transversal and some longitudinal evaluations using lateral cephlograms (Pruzansky and Richmond, 1954; Pruzansky, 1969; Markovic, 1972; Hotz and Gnoinski, 1982; Figueroa et al.,1991; Laitinen and Ranta, 1992; Laitinen et al., 1997; Vegter et al., 1999; Daskalogiannakis et al., 2001; Hermann, 2003a, 2003b; Suri et al., 2006,

2010; Eriksen et al., 2006; Lu, 2007). Ozawa et al. (2012) used photographs in mixed dentition phase e Chung et al. (2012) computed tomographies. The present study performed a longitudinal evaluation of facial growth using longitudinal photographs of 50 individuals at 3 different ages.

The facial convexity of individuals with isolated PRS evaluated longitudinally demonstrated that these individuals present a great facial convexity when babies, mean of 26.77°, which is decreasing throughout development, mean of 18,27° in the mixed dentition but that it remains accentuated until the permanent dentition phase, mean of 17.07°. The individuals with isolated PRS from the Daskalogiannakis (2001) study that evaluated lateral cephalograms at 3 different ages (at 5.5 years, 10.3 years and 16.9 years, in mean) also demonstrated a decreasing facial convexity throughout development but remained increased during the permanent dentition, mean of 17°. The study by Shen (2012) confirms the findings of some previous studies that suggest that individuals with isolated PRS have a proportionate retrusion of the mandible, resulting in a convex facial profile by early adolescence. These data demonstrate that individuals with isolated PRS have an increased facial convexity throughout their life, when compared to individuals of control groups and also that the evaluation through lateral cephalograms and photographs can be considered similar. Figueroa et al. (1991) reported that the natural respiratory condition improvement which occurs during the first 2 years of life of individuals with PRS is due to the higher rate of mandibular growth associated with slow growth of the tongue. However the normal airway dimensions are also not reached in these individuals. On the other hand, studies demonstrate that individuals with PRS didn't show catch-up growth during the first years of life, although respiratory conditions improved (Eriksen et al., 2006; Filip et al., 2015).

When we compared the facial convexity of individuals with isolated PRS and the control group, both in permanent dentition, the data indicated that the first group has an increased facial convexity, mean of 17.07° and maximum of 32.10°, when compared to the second group with mean of 10.75° and maximum of 17°, being this difference statistically significant. The individuals with isolated PRS 78% had a convexity angle greater than 10.75°, means of the control group. In relation to the maximum value of the convexity angle of the control group, 52% was increased. Ozawa et al (2012) found a mean value for the facial convexity of individuals with isolated PRS in mixed dentition phase of 18° and for the control group a value of

13.4° was obtained, mean values close to the present study. These results demonstrated that individuals with isolated SPR have a greater facial convexity when compared to control groups at different stages of development and that convexity doesn't significantly change their value from the mixed to permanent dentition. The nasolabial and mentolabial angles didn't present a significant difference between the groups evaluated in the present study.

The mean value obtained for the facial anterior third angle was higher for individuals with isolated PRS in the permanent dentition, with a mean of 115.09°, when compared to the control group, mean of 101.05°, demonstrating a lack of chin projection in relation to the maxilla. In the study by Ozawa (2012) the value obtained for the facial anterior third angle was also higher in individuals with isolated PRS, approximately 110.4°, when compared to the control group, 103.5°. This demonstrates, once again, that the facial features of retrognathism are maintained throughout development.

When the ratio between MAFH and LAFH is observed, the data indicate a higher ratio for individuals with isolated PRS, 107, when compared to the control group, 1.01, demonstrating a minor LAFH, possibly due to the mandibular deficiency present in these individuals. Ozawa (2012) obtained results compatible with those of the present study, but in individuals with isolated PRS still in mixed dentition phase.

The present study verified that from the 50 patients with isolated PRS evaluated, 11 of them received a rehabilitative treatment involving orthognathic surgery. This number should be higher if all the patients with indication for the orthognathic surgery have accepted the accomplishment of the same one, once 78% these individuals had a convexity facial angle greater than 10.75° (control group mean) and 52% showed a severe convexity above the maximum value of the control group. However it was found that some patients declined due to fear of orthognathic surgery, others due to acceptance of the current face or desire to simplify the treatment. There was an absence of studies in the literature pointing to the rate of occurrence of orthognathic surgery in patients with Pierre Robin sequence and studies in adulthood. Indeed, we don't have references related to the functional consequences (apnoeas) for these individuals in more advanced adulthood due to the maintenance of mandibular retrognathism. A previous study by Staudt, Gnoinski and Peltomaki (2013) concluded that the upper airway dimensions of individuals with PRS improved over time, with the exception of the oropharyngeal airway, but the

group mean remained at the lower levels of normality described in other studies. There is a need for research investigating the prevalence of obstructive sleep apnoea in adults with PRS.

CONCLUSIONS

It is concluded that individuals with isolated Pierre Robin sequence accompanied longitudinally demonstrated an increased facial convexity in all phases evaluated but that decreased with growth. The facial inferior third angle and the MAFH/LAFH ratio were also increased in the permanent dentition phase when compared to control group, suggesting a lack of chin projection in relation to the maxilla leading to a considerable number of orthognathic surgeries for the correction of maxillomandibular discrepancies. If the catch-up growth occurred at some stage in the growth of these individuals with isolated PRS even though it wasn't enough to match growth to of individuals without the anomaly, maintaining a large percentage of mandibular retrognathism.

ACKNOWLEDGEMENTS

The authors would like to thank all the patients participating in the study and also the multidisciplinary team of HRAC/USP responsible for the rehabilitation of these patients. We also thank the Coordination for the Improvement of Higher Education Personnel (CAPES), Brazil. The authors declare no potential conflicts of interest with respect to the authorship and/or publication of this article.

REFERENCES

Anderson KD, Cole A, Chuo CB, Slator R. 2007. Home management of upper airway obstruction in Pierre Robin sequence using a nasopharyngeal airway. The Cleft palate-craniofacial journal. 44(3):269-273.

Argamaso RV. 1992. Glossopexy for upper airway obstruction in Robin sequence. The Cleft palate-craniofacial journal. 29(3):232-238.

Arnett GW, Bergman RT. 1993. Facial keys to orthodontic diagnosis and treatment planning. Part I. Am J Orthod Dentofacial Orthop. 103:299-312.

Arnett GW, Bergman RT. 1993. Facial keys to orthodontic diagnosis and treatment planning. Part II. Am J Orthod Dentofacial Orthop. 103:395-411.

Bath AP, Bull PD. 1997. Management of upper airway obstruction in Pierre Robin sequence. The Journal of Laryngology & Otology. 111(12):1155-1156.

Becker R, Palm D. 1966. Zur kausalen und formalen genese des Pierre Robin syndrome. Dtsch Zahnarztl Z. 21:1321-38.

Caouette-Laberge L, Bayet B, Larocque Y. 1994. The Pierre Robin sequence: review of 125 cases and evolution of treatment modalities. Plastic and reconstructive surgery. 93(5):934-942.

Chung MT, Levi B, Hyun JS, Lo DD, Montoro DT, Lisiecki J. et al. 2012. Pierre Robin sequence and Treacher Collins hypoplastic mandible comparison using three-dimensional morphometric analysis. The Journal of craniofacial surgery. 23(7Suppl 1):1959

Cohen Jr MM. 1976. The Robin anomalad-its nonspecificity and associated syndromes. Journal of oral surgery (American Dental Association: 1965). 34(7):587-593.

Cohen MM. Syndromology's message for craniofacial biology. 1979. Journal of maxillofacial surgery. 7:89-109.

Cozzi F, Totonelli G, Frediani S, Zani A, Spagnol L, Cozzi DA. 2008. The effect of glossopexy on weight velocity in infants with Pierre Robin syndrome. Journal of pediatric surgery. 43(2):296-298.

Daskalogiannakis J, Ross RB, Tompsom BD. 2001. The mandibular catch-up growth controversy in Pierre Robin sequence. Am J Orthod Dentofacial Orthop. 120:280-285.

Denny A, Amm C. 2005. New technique for airway correction in neonates with severe Pierre Robin sequence. The Journal of pediatrics. 147(1):97-101.

Diewert V. 1979. Correlation between mandibular retrognathia and induction of cleft palate with 6-aminonicotinamide in the rat. Teratology. 19:213-227.

Dimaggio FR, Ciusa V, Sforza C, Ferrario VF. 2007. Photographic soft-tissue profile analysis in children at 6 years of age. American Journal of Orthodontics and Dentofacial Orthopedics. 132(4):475-480.

Diouf JS, Rouré B, Ndiaye M, Badiane A, Diop-Ba K, Ngom PI, Diagne F. 2015. Correlation between sagittal photogrammetric measurements of the soft tissue profile and dental arches measurements. L'Orthodontie francaise. 86(4):303-311.

Edwards JRG, Newall DR. 1985. The Pierre Robin syndrome reassessed in the light of recent research. British journal of plastic surgery. 38(3):339-342.

Elliott MA, Studen-Pavlovich DA, Ranalli DN. 1994. Prevalence of selected pediatric conditions in children with Pierre Robin sequence. Pediatric dentistry. 17(2):106-111.

Eriksen J, Hermann NV, Darvann TA, Kreiborg S. 2006. Early postnatal development of the mandible in children with isolated cleft palate and children with nonsyndromic Robin sequence. Cleft Palate Craniofac J. 43:160-167.

Farkas LG, Munro IR. 1981. Anthropometric of the Head and Face in Medicine. New York: Elscuiez North Holland Inc.

Fernandez-Riveiro P, Smyth-Chamosa E, Suarez-Quintanilla D, Suarez-Cunqueiro M. 2003. Angular photogrammetric analysis of the soft tissue facial profile. Eur J Orthod. 25:393-399.

Ferrario VF, Sforza C, Puleo A, Poggio CE, Schimitz JH. 1995. Three-dimensional facial morphometry and conventional cephalometrics: a correlation study. The International journal of adult orthodontics and orthognathic surgery. 11(4):329-338.

Figueroa AA, Glupker, TJ, Fitz MG, Begole EA. 1991. Mandible, tongue, and airway in Pierre Robin sequence: a longitudinal cephalometric study. Cleft Palate Craniofac J. 28:425-434.

Filip C, Feragen KB, Lemvik JS, Lindberg N, Anderson EM, Rashidi M. et al. 2015. Multidisciplinary aspects of 104 patients with Pierre Robin sequence. The Cleft Palate-Craniofacial Journal. 52(6):732-742.

Freeman MK, Manners JM. 1980. Cor pulmonale and the Pierre Robin anomaly. Anaesthesia. 35(3):282-286.

Garner LFD. 1974. Soft-tissue changes concurrent with orthodontic tooth movement. American journal of orthodontics. 66(4):367-377.

Gavan JA, Washburn SL, Lewis PH. 1952. Photography: an anthropometric tool. American journal of physical anthropology. 10(3):331-354.

Genther DJ, Skinner ML, Bailey PJ, Capone RB, Byrne PJ. 2015. Airway obstruction after lingual frenulectomy in two infants with Pierre-Robin Sequence. International journal of pediatric otorhinolaryngology. 79(9):1592-1594.

Heaf DP, Helms PJ, Dinwiddie R, Matthews DJ. 1982. Nasopharyngeal airways in Pierre Robin syndrome. The Journal of pediatrics. 100(5):698-703.

Hermann NV, Kreiborg S, Darvann TA, Jensen BL, Dahl E, Bolund S. 2003. Craniofacial morphology and growth comparisons in children with Robin Sequence, isolated cleft palate, and unilateral complete cleft lip and palate. The Cleft palate-craniofacial journal. 40(4):373-396.

Hermann NV, Kreiborg S, Darvann TA, Jensen BL, Dahl E, Bolund S. 2003. Early craniofacial morphology and growth in children with nonsyndromic Robin Sequence. The Cleft palate-craniofacial journal. 40(2):131-143.

Hotz M, Gnoinsky W. 1982. Clefts of the secondary palate associated with the "Pierre Robin syndrome". Management by early maxillary orthopedics. Swed Dent J. 15:89-98.

Jones KL, Jones MC, Del Campo M. 2013. Smith's recognizable patterns of human malformation. Elsevier Health Sciences.

Laitinen SH, Heliovaara A, Ranta RE. 1997. Craniofacial morphology in young adults with the Pierre Robin sequence and isolated cleft palate. Acta Odontol Scand. 55:223-228

Laitinen SH, Ranta RE. 1992. Cephalometric measurements in patients with Pierre Robin syndrome and isolated cleft palate. Scandinavian journal of plastic and reconstructive surgery and hand surgery. 26(2):177-183.

Latham RA. 1966. The pathogenesis of cleft palate associated with the Pierre Robin syndrome. An analysis of a seventeen-week human foetus. British journal of plastic surgery. 19:205-214

Legan HL, Burstone CJ. 1980. Soft tissue cephalometric analysis for orthognathic surgery. J Oral Surg. 38:744-751.

Lehman Jr JA .1987. Soft-tissue manifestations of the jaws: diagnosis and treatment. Clin Plast Surg. 14:767-183.

Lu DW, Shi B, Wang HJ, Zheng Q. 2007. The comparative study of craniofacial structural characteristic of individuals with different types of cleft palate. Annals of plastic surgery. 59(4):382-387.

Markovic M. 1972. Growth changes in cases of mandibular micrognatha. Transactions. European Orthodontic Society.1:133.

Monasterio FO, Drucker M, Molina F, Ysensa A. 2002. Distraction osteogenesis in Pierre Robin sequence and related respiratory problems in children. Journal of Craniofacial Surgery. 13(1):79-83.

Moshkelgosha V, Fathinejad S, Pakizeh Z, Shamsa M, Golkari A. 2015. Photographic Facial Soft Tissue Analysis by Means of Linear and Angular Measurements in an Adolescent Persian Population. The open dentistry journal. 9:346.

Myer CM, Reed JM, Cotton RT, Willging JP. 1966. Airway management in Pierre Robin sequence. Otolaryngology-Head and Neck Surgery. 118(5):630-635.

Neger M. 1959. A quantitative method for the evaluation of the soft-tissue facial profile. American Journal of Orthodontics. 45(10):738-751.

Olney AH, Kolodziej P. MacDonald, MR, Schaefer GB. 1997. Robin sequence. Ear, nose, & throat jornal. 76(9):620.

Ozawa TO, Oliveira LGF, Lorenzoni DC, Silva Filho OG. 2010. Analisis oclusal en pacientes con secuencia de Robin aislada en la dentición mixta. Revista española de ortodoncia. 40:159-168.

Ozawa TO, Lorenzoni DC, Oliveira LGF, Silva Filho OG. 2012. Facial profile evaluation of isolated Pierre Robin Sequence. The Cleft Palate-Craniofacial Journal. 49(5):546-552.

Pasyayan HM, Lewis MB. 1984. Clinical experience with the Robin sequence. Cleft Palate J. 21(4):270-6.

Poswillo D. 1968. The etiology and surgery of cleft palate with micrognathia. Annals of the Royal College of Surgeons of England. 43(2):61.

Poswillo D. 1988. The etiology and pathogenesis of craniofacial deformity. Development. 103:207-212.

Pruzansky S, Richmond JB. 1954. Growth of mandible in infants with micrognathia. Am J Dis Child. 88:29-42.

Pruzansky S. 1969. Not all dwarfed mandibles are alike. Birth Defects. 5:120-129.

Rintala A, Ranta R, Stegars T. 1984. On the pathogenesis of cleft palate in the Pierre Robin syndrome. Scandinavian Journal of Plastic and Reconstructive Surgery and Hand Surgery. 18(2):237-240.

Roos N. 1977. Soft-tissue profile changes in Class II treatment. American journal of orthodontics. 72(2):165-175.

Scheideman GB, Bell WH, Legan HL, Finn RA, Reisch, JS. 1980. Cephalometric analysis of dentofacial normals**.** Am J Orthod. 78:404-420.

Schubert J, Jahn H, Berginski M. 2005. Experimental aspects of the pathogenesis of Robin sequence. Cleft Palate Craniofac J. 42:372-376.

Sforza C, Dimaggio FR, Dellavia C, Grandi G, Ferrario VF. 2007. Two-dimensional vs three-dimensional assessment of soft tissue facial profile: a non invasive study in 6-year-old healthy children. Minerva Stomatol. 56:253-265.

Shen YF, Vargervik, K, Oberoi S, Chigurupati R. 2012. Facial skeletal morphology in growing children with Pierre Robin sequence. The Cleft Palate-Craniofacial Journal. 49(5):553-560.

Staudt CB, Gnoinski WM, Peltomaki T. 2013. Upper airway changes in Pierre Robin sequence from childhood to adulthood. Orthodontics & craniofacial research. 16(4):202-213.

Suri S, Ross RB, Tompsom BD. 2006. Mandibular morphology and growth with and without hypodontia in subjects with Pierre Robin sequence. American journal of orthodontics and dentofacial orthopedics. 130(1):37-46.

Vegter F, Hage JJ, Mulder JW. 1999. Pierre Robin syndrome: mandibular growth during the first year of life. Annals of plastic surgery. 42(2):154-157.

Vig KWL. 1990. Orthodontic considerations applied to craniofacial dysmorphology. The Cleft Palate-Craniofacial Journal. 27(2):141-145.

Wagener S, Rayatt SS, Tatman AJ, Gornall P, Slator R. 2003. Management of infants with Pierre Robin sequence. The Cleft palate-craniofacial journal. 40(2):180-185.

Wolford LM, Hilliard FH. 1981. The surgical-orthodontic correction of vertical dentofacial deformities. J Oral Surg. 39:883-897.

4 Final Considerations

4 FINAL CONSIDERATIONS

It is concluded that individuals with isolated Pierre Robin sequence accompanied longitudinally demonstrated an increased facial convexity in all phases evaluated but that decreased with growth. The facial inferior third angle and the MAFH/LAFH ratio were also increased in the permanent dentition phase when compared to control group, suggesting a lack of chin projection in relation to the maxilla leading to a considerable number of orthognathic surgeries for the correction of maxillomandibular discrepancies. If the catch-up growth occurred at some stage in the growth of these individuals with isolated PRS even though it wasn’t enough to match growth to of individuals without the anomaly, maintaining a large percentage of mandibular retrognathism.

References

REFERENCES

ANDERSON, K. D., COLE, A., CHUO, C. B., SLATOR, R. Home management of upper airway obstruction in Pierre Robin sequence using a nasopharyngeal airway. **The Cleft palate-craniofacial journal**, v. 44, n. 3, p. 269-273, 2007.

ARGAMASO, R. V. Glossopexy for upper airway obstruction in Robin sequence. **The Cleft palate-craniofacial journal**, v. 29, n. 3, p. 232-238, 1992.

ARNETT, G. W., BERGMAN, R. T. Facial keys to orthodontic diagnosis and treatment planning. Part I. **Am J Orthod Dentofacial Orthop**. v. 103, p.299-312, 1993.

ARNETT, G. W., BERGMAN, R. T. Facial keys to orthodontic diagnosis and treatment planning. Part II. **Am J Orthod Dentofacial Orthop**. v.103, p. 395-411, 1993.

BATH, A. P.; BULL, P. D. Management of upper airway obstruction in Pierre Robin sequence. **The Journal of Laryngology & Otology**, v. 111, n. 12, p. 1155-1156, 1997.

BECKER, R.; PALM, D. Zur kausalen und formalen genese des Pierre Robin syndrome. **Dtsch Zahnarztl Z**, v. 21, p. 1321-38, 1966.

BUSH, P.G.; WILLIAMS, A,J. Incidence of Robin anomalad (Pierre Robin syndrome). **Br J Plast Surg**. v. 36, p. 434-7, 1983.

BURSTONE, C. J. The integumental profile. **Am J Orthod.** v. 44, p. 1-25, 1958.

BÜTOW, K.W.; HOOGENDIJK, C.F.; ZWAHLEN, R.A. Pierre Robin sequence: appearances and 25 years of experience with an innovative treatment protocol. **Journal of pediatric surgery**, v. 44, n. 11, p. 2112-2118, 2009.

CAOUETTE-LABERGE, L.; BAYET, B.; LAROCQUE, Y. The Pierre Robin sequence: review of 125 cases and evolution of treatment modalities. **Plastic and reconstructive surgery**, v. 93, n. 5, p. 934-942, 1994.

CAREY, J. C.; FINEMAN, R. M.; ZITER, F. A. The Robin sequence as a consequence of malformation, dysplasia, and neuromuscular syndromes. **The Journal of pediatrics**, v. 101, n. 5, p. 858-864, 1982.

CHUNG, M. T., LEVI, B., HYUN, J. S., LO, D. D., MONTORO, D. T., LISIECKI, J. et al. Pierre Robin sequence and Treacher Collins hypoplastic mandible comparison using three-dimensional morphometric analysis. **The Journal of craniofacial surgery**, v. 23, n. 7 Suppl 1, p. 1959, 2012.

COHEN JR, M. M. The Robin anomalad-its nonspecificity and associated syndromes. **Journal of oral surgery (American Dental Association: 1965)**, v. 34, n. 7, p. 587-593, 1976.

COHEN, M. M. Syndromology's message for craniofacial biology. **Journal of maxillofacial surgery**, v. 7, p. 89-109, 1979

COCKE JR, W. Experimental production of micrognathia and glossoptosis associated with cleft palate (Pierre Robin syndrome). **Plastic and reconstructive surgery**, v. 38, n. 5, p. 395-403, 1966.

COZZI, F., TOTONELLI, G., FREDIANI, S., ZANI, A., SPAGNOL, L., COZZI, D. A. The effect of glossopexy on weight velocity in infants with Pierre Robin syndrome. **Journal of pediatric surgery**, v. 43, n. 2, p. 296-298, 2008.

DASKALOGIANNAKIS, J., ROSS, R. B., TOMPSOM, B. D. The mandibular catch-up growth controversy in Pierre Robin sequence. **Am J Orthod Dentofacial Orthop.** v. 120, p. 280-285, 2001.

DENNY, A.; AMM, C. New technique for airway correction in neonates with severe Pierre Robin sequence. **The Journal of pediatrics**, v. 147, n. 1, p. 97-101, 2005.

DIEWERT V. Correlation between mandibular retrognathia and induction of cleft palate with 6-aminonicotinamide in the rat. **Teratology.** v. 19, p. 213-227, 1979.

DIMAGGIO, F. R., CIUSA, V. SFORZA, C., FERRARIO, V. F.. Photographic soft-tissue profile analysis in children at 6 years of age. **American Journal of Orthodontics and Dentofacial Orthopedics**, v. 132, n. 4, p. 475-480, 2007.

DIOUF, J. S., ROURÉ, B., NDIAYE, M., BADIANE, A., DIOP-BA, K, NGOM, P. I, DIAGNE, F. Correlation between sagittal photogrammetric measurements of the soft tissue profile and dental arches measurements. **L'Orthodontie francaise**, v. 86, n. 4, p. 303-311, 2015.

EDWARDS, J. R. G.; NEWALL, D. R. The Pierre Robin syndrome reassessed in the light of recent research. **British journal of plastic surgery**, v. 38, n. 3, p. 339-342, 1985.

ELLIOTT, M. A.; STUDEN-PAVLOVICH, D. A.; RANALLI, D. N. Prevalence of selected pediatric conditions in children with Pierre Robin sequence. **Pediatric dentistry**, v. 17, n. 2, p. 106-111, 1994.

ERIKSEN, J., HERMANN, N. V., DARVANN, T. A., KREIBORG, S. Early postnatal development of the mandible in children with isolated cleft palate and children with nonsyndromic Robin sequence. **Cleft Palate Craniofac J***.* v. 43, p. 160-167, 2006.

EVANS, Adele Karen et al. Robin sequence: a retrospective review of 115 patients. **International journal of pediatric otorhinolaryngology**, v. 70, n. 6, p. 973-980, 2006.

FARKAS, L. G.; MUNRO, I. R. Anthropometric of the Head and Face in Medicine. **New York: Elscuiez North Holland Inc**, 1981.

FERNANDEZ-RIVEIRO, P., SMYTH-CHAMOSA, E., SUAREZ-QUINTANILLA, D., SUAREZ-CUNQUEIRO, M. Angular photogrammetric analysis of the soft tissue facial profile. **Eur J Orthod.** v. 25, p. 393-399, 2003.

FERRARIO, V. F., SFORZA, C., PULEO, A., POGGIO, C. E., SCHIMITZ, J. H. Three-dimensional facial morphometry and conventional cephalometrics: a correlation study. **The International journal of adult orthodontics and orthognathic surgery**, v. 11, n. 4, p. 329-338, 1995.

FIGUEROA, A. A., GLUPKER, T. J., FITZ, M. G., BEGOLE, E. A. Mandible, tongue, and airway in Pierre Robin sequence: a longitudinal cephalometric study. **Cleft Palate Craniofac J.** *v.* 28, p. 425-434, 1991.

FILIP, C., FERAGEN, K. B., LEMVIK, J. S., LINDBERG, N., ANDERSON, E. M., RASHIDI, M. et al. Multidisciplinary aspects of 104 patients with Pierre Robin sequence. **The Cleft Palate-Craniofacial Journal**, v. 52, n. 6, p. 732-742, 2015.

FREEMAN, M. K.; MANNERS, J. M. Cor pulmonale and the Pierre Robin anomaly. **Anaesthesia**, v. 35, n. 3, p. 282-286, 1980.

GARNER, L. F. D. Soft-tissue changes concurrent with orthodontic tooth movement. **American journal of orthodontics**, v. 66, n. 4, p. 367-377, 1974.

GAVAN, J. A.; WASHBURN, S. L.; LEWIS, P. H. Photography: an anthropometric tool. **American journal of physical anthropology**, v. 10, n. 3, p. 331-354, 1952.

GENTHER, D. J; SKINNER, M. L.; BAILEY, P. J. CAPONE, R. B.; BYRNE, P. J. Airway obstruction after lingual frenulectomy in two infants with Pierre-Robin Sequence. **International journal of pediatric otorhinolaryngology**, v. 79, n. 9, p. 1592-1594, 2015.

HEAF, D. P., HELMS, P. J., DINWIDDIE, R., MATTHEWS, D. J. Nasopharyngeal airways in Pierre Robin syndrome. **The Journal of pediatrics**, v. 100, n. 5, p. 698-703, 1982.

HERMANN, N. V, KREIBORG, S., DARVANN, T. A, JENSEN, B. L., DAHL, E., BOLUND, S. Craniofacial morphology and growth comparisons in children with Robin Sequence, isolated cleft palate, and unilateral complete cleft lip and palate. **The Cleft palate-craniofacial journal**, v. 40, n. 4, p. 373-396, 2003.

HERMANN, N. V, KREIBORG, S., DARVANN, T. A, JENSEN, B. L., DAHL, E., BOLUND, S. Early craniofacial morphology and growth in children with nonsyndromic Robin Sequence. **The Cleft palate-craniofacial journal**, v. 40, n. 2, p. 131-143, 2003.

HOTZ M., GNOINSKY W. Clefts of the secondary palate associated with the "Pierre Robin syndrome". Management by early maxillary orthopedics. **Swed Dent J.** v. 15, p. 89-98, 1982.

JAKOBSEN, L. P., ULMANN, R., CHRISTENSEN, S. B., JENSEN, K. E., MOLSTED, K., HENRIKSEN, K. F. et al. Pierre Robin sequence may be caused by dysregulation of SOX9 and KCNJ2. **Journal of medical genetics**, v. 44, n. 6, p. 381-386, 2007.

JONES, K. L.; JONES, M. C.; DEL CAMPO, M.. **Smith's recognizable patterns of human malformation**. Elsevier Health Sciences, 2013.

LAITINEN, S. H., HELIOVAARA, A., RANTA, R. E. Craniofacial morphology in young adults with the Pierre Robin sequence and isolated cleft palate. **Acta Odontol Scand.** v. 55, p. 223-228, 1997.

LAITINEN, S. H.; RANTA, R. E. Cephalometric measurements in patients with Pierre Robin syndrome and isolated cleft palate. **Scandinavian journal of plastic and reconstructive surgery and hand surgery**, v. 26, n. 2, p. 177-183, 1992.

LATHAM, R. A. The pathogenesis of cleft palate associated with the Pierre Robin syndrome. An analysis of a seventeen-week human foetus. **British journal of plastic surgery**, v. 19, p. 205-214, 1966.

LEGAN, H. L., BUSTONE, C. J. Soft tissue cephalometric analysis for orthognathic surgery. **J Oral Surg.** v. 38, p.744-751, 1980.

LEHMAN JR, J. A. Soft-tissue manifestations of the jaws: diagnosis and treatment. **Clin Plast Surg.** v.14, p.767-183, 1987.

LU, D. W., SHI, B. WANG, H.J., ZHENG, Q.. The comparative study of craniofacial structural characteristic of individuals with different types of cleft palate. **Annals of plastic surgery**, v. 59, n. 4, p. 382-387, 2007.

MARKOVIC, M. Growth changes in cases of mandibular micrognatha. **Transactions. European Orthodontic Society**, p. 133, 1972.

MARQUES, I. L., SOUSA T. V., CARNEIRO, A. F. PERES, S. P. D., BARBIERI, M. A, BETTIOL, H. Robin sequence: a single treatment protocol. **Jornal de pediatria**, v. 81, n. 1, p. 14-22, 2005.

MONASTERIO, F. O., DRUCKER, M., MOLINA, F., YSENZA, A. Distraction osteogenesis in Pierre Robin sequence and related respiratory problems in children. **Journal of Craniofacial Surgery**, v. 13, n. 1, p. 79-83, 2002.

MOSHKELGOSHA, V., FATHINEJAD, S., PAKIZEH, Z., SHAMSA, M., GOLKARI, A. Photographic Facial Soft Tissue Analysis by Means of Linear and Angular Measurements in an Adolescent Persian Population. **The open dentistry journal**, v. 9, p. 346, 2015.

MYER, C. M., REED, J. M., COTTON, R. T., WILLGING, J. P. Airway management in Pierre Robin sequence. **Otolaryngology-Head and Neck Surgery**, v. 118, n. 5, p. 630-635, 1996.

NEGER, M. A quantitative method for the evaluation of the soft-tissue facial profile. **American Journal of Orthodontics**, v. 45, n. 10, p. 738-751, 1959.

OLNEY, A. H., KOLODZIEJ, P. MacDONALD, M. R., SCHAEFER, G. B. Robin sequence. **Ear, nose, & throat journal**, v. 76, n. 9, p. 620, 1997.

OZAWA, T. O.; OLIVEIRA, L. G. F.; LORENZONI, D. C. ; SILVA FILHO, O.G. Analisis oclusal en pacientes con secuencia de Robin aislada en la dentición mixta. **Revista española de ortodoncia**, v. 40, p. 159-168, 2010.

OZAWA, T.O, LORENZONI, D. C.; OLIVEIRA, L. G. F.; SILVA FILHO, O.G.. Facial profile evaluation of isolated Pierre Robin Sequence. **The Cleft Palate-Craniofacial Journal**, v. 49, n. 5, p. 546-552, 2012.

PASYAYAN, H.M.; LEWIS, M.B. Clinical experience with the Robin sequence. **Cleft Palate J**, v. 21, n. 4, p. 270-6, 1984.

POSWILLO, D. The etiology and surgery of cleft palate with micrognathia. **Annals of the Royal College of Surgeons of England**, v. 43, n. 2, p. 61, 1968.

POSWILLO, D. The etiology and pathogenesis of craniofacial deformity. **Development**, v. 103, n. Supplement, p. 207-212, 1988.

PRUZANSKY, S., RICHMOND, J. B. Growth of mandible in infants with micrognathia. **Am J Dis Child.** v.88, p.29-42, 1954.

PRUZANSKY, S. Not all dwarfed mandibles are alike. **Birth Defects**. v.5, p.120-129, 1969.

RINTALA, A.; RANTA, R.; STEGARS, T. On the pathogenesis of cleft palate in the Pierre Robin syndrome. **Scandinavian Journal of Plastic and Reconstructive Surgery and Hand Surgery**, v. 18, n. 2, p. 237-240, 1984.

ROBIN, P. La glossoptose. Son diagnostic, ses conséquences, son traitement. **J Med Paris**, v. 12, p. 235-257, 1923.

ROBIN, P. Glossoptosis due to atresia and hypotrophy of the mandible. **American Journal of Diseases of Children**, v. 48, n. 3, p. 541-547, 1934.

ROOS, N. Soft-tissue profile changes in Class II treatment. **American journal of orthodontics**, v. 72, n. 2, p. 165-175, 1977.

SCHEIDEMAN, G. B, BELL, W. H, LEGAN, H. L, FINN, R. A, Reisch, J. S. Cephalometric analysis of dentofacial normals. **Am J Orthod**. v.78, p.404-420, 1980.

SCHUBERT J., JAHN H., BERGINSKI M. Experimental aspects of the pathogenesis of Robin sequence. **Cleft Palate Craniofac J.** v.42, p.372-376, 2005.

SELVI, R., MUKUNDA PRIYANKA, A. Role of SOX9 in the etiology of Pierre-Robin Syndrome. **Iranian journal of basic medical sciences**, v. 16, n. 5, p. 700, 2013.

SFORZA, C., DIMAGGIO, F. R, DELLAVIA, C., GRANDI, G., FERRARIO, V. F. Two-dimensional vs three-dimensional assessment of soft tissue facial profile: a non invasive study in 6-year-old healthy children. **Minerva Stomatol.** v.56, p.253-265, 2007.

SHEN, Y F., VARGERVIK, K., OBEROI, S., CHIGURUPATI, R. Facial skeletal morphology in growing children with Pierre Robin sequence. **The Cleft Palate-Craniofacial Journal**, v. 49, n. 5, p. 553-560, 2012.

SINGER, L., SIDOTI, E. J. Pediatric management of Robin sequence. **The Cleft palate-craniofacial journal**, v. 29, n. 3, p. 220-223, 1992.

SURI, S.; ROSS, R. B.; TOMPSON, B. D. Craniofacial morphology and adolescent facial growth in Pierre Robin sequence.**American Journal of Orthodontics and Dentofacial Orthopedics**, v. 137, n. 6, p. 763-774, 2010.

STAUDT, C. B.; GNOINSKI, W. M.; PELTOMÄKI, T. Upper airway changes in Pierre Robin sequence from childhood to adulthood. **Orthodontics & craniofacial research**, v. 16, n. 4, p. 202-213, 2013.

SURI, S.; ROSS, R. B.; TOMPSON, B. D. Mandibular morphology and growth with and without hypodontia in subjects with Pierre Robin sequence. **American journal of orthodontics and dentofacial orthopedics**, v. 130, n. 1, p. 37-46. e1, 2006.

VEGTER, F.; HAGE, J. J.; MULDER, J. W. Pierre Robin syndrome: mandibular growth during the first year of life. **Annals of plastic surgery**, v. 42, n. 2, p. 154-157, 1999.

VIG, K. W. L. Orthodontic considerations applied to craniofacial dysmorphology. **The Cleft Palate-Craniofacial Journal**, v. 27, n. 2, p. 141-145, 1990.

WAGENER, S., RAYATT, S. S., TATMAN, A. J., GORNALL, P., SLATOR, R. Management of infants with Pierre Robin sequence.**The Cleft palate-craniofacial journal**, v. 40, n. 2, p. 180-185, 2003.

WOLFORD, L. M, HILLIARD, F. H. The surgical-orthodontic correction of vertical dentofacial deformities. **J Oral Surg.** v.39, p.883-897, 1981.

ANNEXES

ANNEX A – Guidelines for Journal of Dental Research

The *Journal of Dental Research (JDR)* adheres to the CSE (8th Edition) editorial style. All submitted manuscripts should be formatted in this style

The *Journal of Dental Research* (*JDR*) is a peer-reviewed scientific journal dedicated to the dissemination of new knowledge and information on all science relevant to dentistry and to the oral cavity and associated structures in health and disease. The *Journal of Dental Research*'s primary readership consists of oral, dental and craniofacial researchers, clinical scientists, hard-tissue scientists, dentists, dental educators, and oral and dental policy-makers. The *Journal* is published monthly, allowing for frequent dissemination of its leading content. The *Journal of Dental Research* also offers OnlineFirst, by which forthcoming articles are published online before they are scheduled to appear in print.

Authors of all types of articles should be aware of the following guidelines when submitting to JDR.

ONLINE SUBMISSION

Submissions to the *Journal of Dental Research* are only accepted for consideration via the SAGETrack online manuscript submission site at http://mc.manuscriptcentral.com/jdr. Authors who do not have an active account within the system are required to create a new account by clicking, "Create Account," on the log-in page. The system will prompt the authors through a step by step process to create their account. Once created authors can submit their manuscripts by entering their "Author Center" and clicking the button by "Click Here to Submit a New Manuscript."

If any difficulty is encountered at anytime during the account creation or submission process, authors are encouraged to contact the *Journal of Dental Research* Publications Coordinator, Kourtney Skinner, at kskinner@iadr.org

MANUSCRIPT REQUIREMENTS BY TYPE

The *Journal of Dental Research* accepts the following types of manuscripts for consideration:

Original Research Reports: These manuscripts are based on clinical, biological, and biomaterials and bioengineering subject matter. Manuscripts submitted as research reports have a limit of 3,200 words (including introduction, materials, methods results, discussion and; excluding abstracts , acknowledgments, figure legends and references); a total of 5 figures or tables; 40 references; and must contain a 300 word abstract.

Letters to the Editor*: Letters must include evidence to support a position about the scientific or editorial content of the *JDR*. Manuscripts submitted as a letter to editor have a limit of 250 words. No figures or tables are permitted. Letters on published articles must be submitted within 3 months of the article's print publication date.

Guest Editorials*: A clear and substantiated position on issues of interest to the readership community can be considered for this manuscript type. Guest Editorials are limited to 1,000 words. No figures or tables are permitted.

Discovery!: Essays that explore seminal events and creative advances in the development of dental research are considered for the "Discovery!" section of the

journal. Manuscripts submitted for "Discovery!" have a limit of 2,500 words and a total of 2 figures or tables. Manuscripts are to be submitted by invitation only.

Critical Reviews in Oral Biology & Medicine: These manuscripts should summarize information that is well known and emphasize recent developments over the last three years with a prominent focus on critical issues and concepts that add a sense of excitement to the topic being discussed. Manuscripts are to be submitted by invitation only. Authors interested in submitting to this section must contact the Editor of *Critical Reviews in Oral Biology & Medicine,* Dr. Dana Graves, at dgraves@iadr.org for submission approval and instructions. Manuscripts submitted as Critical Reviews have a limit of 4,000 words; a total of 6 figures or tables; 60 references; and must contain a 300 word abstract.

Additional Instructions for Critical Reviews:

-It is important to include several illustrations or diagrams to enhance clarity. Manuscripts that lack figures or diagrams typically receive a low priority score.

-Summarize important concepts in tables or flow charts or show critical data in the form of figures. NOTE: authors will need to obtain permission to reproduce a previously published figure or table.

-Due to the broad readership, abbreviations commonly recognized in one field may not be readily apparent to those in a different field. Keep abbreviation use to a minimum.

-The cover page, abstract, text, summary, figure legends, and tables should be combined into a single Word document. Figures should be submitted as a separate document.

-To view examples of recent Critical Reviews in the Journal, please click the following links: http://jdr.iadrjournals.org/cgi/content/full/86/9/800 or http://jdr.iadrjournals.org/cgi/content/full/85/7/584

***Brief responses to Letters to the Editor or Guest Editorials will be solicited for concurrent publication.**

Clinical Reviews (formerly Concise Reviews): These manuscripts are generally systematic reviews of topics of high clinical relevance to oral, dental and craniofacial research. Meta-analyses should be considered only when sufficient numbers of studies are available. Manuscripts that include investigations of limited study quality of under-studied areas are typically not acceptable as topics for a clinical review. Although some systematic reviews may be well done, those that receive highest scientific priority will only be considered given the very limited space allowed for these reviews in the journal.

Manuscripts submitted as Clinical Reviews have a strict limit of 4,000 words (including introduction, materials, methods results, discussion and; excluding abstracts , acknowledgments, figure legends and references); a total of 6 figures or tables; up to a maximum of 60 references; and must contain a 300 word abstract. Manuscripts above the 4,000 word/6 figure or table limit may use supplemental appendices for other supporting information that would be available online only.

Additional Instructions for Clinical Reviews:

-It is important to include illustrations or diagrams to enhance clarity. Manuscripts that lack figures or diagrams typically receive a low priority score.

-Summarize important concepts in tables or flow charts or show critical data in the form of figures. NOTE: authors will need to obtain permission to reproduce a previously published figure or table.

-Due to the broad readership, abbreviations commonly recognized in one field may not be readily apparent to those in a different field. Keep abbreviation use to a minimum.

-The cover page, abstract, text, summary, figure legends, and table(s) should be combined into a single Word document. Figures should be submitted as a separate document.

-To view examples of recent Clinical Reviews in the Journal, please click the following links: http://jdr.sagepub.com/content/90/3/304.full.pdf+html or http://jdr.sagepub.com/content/90/5/573.full.pdf+html

All submissions must include a title page and be accompanied by a cover letter and list of suggested reviewers. Cover letters should certify the research is original, not under publication consideration elsewhere, and free of conflict of interest. Title pages should include: abstract word count, total word count (Abstract to Acknowledgments), total number of tables/figures, number of references, and a minimum of 6 keywords. Keywords cannot be words that have been included in the manuscript title. Key words should be selected from Medical Subject Headings (MeSH) to be used for indexing of articles. See: http://www.nlm.nih.gov/mesh/MBrowser.html for information on the selection of key words.

Please submit the names and email addresses of four preferred reviewers when prompted by the SAGETrack system. Preferred reviewers cannot be colleagues at the contributors' institution or present or former collaborators.

TITLES

Titles can consist of a maximum of 75 characters (including spaces). Titles do not normally include numbers, acronyms, abbreviations or punctuation. The title should include sufficient detail for indexing purposes but be general enough for readers outside the field to appreciate what the paper is about.

ACKNOWLEDGMENTS

Authors are required to report all sources of support for their project or study, including but not limited to: grant funds, commercial sources, funds from a contributors' institution. Do not refer to a study being "partially funded by the cited sources." Consultancies and funds paid directly to investigators must also be listed. Authors are required to specify during the submission process if their paper received funding from NIH, NIDCR, or any other NIH Institute or Center and provide the grant number. To comply with the NIH Public Access Mandate, for qualifying NIH-funded papers, the *Journal of Dental Research* will deposit the final, copyedited paper to PubMed Central on behalf of the authors.

Any perceived or actual conflicts of interest need to be identified in the acknowledgments section. The *JDR* abides by the International Committee of Medical Journal Editors guidelines for the Ethical Considerations in the Conduct and Report of Research (http://www.icmje.org). Authors are requested to include this information in the acknowledgments section and the corresponding author must confirm that all co-authors have reported any potential conflicts.

FIGURE AND TABLE REQUIREMENTS

These guidelines are intended to aid authors in providing figures that will reproduce well in both print and online media. Submitting digital image files that conform to these guidelines will prevent delays in the review and publication processes, and maximize the published quality of your figures.

Figure Types

JDR figures can fall into one of three categories: **Continuous-tone images**, **Line-art images**, and **Combination images.** Each image type has specific requirements in terms of the resolution needed for publication and the file types best suited for the figure. See the following panels for examples and requirements.

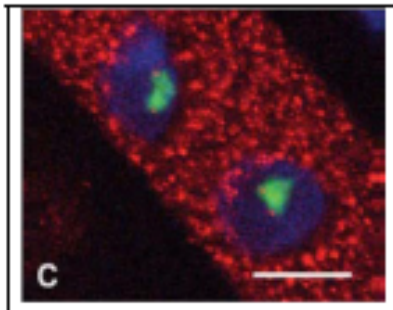	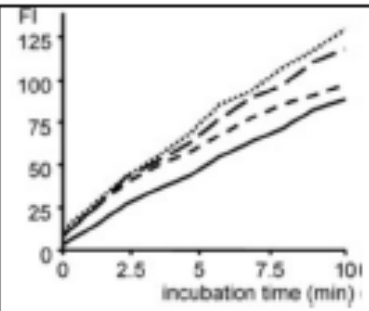	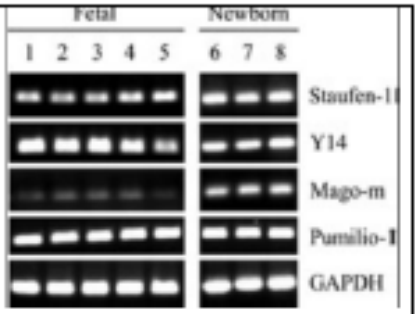
Continuous-tone Image Minimum resolution: 300dpi. Preferred File Formats: TIFF, Bitmap.	**Line-art Image** Minimum resolution: 800dpi. Preferred File Formats: EPS, PowerPoint, Illustrator.	**Combination Image** Minimum resolution: 800dpi. Preferred File Formats: PDF, EPS, PowerPoint, Illustrator, InDesign.

Resolution

In order for a figure to be used in publication, its Digital Image File must have the required resolution when it is created. The resolution cannot be raised *after* the original image is made. Attempting to do so (for example, with Adobe Photoshop's© *"Image Size"* command) results in the addition of artificial pixels that distort the image and lower its sharpness. The figures on the right show an example of this reduced sharpness.

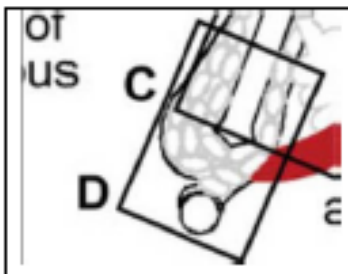	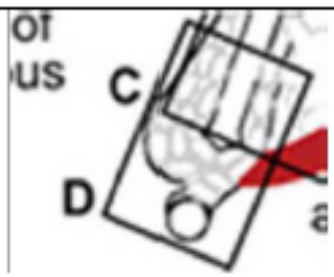
Line-art supplied at high resolution (1000dpi).	Using "Image Size" to go from 300 DPI to 1000 DPI.

Fonts

Limit fonts used in any figure to Times, Times New Roman, Arial, Frutiger, and Sabon. Other fonts cannot be guaranteed to reproduce properly.

Files containing figures and tables should be clearly labeled to indicate their placement in the text or appendix. Tables should be viewable in a portrait view. Tables that are created in a landscape view are more suitable for an appendix.

If the online version is in color and the printed version in black and white, please submit separate files for each version. Figures should be identical except in color or grayscale. The cost of color figures in the print version will be borne by the authors. Rates for color reproduction are $300 per initial page of color and $150 for each additional page of color. However, there are no charges for figures and diagrams printed in black and white. Color figures many be included in the online version of *JDR* with no extra charges.

REFERENCES

The *Journal of Dental Research (JDR)* adheres to the CSE (8th Edition) editorial style. All submitted manuscripts should be formatted in this style: http://www.scientificstyleandformat.org/Tools/SSF-Citation-Quick-Guide.html.

SUPPLEMENTAL FILES

Additional supporting data may be referenced as a supplemental appendix for publication online only. All supplemental appendix files must be submitted with the manuscript for review. Supplementary files will be subjected to peer-review alongside the article.

Supplementary files will be uploaded as supplied. They will not be checked for accuracy, copyedited, typeset or proofread. The responsibility for scientific accuracy and file functionality remains with the authors. A disclaimer will be displayed to this effect with any supplementary material published. Supplemental files may include additional figures or tables that exceed the Journal's limit. Material intended for the supplemental appendix must have "supplemental" or "appendix" in the file name upon upload. When formatting your supplemental files, please follow these instructions:

- Authors should provide a single Word file with all Appendix content. Figures can be copied in or supplied separately.
- The Appendix should include the title of the article and all authors. Page numbers are recommended.
- Figures and Tables should be labeled Appendix Figure/Table 1, Appendix Figure/Table 2, etc. Avoid labeling as S1, S2, and so forth.
- All table footnotes and figure legends should be included.
- Preferably, authors shouldn't label separate parts as "Appendix 1", "Appendix 2", etc.;

just use section heads as in a regular article.

Language Editing: Manuscripts submitted for publication consideration should be written in English. Prior to submission, if a manuscript would benefit from professional editing, authors may consider using a language-editing service. Suggestions for this type of service can be found at www.iadr.org/EditingServices. The *Journal of Dental Research* does not take responsibility for, or endorse these services, and their use has no bearing on acceptance of a manuscript for publication.

GENERAL INFORMATION FOR AUTHORS SUBMITTING A MANUSCRIPT

PRIOR PUBLICATION

Manuscripts submitted to the *Journal of Dental Research* are accepted for consideration giving the understanding that it contains original material that has not been submitted for publication or has been previously published elsewhere. Any form of publication other than an abstract only constitutes prior publication.

ICMJE COMPLIANCE STATEMENT

Manuscript submission guidelines for the *Journal of Dental Research* follow the "Uniform Requirements for Manuscripts Submitted to Biomedical Journals" set forth by the International Committee of Medical Journal Editors (ICMJE). For additional information please visit the ICMJE web site at http://www.icmje.org/.

CONSORT 2010 CHECKLIST COMPLETION RANDOMIZED CLINICAL TRIALS POLICY

Manuscripts reporting a randomized clinical trial are required to follow the CONSORT guidelines. The Journal requires authors of pre-clinical animal studies submit with their manuscript the Animal Research: Reporting In Vivo Experiments (ARRIVE) guidelines. Authors of human observations studies in epidemiology are required to review and submit a STROBE statement. When uploaded to the SAGETrack system, any checklists completed by authors should be given a supplementary file designation. Authors who have completed the ARRIVE guidelines or STROBE checklist should include as the last sentence in the Methods section a sentence stating compliance with the appropriate guidelines/checklist.

Additional guidance on compliance with various research guidelines can be found on the Guideline Information - Enhancing the Quality and Transparency of Health Research: www.equator-network.org.

The CONSORT checklist can be downloaded from:
mc.manuscriptcentral.com/societyimages/jdr/CONSORT+2010+checklist%5b1%5d.doc

The ARRIVE guidelines can be found here:
www.nc3rs.org.uk/downloaddoc.asp?id=1206&page=1357&skin=0

The STROBE checklists can be found here:
www.strobe-statement.org/index.php?id=strobe-home

The *Journal of Dental Research* requires authors to register their clinical trials in a public trials registry. Authors of manuscripts describing such studies are asked to submit the name of the registry and the study registration number prior to publication. Authors are asked to include their clinical trial registration number at the end of their abstracts. In accordance with the aforementioned "Uniform Requirements for Manuscripts Submitted to Biomedical Journals," clinical trials will only be considered for publication if they are registered.

INSTITUTIONAL REVIEW BOARD AND WRITTEN INFORMED CONSENT

For protocols involving the use of human subjects, authors should indicate in their Methods section that subjects' rights have been protected by an appropriate Institutional Review Board and written informed consent was granted from all subjects. When laboratory animals are used, indicate the level of institutional review and assurance that the protocol ensured humane practices.

PUBLIC GENE DATA

Prior to submission, the *Journal of Dental Research* asks that novel gene sequences be deposited in a public database and the accession number provided to the Journal. Authors may want to use the following Journal approved databases:

GenBank: www.ncbi.nlm.nih.gov/Genbank/submit.html

EMBL: www.ebi.ac.uk/embl/Submission/index.html

DDBJ: www.ddbj.nig.ac.jp/index-e.html

Manuscript submissions including microarray data should include the information recommended by the MIAME guidelines in their submission, and/or identify the submission details for the experiments details to one of the publicly available databases such as Array Express or GEO. Information on MIAME, Array Express and GEO can be found by clicking on the corresponding links below:

MIAME: www.mged.org/Workgroups/MIAME/miame.html

ArrayExpress: www.ebi.ac.uk/arrayexpress

GEO: www.ncbi.nlm.nih.gov/geo

OPEN ACCESS COMPLIANCE STATEMENT

Effective April 7, 2008 the National Institutes of Health (NIH) Revised Policy on Enhancing Public Access to Archived Publications Resulting from NIH-Funded Research (Public Access Policy) requires all studies funded by NIH to submit or have submitted for them their final peer-reviewed manuscript upon acceptance for publication to the National Library of Medicine's PubMed Central (PMC) to be made publicly available no later than 12 months after the official date of publication. Only final, copyedited manuscripts are uploaded.

Manuscripts by authors whose work is funded by the Wellcome Trust will be released from access control immediately upon publication. Members of the IADR/AADR will be invoiced $3,800; non-Members will be billed $4,300 for this immediate access. No separate page or color charges will be assessed.

Authors are required to specify during the submission process if their paper received funding from NIH or NIDCR and provide the grant number.

The *Journal of Dental Research* will deposit final, copyedited papers to PubMed Central on behalf of the authors.

DEFINITION OF CONTRIBUTORSHIP IN JDR

As stated in the Uniform Requirements for Manuscripts Submitted to Biomedical Journals, put forth by the ICMJE, the *Journal* considers the following as an accurate definition of contributorship:

Contributors Listed in Acknowledgments

All contributors who do not meet the criteria for authorship should be listed in an acknowledgments section. Examples of those who might be acknowledged include a person who provided purely technical help, writing assistance, or a department chairperson who provided only general support. Editors should ask corresponding authors to declare whether they had assistance with study design, data collection, data analysis, or manuscript preparation. If such assistance was available, the authors should disclose the identity of the individuals who provided this assistance and the entity that supported it in the published article. Financial and material support should also be acknowledged.

Groups of persons who have contributed materially to the paper but whose contributions do not justify authorship may be listed under such headings as "clinical investigators" or "participating investigators," and their function or contribution should be described—for example, "served as scientific advisors," "critically reviewed the study proposal," "collected data," or "provided and cared for study patients." Because readers may infer their endorsement of the data and conclusions, these persons must give written permission to be acknowledged.

CONTRIBUTOR FORMS

All rights to manuscripts will be transferred to the *Journal of Dental Research* upon submission. Submission of a manuscript will constitute each author's agreement that the Journal holds all propriety rights in the manuscript submitted, including all copyrights. Upon acceptance, the corresponding author will be asked to sign a formal transfer of copyright. Only the corresponding author is required to complete a contributor form unless any co-authors are work-for-hire or government employees. If co-authors fall into either of these categories, the corresponding author should contact the editorial office at jdr@iadr.org for additional instruction.

Please note that the *Journal of Dental Research* secures completed contributor forms electronically via the SAGETrack online submission and review system.

Without the completion of the contributor form for all co-authors listed, accepted manuscripts cannot continue into production, delaying publication.

CHARGES ASSOCIATED WITH PUBLICATION

Page Charges
There is a charge of $40 (U.S.) for every printed page in the *Journal of Dental Research*. You will receive an invoice with your page proofs.

Color Figure Charges
The cost of color figures in the print version will be borne by the authors. Rates for color reproduction are $300 per initial page of color and $150 for each additional page of color. However, there are no charges for figures and diagrams printed in black and white. Color figures many be included in the online version of *JDR* with no extra charges.

Reprint Charges
Reprints can be ordered for material printed in the *Journal of Dental Research* and online only appendices. Quantities of reprints can be purchased with the reprint order form sent with page proofs to the contributors. Pre-payment is required for reprints. Visa, MasterCard, American Express and check are all acceptable forms of payment. Authors must pay for color figures in reprints. Reprints will be mailed from 6 to 8 weeks after the article appears in the *Journal*. To contact SAGE for additional information or to order reprints, visit the SAGE site at www.sagepub.com/journalsReprints.nav.

ANNEX B – Approval of the Ethics Committee

USP - HOSPITAL DE REABILITAÇÃO DE ANOMALIAS CRANIOFACIAIS

PARECER CONSUBSTANCIADO DO CEP

DADOS DA EMENDA

Título da Pesquisa: Comportamento longitudinal do crescimento mandibular e facial de pacientes com Sequência de Pierre Robin isolada

Pesquisador: Gabriela Leticia Clavisio Siqueira Machado

Área Temática:

Versão: 3

CAAE: 53785816.4.0000.5441

Instituição Proponente: Hospital de Reabilitação de Anomalias Craniofaciais da USP

Patrocinador Principal: Financiamento Próprio

DADOS DO PARECER

Número do Parecer: 1.869.005

Apresentação do Projeto:

O projeto de Dissertação, de autoria de Gabriela Leticia Clavisio Siqueira Machado sob orientação de Terumi Okada Ozawa retorna ao CEP comunicando algumas alterações. O estudo avaliará a evolução longitudinal do crescimento mandibular e facial de indivíduos com SRi. A amostra deste estudo será composta por 200 fotografias do perfil facial direito de 100 indivíduos. Essas fotografias são parte da documentação ortodôntica do Hospital de Reabilitação de Anomalias Craniofaciais e da Sociedade de Promoção Social do Fissurado Labio Palatal. A principal hipótese é de que os indivíduos com Sequência de Pierre Robin apresentem um crescimento facial e mandibular diferente de indivíduos que não apresentam a anomalia, com deficiência mandibular e um perfil convexo.

Objetivo da Pesquisa:

Avaliar a evolução longitudinal do crescimento mandibular e facial de indivíduos com SPRi.

Avaliação dos Riscos e Benefícios:

Riscos: Não se aplica, por se tratar de uma pesquisa com fonte de dados secundários.

Benefícios (segunda as autoras):

Por se tratar de um estudo com fonte de dados secundários, os benefícios serão indiretos e não apenas

Endereço: Rua Silvio Marchione, 3-20
Bairro: Vila Nova Cidade Universitária **CEP:** 17.012-900
UF: SP **Município:** BAURU
Telefone: (14)3235-8421 **Fax:** (14)3234-7818 **E-mail:** uep_projeto@centrinho.usp.br

para os pacientes cujas fotografias serão utilizadas e sim para toda a comunidade, incluindo outros indivíduos que possuem a Sequência de Pierre Robin, uma vez que esta pesquisa visa avaliar longitudinalmente o crescimento dos mesmos e mais informações serão obtidas sobre este quadro. Isso será importante para avaliação de possíveis protocolos de tratamento para estes indivíduos, a partir da verificação da condição de crescimento dos mesmos (adequado ou não). Esta pesquisa também contribuirá de forma significa com a literatura sobre esta temática, assim que sua publicação for realizada.

Comentários e Considerações sobre a Pesquisa:

As autoras informam as seguintes alterações:

Aumento da amostra de 30 para 50 pacientes em cada grupo (SPRi e controle)

Avaliação das fotografias de 2 para 3 fases (bebê, dentadura mista e permanente), formando 4 grupos (SRbebê, SRmista, SRpermanente e controle).

Alteração do teste estatístico (ANOVA)

Considerações sobre os Termos de apresentação obrigatória:

Os seguintes termos foram apresentados adequadamente:

Carta de encaminhamento dos pesquisadores aos CEP;

Formulário HRAC;

Folha de Rosto Plataforma Brasil;

Termo de Compromisso de Manuseio de Informações;

Formulário de Permissão para uso de Registros para Fins Científicos;

Termo de Compromisso de Tornar Públicos os Resultados da Pesquisa e Destinação de Materiais ou Dados Coletados;

Termo de Compromisso do Pesquisador Responsável.

Recomendações:

Endereço: Rua Silvio Marchione, 3-20
Bairro: Vila Nova Cidade Universitária **CEP:** 17.012-900
UF: SP **Município:** BAURU
Telefone: (14)3235-8421 **Fax:** (14)3234-7818 **E-mail:** uep_projeto@centrinho.usp.br

USP - HOSPITAL DE REABILITAÇÃO DE ANOMALIAS CRANIOFACIAIS

Continuação do Parecer: 1.869.005

Não há.

Conclusões ou Pendências e Lista de Inadequações:

As alterações comunicadas não ferem a ética, assim sugiro aprovação da emenda.

Considerações Finais a critério do CEP:

O pesquisador deve atentar que o projeto de pesquisa aprovado por este CEP refere-se ao protocolo submetido para avaliação. Portanto, conforme a Resolução CNS 466/12, o pesquisador é responsável por "desenvolver o projeto conforme delineado", se caso houver alterações nesse projeto, este CEP deverá ser comunicado em emenda via Plataforma Brasil, para nova avaliação.

Cabe ao pesquisador notificar via Plataforma Brasil o relatório final para avaliação. Os Termos de Consentimento Livre e Esclarecidos e/ou outros Termos obrigatórios assinados pelos participantes da pesquisa deverão ser entregues ao CEP. Os relatórios semestrais devem ser notificados quando solicitados no parecer.

Este parecer foi elaborado baseado nos documentos abaixo relacionados:

Tipo Documento	Arquivo	Postagem	Autor	Situação
Informações Básicas do Projeto	PB_INFORMAÇÕES_BÁSICAS_835908_E1.pdf	01/12/2016 11:05:55		Aceito
Projeto Detalhado / Brochura Investigador	projetocomemenda.pdf	01/12/2016 11:01:57	Gabriela Leticia Clavisio Siqueira Machado	Aceito
Outros	carta.pdf	01/12/2016 11:00:07	Gabriela Leticia Clavisio Siqueira Machado	Aceito
Outros	CARTA_RESPOSTA.pdf	04/04/2016 11:04:44	Gabriela Leticia Clavisio Siqueira Machado	Aceito
Outros	Permissao.pdf	01/04/2016 14:13:55	Gabriela Leticia Clavisio Siqueira Machado	Aceito
Outros	Lista_checagem_Plataforma_Brasil_Protocolo_7_2016.pdf	03/03/2016 15:34:56	Rafael Mattos de Deus	Aceito
Outros	Gabriela_Termo_Tornar_Publico.pdf	16/02/2016 13:54:20	Gabriela Leticia Clavisio Siqueira Machado	Aceito
Outros	Gabriela_Termo_Manuseio_Informacoes.pdf	16/02/2016 13:53:59	Gabriela Leticia Clavisio Siqueira Machado	Aceito
Outros	Gabriela_Oficio.pdf	16/02/2016 13:53:00	Gabriela Leticia Clavisio Siqueira	Aceito

Endereço: Rua Silvio Marchione, 3-20
Bairro: Vila Nova Cidade Universitária **CEP:** 17.012-900
UF: SP **Município:** BAURU
Telefone: (14)3235-8421 **Fax:** (14)3234-7818 **E-mail:** uep_projeto@centrinho.usp.br

USP - HOSPITAL DE REABILITAÇÃO DE ANOMALIAS CRANIOFACIAIS

Continuação do Parecer: 1.869.005

Outros	Gabriela_Oficio.pdf	16/02/2016 13:53:00	Machado	Aceito
Outros	Gabriela_Formulario_HRAC.pdf	16/02/2016 13:52:14	Gabriela Leticia Clavisio Siqueira Machado	Aceito
Declaração de Pesquisadores	Gabriela_Termo_Compromisso.pdf	16/02/2016 13:49:29	Gabriela Leticia Clavisio Siqueira Machado	Aceito
Projeto Detalhado / Brochura Investigador	ProjetodePesquisa.pdf	04/02/2016 01:20:18	Gabriela Leticia Clavisio Siqueira Machado	Aceito
Folha de Rosto	Gabriela_Folha_Rosto.pdf	04/02/2016 01:14:41	Gabriela Leticia Clavisio Siqueira Machado	Aceito

Situação do Parecer:
Aprovado

Necessita Apreciação da CONEP:
Não

BAURU, 15 de Dezembro de 2016

Assinado por:
Silvia Maria Graziadei
(Coordenador)

Endereço: Rua Silvio Marchione, 3-20
Bairro: Vila Nova Cidade Universitária **CEP:** 17.012-900
UF: SP **Município:** BAURU
Telefone: (14)3235-8421 **Fax:** (14)3234-7818 **E-mail:** uep_projeto@centrinho.usp.br