Allana Christina Fortunato Maciel

Descrição de nova técnica para o fechamento da parede abdominal com o uso do curativo à vácuo associado a incisões relaxadoras no transplante de intestino

Tese apresentada à Faculdade de Medicina da Universidade de São Paulo para obtenção do título de Doutora em Ciências

Programa Ciências em Gastroenterologia

Orientador: Prof. Dr. Wellington Andraus

São Paulo

2022

Allana Christina Fortunato Maciel

Descrição de nova técnica para o fechamento da parede abdominal com o uso do curativo à vácuo associado a incisões relaxadoras no transplante de intestino

Tese apresentada à Faculdade de Medicina da Universidade de São Paulo para obtenção do título de Doutora em Ciências

Programa Ciências em Gastroenterologia

Orientador: Prof. Dr. Wellington Andraus

São Paulo

2022

Dados Internacionais de Catalogação na Publicação (CIP)

Preparada pela Biblioteca da
Faculdade de Medicina da Universidade de São Paulo

©reprodução autorizada pelo autor

Maciel, Allana Christina Fortunato
Descrição de nova técnica para o fechamento da parede abdominal com o uso do curativo à vácuo associado a incisões relaxadoras no transplante de intestino / Allana Christina Fortunato Maciel. -- São Paulo, 2022.
Tese(doutorado)--Faculdade de Medicina da Universidade de São Paulo.
Programa de Ciências em Gastroenterologia.
Orientador: Wellington Andraus.

Descritores: 1.Transplantes 2.Intestinos 3.Síndrome do intestino curto 4.Parede abdominal 5.Tratamento de ferimentos com pressão negativa

USP/FM/DBD-271/22

Responsável: Erinalva da Conceição Batista, CRB-8 6755

Dedico essa tese a minha amada e querida mãe Elizabetth, por todos esses anos de amor imensurável, incansável incentivo e exemplo de garra e força.

Ao querido amigo Zeca por nunca falhar diante dos obstáculos que enfrentei, além de me ensinar que com suor, dedicação e honestidade posso atingir o êxito em todas as esferas da vida.

Ao meu amor, por ser abrigo, solo fértil e inspiração.

AGRADECIMENTOS

Ao Prof. Luiz Augusto Carneiro D'Albuquerque, pelo estímulo contínuo às atividades acadêmicas e por propiciar as condições necessárias para realização de pesquisas, além de todas as oportunidades oferecidas.

Ao Prof. Wellington Andraus, orientador desse estudo, que me permitiu fazer parte dessa jornada e me maravilhar com o mundo do transplante. Pelo brilhantismo como médico e pessoa e por ser exemplo e inspiração diária. Pela condução exemplar do estudo, orientação meticulosa e pertinente que possibilitou a elaboração dessa tese.

Ao Dr. Rafael Pinheiro, idealizador dessa tese, que conduziu com maestria esse estudo. Pela paciência, pela amizade e pelo incansável esforço para meu crescimento profissional e pessoal. Além do apoio ininterrupto.

A todos os médicos do departamento de transplante de fígado e da nutrologia, assim como os colegas médicos residentes, que junto comigo estagiaram no serviço e prestaram cuidados e atendimentos aos pacientes desse estudo.

Agradeço também às instrumentadoras cirúrgicas, às circulantes de sala operatória, enfermeiras, nutricionistas, fisioterapeutas, fonoaudiólogas, assistentes sociais, auxiliares e técnicas de enfermagem do centro cirúrgico, enfermaria, UTI e do ambulatório do departamento de transplante de fígado que exerceram sua profissão de forma gentil, atenciosa e cortês, aliviando o sofrimento dos pacientes desse estudo.

A Karina Segatto, secretária do Prof. Wellington, que sempre muito prestativa, simpática e eficiente me ajudou com toda documentação, além de nunca o deixar esquecer os meus prazos.

A Vilma Libério, secretária da pós-graduação, sempre pronta para resolução das dificuldades operacionais e burocráticas, bem como não me deixar esquecer dos prazos de entrega.

Para meu pai

“E de repente
você escorrega e bate a cabeça na quina do vaso
De repente você faz uma curva com a moto acelerada
De repente você tem um diagnostico em que se lê
“invasivo, metastático”
De repente você supra seu ECG
De repente você rompe uma artéria e desvia sua linha média
No momento em que você era mais feliz, tinha acabado de
comprar seu carro, ver um filho nascer, chegar de férias, se apaixonar por ela,
tomar sorvete de chocolate meio amargo...
A vida sempre será um sopro
Um sopro difícil de entender.”

Carmem O. in Lírios de Sangue.

NORMALIZAÇÃO ADOTADA

Esta dissertação ou tese está de acordo com as seguintes normas, em vigor no momento desta publicação:

Referências adaptadas de *International Committee of Medical Journals Editors* (Vancouver).

Universidade de São Paulo. Faculdade de Medicina. Divisão de Biblioteca e Documentação. *Guia de apresentação de dissertações, teses e monografias*. Elaborado por Anneliese Carneiro da Cunha, Maria Julia de A. L. Freddi, Maria F. Crestana, Marinalva de Souza Aragão, Suely Campos Cardoso, Valéria Vilhena. 3a ed. São Paulo: Divisão de Biblioteca e Documentação; 2011.

Associação Brasileira de Normas Técnicas (ABNT): NBR14.724:2011 e NBR10.520:2002.

Abreviaturas dos títulos dos periódicos de acordo com *List of Journals Indexed in Index Medicus*.

SUMÁRIO

LISTA DE SIGLAS E ABREVIATURAS
LISTA DE FIGURAS
LISTA DE TABELAS
RESUMO
ABSTRACT
1 – INTRODUÇÃO.....2
2 – OBJETIVO.....10
3 – MÉTODOS.....12
3.1 Aspectos Éticos.....12
3.2 Casuística.....12
3.3 Critérios de Inclusão.....13
3.4 Critérios de Exclusão 13
3.5 Variáveis Estudadas.....13
3.6 Análise Estatística.....14
4 – RESULTADOS.....16
5 – DISCUSSÃO.....30
6 – CONCLUSÕES.....39
7 – REFERÊNCIAS.....41
8 – APÊNDICES
APÊNDICE A – Termo de Consentimento Livre Esclarecido
APÊNDICE B – Aprovação comitê de Ética e Pesquisa - CAPPESQ
APÊNDICE C – Artigos Publicados
APÊNDICE D – Artigos Submetidos a Publicação

LISTA DE SIGLAS E ABREVIATURAS

CMV	Citomegalovírus
CS	Ciclosporina
EUA	Estados Unidos da América
FII	Falência intestinal irreversível
FMUSP	Faculdade de Medicina da Universidade de São Paulo
IC95%	Intervalo de confiança
IC	Inibidor de calcineurina
ID	Intestino delgado
IGG	Imunoglobulina G
IMC	Índice de massa corpórea
NP	Nutrição parenteral
PA	Parede abdominal
QoL	*Quality of life*
SIC	Síndrome do intestino curto
TAC	Tacrolimos
TC	Tomografia computadorizada
TE	Expansores de tecido
TI	Transplante de intestino
TII	Transplante de intestino isolado
TX	Transplante
UTI	Unidade de terapia intensiva
VAC	Curativo a vácuo

LISTA DE FIGURAS

Figura 1 Imagem extraída de exame tomográfico de paciente com síndrome do intestino curto demonstrando a importante redução da cavidade abdominal.....6

Figura 2 Ilustração da desproporção entre a cavidade abdominal de um paciente com redução crônica da cavidade abdominal após receber um enxerto de intestino isolado.....7

Figura 3 Fluxograma das etapas para fechamento da parede abdominal com o VAC.....17

Figura 4 Confecção do curativo à vácuo: a) plástico estéril multiperfurado cobrindo as vísceras; (b) esponja de poliuretano acoplada acima do plástico multiperfurado; (c) confecção do vácuo com auxílio de filmes plásticos.....17

Figura 5 Retirada do VAC anterior de forma estéril.....18

Figura 6 Demonstração da separação dos componentes da parede abdominal e incisões relaxadoras.....19

Figura 7 Aproximação dos bordos da aponeurose e pontos de orientação da força do vácuo.....20

Figura 8 Pele protegida com placas de hidrocolóide e pontos de orientação das forças do vácuo.....20

Figura 9 Aproximação gradual das bordas aponeuróticas da lesão.....21

Figura 10 Fechamento total do defeito aponeurótico e da pele: (a) fechamento completo da aponeurose; (b) fechamento completo da pele.....22

Figura 11 Sobrevida dos pacientes submetidos ao tranſsplante de intestino no HC-FMUSP.....25

Figura 12 Exames tomográficos antes e após o transplante de intestino: (a) paciente 1 pré transplante (b) paciente 1 pós transplante (c) paciente 2 pré transplante (d) paciente 2 pós transplante.....27

Figura 13 Volumetrias abdominais antes e após transplante de intestino: (a) volumetria abdominal pré transplante de intestino (4339,77cm^3) (b) volumetria abdominal pós transplante de intestino (5369,06cm^3).....28

LISTA DE TABELAS

Tabela 1 Dados demográficos e particularidades técnicas do transplante de intestino.....24

RESUMO

Maciel ACF. *Descrição de nova técnica para o fechamento da parede abdominal com o uso do curativo à vácuo associado a incisões relaxadoras no transplante de intestino* [tese]. São Paulo: Faculdade de Medicina, Universidade de São Paulo; 2022.

INTRODUÇÃO: O transplante de intestino isolado (TI) é indicado nos casos de falência intestinal (FI) com ausência de disfunção hepática severa. A síndrome do intestino curto (SIC) ocasiona a perda do domínio e elasticidade abdominal. Assim, frequentemente é extremamente difícil o fechamento primário da parede abdominal (PA) após o TI. **OBJETIVO:** O objetivo desse estudo é descrever uma nova técnica que associa o curativo à vácuo seriado (VAC) a incisões relaxadoras para o fechamento da parede abdominal após o TI em pacientes com SIC e analisar os resultados em uma série de casos inicial. **MÉTODOS:** Entre dezembro de 2017 e fevereiro de 2021 quatro pacientes com SIC realizaram o TI e foram submetidos ao fechamento da cavidade abdominal coma técnica proposta. **RESULTADOS:** Todos os pacientes obtiveram sucesso no fechamento da PA e da pele após o TI utilizando a nova técnica. A média de abordagens para o fechamento da PA foi de 5 (variação:2-9), num período médio de 15 ± 11,2 dias. A comparação tomográfica por volumetria antes e após o fechamento da PA evidenciou ganho de 41% no domínio abdominal. Não houve incidência de hérnias, deiscências, fístulas, infecção de sítio cirúrgico ou qualquer outra complicação relacionada a PA. **CONCLUSÃO:** A nova técnica mostrou-se factivel, eficaz e acessível aumentando o arsenal de possibilidades para o fechamento da PA após o TI.

Descritores: Transplantes; Intestinos; Síndrome do intestino curto; Parede abdominal; Tratamento de ferimentos com pressão negativa

ABSTRACT

Maciel ACF. *Description of a new technique for closing the abdominal wall with the use of vacuum dressing associated with relaxing incisions in intestinal transplantation* [thesis] .Sao Paulo: “Faculdade de Medicina, Universidade de São Paulo”; 2022.

INTRODUCTION: Isolated intestinal transplantation (IT) is the standard treatment in patients with intestinal failure (IF) without severe liver dysfunction. Short bowel syndrome (SBS) causes loss of abdominal dominance and elasticity. Thus, primary closure of the abdominal wall (AW) after IT is often impossible. **OBJECTIVE:** The aim of this study is to describe a new technique that combines serial vacuum dressing (VAC) with relaxing incisions for closure of the AW after IT in patients with SBS, and to analyze the results in an initial series. **METHODS**: Between December 2017 and February 2021, four patients with SBS underwent IT using the proposed technique. **RESULTS**: All patients successfully closed the AW and the skin after TI using the new technique. The median of operations to close the AW was 5 (range:2-9), in a mean period of 15 ± 11.2 days. The comparison of volumetric tomographic before and after AW closure showed a mean increase of 41% of the abdominal domain. There was no incidence of hernias, dehiscence, leaks, surgical site infection or any other AW-related complication. **CONCLUSION**: The new technique proved to be feasible, effective and accessible, increasing the arsenal of possibilities for closure of the AW after IT.

Descriptors: Transplantation; Intestines; Short bowel syndrome; Abdominal wall; Negative-pressure wound therapy.

1 Introdução

1 INTRODUÇÃO

Falência intestinal é diagnosticada em pacientes incapazes de manter homeostase através da absorção enteral de nutrientes, eletrólitos e água.[1; 2; 3] Essa afecção pode ser transitória, sendo uma condição que ocorre principalmente após cirurgias abdominais ou em pacientes gravemente doentes que apresentam disfunção orgânica. Rotineiramente, esses pacientes recuperam a função intestinal após algumas semanas ou meses.[4]

Já a falência intestinal irreversível (FII) é decorrente de afecções que resultam na redução da capacidade funcional do trato gastrointestinal em manter a digestão e absorção de nutrientes necessários para a manutenção do aporte nutricional e absorção hídrica.[3]O tratamento inicial da FII é a nutrição parenteral (NP).

Dentre as etiologias da FII a síndrome do intestino curto (SIC) é a mais comum, sendo consequência de ressecções de segmentos variados do intestino. Os distúrbios funcionais e de motilidade intestinal são outras possíveis causas de FII.[5] Cerca de 60% dos pacientes com FII são pediátricos e as causas mais frequentes nessa população são: atresia intestinal, enterocolite necrotizante, volvo, gastrosquise, pseudoobstrução intestinal e aganglionose. Entre os adultos, isquemia mesentérica, trauma, enterite actínica, tumores e doença inflamatória intestinal, como a doença de Crohn, são as causas mais comuns.[6]

Messing*et al.* correlacionaram o remanescente intestinal com o diagnóstico de FII secundária a SIC. A dependência permanente de NP é alta entre os pacientes que apresentam menos que 100cm de intestino delgado (ID) e jejunostomia terminal, naqueles que apresentam menos de 65cm de ID com algum remanescente colônico,

ou naqueles que apresentam menos de 30cm de ID com preservação da válvula íleo-cecal e todo o cólon. A porcentagem de ressecção intestinal é outro fator relevante na FII; pacientes com ressecções intestinais maiores que 75% são de alto risco para desenvolvimento da SIC.[7] Pacientes com remanescente intestinal de 20cm ou menos são denominados pacientes com intestino ultracurto e estão sob maior risco de complicações.

Na década de 1950, a FII era considerada incompatível com a vida.[8] No entanto, em 1960 o desenvolvimento da NP possibilitou maior sobrevida e melhor qualidade de vida aos pacientes. Desde então, a NP tem sido o principal tratamento para pacientes com FI. Contudo, o uso prolongado de NP pode levar a complicações que resultam na falha da terapia nutricional. Além disso, a NP deve ser administrada via cateter venoso central (CVC) e a longa permanência desses cateteres aumenta o risco de complicações, como infecção e trombose venosa.

Os pacientes que apresentam complicações graves ou recorrentes associadas a NP são candidatos ao transplante de intestino (TI). As indicações bem definidas na literatura para o TI são: trombose de dois dos seis acessos venosos centrais principais; doença hepática colestática associada a NP; episódios de infecções relacionadas ao cateter (dois ou mais episódios de infecção bacteriana de corrente sanguínea ao ano, fungemia, ou choque séptico); distúrbios hidroeletrolíticos refratários; e déficit do desenvolvimento pondero estatural em crianças.[9] Além das indicações ao TI por complicações, a *US Center for Medicare and Medicaid Services* (que regulamenta o sistema de reembolso de procedimentos médicos nos EUA) aprovou o TI nos pacientes com baixa qualidade de vida ou com internações recorrentes relacionadas ao uso de NP a longo prazo.[10;11] Atualmente, o TI é a única terapia curativa para FI.[9]

Estima-se que 2-3 pessoas por milhão de habitantes por ano apresentarão FII.[12] Goulet *et al.* demonstraram 87% de sobrevida em 5 anos nos pacientes dependentes de NP que não apresentavam complicações.[13] Estudos multicêntricos sugerem que 19 a 26% dos pacientes dependentes da NP desenvolverão algum tipo de complicação e serão candidatos ao transplante de intestino.[14] A mortalidade após o surgimento de complicações é alta, atingindo 40% em cinco anos nos pacientes com menos de 50 cm de intestino delgado.[15]

O primeiro transplante de intestino foi realizado em 1959 em cães por Lillehei *et al*.[16] Os primeiros transplantes de intestino em humanos foram realizados em pacientes pediátricos em 1964, em Boston.[17] Em 1968, Okumura[18] realizou a primeira tentativa de TI em adultos no Hospital das Clínicas da Faculdade de Medicina da Universidade de São Paulo. No período de 1964 a 1970, outras oito tentativas de TI foram realizadas em humanos, porém os resultados foram precários, com apenas um paciente sobrevivendo mais que 30 dias. Os resultados negativos desses primeiros pacientes foram atribuídos a complicações técnicas, infecciosas e a imunossupressão ineficaz.[19] A imunossupressão é especialmente complicada no TI, pois o intestino é um órgão altamente imunogênico.

No final da década de 1980 Calne *et al*. obtiveram sobrevida de 109 e 192 dias após o TI em dois pacientes, devido a introdução da Ciclosporina (CS), um inibidor da calcineurina(IC).[9;20] O surgimento desse imunossupressor no tratamento e prevenção da rejeição permitiu a melhora dos resultados dos transplantes de órgãos sólidos em geral. Em 1989, Goulet *et al*.[21] realizaram o primeiro transplante isolado de intestino delgado (TII) com sobrevida a longo prazo. Ao mesmo tempo, Grant *et al*.[22] relataram o primeiro transplante combinado de intestino e fígado. Apesar do sucesso do uso da

CS em outros tipos de transplante na década de 80, os resultados no TI permaneciam conflitantes.

Em 1990 houve a introdução na prática clínica do Tacrolimos (TAC) que é um IC mais potente. Esse novo medicamento propiciou melhora significativa nas taxas de sobrevida de pacientes e órgãos transplantados, devido ao melhor controle da rejeição. Imunossupressores mais eficientes permitiram a expansão na indicação, realização e aperfeiçoamento técnico do TI.[22] Em 2001, o TI foi aceito nos EUA como modalidade terapêutica para pacientes com FII que apresentavam complicações da NP. Atualmente, a sobrevida dos pacientes no primeiro ano após o TI se aproxima a sobrevida de outros órgãos sólidos.

Além do incremento da sobrevida, houve melhora significativa da qualidade de vida dos pacientes submetidos ao TI comparados aos pacientes com FII em uso de NP.[23] O decréscimo dos custos do TI associado ao alto custo da NP também influenciaram na sua expansão. Na Universidade de Pittsburgh (EUA), o custo de cada paciente transplantado reduziu de US$ 203.111 para US$ 132.280 em 5 anos. Por outro lado, o custo da NP atinge até US$ 120.000 por ano, sem contar as despesas com internações. Assim, no final do segundo ano de NP, os custos monetários desse procedimento seriam equivalentes ao do TI.[24] A mortalidade anual de pacientes dependentes de NP com doença benigna é de 5% a 25%.[24;25;26;27]

O TI envolve algumas modalidades cujo principal órgão a ser transplantado é o intestino delgado, podendo ser transplantado em conjunto com outros órgãos. A modalidade do transplante depende da doença de base, qualidade dos demais órgãos abdominais, presença de doença hepática e número de operações abdominais pregressas. O transplante de intestino isolado é indicado na FII com ausência de disfunção hepática severa. Na presença de doença hepática grave e irreversível, o

fígado deverá ser incluído no enxerto. Em 2020, nos EUA 53% dos pacientes submetidos ao TI receberam um enxerto incluindo o fígado. Quando há falência de múltiplos órgãos abdominais o enxerto deve ser multivisceral e, nesse caso, são transplantados em bloco: estômago, duodeno, pâncreas, intestino delgado e fígado.[28]

A SIC é a etiologia mais frequente de FII, sendo responsável por 35 a 75% dos casos.[29;30;31] Nesses pacientes, em virtude da ausência ou redução considerável das alças intestinais na cavidade abdominal, há atrofia e retração da musculatura do abdome, levando a perda do domínio e elasticidade abdominal (Figura 1).

Figura 1 - Imagem extraída de exame tomográfico de paciente com síndrome do intestino curto demonstrando a importante redução da cavidade abdominal.

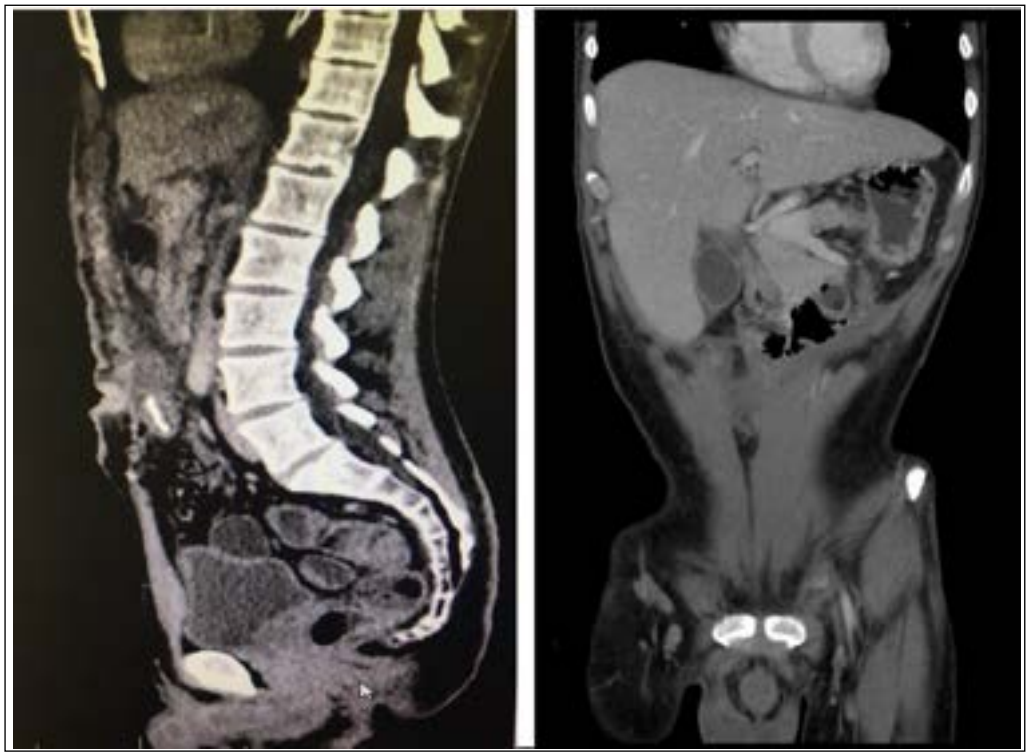

Fonte: Produção do próprio autor.

Essa complicação é um agravante no TI, pois impossibilita o fechamento primário da parede abdominal. Outras situações recorrentes dentre os candidatos ao TI

também podem dificultar o fechamento da parede abdominal, como nas catástrofes abdominais resultante de inúmeros procedimentos cirúrgicos prévios, ocorrência de fístulas, ostomias ou extensa fibrose abdominal resultante da cicatrização por segunda intenção de peritoneostomias.[19] Além disso, o edema intraoperatório do enxerto após revascularização tende a agravar a dificuldade do fechamento primário livre de tensão.[32] Uma tentativa forçada de fechamento pode resultar em síndrome compartimental, isquemia e consequente necrose do enxerto.[14; 33] O fechamento da cavidade diminui o risco de infecção e propicia ambiente ideal para restabelecimento dos movimentos peristálticos intestinais. Contudo, o fechamento primário livre de tensão é inatingível em cerca de 20 – 50% dos pacientes submetidos ao TI[19; 20; 34; 35] (Figura 2).

Figura 2 - Ilustração da desproporção entre a cavidade abdominal de um paciente com redução crônica da cavidade abdominal após receber um enxerto de intestino isolado.

Fonte: Produção do próprio autor.

Existem algumas estratégias para reconstrução da parede abdominal na ocasião da impossibilidade do fechamento primário. As principais abordagens se concentram na redução do volume do enxerto ou na expansão da cavidade abdominal.[33] A redução do volume do enxerto pode ser alcançada utilizando doadores pequenos em relação aos receptores[36;37] ou redução anatômica do enxerto na cirurgia de bancada[38], contudo esse procedimento está associado a maior risco de complicações. Devido a crescente escassez de órgãos, o uso de doadores pequenos em relação ao receptor em adultos é cada vez menos frequente e as técnicas para aumento de cavidade abdominal são preferidas.

As técnicas variam desde expansores temporários até o transplante de parede abdominal.[39;40] São descritas técnicas como separação de componentes, uso de telas absorvíveis, telas inabsorvíveis, equivalente de pele com bioengenharia, matriz dérmica acelular, enxertos de pele, transplante de parede abdominal[39] e de aponeurose. Fortunato *et al*[41], numa revisão sistemática recente aborda as principais técnicas disponíveis e demonstra que não existe consenso para seleção da melhor estratégia, já que cada uma dessas técnicas apresenta suas limitações, como: aplicabilidade limitada e altos custos. As principais complicações associadas ao fechamento da parede abdominal no TI são as infecções de ferida operatória, fistulas intestinais e síndrome compartimental.

Ainda existe uma área a ser investigada para resolver esse problema clínico com mais simplicidade e menos riscos ao paciente.

2 Objetivo

2 OBJETIVO

O objetivo do estudo é descrever uma nova técnica que associa o curativo à vácuo seriado (VAC) a incisões relaxadoras para o fechamento da parede abdominal após o transplante de intestino em pacientes com redução crônica da cavidade abdominal e analisar os resultados em uma série inicial de casos.

3 Métodos

3 MÉTODOS

3.1 Aspectos Éticos

O projeto deste estudo foi analisado e aprovado pela Comissão Ético-Científica do Departamento de Gastroenterologia da FMUSP, pelo parecer número 3.730.175.

Todos os pacientes incluídos após o início do estudo foram submetidos à extensa explicação sobre o delineamento do estudo, das dificuldades operacionais para sua realização, entrega do termo de consentimento livre esclarecido para análise e posterior assinatura em caso de concordância.

3.2 Casuística

Estudo prospectivo, baseado no seguimento de pacientes com SIC submetidos ao TI no Hospital das Clínicas da Faculdade de Medicina da Universidade de São Paulo no departamento de Gastroenterologia, pela disciplina de Transplante de fígado e órgãos do aparelho digestivo. Os pacientes aguardavam em lista de espera para TII recebendo NPT em acompanhamento conjunto com a equipe da nutrologia.

3.3 Critérios de Inclusão

Foram incluídos no estudo pacientes com FII decorrente da SIC submetidos ao TI, que apresentavam redução crônica da cavidade abdominal no momento do transplante.

3.4 Critérios de Exclusão

Foram excluídos do estudo pacientes submetidos ao TI que não apresentavam redução significativa da cavidade abdominal e/ou com sucesso no fechamento primário.

3.5 Variáveis Estudadas

Foram estudadas as características demográficas dos doadores e receptores, características do ato operatório incluindo tempo de isquemia fria, tempo total de cirurgia e data do TI além dos dados do pós operatório, como ocorrência de rejeições, infecção por citomegalovírus (CMV), número de abordagens, dias necessários para fechamento completo da cavidade, infecções de ferida operatória (FO), complicações relacionadas a parede abdominal ou FO, avaliação das alças caso reabordagem por laparotomia e

calculado o incremento de volume abdominal após o fechamento completo da cavidade.

Os dados pré TI foram coletados através de informações de prontuários, e os dados cirúrgicos e pós TI foram acompanhados prospectivamente. Todos os pacientes foram esclarecidos sobre o estudo e assinaram o termo de consentimento livre e esclarecido (TCLE). Para quantificar o progresso da expansão da cavidade foram realizadas volumetrias abdominais a partir de estudo tomográfico computadorizado antes e após o TI. O volume foi estimado em cm^3 com auxílio do *software* Clinical PACS (PHILIPS insite®). O *software* multiplica automaticamente a área delimitada em um corte pela sua espessura, obtendo o volume de um corte tomográfico. O volume total foi calculado automaticamente pela soma dos volumes de cada corte.

3.6 Análise Estatística

Na análise dos dados foram utilizadas técnicas de estatística descritiva através de distribuições absolutas e percentuais e pelas medidas estatísticas: média, mediana, desvio padrão, valor mínimo e valor máximo. Realizou-se análise descritiva da população de estudo e características dos doadores, ato cirúrgico e pós-operatório. A análise estatística foi realizada no Review Manager, versão 5.2.

4 Resultados

4 RESULTADOS

Descrição da Técnica

A técnica do TI consiste em anastomoses vasculares da artéria mesentérica superior e veia mesentérica superior, com a aorta e veia cava, respectivamente, interpostas por enxerto ilíaco do mesmo doador. Após revascularização do intestino transplantado, anastomoses intestinais proximal e distal são confeccionadas com o remanescente intestinal do receptor. Nos casos com inclusão de colón, o apêndice cecal é estrategicamente removido. O intestino transplantando é cuidadosamente fixado e as brechas mesentéricas são fechadas. Ao final da cirurgia, uma sonda enteral triplo-lúmen é passada pela gastrostomia com a finalidade de descompressão gástrica e nutrição enteral. A ileostomia em alça é confeccionada em hipocôndrio direito, o mais distante possível da ferida operatória.

Ao final do transplante, é iniciada a primeira etapa da nova técnica utilizando curativo a vácuo (VAC) contínuo da seguinte forma (Figura 3): posicionada cobertura plástica estéril multiperfurada para recobrir todas as vísceras abdominais; inserção de esponja de poliuretano reticulada com poros de 400 a 600 µm e 2 cm de espessura sobre a cobertura plástica de modo a cobrir o defeito aponeurótico; faixas de adesivo plástico estéril são acopladas meticulosamente a fim de isolar e cobrir a incisão, esponja e pele adjacente, com o cuidado de contornar e tamponar orifícios externos (gastrostomia / ileostomia); posicionado a ventosa de aspiração sobre a esponja e conectado

a mangueira de aspiração a bomba de vácuo contínuo (Figura 4). O paciente é então encaminhado a UTI.

Figura 3 - Fluxograma das etapas para fechamento da parede abdominal com o VAC.

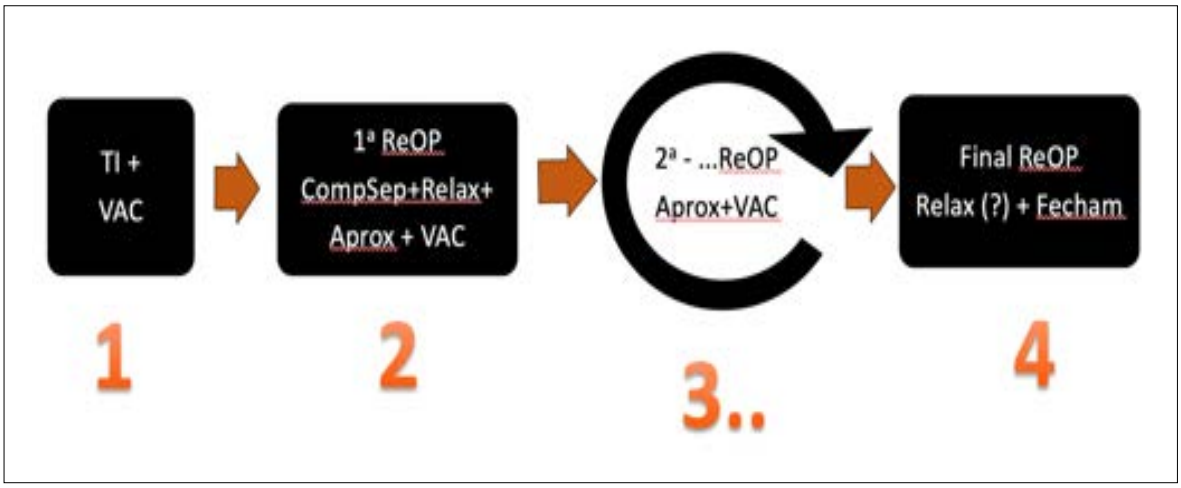

Fonte: Produção do próprio autor.

Figura 4 - Confecção do curativo à vácuo: a) plástico estéril multiperfurado cobrindo as vísceras; (b) esponja de poliuretano acoplada acima do plástico multiperfurado; (c) confecção do vácuo com auxílio de filmes plásticos.

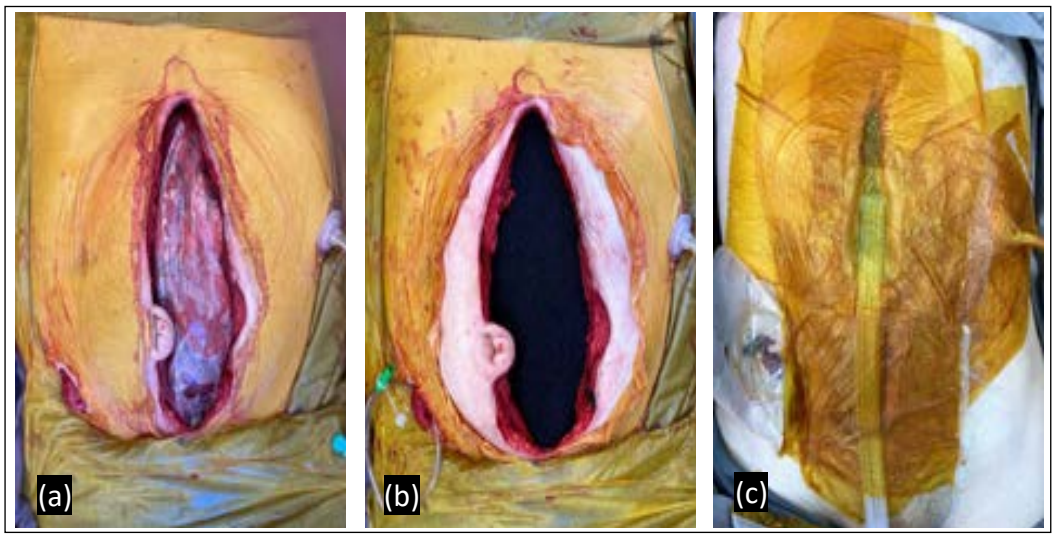

Fonte: Produção do próprio autor.

Após 48-72 horas do transplante é iniciada a segunda etapa, sendo realizada nova abordagem cirúrgica com retirada do curativo anterior de maneira estéril (Figura 5). Nesse momento é realizada uma ampla separação dos componentes anteriores da parede abdominal, liberando a gordura subcutânea da bainha anterior dos músculos reto abdominal e oblíquo externo, bilateralmente, respeitando os limites da gastrostomia e ileostomia. Em seguida são confeccionadas incisões relaxadoras na bainha anterior do reto abdominal (Figura 6).

Figura 5 - Retirada do VAC anterior de forma estéril.

Fonte: Produção do próprio autor.

Figura 6 - Demonstração da separação dos componentes da parede abdominal e incisões relaxadoras.

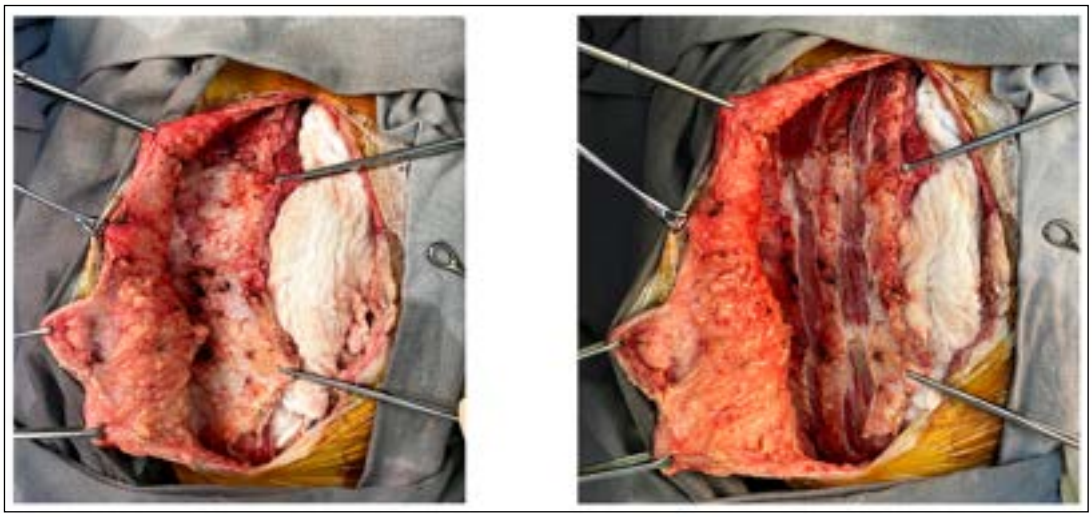

Fonte: Produção do próprio autor.

As extremidades da aponeurose e da pele que se aproximam sem tensão são suturadas com pontos separados de fio inabsorvível. Além disso, alguns pontos separados em “U” são realizados na aponeurose e pele com a finalidade de aproximar as bordas e orientar a força do vácuo para o fechamento posterior (Figura 7). Para evitar lacerações, a pele e a aponeurose são protegidas por placas de hidrocoloide, seguido de nova confecção de VAC (Figura 8).

Figura 7 - Aproximação dos bordos da aponeurose e prontos de orientação da força do vácuo.

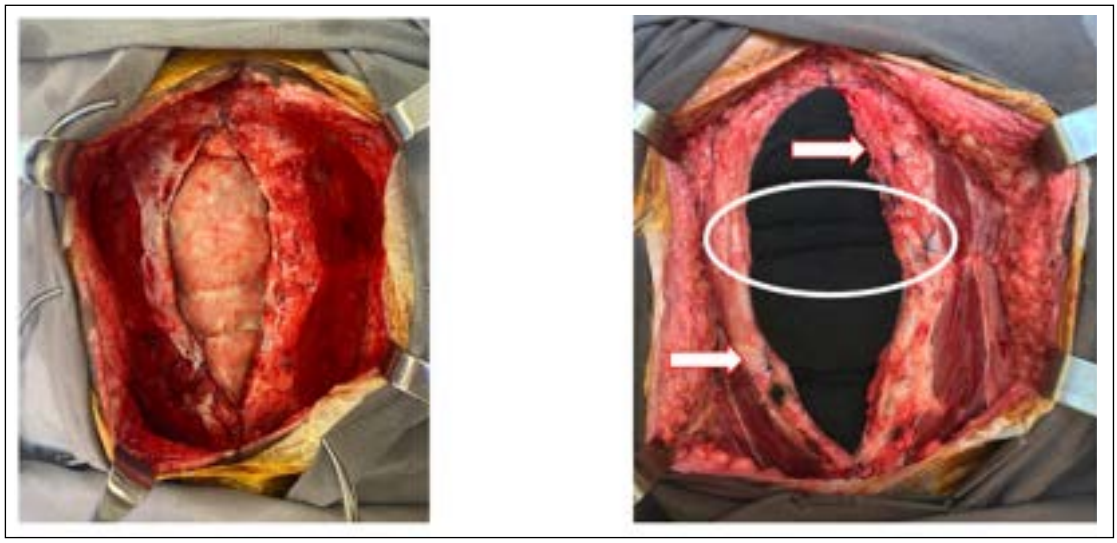

Fonte: Produção do próprio autor.

Figura 8 - Pele protegida com placas de hidrocolóide e pontos de orientação das forças do vácuo.

Fonte: Produção do próprio autor.

A partir de então, é dado início a terceira etapa e novas abordagens a cada 48-72 horas são realizadas com o intuito de suturar as extremidades da pele e aponeurose que se aproximem sem tensão. Se ainda houver defeito

aponeurótico, novos pontos de aproximação de pele e aponeurose são realizados, seguidos da confecção de novo VAC (Figura 9). Esse passo é repetido até a obtenção do fechamento primário total do defeito abdominal, na quarta e última etapa (Figura 10). Caso as incisões relaxadoras prévias já estiverem cicatrizadas novas são realizadas em localização diferente da anterior. Se houver fechamento completo da aponeurose e ainda houver tensão para fechamento da pele, realiza-se o VAC apenas no subcutâneo.

Figura 9 - Aproximação gradual das bordas aponeuróticas da lesão.

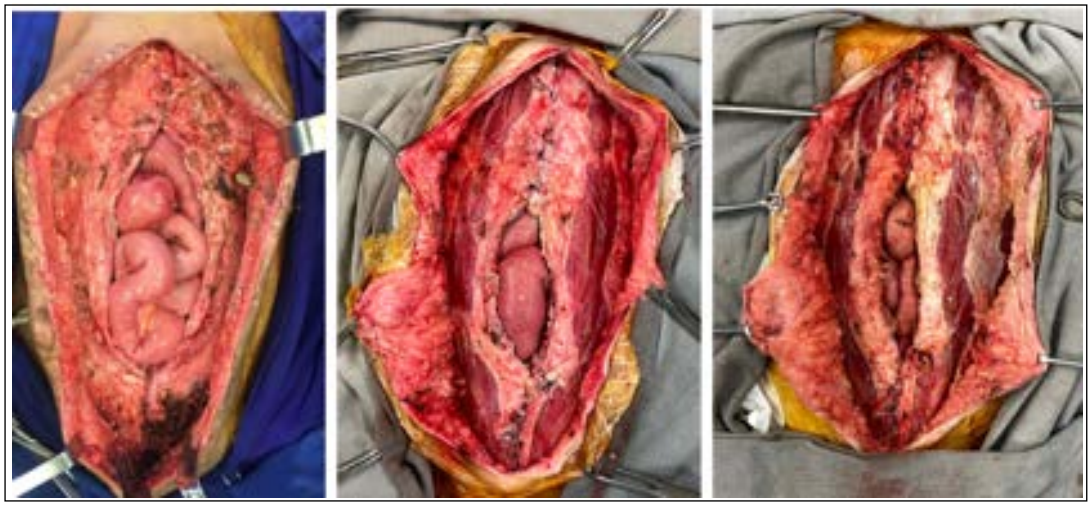

Fonte: Produção do próprio autor.

Durante o intervalo entre as abordagens cirúrgicas, é estimulado ao paciente a fisioterapia motora e a deambulação precoce. Como o dispositivo de pressão negativa é móvel, o paciente consegue se locomover facilmente acoplado ao suporte móvel.

O jejum preconizado é limitado a demanda anestésica precedente ao ato cirúrgico. Durante os intervalos o paciente recebe nutrição enteral conforme meta nutricional, sem prejuízo calórico-proteico.

Após 6 meses do transplante é realizado o fechamento de ileostomia em alça, sem dificuldades.

Figura 10 - Fechamento total do defeito aponeurótico e da pele: (a) fechamento completo da aponeurose; (b) fechamento completo da pele.

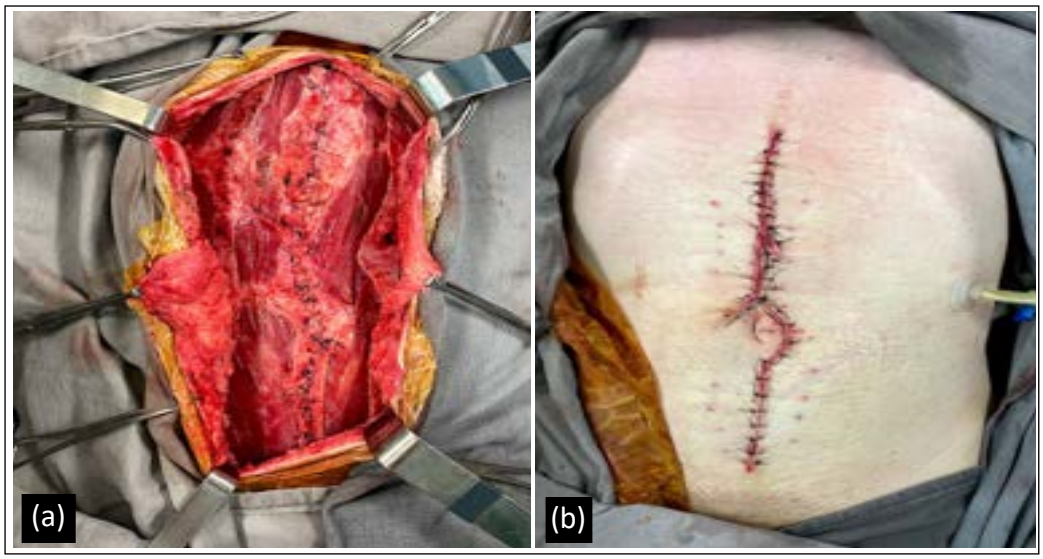

Fonte: Produção do próprio autor.

Os dados demográficos dos doadores e receptores, bem como as informações sobre o transplante e o fechamento da parede abdominal estão descritos na Tabela 1.

Os quatro pacientes do estudo eram do sexo masculino, com idade variando de 19 a 45 anos. O número de abordagens para troca de curativo foi em média de 5 (mínimo: 2 e máximo: 9) reabordagens por paciente num período médio de 15 ± 11,2 dias. Nenhum paciente apresentou complicação relacionada ao fechamento da parede abdominal no período das trocas de curativo, após o fechamento completo ou após 18 meses de seguimento.

Todos os pacientes operados com a técnica descrita apresentaram sobrevida de 100% em um ano; apenas um paciente evoluiu a óbito com 18 meses em decorrência de complicações pulmonares (Figura 11).

Tabela 1 - Dados demográficos e particularidades técnicas do transplante de intestino.

Característica	PACIENTE #1	PACIENTE #2	PACIENTE #3	PACIENTE #4
Idade (anos)	25	45	27	21
Gênero	MASC	MASC	MASC	MASC
Peso (kg)	60	55	70	51
IMC	19,6	18	18	19,4
CMV IgG	POSITIVO	POSITIVO	NEGATIVO	POSITIVO
Tipo Sanguíneo	A	O	A	O
Idade Doador (anos)	14	19	30	5
Gênero Doador	MASC	MASC	FEM	FEM
Peso Doador (kg)	60	75	70	26
IMC Doador	20,7	25,9	24,2	20,3
CMV IgG Doador	POSITIVO	POSITIVO	POSITIVO	POSITIVO
Dias UTI Doador	3	8	3	4
Painel Imunológico	NEGATIVO	NEGATIVO	NEGATIVO	NEGATIVO
Tempo de FII (meses)	24	12	96	72
Etiologia da FI	SIC	SIC	SIC	SIC
Perda de Acessos C.*	4	1	0	2
Data do transplante	13/12/2017	14/02/2019	05/02/2020	11/02/2021
Tempo de cirurgia	07:27	07:14	07:40	09:50
Tempo total isquemia	07:30	06:00	05:38	07:45
Inclusão do Cólon	NÃO	SIM	SIM	SIM
Trombose cava	SIM	NÃO	NÃO	NÃO
Reconstrução trânsito	6M	6M	7M	8M
Infecção CMV	NO	NO	NO	NO
Abordagens fechamento	3	6	2	9
Dias para fechamento	8	28	9	21
Fechamento da pele	SIM	SIM	SIM	SIM
Fechamento aponeurose	SIM	SIM	SIM	SIM
Infecção PA†	NÃO	NÃO	NÃO	NÃO
Deiscência PA†	NÃO	NÃO	NÃO	NÃO
Volume pré TI cm^3	2.681,59	5.072,92	3.681,8	4.339,77
Volume pós TI cm^3	4.562,56	5.994,76	6.395,56	5.369,06
Aumento vol. abdominal	170%	118%	173%	123%
Hérnias	NÃO	NÃO	NÃO	NÃO

Dados demográficos, dados pré e pós transplante dos doadores e receptores do TI.
Abrev.:PA†: parede abdominal; M meses; C.*: centrais.

Fonte: Produção do próprio autor.

Figura 11 - Sobrevida dos pacientes submetidos ao transplante de intestino no HC-FMUSP.

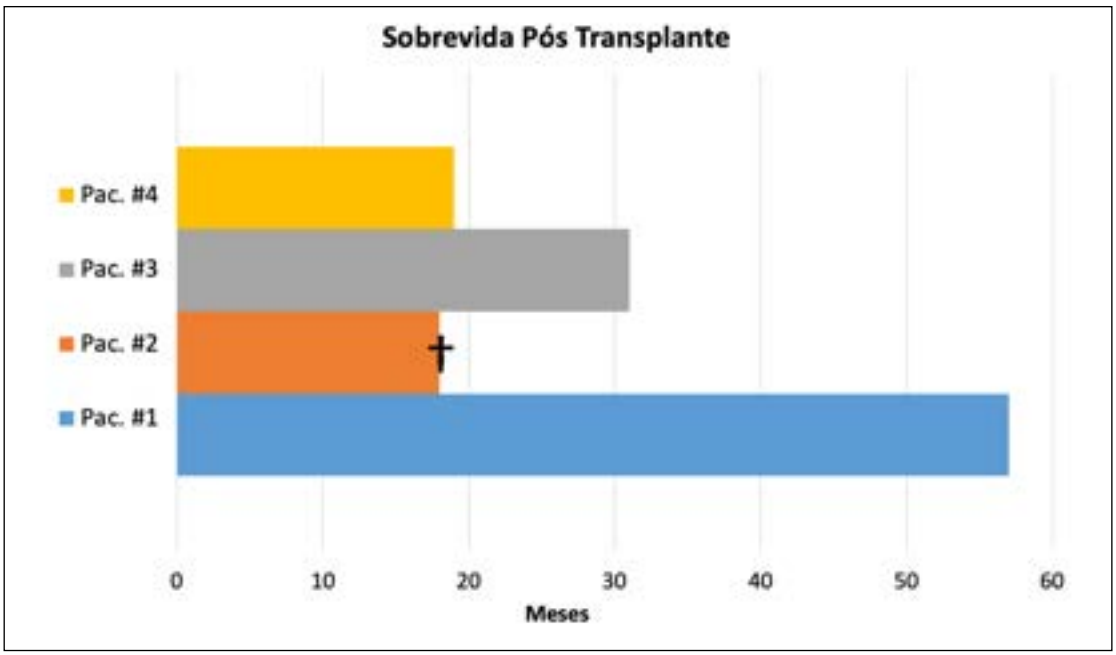

†Falecimento
Fonte: Produção do próprio autor.

Não houve nenhum caso de hérnia, deiscência, infecção de sítio cirúrgico ou qualquer outra complicação relacionada a parede abdominal; também não foi evidenciado casos de coleções ou infecções de foco intra-abdominal. Apesar do grande descolamento promovido pela separação dos componentes, nenhum paciente evoluiu com seroma ou coleções subcutâneas após fechamento completo e remoção do vácuo. O quarto paciente alcançou o fechamento da aponeurose com 10 dias após o transplante. Contudo, devido a sangramento do cólon nativo (segmento distal do colón transverso, colón descendente e reto) o paciente apresentou importante distensão abdominal com dor refratária a analgesia, sendo necessário nova confecção do vácuo na espessura total da parede. Após esse episódio o paciente evoluiu bem, sem novos sangramentos e o fechamento completo da parede abdominal foi concluído com 21 dias. O paciente não apresentou nenhuma complicação relacionada a parede abdominal após o fechamento completo e já foi submetido a cirurgia para reconstrução do trânsito intestinal.

Em todos os casos, a dieta foi reintroduzida antes do fechamento completo da parede abdominal. Todos os pacientes receberam dieta precoce após a abordagem cirúrgica e eram estimulados com fisioterapia motora e deambulação no intervalo dos procedimentos.

Todos os pacientes foram submetidos a reconstrução do trânsito intestinal com retirada da ileostomia num período de 6 a 8 meses do fechamento completo da parede abdominal. Nessa abordagem não foi evidenciado aderências entre alças intestinais e a parede abdominal.

As tomografias computadorizadas dos pacientes demostraram grande aumento do domínio abdominal após o transplante em comparação com os exames pré TI (Figura 12). A mediana da distância anteroposterior no mesmo corte tomográfico dos pacientes no pré-transplante era de 63,2mm (mín: 29mm e máx: 73,3mm) e após o fechamento da parede abdominal a mediana da mesma distância foi de 98,8mm (mín:90mm e máx:124,4mm).

Figura 12 - Exames tomográficos antes e após o transplante de intestino: (a) paciente 1 pré transplante (b) paciente 1 pós transplante (c) paciente 2 pré transplante (d) paciente 2 pós transplante.

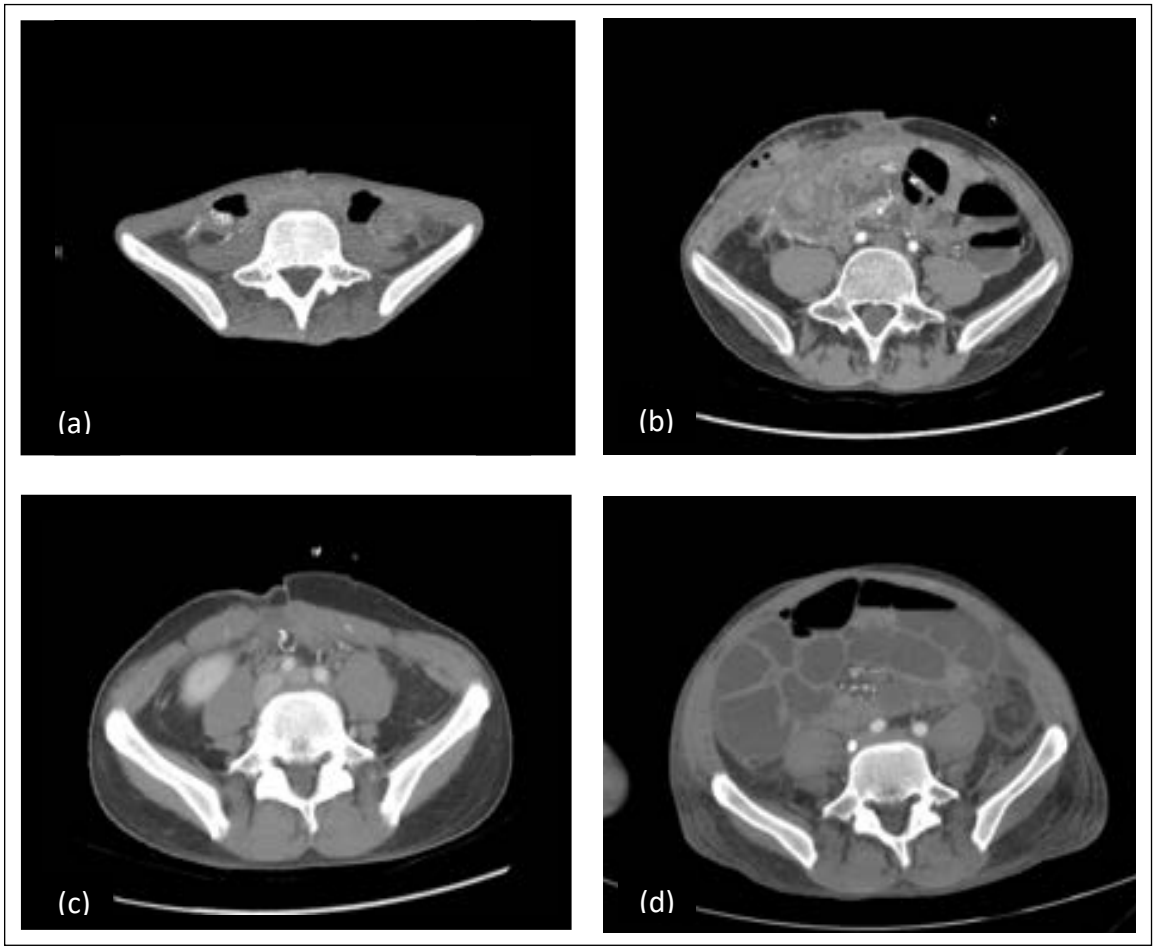

Fonte: Produção do próprio autor.

Em relação as volumetrias abdominais pré TI, a mediana foi de 4.010,7cm^3 (min: 3.681,8cm3 e max: 5.072,9cm^3) e a média de 3.944,02cm^3 com desvio padrão de ±879,42cm^3. Enquanto a mediana após o TI foi de 5.681,9cm^3 (min: 4.562,5cm^3 e max: 6.395,5cm^3), a média foi de 5.580,49cm^3 com desvio padrão de ±692,25cm^3 (Figura 13). O aumento de volume apresentou mediana de 1.455,13cm^3 (min: 921,84cm^3 e max: 2.713,76cm^3), representando um incremento de 41,49% no volume abdominal, a média foi de 1.636,47cm^3 (aumento de 41,66%) com desvio padrão de ±724,51cm^3.

Figura 13 Volumetrias abdominais antes e após transplante de intestino: (a) volumetria abdominal pré transplante de intestino (4339,77cm^3) (b) volumetria abdominal pós transplante de intestino (5369,06cm^3)

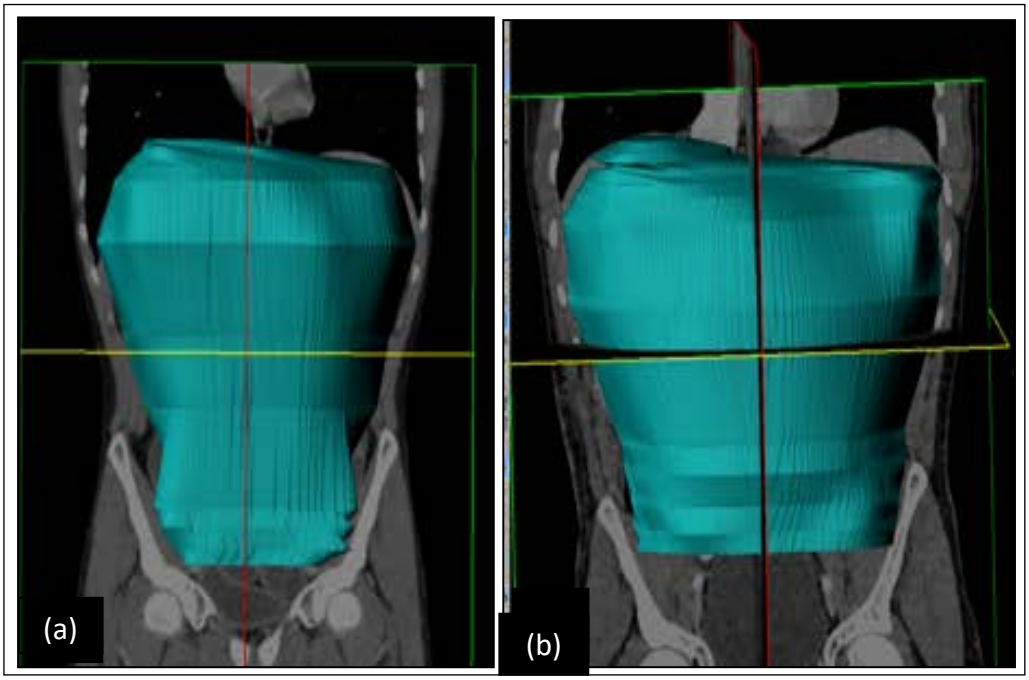

Fonte: Produção do próprio autor.

6 Discussão

5 DISCUSSÃO

O estudo realizado descreve uma técnica original e factível para o fechamento da parede abdominal após o TI, além de apresentar a primeira série brasileira de pacientes submetidos ao TII com sucesso.

A FII, apesar de rara, é uma complicação que afeta diretamente a saúde pública. Estima-se que, no Brasil, cerca de 800 pessoas apresentem FII a cada ano.[43] Esses pacientes tornam-se dependentes de NP diária e devem ficar internados, pois o sistema único de saúde (SUS) não financia NP domiciliar.[44;45;46] Poucos centros médicos brasileiros disponibilizam a NP domiciliar pelo sistema público de saúde, através de convênios com o Ministério da Saúde, contudo as vagas disponíveis são extremamente limitadas. A internação dos pacientes para realização de NP implica em alta morbimortalidade[47;48;49;50] e acarreta despesas relacionadas a hospitalização, mão de obra especializada, uso de equipamentos de alta tecnologia, custos com medicamentos e exames.[51;52] Além do importante impacto na qualidade de vida do paciente que fica restrito ao nosocômio.

Nos últimos 10 anos, a sobrevida global do enxerto e do paciente submetido ao TI melhorou significativamente. A maioria dos pacientes apresenta bom funcionamento do enxerto e completo reestabelecimento da alimentação via oral.[24;37;53;54]

Em um relatório recente do Scientific Registry of Transplant Recipients que cobriu os resultados de janeiro de 2014 a junho de 2016, nos 6 centros dos EUA que realizaram 10 ou mais transplantes de intestino em adultos em

2016, a sobrevida do enxerto em 1 ano variou de 60,5% a 83,0%. Incluindo todos os centros que realizaram pelo menos 1 transplante de intestino adulto, a sobrevida média do enxerto em 1 ano nos EUA foi de 73,6%.[55]

Com a melhora nos resultados dos pacientes submetidos ao TI, a qualidade de vida (QoL) tornou-se um importante desfecho. O objetivo final de qualquer intervenção terapêutica é aliviar a doença e melhorar a QoL. Está bem estabelecido que a QoL em receptores de TI é melhor do que em pacientes com FII em NP. Rovera *et al*.[56;57] relataram uma melhora significativa na QoL no grupo de transplante em comparação com seu estado pré-transplante quando eles estavam recebendo NP. A QoL é uma das principais vantagens do transplante intestinal em comparação com a NP e, portanto, deve ser considerada como uma das possíveis indicações para o transplante intestinal.

Em razão da complexidade do procedimento, poucos centros realizaram TI no mundo. Habitualmente os programas se desenvolveram em instituições onde os programas de transplante de fígado eram bem estabelecidos e com grande número de casos. Atualmente, cerca de 76% dos TI do mundo, ocorrem nos EUA. Em 2020, 16 centros realizaram 43 TII e 48 TI em associação com o fígado, 63% deles em receptores pediátricos (UNOS 2021).

A Disciplina de Transplante de Fígado e Órgãos do Aparelho Digestivo, do Departamento de Gastroenterologia, do Hospital das Clínicas da Faculdade de Medicina da Universidade de São Paulo apresenta quatro casos de TII bem-sucedidos, com independência completa de NP. A perspectiva é beneficiar cada vez mais pacientes portadores de FII com o TI.

O fechamento da parede abdominal após implante do enxerto no TI, implica em alguns agravantes, uma vez que muitos pacientes apresentam redução crônica da cavidade abdominal. Entre os pacientes que obtiveram sucesso no fechamento primário após o TI, cerca de 20 a 33% evoluem com deiscência secundária da ferida operatória, levando a complicações como eviscerações, fístulas e infecções.[1; 2; 3; 6]

Dentre as técnicas propostas na literatura, os expansores de tecido (TE) são comumente usados para fechamento de grandes defeitos de pele e parede abdominal, contudo apresentam várias desvantagens em potencial, como: impossibilidade de previsão da data da realização do TI; exposição adicional a anestesia; dificuldade de cicatrização em pacientes desnutridos e complicações relacionadas à injeção gradual em TE inflável.[58]

Apesar de sua versatilidade, o TE tem sido associado a complicações significativas desde o início do seu uso. Foi relatada uma taxa geral de complicações de 13 a 20%, sendo infecção, migração da prótese e hematoma as mais frequentes.[59] A utilização de TE intraperitoneais pode resultar em complicações potencialmente mais graves, como peritonite e compressão dos órgãos intra-abdominais. A experiência do TE em pacientes que aguardam o TI é limitada devido a preocupações relacionadas ao uso de material estranho em pacientes críticos, bem como a limitações de espaço causadas por fístulas, tecido cicatricial e, muitas vezes, estomas.

Outra técnica frequentemente utilizada para correção de grandes defeitos abdominais é a separação de componentes. Um fator de relevância para bons resultados desta técnica é a necessidade de que os componentes

da parede estejam íntegros, bem vascularizados, inervados e complacentes, ou seja, ausentes de fibrose de cicatrizes prévias.[60] Entretanto, essa é uma condição frequentemente inexistente nos candidatos ao TI, devido a múltiplas abordagens prévias. Outro fator complicador é a presença de estomas na parede abdominal, pois o fechamento do defeito aponeurótico durante a reversão da colostomia/ ileostomia colocaria alguma tensão na fáscia ipsilateral da parede abdominal. Além do mais a técnica não garante o fechamento completo da aponeurose e pele.

A telas tem seu uso amplamente difundido e no geral são a principal escolha para correções abdominais. O uso de próteses no reparo de defeitos da parede abdominal nos pacientes transplantados introduziu novos problemas. Embora a tela reduza as taxas de ocorrência de hérnia, ela tem seu próprio conjunto de complicações; a infecção é uma das complicações mais devastadoras após o implante de qualquer tela.[61] O risco de infecção em correção dos defeitos da parede abdominal parece ser maior do que em outros casos limpos, mas há uma grande variedade relatada na literatura - de 1% a 10%[62] dependendo do tipo de tela, técnica e população de pacientes. A infecção de próteses na parede abdominal pode ter consequências sérias, dispendiosas e impacto grave na vida do paciente, devido a hospitalizações prolongadas, múltiplas re-intervenções e custos sociais muito elevados. A ileostomia próxima a ferida operatória é um fator complicador que associado ao uso de imunossupressores podem acarretar infecções potencialmente fatais aos pacientes. Além do fato que na população do TI, a correção da aponeurose com a tela não resolve o problema do fechamento da pele.

A maioria das técnicas já descritas resolve o problema da pele ou da aponeurose. O transplante de parede abdominal, adotado como técnica alternativa para o fechamento da parede após o TI aumenta complexidade do procedimento, aumentando o tempo de isquemia do enxerto intestinal. Além de colocar o paciente em risco imunológico elevado, visto que a pele é um dos órgãos mais imunogênicos e com maior chance de rejeição. Esse enxerto deve ser vascularizado com anastomoses arteriais e venosas epigástricas que ficam sob risco de complicações. O transplante exclusivo de aponeurose tem risco aumentado de falha, pela menor vascularização desse tipo de enxerto. Além disso, tanto os transplantes exclusivos de aponeurose, como a colocação de tela protética, não eliminam o problema do fechamento da pele.

A técnica do VAC para o fechamento da parede abdominal é uma técnica utilizada para pacientes críticos, particularmente naqueles envolvendo procedimentos cirúrgicos complexos, como vítimas de trauma que foram submetidos a cirurgia de controle de danos, pacientes com infecções intra-abdominais graves, isquemia mesentérica aguda, síndrome compartimental abdominal e infecções necróticas da parede abdominal.[63;64]

Na técnica VAC, a interação da espuma com tecido sob pressão negativa resulta em macro e micro deformações que estimulam a granulação da ferida e aumentam a produção de fator de crescimento pró-angiogênico, acelerando a cicatrização.[65] Além de contribuir para a redução da inflamação sistêmica e de danos aos órgãos abdominais, diminuir a colonização bacteriana e melhorar a deposição de colágeno na ferida.[63;66;67;68;69;70] Em 2001 foi demonstrado que o curativo sob pressão negativa provoca uma força

centrípeta que tem como consequência a aproximação dos bordos da lesão.[70] Cheatham*et al.*[72] concluíram que a técnica de VAC está associada a altas taxas de fechamento abdominal em 30 dias e menor morbimortalidade. O VAC reduz os cuidados médicos e de enfermagem, especialmente em pacientes que apresentam quantidade excessiva de secreção abdominal. Estudos com nível de evidência e grau de recomendação 1A[73] e 2A[74] orientam trocas a cada 48 a 72 horas, o que proporciona um conforto significativo tanto aos pacientes quanto às equipes responsáveis pelo atendimento. Um benefício adicional é a aspiração contínua da cavidade abdominal, o que impede a formação de coleções intra-abdominais. Essas coleções frequentemente irritam a musculatura diafragmática e podem ocasionar derrames pleurais e estímulos álgicos. Com isso o paciente tem potencial para recuperação respiratória e motora mais rápida e eficaz.

A técnica proposta nesse estudo é uma combinação do VAC com separação de componentes e incisões relaxadoras seriadas. É uma técnica facilmente reprodutível que não utiliza próteses sintéticas ou materiais biológicos, permitindo a avaliação do enxerto a cada reabordagem. Com isso há menor potencial para formação de aderências entre alças intestinais e entre as alças com parede abdominal, além de promover uma drenagem otimizada da cavidade abdominal nos primeiros dias do pós-operatório. A troca do VAC não interfere na peristalse intestinal, não impedindo a reintrodução de dieta enteral imediatamente após o procedimento. Durante os intervalos das abordagens é permitido a deambulação sem dificuldades, uma vez que o dispositivo de pressão negativa é móvel e facilmente manipulável.

O potencial de fistulização promovido pelo vácuo é uma possível crítica ao emprego da técnica proposta. Esse risco seria ainda maior nos primeiros dias de pós-operatório, uma vez que as anastomoses são recém confeccionadas e ainda não estão cicatrizadas. Contudo, várias publicações destacaram as vantagens da terapia VAC em abdomes com impossibilidade de fechamento primário, salientado o baixo risco de desenvolvimento de fístula intestinal. Em uma série de 112 pacientes apenas cinco (4,5%) desenvolveram fistula; sendo três do intestino delgado, uma pancreática e uma gástrica.[75] Kaplan *et al.*[76], em 2005, identificaram que o VAC é uma técnica satisfatória para fechamento temporário da cavidade abdominal, relacionado à ocorrência de complicações como fístulas, em apenas 2,6% dos casos. Rao *et al*[56], avaliaram 29 pacientes com fechamento abdominal com o VAC, sendo 14 pacientes com anastomose intestinal e 15 sem anastomose. Dos pacientes com anastomose três desenvolveram fístula intestinal, embora o local da fístula fosse diferente do local da linha de sutura. Nos demais pacientes sem sutura intestinal, três também desenvolveram fístula intestinal. Assim, o estudo sugere que a pressão negativa contínua não predispõem à ocorrência de fístula anastomótica.[56] Uma revisão sistemática e mata-análise publicada por Atema *et al.*[77] identificou 74 estudos que descrevem 78 séries de pacientes, compreendendo 4.358 pacientes, dos quais 3.461 (79%) apresentavam impossibilidade do fechamento abdominal por causas não traumáticas. A taxa mais alta de fístulas foi observada após a associação do fechamento abdominal com tela (17,2%, IC 95% 9,3–29,5%, χ^2 p = 0,012, I^2 = 66%), enquanto VAC com tração fascial mostrou

a menor taxa de fístula ponderada (5,7%, 95% IC 2,2–14,1%, χ^2 p = <0,001, I^2 = 79%). Assim, as complicações intra-abdominais resultantes da terapia VAC não são frequentes.[78] As taxas de complicações mais relatadas na literatura decorrem das comorbidades prévias do paciente e da irritação cutânea pelo uso do adesivo.[79] Além disso, departamentos de grande volume de TI, como o de Georgetown University, já utilizam o VAC no dia do TI como ferramenta para diminuir o edema inicial pós revascularização e possibilitar o implante de tela de menores proporções em um segundo momento, sem relatos de fistulas intestinais.

Uma das limitações do presente estudo foi o baixo número de pacientes incluídos no estudo. Com um número maior de casos provavelmente novas características serão avaliadas e contribuirão para melhores resultados. Além disso, nem todos os pacientes serão elegíveis para fechamento completo com a técnica de separação de componentes associado ao VAC, contudo, o defeito abdominal resultante será de tamanho menor. Essa técnica apresenta como ponto negativo a necessidade de reabordagens cirúrgicas, que podem prolongar o período de internação hospitalar.

A técnica descrita apresenta três importantes benefícios que são: a resolução do defeito tanto da pele quanto da aponeurose, dispensar a utilização de telas protéticas e realizar drenagem eficiente do abdome e subcutâneo, reduzindo o risco de coleções.

7 Conclusões

6 CONCLUSÕES

O presente trabalho descreve uma técnica original para o fechamento da parede abdominal em pacientes submetidos ao TII com perda do domínio abdominal.

A análise da série inicial de casos é mostra que a técnica é factível, eficaz e acessível, aumentando o arsenal de possibilidades para o fechamento da parede abdominal após o TI. Além de ser uma técnica facilmente reprodutível, permite avaliações seriadas do enxerto e potencialmente reduz o risco de coleções de parede ou intra-abdominais.

8 Referências

7 REFERÊNCIAS

1. BOND, G. et al. The impact of positive T-cell lymphocytotoxic crossmatch on intestinal allograft rejection and survival. Transplant Proc, v. 32, n. 6, p. 1197-8, Sep 2000.

2. DUDRICK, S. J. et al. Long-term total parenteral nutrition with growth, development, and positive nitrogen balance. Surgery, v. 64, n. 1, p. 134-42, Jul 1968.

3. GOULET, O.; RUEMMELE, F. Causes and management of intestinal failure in children. Gastroenterology, v. 130, n. 2 Suppl 1, p. S16-28, Feb 2006.

4. GONZÁLEZ-SALAZAR, L. E.; GUEVARA-CRUZ, M.; SERRALDE-ZÚÑIGA, A. E. Medical and nutritional treatment in adult patients with acute intestinal failure. Rev Clin Esp, v. 219, n. 3, p. 151-160, Apr 2019.

5. REYES, J. D. Intestinal transplantation. Semin Pediatr Surg, v. 15, n. 3, p. 228-34, Aug 2006.

6. MAZARIEGOS, G. V. Intestinal transplantation: current outcomes and opportunities. Curr Opin Organ Transplant, v. 14, n. 5, p. 515-21, Oct 2009.

7. MESSING, B. et al. Long-term survival and parenteral nutrition dependence in adult patients with the short bowel syndrome. Gastroenterology, v. 117, n. 5, p. 1043-50, Nov 1999.

8. O'KEEFE, S. J. et al. Nutrition and quality of life following small intestinal transplantation. Am J Gastroenterol, v. 102, n. 5, p. 1093-100, May 2007.

9. VIANNA, R. M.; MANGUS, R. S.; TECTOR, A. J. Current status of small bowel and multivisceral transplantation. Adv Surg, v. 42, p. 129-50, 2008.

10. BUCHMAN, A. L.; SCOLAPIO, J.; FRYER, J. AGA technical review on short bowel syndrome and intestinal transplantation. Gastroenterology, v. 124, n. 4, p. 1111-34, Apr 2003.

11. PIRONI, L. et al. Survival of patients identified as candidates for intestinal transplantation: a 3-year prospective follow-up. Gastroenterology, v. 135, n. 1, p. 61-71, Jul 2008.

12. HOWARD, L.; HASSAN, N. Home parenteral nutrition. 25 years later. Gastroenterol Clin North Am, v. 27, n. 2, p. 481-512, Jun 1998.

13. GOULET, O. et al. Irreversible intestinal failure. J Pediatr Gastroenterol Nutr, v. 38, n. 3, p. 250-69, Mar 2004.

14. ALEXANDRIDES, I. J. et al. Abdominal wall closure after intestinal transplantation. Plast Reconstr Surg, v. 106, n. 4, p. 805-12, Sep 2000.

15. CHAN, S. et al. Incidence, prognosis, and etiology of end-stage liver disease in patients receiving home total parenteral nutrition. Surgery, v. 126, n. 1, p. 28-34, Jul 1999.

16. LILLEHEI, R. C.; GOOTT, B.; MILLER, F. A. The physiological response of the small bowel of the dog to ischemia including prolonged in vitro preservation of the bowel with successful replacement and survival. Ann Surg, v. 150, n. 4, p. 543-60, Oct 1959.

17. ALICAN, F. et al. Intestinal transplantation: laboratory experience and report of a clinical case. Am J Surg, v. 121, n. 2, p. 150-9, Feb 1971.

18. OKUMURA, M. et al. [Transplantation of the small intestine. Case report]. Rev Hosp Clin Fac Med Sao Paulo, v. 24, n. 1, p. 39-54, Jan-Feb 1969.

19. LEVI, D. M. et al. Transplantation of the abdominal wall. Lancet, v. 361, n. 9376, p. 2173-6, Jun 2003.

20. CALNE, R. Y. et al. Cyclosporin A initially as the only immunosuppressant in 34 recipients of cadaveric organs: 32 kidneys, 2 pancreases, and 2 livers. Lancet, v. 2, n. 8151, p. 1033-6, Nov 17 1979.

21. GOULET, O. et al. Two and one-half-year follow-up after isolated cadaveric small bowel transplantation in an infant. Transplant Proc, v. 24, n. 3, p. 1224-5, Jun 1992.

22. GRANT, D. et al. Successful small-bowel/liver transplantation. Lancet, v. 335, n. 8683, p. 181-4, Jan 27 1990. I

23. DIMARTINI, A. et al. Quality of Life After Small Intestinal Transplantation and Among Home Parenteral Nutrition Patients. Journal of Parenteral and Enteral Nutrition, v. 22, n. 6, p. 357-362, 1998/11/01 1998.

24. ABU-ELMAGD, K. et al. Clinical intestinal transplantation: a decade of experience at a single center. Ann Surg, v. 234, n. 3, p. 404-16; discussion 416-7, Sep 2001.

25. DIONIGI, P.; ALESSIANI, M.; FERRAZI, A. Irreversible intestinal failure, nutrition support, and small bowel transplantation. Nutrition, v. 17, n. 9, p. 747-50, Sep 2001.

26. GALVAO, F. H. et al. Experimental animal model of graft-versus-host disease (GVHD) after small-bowel transplantation: characteristics of the model and application to developing treatment strategies. Transplant Proc, v. 29, n. 1-2, p. 700, Feb-Mar 1997.

27. KATO, T. et al. Intestinal and multivisceral transplantation. World J Surg, v. 26, n. 2, p. 226-37, Feb 2002.

28. PÉCORA, R. A. A. et al. Transplante de intestino delgado. ABCD. Arquivos Brasileiros de Cirurgia Digestiva (São Paulo), v. 26, p. 223-229, 2013.

29. FISHBEIN, T. M. et al. Isolated intestinal transplantation: proof of clinical efficacy. Transplantation, v. 76, n. 4, p. 636-40, Aug 27 2003.

30. LAURO, A. et al. Twenty-seven consecutive intestinal and multivisceral transplants in adult patients: a 4-year clinical experience. Transplant Proc, v. 37, n. 6, p. 2679-81, Jul-Aug 2005.

31. JEPPESEN, P. B.; STAUN, M.; MORTENSEN, P. B. Adult patients receiving home parenteral nutrition in Denmark from 1991 to 1996: who will benefit from intestinal transplantation? Scand J Gastroenterol, v. 33, n. 8, p. 839-46, Aug 1998.

32. MESSING, B. et al. Prognosis of patients with nonmalignant chronic intestinal failure receiving long-term home parenteral nutrition. Gastroenterology, v. 108, n. 4, p. 1005-10, Apr 1995.

33. GONDOLESI, G. et al. Use of the Abdominal Rectus Fascia as a Nonvascularized Allograft for Abdominal Wall Closure After Liver, Intestinal, and Multivisceral Transplantation. Transplantation, v. 87, n. 12, 2009.

34. CARLSEN, B. T. et al. Incidence and Management of Abdominal Wall Defects after Intestinal and Multivisceral Transplantation. Plastic and Reconstructive Surgery, v. 119, n. 4, 2007.

35. ZANFI, C. et al. Incidence and management of abdominal closure-related complications in adult intestinal transplantation. Transplantation, v. 85, n. 11, p. 1607-9, Jun 15 2008.

36. CASAVILLA, A. et al. Donor selection and surgical technique for en bloc liver-small bowel graft procurement. Transplant Proc, v. 25, n. 4, p. 2622-3, Aug 1993.

37. FRYER, J. P. Intestinal transplantation: current status. Gastroenterol Clin North Am, v. 36, n. 1, p. 145-59, vii, Mar 2007.

38. NERY, J. R. et al. Is the graft too big or too small? Technical variations to overcome size incongruity in visceral organ transplantation. Transplant Proc, v. 30, n. 6, p. 2640-1, Sep 1998.

39. GREVIOUS, M. A. et al. Staged approach for abdominal wound closure following combined liver and intestinal transplantation from living donors in pediatric patients. Pediatric Transplantation, v. 13, n. 2, p. 177-181, 2009/03/01 2009.

40. JERNIGAN, T. W. et al. Staged management of giant abdominal wall defects: acute and long-term results. Ann Surg, v. 238, n. 3, p. 349-55; discussion 355-7, Sep 2003. I

41. FORTUNATO, A. C. et al. Techniques for Closing the Abdominal Wall in Intestinal and Multivisceral Transplantation: A Systematic Review. Annals of transplantation vol. 27 e934595. 1 Mar. 2022

42. MOHER, D. et al. Preferred reporting items for systematic reviews and meta-analyses: the PRISMA statement. PLoS med, v. 6, n. 7, p. e1000097, 2009.

43. LEE, A. D. W. et al. Home parenteral nutrition program and referral of potential candidates for intestinal and multivisceral transplantation in a single Brazilian center. Transplantation proceedings, v. 46, n. 6, p. 1839-1841, 2014 Jul-Aug 2014.

44. GALVÃO, F. H. et al. [Small intestine transplantation]. Arq Gastroenterol, v. 40, n. 2, p. 118-25, Apr-Jun 2003.

45. TANNURI, U. [Short bowel syndrome in children--treatment with home parenteral nutrition]. Rev Assoc Med Bras (1992), v. 50, n. 3, p. 330-7, Jul-Sep 2004.

46. BAKONYI NETO, A. et al. Demographic of short gut syndrome: increasing demand is not followed by referral of potential candidates for small bowel transplantation. Transplant Proc, v. 36, n. 2, p. 259-60, Mar 2004.

47. WINKLER, M. F.; SMITH, C. E. Clinical, social, and economic impacts of home parenteral nutrition dependence in short bowel syndrome. JPEN J Parenter Enteral Nutr, v. 38, n. 1 Suppl, p. 32s-37s, May 2014.

48. WANTEN, G. J. Parenteral approaches in malabsorption: Home parenteral nutrition. Best Pract Res Clin Gastroenterol, v. 30, n. 2, p. 309-18, Apr 2016.

49. HOWARD, L. Home parenteral nutrition: survival, cost, and quality of life. Gastroenterology, v. 130, n. 2 Suppl 1, p. S52-9, Feb 2006.

50. GIRKE, J. et al. Quality of Life and Nutrition Condition of Patients Improve Under Home Parenteral Nutrition: An Exploratory Study. Nutr Clin Pract, v. 31, n. 5, p. 659-65, Oct 2016.

51. OKUMURA, M.; MESTER, M. The coming of age of small bowel transplantation: a historical perspective. Transplant Proc, v. 24, n. 3, p. 1241-2, Jun 1992.

52. GOLDSTEIN, M.; BRAITMAN, L. E.; LEVINE, G. M. The medical and financial costs associated with termination of a nutrition support nurse. JPEN J Parenter Enteral Nutr, v. 24, n. 6, p. 323-7, Nov-Dec 2000.

53. MAZARIEGOS, G. V. et al. Intestine transplantation in the United States, 1999-2008. Am J Transplant, v. 10, n. 4 Pt 2, p. 1020-34, Apr 2010.

54. VIANNA, R. M.; MANGUS, R. S. Present prospects and future perspectives of intestinal and multivisceral transplantation. Current opinion in clinical nutrition and metabolic care, v. 12, n. 3, p. 281-286, 2009/05// 2009.

55 MATSUMOTO, C. S.; SUBRAMANIAN, S.; FISHBEIN, T. M. Adult Intestinal Transplantation. Gastroenterol Clin North Am, v. 47, n. 2, p. 341-354, Jun 2018.

56. RAO, M. et al. The use of vacuum-assisted closure of abdominal wounds: a word of caution. Colorectal Dis, v. 9, n. 3, p. 266-8, Mar 2007.

57. ROVERA, G. M. et al. Quality of life of patients after intestinal transplantation. Transplantation, v. 66, n. 9, p. 1141-5, Nov 15 1998.

58. CEULEMANS, L. J. et al. The role of osmotic self-inflatable tissue expanders in intestinal transplant candidates. Transplant Rev (Orlando), v. 30, n. 4, p. 212-7, 10 2016.

59. CLIFTON, M. S. et al. Use of tissue expanders in the repair of complex abdominal wall defects. J Pediatr Surg, v. 46, n. 2, p. 372-7, Feb 2011.

60. SHESTAK, K. C.; EDINGTON, H. J.; JOHNSON, R. R. The separation of anatomic components technique for the reconstruction of massive midline abdominal wall defects: anatomy, surgical technique, applications, and limitations revisited. Plast Reconstr Surg, v. 105, n. 2, p. 731-8; quiz 739, Feb 2000.

61. KRPATA, D. M. et al. Evaluation of high-risk, comorbid patients undergoing open ventral hernia repair with synthetic mesh. Surgery, v. 153, n. 1, p. 120-125, 2013.

62. BROWN, R. H. et al. Comparison of infectious complications with synthetic mesh in ventral hernia repair. The American Journal of Surgery, v. 205, n. 2, p. 182-187, 2013.

63. MARINIS, A. et al. "Enteroatmospheric Fistulae"--Gastrointestinal Openings in the Open Abdomen: A Review and Recent Proposal of a Surgical Technique. Scandinavian journal of surgery : SJS : official organ for the Finnish Surgical Society and the Scandinavian Surgical Society, v. 102, p. 61-68, 06/01 2013.

64. D'HONDT, M. et al. Treatment of small-bowel fistulae in the open abdomen with topical negative-pressure therapy. Am J Surg, v. 202, n. 2, p. e20-4, Aug 2011.

65. TRUEMAN, P. et al. The feasibility of using V.A.C.® Therapy in home care patients with surgical and traumatic wounds in the Netherlands. International Wound Journal, v. 5, n. 2, p. 225-231, 2008/05/01 2008.

66. MENDEZ-EASTMAN, S. Negative pressure wound therapy. Plast Surg Nurs, v. 18, n. 1, p. 27-9, 33-7, Spring 1998.

67. GOVERMAN, J. et al. The "Fistula VAC," a technique for management of enterocutaneous fistulae arising within the open abdomen: report of 5 cases. J Trauma, v. 60, n. 2, p. 428-31; discussion 431, Feb 2006.

68. CIPOLLA, J. et al. Negative pressure wound therapy: Unusual and innovative applications. OPUS 12 Scientist; Volume 2, Number 3 (May-Jun 2008); 15-29, v. 2, 01/01 2008.

69. KUBIAK, B. D. et al. Peritoneal negative pressure therapy prevents multiple organ injury in a chronic porcine sepsis and ischemia/reperfusion model. Shock, v. 34, n. 5, p. 525-34, Nov 2010.

70. JACOBS, S. et al. Efficacy and mechanisms of vacuum-assisted closure (VAC) therapy in promoting wound healing: a rodent model. J Plast Reconstr Aesthet Surg, v. 62, n. 10, p. 1331-8, Oct 2009.

71. FRANCIOSI LFN, L. L.; VIEIRA VRS, C. M., SOUZA MRP. O uso de curativos a vácuocomo tratamento intermediário no trauma complexo de extremidade: experiência clínica e padronização técnica. Arq. Catar. Med. 39: 50-60 p. 2010.

72. CHEATHAM, M. L. et al. Prospective study examining clinical outcomes associated with a negative pressure wound therapy system and Barker's vacuum packing technique. World J Surg, v. 37, n. 9, p. 2018-30, Sep 2013.

73. GÄDDNÄS, F. et al. Continuous retention suture for the management of open abdomen: a high rate of delayed fascial closure. Scandinavian journal of surgery : SJS : official organ for the Finnish Surgical Society and the Scandinavian Surgical Society, v. 96, n. 4, p. 301-307, 2007 2007.

74. GRACIAS, V. H. et al. Abdominal compartment syndrome in the open abdomen. Arch Surg, v. 137, n. 11, p. 1298-300, Nov 2002.

75. BARKER, D. E. et al. Vacuum pack technique of temporary abdominal closure: a 7-year experience with 112 patients. J Trauma, v. 48, n. 2, p. 201-6; discussion 206-7, Feb 2000.

76. M, K. Guidelines for the management of the open abdomen. BANWELL P, O. D., IVATURY RR, DEMETRIADES VD, MOORE FA, ET AL. Dallas: HMP Communication; 2005.

77. ATEMA, J. J.; GANS, S. L.; BOERMEESTER, M. A. Systematic review and meta-analysis of the open abdomen and temporary abdominal closure techniques in non-trauma patients. World J Surg, v. 39, n. 4, p. 912-25, Apr 2015.

78. MILLER, P. R. et al. Prospective evaluation of vacuum-assisted fascial closure after open abdomen: planned ventral hernia rate is substantially reduced. Ann Surg, v. 239, n. 5, p. 608-14; discussion 614-6, May 2004.

79. LEIJNEN, M. et al. Does VAC increase the risk of venous thromboembolism? J Wound Care, v. 16, n. 5, p. 211-2, May 2007.

8 Apêndices

APÊNDICE A

TERMO DE CONSENTIMENTO LIVRE E ESCLARECIDO

DADOS DE IDENTIFICAÇÃO DO PARTICIPANTE DA PESQUISA OU RESPONSÁVEL LEGAL

1. NOME: .:..... .....

DOCUMENTO DE IDENTIDADE Nº : ..... SEXO : .M □ F □

DATA NASCIMENTO: ...../...../.....

ENDEREÇO ..... Nº ..... APTO: .....

BAIRRO: ..... CIDADE .....

CEP:..... TELEFONE: DDD (.....) .....

2.RESPONSÁVEL LEGAL .....

NATUREZA (grau de parentesco, tutor, curador etc.) .....

DOCUMENTO DE IDENTIDADE :.....SEXO: M □ F □

DATA NASCIMENTO.: ...../...../.....

ENDEREÇO: ..... Nº ..... APTO: .....

BAIRRO: ..... CIDADE: .....

CEP: ..... TELEFONE: DDD (.....).....

DADOS SOBRE A PESQUISA

1. TÍTULO DO PROTOCOLO DE PESQUISA: **Desenvolvimento da Técnica para o Fechamento da Parede Abdominal com o Uso Do Curativo à Vácuo Associado a Incisões Relaxadoras no Transplante de Intestino e Multivisceral.**

2. PESQUISADOR: Allana Christina Fortunato Maciel

CARGO/FUNÇÃO: médica INSCRIÇÃO CONSELHO REGIONAL Nº: 183146

UNIDADE DO HCFMUSP: "Faculdade de Medicina da Universidade de São Paulo"

3. AVALIAÇÃO DO RISCO DA PESQUISA:

RISCO MÍNIMO	x	RISCO MÉDIO	□
RISCO BAIXO	□	RISCO MAIOR	□

4.DURAÇÃO DA PESQUISA: 4 anos

5. APRESENTAÇÃO:

Convidamos o(a) senhor(a) a participar de uma pesquisa científica. Pesquisa é um conjunto de procedimentos que procura criar ou aumentar o conhecimento sobre um assunto. Estas descobertas embora frequentemente não tragam benefícios diretos ao participante da pesquisa, podem no futuro ser úteis para muitas pessoas.

Para decidir se aceita ou não participar desta pesquisa, o(a) senhor(a) precisa entender o suficiente sobre os riscos e benefícios, para que possa fazer um julgamento consciente. Inicialmente explicaremos as razões da pesquisa. A seguir, forneceremos um termo de consentimento livre e esclarecido (TCLE), documento que contém informações sobre a pesquisa, para que leia e discuta com familiares e ou outras pessoas de sua confiança. Uma

vez compreendido o objetivo da pesquisa e havendo seu interesse em participar, será solicitada a sua rubrica em todas as páginas do TCLE e sua assinatura na última página. Uma via assinada deste termo deverá ser retida pelo senhor(a) ou por seu representante legal e uma cópia será arquivada pelo pesquisador responsável.

5A) Justificativa, objetivos e procedimentos:

O estudo tem como objetivo coletar dados para descrever uma nova técnica de fechamento abdominal para pacientes submetidos ao transplante de intestino. A técnica estudada consiste no fechamento seriado da parede abdominal com auxílio do curativo a vácuo combinado com técnicas de separação de componentes. Este procedimento faz parte do conjunto de atos cirúrgicos do transplante de intestino. Nenhum procedimento adicional ser será realizado caso o senhor(a) concorde em participar desta pesquisa.

5B) Desconfortos, riscos e benefícios

O estudo não apresenta riscos e/ou benefícios direto para o(a) senhor(a). Serão coletados apenas dados de prontuários e fotografias dos procedimentos realizados. O tipo de técnica estudada é parte do conjunto de procedimentos que engloba o transplante de intestino, sendo apenas os seus dados utilizados na pesquisa. Nenhum procedimento adicional será realizado se o senhor(a) concordar em participar da pesquisa.

5C) Forma de acompanhamento e assistência

O(A) senhor(a) será acompanhado pela equipe médica do hospital durante o estudo e após o término do mesmo.

Em qualquer etapa do estudo, o(a) senhor(a) terá acesso aos profissionais responsáveis pela pesquisa. O investigador principal é **Wellington Andraus**, que pode ser encontrado no **Hospital das Clínicas da FMUSP, oitavo andar, setor de transplante de fígado,** Telefone (11) 2661-5000, horário de 07:00 as 17:00h.

O investigador executante é **Allana Christina Fortunato Maciel** que pode ser encontrado no Hospital das Clínicas da FMUSP, oitavo andar, departamento de transplante de fígado Telefone (11)2661-5000, horário de atendimento das 7:00 as 17:00 horas.

Se apresentar qualquer evento adverso, entre em contato com os investigadores ou ligue para **Telefone 24 horas (35) 984313572.**

Se você tiver alguma consideração ou dúvida sobre a ética da pesquisa, entre em contato com o Comitê de Ética em Pesquisa da Faculdade de Medicina da Universidade de São Paulo (**CEP-FMUSP**): Av. Dr. Arnaldo, 251 - Cerqueira César - São Paulo - SP -21º andar – sala 36- CEP: 01246-000, horário de atendimento: 8:00-17:00h; Tel: (11) 3893-4401/4407 E-mail: cep.fm@usp.br

5D) Liberdade de recusar-se e retirar-se do estudo

A escolha de entrar ou não nesse estudo é inteiramente sua. Caso o(a) senhor(a) se recuse a participar deste estudo, o(a) senhor(a) receberá o tratamento habitual, sem qualquer tipo de prejuízo ou represália. O(A) senhor(a) também tem o direito de retirar-se deste estudo a qualquer momento e, se isso acontecer, seu médico continuará a tratá-lo(a) sem qualquer prejuízo ao tratamento ou represália.

5E) Manutenção do sigilo e privacidade

Os seus dados serão analisados em conjunto com outros pacientes, não sendo divulgado a identificação de nenhum paciente sob qualquer circunstância.

Solicitamos sua autorização para que os dados obtidos nesta pesquisa sejam utilizados em uma publicação científica, meio como os resultados de uma pesquisa são divulgados e compartilhados com a comunidade científica.

5F) O (A) senhor(a) receberá uma via deste Termo de Consentimento Livre e Esclarecido.

5G) Garantia de Ressarcimento

O(A) senhor(a) não terá qualquer custo, pois o custo desta pesquisa será de responsabilidade do orçamento da pesquisa. O (A) senhor(a) tem direito a ressarcimento em caso de despesas decorrentes da sua participação na pesquisa.

5H) Garantia de indenização

O (A) senhor(a) tem direito à indenização diante de eventuais danos decorrentes da pesquisa.

Acredito ter sido suficientemente informado a respeito das informações que li ou que foram lidas para mim, descrevendo o estudo **Título da Pesquisa Desenvolvimento da Técnica para o Fechamento da Parede Abdominal com o Uso Do Curativo à Vácuo Associado a Incisões Relaxadoras no Transplante de Intestino e Multivisceral.**

Eu discuti com a Dra Allana Christina Fortunato Maciel sobre a minha decisão em participar nesse estudo. Ficaram claros para mim quais são os propósitos do estudo, os procedimentos a serem realizados, seus desconfortos e riscos, as garantias de confidencialidade e de esclarecimentos permanentes. Ficou claro também que minha participação é isenta de despesas e que tenho garantia do acesso a tratamento hospitalar, quando necessário. Concordo voluntariamente em participar deste estudo e poderei retirar o meu consentimento a qualquer momento, antes ou durante o mesmo, sem penalidades ou prejuízo ou perda de qualquer benefício que eu possa ter adquirido, ou no meu atendimento neste Serviço.

---------- Data / /
Assinatura do paciente/representante legal

---------- Data / /
Assinatura da testemunha

(Somente para o responsável do projeto)
Declaro que obtive de forma apropriada e voluntária o Consentimento Livre e Esclarecido deste paciente ou representante legal para a participação neste estudo.

Assinatura do responsável pelo estudo Data / /

APÊNDICE B

APROVAÇÃO DA COMISSÃO DE ÉTICA E PESQUISA

PARECER CONSUBSTANCIADO DO CEP

DADOS DO PROJETO DE PESQUISA

Título da Pesquisa: Avaliação da técnica de curativo à vácuo seriado para o fechamento da parede abdominal no transplante de intestino

Pesquisador: WELLINGTON ANDRAUS

Área Temática:

Versão: 1

CAAE: 25935019.4.0000.0068

Instituição Proponente: Hospital das Clínicas da Faculdade de Medicina da USP

Patrocinador Principal: Financiamento Próprio

DADOS DO PARECER

Número do Parecer: 3.730.175

Apresentação do Projeto:

Falência intestinal (FI) é a denominação dada aos pacientes incapazes de manter homeostase através da absorção enteral de nutrientes, eletrólitos e água e pode ser classificada como transitória ou irreversível. O tratamento definitivo dessa condição é o transplante de intestino (TI). Dentre as etiologias de FI irreversível (FII) a síndrome do intestino curto (SIC) é a mais comum, um agravante do TI nessa condição é a dificuldade do fechamento primário da parede abdominal após implante do enxerto, devido a atrofia crônica da musculatura abdominal com redução da cavidade. As estratégias existentes para fechamento da parede abdominal após o TI implicam na utilização de telas ou do transplante de parede abdominal de doador falecido, acarretando em elevado custo financeiro e alto risco de complicações infecciosas, imunológicas e do surgimento de aderências. O curativo à vácuo seriado é uma estratégia empregada no fechamento da parede abdominal de pacientes com condições agudas que dificultam o fechamento abdominal. Objetivo: O objetivo do estudo é avaliar a utilização da técnica do curativo à vácuo seriado (VAC) para o fechamento da parede abdominal após o transplante de intestino em pacientes com redução crônica da cavidade abdominal.Método: Serão avaliados pacientes com SIC, que desenvolveram redução crônica da cavidade abdominal, submetidos ao TI com fechamento da parede abdominal com técnica VAC, no Hospital das Clínicas da Faculdade de Medicina da Universidade de São Paulo.

Endereço: Rua Ovídio Pires de Campos, 225 5º andar
Bairro: Cerqueira Cesar **CEP:** 05.403-010
UF: SP **Município:** SAO PAULO
Telefone: (11)2661-7585 **Fax:** (11)2661-7585 **E-mail:** cappesq.adm@hc.fm.usp.br

Objetivo da Pesquisa:

O objetivo do estudo é avaliar a utilização da técnica do curativo à vácuo seriado (VAC) para o fechamento da parede abdominal após o transplante de intestino em pacientes com redução crônica da cavidade abdominal.

Avaliação dos Riscos e Benefícios:

Riscos: Não há riscos adicionais a paciente que concorde em participar do estudo, excetuando-se os riscos inerentes ao transplante e o manejo da imunossupressão pós operatória.Benefícios: Fechamento efetivo da parede abdominal, minimizando as complicações e oferecendo conforto ao paciente.

Comentários e Considerações sobre a Pesquisa:

Considerar risco mínimo de danificar o prontuário durante seu manuseio.Caso algum novo paciente seja incluído no estudo deverá anexar o TCLE ao projeto e informar ao CEP.

Considerações sobre os Termos de apresentação obrigatória:

Aceito a dispensa do TCLE por se tratar de um estudo analítico e retrospectivo.Caso algum novo paciente seja incluído no estudo, o TCLE será aplicado conforme informado pelo pesquisador no projeto.

Conclusões ou Pendências e Lista de Inadequações:

Não apresenta pendência ou necessidade de adequações.

Considerações Finais a critério do CEP:

Em conformidade com a Resolução CNS nº 466/12 – cabe ao pesquisador: a) desenvolver o projeto conforme delineado; b) elaborar e apresentar relatórios parciais e final; c)apresentar dados solicitados pelo CEP, a qualquer momento; d) manter em arquivo sob sua guarda, por 5 anos da pesquisa, contendo fichas individuais e todos os demais documentos recomendados pelo CEP; e) encaminhar os resultados para publicação, com os devidos créditos aos pesquisadores associados e ao pessoal técnico participante do projeto; f) justificar perante ao CEP interrupção do projeto ou a não publicação dos resultados.

Este parecer foi elaborado baseado nos documentos abaixo relacionados:

Tipo Documento	Arquivo	Postagem	Autor	Situação
Informações Básicas do Projeto	PB_INFORMAÇÕES_BÁSICAS_DO_PROJETO_1469904.pdf	20/11/2019 00:05:40		Aceito

Endereço: Rua Ovídio Pires de Campos, 225 5º andar
Bairro: Cerqueira Cesar **CEP:** 05.403-010
UF: SP **Município:** SAO PAULO
Telefone: (11)2661-7585 **Fax:** (11)2661-7585 **E-mail:** cappesq.adm@hc.fm.usp.br

Outros	Semcusto.pdf	20/11/2019 00:03:19	WELLINGTON ANDRAUS	Aceito
Projeto Detalhado / Brochura Investigador	doutorado_20_11.docx	20/11/2019 00:00:58	WELLINGTON ANDRAUS	Aceito
Folha de Rosto	FRWELLINGTONANDRAUS.pdf	18/11/2019 19:40:58	WELLINGTON ANDRAUS	Aceito
Declaração de Pesquisadores	termocompromisso.pdf	18/11/2019 19:17:59	WELLINGTON ANDRAUS	Aceito
TCLE / Termos de Assentimento / Justificativa de Ausência	justificativa.pdf	18/11/2019 19:14:58	WELLINGTON ANDRAUS	Aceito
Cronograma	CRONOGRAMA.docx	18/11/2019 18:59:01	WELLINGTON ANDRAUS	Aceito

Situação do Parecer:
Aprovado

Necessita Apreciação da CONEP:
Não

SAO PAULO, 27 de Novembro de 2019

Assinado por:
Joel Faintuch
(Coordenador(a))

Endereço: Rua Ovídio Pires de Campos, 225 5º andar
Bairro: Cerqueira Cesar **CEP:** 05.403-010
UF: SP **Município:** SAO PAULO
Telefone: (11)2661-7585 **Fax:** (11)2661-7585 **E-mail:** cappesq.adm@hc.fm.usp.br

APÊNDICE C

ARTIGOS PUBLICADOS COMO RESULTADO DA TESE

CLINICS

COMMENTS

First Successful Isolated Intestinal Transplant in a Brazilian Series

Wellington Andraus,[I] Rafael Soares Pinheiro,[I,*] Allana Christina Fortunato,[I] Flavio Henrique Ferreira Galvão,[I] Rubens Macedo Arantes Junior,[I] Daniel Reis Waisberg,[I] Andre Dong Lee,[I] Mariana Hollanda Martins da Rocha,[II] Lucas Souto Nacif,[I] Vinicius Rocha Santos,[I] Liliana Ducatti,[I] Rodrigo Bronze de Martino,[I] Luciana Bertocco de Paiva Haddad,[I] Ryan Yukimatsu Tanigawa,[III] Regis O.F. Bezerra,[IV] Alice Tung Wan Song,[I] Luiz Augusto Carneiro-D'Albuquerque[I]

[I]Disciplina de Transplante de Figado e Orgaos do Aparelho Digestivo, Departamento de Gastroenterologia, Hospital das Clinicas HCFMUSP, Faculdade de Medicina, Universidade de Sao Paulo, Sao Paulo, SP, BR. [II]Unidade de Nutrologia, Departamento de Gastroenterologia, Hospital das Clinicas HCFMUSP, Faculdade de Medicina, Universidade de Sao Paulo, Sao Paulo, SP, BR. [III]Disciplina de Anatomia Patologica, Hospital das Clinicas HCFMUSP, Faculdade de Medicina, Universidade de Sao Paulo, Sao Paulo, SP, BR. [IV]Departamento de Radiologia, Instituto do Cancer do Estado de Sao Paulo (ICESP), Hospital das Clinicas HCFMUSP, Faculdade de Medicina, Universidade de Sao Paulo, Sao Paulo, SP, BR.

Andraus W, Pinheiro RS, Fortunato AC, Galvão FHF, Arantes Junior RM, Waisberg DR. First Successful Isolated Intestinal Transplant in a Brazilian Series. (Sao Paulo) Clinics. 2021;76:e3016

*Corresponding author. E-mail: rsnpinheiro@gmail.com

Intestinal failure (IF) is the inability to maintain nutritional and hydroelectrolytic support in the digestive tract (1-3). Patients with irreversible IF depend lifelong on total parenteral nutrition (PN).

The advent of PN has contributed to longer survival and better quality of life (QoL) for these patients; however, the prolonged use of PN can lead to complications that may result in failure of nutritional therapy, infections, and vein thrombosis. Currently, intestinal transplantation (IT) is the treatment of choice for most patients with IF who develop complications related to PN.

The most common etiology of IF is short bowel syndrome, accounting for 35%–75% of cases (4,5), and it is generally a consequence of multiple resections of different parts of the intestine.

In 1968, Okumura et al. (6) made the first attempt at IT in adults at the Hospital das Clinicas of the University of São Paulo (HC-FMUSP). From 1964 to 1970, eight other attempts were made in this direction, but the results were poor, with only one patient surviving for more than 30 days (7). The negative results of these patients were attributed to technical complications, infections, and immunosuppression (7).

In 1990, tacrolimus (FK), a more potent calcineurin inhibitor than cyclosporine, was introduced in clinical practice. This new medication led to a significant improvement in the survival rates of transplant patients and organs because of better rejection control. In 2001, IT was accepted in the USA as a therapeutic modality for patients with irreversible intestinal failure who had complications related to PN. However, the number of transplants performed remained few because of the complexity of the entire procedure. In Latin America, it was only after 2004 that a few units of IT were established in countries such as Argentina, Brazil, and Colombia (8). In Brazil, only a few attempts of isolated IT have been made, but without success.

Nevertheless, this scenario has since changed; here, we report the first successful series of isolated IT in Brazil.

The patients were operated at HC-FMUSP between 2017 and 2021. Four patients underwent isolated IT because of short bowel syndrome.

The IT technique included anastomoses of the superior mesenteric artery (SMA) and superior mesenteric vein, with the aorta and vena cava, respectively, interposed by an iliac graft from the same deceased donor. After graft revascularization, intestinal anastomoses were performed with the intestinal remnant of the recipient (duodenum, ileum, or colon). The transplanted intestine was carefully fixed, and the mesenteric gaps were closed. At the end of the surgery, a three-lumen tube was passed through the gastrostomy for gastric drainage and enteral nutrition. The triple-lumen enteral tube includes a distal jejunal lumen for enteral nutrition infusion, a proximal gastric aspiration lumen, and an assisted air vent lumen to facilitate constant or intermittent suction of gastric contents. Temporary loop ileostomy was performed in the right hypochondrium as far as possible from the surgical wound. Ileostomy closure surgery is performed 6–12 months following transplant, if there is no rejection within the preceding 3 months.

Our immunosuppression protocol comprised induction therapy with 2 mg/kg anti-thymocyte globulin (ATG) plus 1 g intravenous bolus steroid injection (methylprednisolone). Subsequent doses of ATG were administered daily and withheld if the lymphocyte count dropped below 100 cells/mm^3. If a dose was withheld, it was administered the next day if lymphocyte count was higher than 100 cells/mm^3. The cumulative target dose was 10 mg/kg. Steroid tapering followed the standard protocol (200, 160, 120, 80, and 40 mg). Anti-B cell antibody treatment (rituximab 150 mg/m^2) was

Copyright © 2021 **CLINICS** – This is an Open Access article distributed under the terms of the Creative Commons License (http://creativecommons.org/licenses/by/4.0/) which permits unrestricted use, distribution, and reproduction in any medium or format, provided the original work is properly cited.

No potential conflict of interest was reported.

DOI: 10.6061/clinics/2021/e3016

administered on the 3rd postoperative day (POD) as a single dose. The maintenance immunosuppression regimen comprised a three-drug combination: FK, everolimus, and prednisone. FK is the mainstay therapy and is initiated immediately after IT. FK was administered via the gastric tube lumen following clamping for 1h. The initial dose was 0.15 mg/kg administered four times per day to achieve an early target range for the trough level of 20–25 ng/ml. The doses were altered according to trough levels. If the FK trough level was below the target range within 5 days, the administration route was changed in a sublingual fashion. Everolimus was started after complete abdominal wall closure, targeted to a 4–6 ng/ml trough level. Prednisone (20 mg) was introduced after methylprednisolone tapering.

Infectious disease prophylaxis included systemic antibiotics at the time of anesthesia induction and was continued for 7 days after IT Standard therapy comprised vancomycin and piperacillin–tazobactam. Concurrent antifungal coverage was employed with fluconazole for 21 days. All patients received trimethoprim–sulfamethoxazole for prophylaxis against *Pneumocystis carinii* for 1 year after IT. Albendazole and ivermectin were administered systematically for parasitic infection prophylaxis. Blood cultures were collected on the day of transplantation because of the risk of line sepsis and bacterial translocation.

Cytomegalovirus (CMV) is a viral prophylaxis target. Recipients (R) with negative CMV immunoglobulin (Ig) G antibody serostatus are considered at a higher risk to develop CMV infection. Patients were stratified according to the CMV IgG status and were considered high-risk patients when an IgG-negative recipient received a graft from an IgM-positive donor. All patients received ganciclovir 5 mg/kg twice daily for 3 weeks, starting immediately after transplantation. Prophylactic ganciclovir (5 mg/kg) was administered once daily and valganciclovir 900 mg was continued for 1 year. High-risk patients additionally received CMV Ig 150 mg/kg within 72 hours of transplantation, every alternate week for 8 weeks, and then monthly for 1 year (15 doses total). Surveillance of subclinical CMV replication included weekly serum CMV polymerase chain reaction (PCR) for 12 weeks and then monthly for 1 year.

Allograft rejection was diagnosed based on clinical parameters, particularly high ileostomy output, endoscopic mucosal aspect, and histology of biopsy specimens. Rejection surveillance was based on routine ileoscopy with collection of biopsies (five samples). The first examination was performed on day 5 after IT, then twice weekly for 2 months, once a week at the 3rd month, and finally once per month in the first year. Acute rejection was stratified as mild, moderate, or severe. Mild rejection depicts localized inflammatory infiltrates concentrated around the small venules in the lamina propria. The mucosa is intact, but the crypt epithelium displays evidence of injury. Further, the rate of crypt epithelial apoptosis increases, usually with more than six apoptotic bodies per 10 crypts. Moderate rejection depicts an inflammatory infiltrate that is widely dispersed within the lamina propria. Crypt damage is distributed more diffusely, usually in areas of confluent apoptosis. Focal superficial erosions may be present in the mucosa. Severe acute rejection is distinguished by a marked degree of crypt damage, usually associated with exfoliation, histological mucosal denudation, and mucosal ulceration. Treatment for rejection must be individualized, but as a general rule, mild rejection is treated with bolus steroid therapy (1 g methylprednisolone for 3–5 days). ATG is administered in cases of steroid-resistant rejection and moderate or severe rejection. Alemtuzumab is warranted in patients with poor response to ATG treatment.

The characteristics of the IT recipients and donors and the intraoperative data are presented in Table 1. Four patients underwent transplant, three of whom are alive and well (Table 1). One patient died after 19 months of follow-up

Table 1 - Characteristics of patients who underwent intestinal transplantation at Hospital das Clinicas of the University of São Paulo (HCFMUSP).

	PATIENT #1	PATIENT #2	PATIENT #3	PATIENT #4
AGE (YEARS)	25	45	27	21
SEX	MALE	MALE	MALE	MALE
WEIGHT (kg)	60	55	70	51
BMI (kg/M^2)	19.6	18	18	19.4
CMV IgG	POSITIVE	POSITIVE	NEGATIVE	POSITIVE
BLOOD TYPE	A	O	A	O
DONOR AGE (YEARS)	14	19	30	5
DONOR SEX	MALE	MALE	FEMALE	FEMALE
DONOR WEIGHT (kg)	60	75	70	26
DONOR BMI (kg/M^2)	20.7	25.9	24.2	20.3
DONOR CMV IgG	POSITIVE	POSITIVE	POSITIVE	POSITIVE
DONOR ICU DAYS	3	8	3	4
HLA CROSSMATCH	NEGATIVE	NEGATIVE	NEGATIVE	NEGATIVE
IF TIME (MONTHS)	24	12	96	72
ETIOLOGY	SIC	SIC	SIC	SIC
LOSS OF CENTRAL VENOUS ACCESS	4	1	0	2
TRANSPLANTATION DATE	13/12/2017	14/02/2019	05/02/2020	11/02/2021
SURGERY TIME	07:27	07:14	07:40	09:50
TOTAL ISCHEMIC TIME	07:30	06:00	5:38	07:45
COLON INCLUSION	NO	YES	YES	YES
SUPRARENAL CAVAL VEIN THROMBOSIS	YES	NO	NO	NO
ILEOSTOMY TAKE DOWN	6 M	6 M	7 M	
REJECTION	NO	YES	YES	YES
CMV INFECTION	NO	NO	NO	NO

BMI, body mass index; CMV, cytomegalovirus; ICU, intensive care unit; IF, intestinal failure; HLA, human leukocyte antigen.

because of pulmonary infection, therefore, the first three cases had 100% 19-month survival (Figure S1).

Case 1

A 23 year-old male, who underwent surgery for intestinal malrotation at 15 days of age, presented with mid-bowel volvulus, which led to occlusion of the SMA territory and required total enterectomy. Six months later, intestinal tract reconstruction with duodenocolic anastomosis was performed. After a failed rehabilitation attempt with PN and multiple central catheter-related infections, he underwent IT in December 2017 with a graft composed solely of the small bowel. The surgery lasted 7 hours and 27 minutes. On the 6th POD, enteral diet was introduced. The patient presented with worsening renal function. The FK doses were reduced, and everolimus therapy was initiated on the 10th POD. An oral diet was started on the 18th POD, with good acceptance. As a side effect of everolimus therapy, the patient developed serositis and pericardial effusion, requiring surgical intervention. Everolimus has since been replaced with mycophenolate sodium. The intestinal function recovered, and the patient was discharged 60 days after IT. Currently, the patient is rehabilitated on an exclusive oral diet using double immunosuppression. He did not present with hernia or abdominal defects during follow-up.

Case 2

A 44 year-old male, with a medical history of surgical correction of sigmoid volvulus at 2 months of age, presented with acute intestinal obstruction because of adhesions. He underwent surgical intervention; however, on the 30th POD, he developed new acute intestinal obstruction, which was treated by enterectomy, total colectomy, rectal stump closure, and duodenostomy. After 1 year of in-hospital clinical rehabilitation, he underwent IT in February 2019, with an isolated bowel graft containing the small intestine, ileocecal valve, and ascending and transverse colon. The total surgery time was 7 hours and 14 minutes. Transplantation was uneventful. On the 15th POD, an oral diet was started. Two months after transplant, the patient presented with steroid-resistant graft rejection and was successfully treated with 1.5 mg/kg/day ATG up to a total dose of 7 mg/kg. After 6 months, ileostomy closure surgery was performed; however, the patient developed acute intestinal obstruction and subsequently underwent laparotomy, which revealed internal herniation. The intestinal function fully recovered, and the patient was discharged on an exclusive oral diet, with triple immunosuppression and no hernias or abdominal defects. After 19 months of follow-up, the patient was hospitalized because of fever and dyspnea. Radiological investigation revealed pneumonia, and blood cultures identified multidrug-resistant *Klebsiella pneumoniae* carbapenemase-producing bacteria. He developed septic shock and died.

Case 3

A 19 year-old male underwent segmental enterectomy in 2012 because of intestinal malrotation. In the postoperative period, he presented with mesenteric ischemia, which required resection of the entire intestinal segment nourished by the SMA and terminal jejunostomy. Four years later, he underwent intestinal tract reconstruction with jejunocolic anastomosis. He remained on home PN until 2020. In February 2020, he underwent IT with an isolated intestinal graft composed of the small intestine, ileocecal valve, ascending colon, and transverse colon. The total surgery time was 7 hours and 40 minutes. An oral diet was introduced on the 14th POD with good acceptance. Ten months after transplantation, he presented with acute graft rejection and was successfully treated with ATG. Eleven months after transplantation, arterial conduit stenosis was identified and the patient underwent stent angioplasty. He remains rehabilitated on an exclusive oral diet using triple immunosuppression.

An important feature of this case is that the recipient's CMV serology was negative (IgM^-/IgG^-), whereas the donor was IgG-positive. The recipient received ganciclovir in addition to intravenous immunoglobulin against CMV, according to our protocol for high-risk patients. After 13 months of follow-up, the patient has not presented with any signs or symptoms of CVM infection, including negative serum CMV PCR and negative immunohistochemistry findings on routine intestinal biopsies.

Case 4

A 16 year-old male underwent extensive enterectomy because of intestinal torsion, remaining with 10 cm of the jejunum, transverse, and descending colon. For 5 years, he continued intestinal rehabilitation with PN and microelements. On February 2021, he underwent IT with an isolated intestinal graft composed of small intestine, ileocecal valve, ascending colon, and transverse colon. The total surgery time was 9 hours and 50 minutes. He was started an oral diet on the 8th POD; however, he developed gastric distension and vomiting. On the 20th POD, he presented with mild acute cellular rejection and was successfully treated with pulse steroid therapy for 3 days. On the 50th POD, he developed moderate acute cellular rejection, and ATG treatment was initiated. After the second ATG dose, he was diagnosed with coronavirus disease 2019 (COVID-19) during routine nasal swab screening. We decided to proceed with ATG treatment, despite a second nasal swab positive for SARS-CoV-2 (causative virus of COVID-19) and mild respiratory symptoms. Rejection was successfully treated, and he had no complications related to COVID-19. Oral diet acceptance steadily improved, and he was discharged 3 months after the procedure. After 6 months of follow-up, he remained on an exclusive oral diet using triple immunosuppression.

Brazil has a solid foundation in organ transplants and has the largest number of recorded transplants performed in Latin America. In 2019, 14,943 transplants were performed across the country, and approximately 96% of the procedures were financed by the public Unified Health System (SUS) (9).

Although Brazil was a pioneer in IT with Okumura in the 60s, IT is still not a well-established modality in the country. Nonetheless, in the last 4 years, four ITs were performed in our center at HC-FMUSP with good outcomes, indicating promising prospects in the treatment of patients with IF in the future (Figure 1).

IF, although rare, is a complication that directly affects public health. It is estimated that in Brazil, approximately 800 people present with IF each year (10). These patients become dependent on daily PN and must be hospitalized, as the SUS does not finance home PN (11-13). Only a few Brazilian medical centers offer home PN through the public health system via direct agreements with the Ministry of Health; however, the available institutions are limited. Hospitalization of patients for PN results in high morbidity

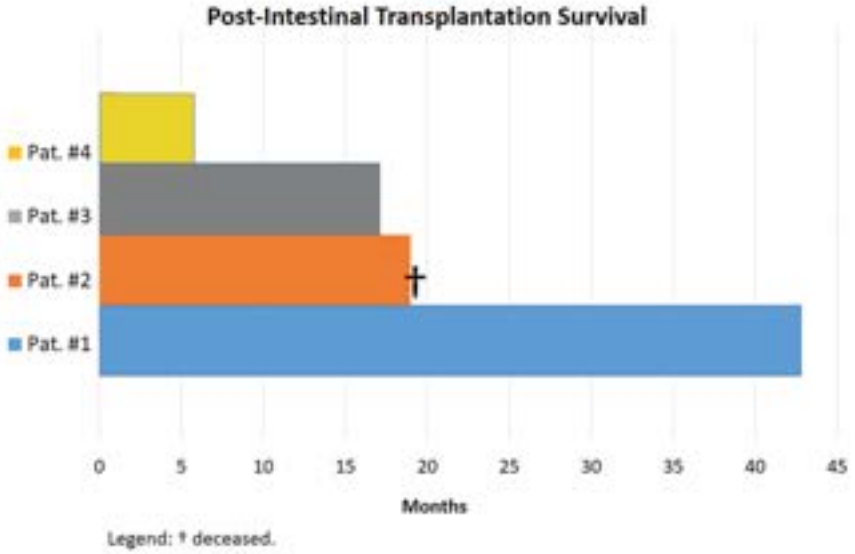

Figure 1 - Overall survival of patients after intestinal transplantation at the Hospital das Clinicas of the University of São Paulo.

and mortality (14-16) and entails expenses related to hospitalization, specialized health care personnel, use of high-tech equipment, and costs of medication and secondary examinations (17). In addition, hospitalization for PN negatively impacts QoL as patients remain restricted to hospitals with limited family living along.

IT involves different modalities; although the small intestine is the main organ to be transplanted, it may be transplanted together with different organs. This type of transplant depends on the underlying disease, the quality of the other abdominal organs, the presence of liver disease, and the number of previous abdominal operations. Isolated IT is indicated in IF in the absence of severe liver dysfunction. The liver should be included in the graft in the presence of severe and irreversible liver diseases. In 2019, 81 ITs were performed in the United States, among which 55.5% required an associated liver transplant (18). When multiple abdominal organs fail, the graft must be multivisceral, and in such cases, they are transplanted en bloc: stomach, duodenum, pancreas, small intestine, and liver.

In the past decade, the overall patient and graft survival rate has improved significantly in the context of IT. Most patients have good graft function and complete restoration of oral feeding (19-21). Some centers in the USA have reached very satisfactory long-term results, with 1- and 5-year graft survival rates of 77.5% and 57.9% in the pediatric population, respectively. Among adults, the 1- and 5-year graft survival rates were 72% and 43.5%, respectively (22).

In a more recent report from the Scientific Registry of Transplant Recipients, the results from January 2014 to June 2016 showed that the 1-year graft survival varied from 60.5% to 83.0%, when including only six US centers that performed 10 or more adult IT in 2016. Including all centers that performed at least one adult IT, the mean 1-year graft survival rate in the USA was 73.6%, including all centers that performed at least one adult IT (23).

Despite the improvement in the clinical outcomes of IT, QoL should also be considered an important measure of success. The ultimate goal of any therapeutic intervention is to alleviate the disease condition and improve QoL. It is well established that QoL in IT recipients is better than that in patients with FI in PN. Rovera et al. (24) reported a significant improvement in QoL in the transplant group compared with their pre-transplant status when they were receiving PN. QoL is one of the main advantages of IT compared with PN, and, therefore, should be considered as one of the possible indications for IT.

Due to the complexity of the procedure, few centers have performed IT in the world. Usually, programs are developed in institutions where liver and other solid organ transplantation programs are already well established and have a large number of cases. Between 2005 and 2007, only 28 centers worldwide reported IT in the Intestinal Transplant Registry (25). To the best of our knowledge, this is the first successful Brazilian isolated IT series to be reported.

In conclusion, the outcomes of IT have improved in recent decades, and graft survival is now comparable to that of other solid organs. In Brazil, there has been improvement in the outcomes of IT, with the potential to benefit more patients with IF. IT is a therapeutic modality that must be offered given that intestinal rehabilitation with early restoration of nutritional autonomy has been shown to lead to better survival rate and QoL.

REFERENCES

1. Dionigi P, Alessiani M, Ferrazi A. Irreversible intestinal failure, nutrition support, and small bowel transplantation. Nutrition. 2001;17(9):747-50. https://doi.org/10.1016/S0899-9007(01)00630-X
2. Galvao FH, Ye Q, Doughton C, Murase N, Todo S, Zeevi A, et al. Experimental animal model of graft-versus-host disease (GVHD) after small-bowel transplantation: characteristics of the model and application to developing treatment strategies. Transplant Proc. 1997;29(1-2):700. https://doi.org/10.1016/S0041-1345(96)00425-3
3. Kato T, Ruiz P, Thompson JF, Eskind LB, Weppler D, Khan FA, et al. Intestinal and multivisceral transplantation. World J Surg. 2002;26(2):226-37. https://doi.org/10.1007/s00268-001-0210-5
4. Fishbein TM, Kaufman SS, Florman SS, Gondolesi GE, Schiano T, Kiss-Schluger L, et al. Isolated intestinal transplantation: proof of clinical efficacy. Transplantation. 2003;76(4):636-40. https://doi.org/10.1097/01.TP.0000083042.03188.6C
5. Lauro A, Di Benedetto F, Masetti M, Cautero N, Ercolani G, Vivarelli M, et al. Twenty-seven consecutive intestinal and multivisceral transplants

in adult patients: a 4-year clinical experience. Transplant Proc. 2005; 37(6):2679-81. https://doi.org/10.1016/j.transproceed.2005.06.071
6. Okumura M, Fujimura I, Ferrari AA, Nakiri K, Lemos PC, de Andréa EA, et al. [Transplantation of the small intestine. Case report]. Rev Hosp Clin Fac Med Sao Paulo. 1969;24(1):39-54.
7. Levi DM, Tzakis AG, Kato T, Madariaga J, Mittal NK, Nery J, et al. Transplantation of the abdominal wall. Lancet. 2003;361(9376):2173-6. https://doi.org/10.1016/S0140-6736(03)13769-5
8. Gondolesi GE, Doeyo M, Solar-Muñiz H. A detailed analysis of the current status of intestinal transplantation in Latin America. Curr Opin Organ Transplant. 2020;25(2):189-95. https://doi.org/10.1097/MOT.0000000000000737
9. Registro Brasileiro de Transplantes. In:ABTO, editor. 2019.
10. Lee AD, Galvao FH, Dias MC, Cruz ME, Marin M, Pedrol CN, et al. Home parenteral nutrition program and referral of potential candidates for intestinal and multivisceral transplantation in a single Brazilian center. Transplant Proc. 2014;46(6):1839-41. https://doi.org/10.1016/j.transproceed.2014.05.056
11. Galvão FH, Waitzberg DL, Bacchella T, Gama-Rodrigues J, Machado MC. [Small intestine transplantation]. Arq Gastroenterol. 2003;40(2):118-25. https://doi.org/10.1590/S0004-28032003000200011
12. Tannuri U. [Short bowel syndrome in children--treatment with home parenteral nutrition]. Rev Assoc Med Bras (1992). 2004;50(3):330-7. https://doi.org/10.1590/S0104-42302004000300044
13. Bakonyi Neto A, Takegawa B, Ortolan E, Galvão F, Mendonça F, Sbragia L, et al. Demographic of short gut syndrome: increasing demand is not followed by referral of potential candidates for small bowel transplantation. Transplant Proc. 2004;36(2):259-60. https://doi.org/10.1016/j.transproceed.2004.01.110
14. Winkler MF, Smith CE. Clinical, social, and economic impacts of home parenteral nutrition dependence in short bowel syndrome. JPEN J Parenter Enteral Nutr. 2014;38(1 Suppl):32S-37S. https://doi.org/10.1177/0148607113517717
15. Wanten GJ. Parenteral approaches in malabsorption: Home parenteral nutrition. Best Pract Res Clin Gastroenterol. 2016;30(2):309-18. https://doi.org/10.1016/j.bpg.2016.03.010
16. Girke J, Seipt C, Markowski A, Luettig B, Schettler A, Momma M, et al. Quality of Life and Nutrition Condition of Patients Improve Under Home Parenteral Nutrition: An Exploratory Study. Nutr Clin Pract. 2016; 31(5):659-65. https://doi.org/10.1177/0884533616637949
17. Goldstein M, Braitman LE, Levine GM. The medical and financial costs associated with termination of a nutrition support nurse. JPEN J Parenter Enteral Nutr. 2000;24(6):323-7. https://doi.org/10.1177/014860710002400323
18. Horsley SP, Smith JM, Ahn Y, Skeans MA, Cafarella M, Noreen SM, et al. OPTN/SRTR 2019 Annual Data Report: Intestine. Am J Transplant. 2021;21 Suppl 2:316-55. https://doi.org/10.1111/ajt.16498
19. Fryer JP. Intestinal transplantation: current status. Gastroenterol Clin North Am. 2007;36(1):145-59. https://doi.org/10.1016/j.gtc.2007.01.001
20. Mazariegos GV, Steffick DE, Horslen S, Farmer D, Fryer J, Grant D, et al. Intestine transplantation in the United States, 1999-2008. Am J Transplant. 2010;10(4 Pt 2):1020-34. https://doi.org/10.1111/j.1600-6143.2010.03044.x
21. Vianna RM, Mangus RS. Present prospects and future perspectives of intestinal and multivisceral transplantation. Curr Opin Clin Nutr Metab Care. 2009;12(3):281-6. https://doi.org/10.1097/MCO.0b013e32832a2215
22. Smith JM, Weaver T, Skeans MA, Horslen SP, Miller E, Noreen SM, et al. OPTN/SRTR 2018 Annual Data Report: Intestine. Am J Transplant. 2020;20 Suppl s1:300-39. https://doi.org/10.1111/ajt.15675
23. Matsumoto CS, Subramanian S, Fishbein TM. Adult Intestinal Transplantation. Gastroenterol Clin North Am. 2018;47(2):341-54. https://doi.org/10.1016/j.gtc.2018.01.011
24. Rovera GM, DiMartini A, Schoen RE, Rakela J, Abu-Elmagd K, Graham TO. Quality of life of patients after intestinal transplantation. Transplantation. 1998;66(9):1141-5. https://doi.org/10.1097/00007890-199811150-00005
25. Grant D, Abu-Elmagd K, Mazariegos G, Vianna R, Langnas A, Mangus R, et al. Intestinal transplant registry report: global activity and trends. Am J Transplant. 2015;15(1):210-9. https://doi.org/10.1111/ajt.12979

APPENDIX

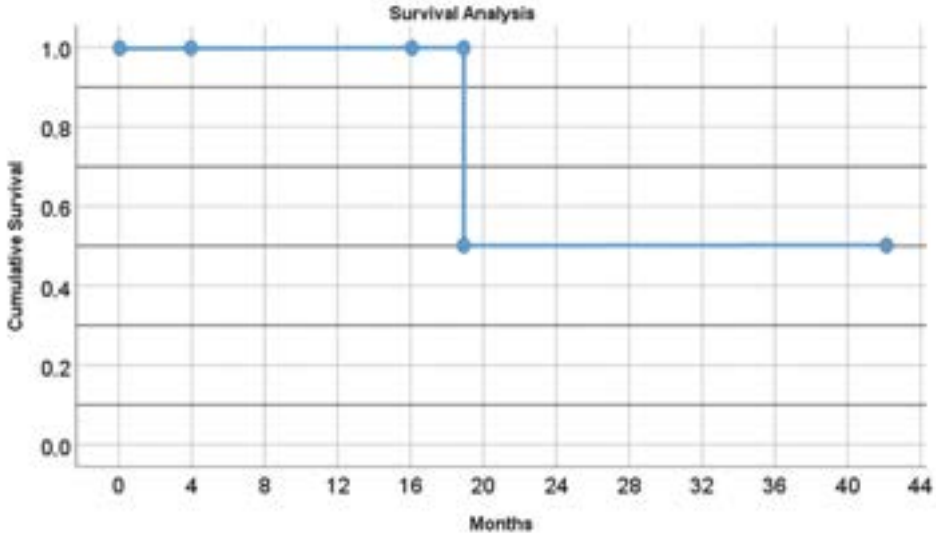

Figure S1 - Kaplan–Meier curve.

ANNALS OF TRANSPLANTATION

REVIEW PAPER

e-ISSN 2329-0358
© Ann Transplant, 2022; 27: e934595
DOI: 10.12659/AOT.934595

Received: 2021.08.31
Accepted: 2022.01.13
Available online: 2022.01.26
Published: 2022.03.01

Techniques for Closing the Abdominal Wall in Intestinal and Multivisceral Transplantation: A Systematic Review

Authors' Contributions:
Study Design A
Data Collection B
Statistical Analysis C
Data Interpretation D
Manuscript Preparation E
Literature Search F
Funds Collection G

ABCEF 1 Allana C. Fortunato
ABCEG 1 Rafael S. Pinheiro
BEF 2 Cal S. Matsumoto
A 1 Rubens M. Arantes
A 1 Vinicius Rocha-Santos
A 1 Lucas S. Nacif
A 1 Daniel R. Waisberg
F 1 Liliana Ducatti
F 1 Rodrigo B. Martino
AFG 1 Luiz Carneiro-D'Albuquerque
AEG 1 Wellington Andraus

1 Department of Gastroenterology, Clinics Hospital of the University of São Paulo, São Paulo, SP, Brazil
2 MedStar Georgetown Transplant Institute, MedStar Georgetown University Hospital, Washington, DC, USA

Corresponding Author: Allana C. Fortunato, e-mail: fortunato_a@hotmail.com
Financial support: None declared
Conflict of interest: None declared

Short bowel syndrome is the most common etiology of intestinal failure, resulting from either resections of different intestinal segments or a congenital condition. Due to the absence or considerable reduction of intestinal loops in the abdominal cavity, patients with short bowel syndrome present with atrophy and muscle retraction of the abdominal wall, which leads to loss of abdominal domain and elasticity. This complication is an aggravating factor of intestinal transplantation since it can prevent the primary closure of the abdominal wall. A vast array of surgical techniques to overcome the challenges of the complexity of the abdominal wall have been described in the literature. The aim of our study was to review the modalities of abdominal wall closure in intestinal/multivisceral transplantation.

Our study consisted of a systematic review following the methodological instructions described in the PRISMA guidelines. Duplicate studies and studies that did not meet the criteria for the systematic review were excluded, especially those without relevance and an explicit relationship with the investigated theme. After this step, 63 articles were included in our study.

The results obtained with these techniques have been encouraging, but a high incidence of wound complications in some reports has raised concerns.

There is no consensus among transplantation centers regarding which technique would be ideal and with higher success rates and lower rates of complications.

Keywords: **Open Abdomen Techniques • Transplantation • Abdominal Wall • Organ Transplantation • Short Bowel Syndrome**

Full-text PDF: https://www.annalsoftransplantation.com/abstract/index/idArt/934595

6714 2 7 100

Background

Intestinal failure is defined as the inability to maintain homeostasis through enteral absorption of nutrients, electrolytes, and water [1-3]. Short bowel syndrome is the most common etiology of intestinal failure and results from either resections of different intestinal segments or a congenital condition. Parenteral nutrition is the first line therapy for intestinal failure; however, when life-threatening complications of parenteral nutrition occur, intestinal transplantation is the only curative treatment possible for these patients.

Owing to the absence or considerable reduction of intestinal loops in the abdominal cavity, these patients present with atrophy and muscle retraction of the abdominal wall, which leads to the loss of abdominal domain and elasticity. Furthermore, patients with short bowel syndrome often undergo multiple surgical procedures, leading to extensive abdominal scarring or even a frozen abdomen (**Figure 1**). This complication is an aggravating factor of intestinal transplantation since it can prevent the primary closure of the abdominal wall. Even in patients without short bowel syndrome, other situations commonly faced by potential intestinal transplantation recipients, such as abdominal adhesions resulting from previous surgical procedures, fistulas, ostomies, or extensive abdominal fibrosis that result from second intention healing of peritoneostomies/laparostomies [4], can also pose challenges for abdominal wall closure. In addition, edema after revascularization of the intestinal graft tends to exacerbate the difficulty of tension-free primary closure [5]. A forced closure attempt can result in intestinal ischemia, wound dehiscence, infection, abdominal compartment syndrome, respiratory complications, vascular thrombosis, and consequent graft necrosis [6,7].

Figure 1. Extensive abdominal fibrosis resulting from second intention healing of peritoneostomy and ostomy scars. (Arsenal of the department.)

Successful closure in this chronically ill and highly immunosuppressed population has been proven to be crucial, not only to decrease the risk of infections, fistulas, and mycotic aneurysms, but also to improve the survival of the graft and the patient [8,9]. The rate of primary abdominal wall closure after intestinal transplantation or multivisceral transplantation varies from 40% to 85% [10]. A vast array of surgical techniques to overcome the challenges of the complex abdominal wall have been described in the literature. The aim of our study was to review the modalities of abdominal wall closure in intestinal/multivisceral transplantation.

Our study consisted of a systematic review following the methodological instructions described in the PRISMA guidelines [11].

Initially, a search for data was performed in the Medline-PubMed database in English. Data collection was completed in November 2019. The interventions analyzed in our study consisted of the techniques used for abdominal wall closure during intestinal or multivisceral transplantation. The search on Medline was performed in the PubMed database (www.ncbi.nlm.nih.gov/pubmed) and was adapted using MeSH terms in English (intestinal OR small bowel OR multivisceral) AND (transplantation). After this initial search, we made other selections with the more specific terms as follows: (abdominal OR wall) AND (technique) AND (humans).

The sample consisted of articles published in indexed journals and selected by 2 independent researchers (ACF and RSP) who read and analyzed the abstracts according to the following inclusion criteria: 1) publication vehicle: indexed journals, since they present greater dissemination and access to researchers; 2) publication language: articles published in English, French, Spanish, or Portuguese; 3) year of publication: articles published between 2003 and 2019, totaling a period of 16 years; and 4) modality of scientific production: original articles, case reports, and systematic reviews regarding techniques for abdominal wall closure after intestinal transplantation.

Our study was approved by the Research Ethics Committee of the institution.

The bibliographic search encompassed articles from national and international literature regarding techniques to correct complex abdominal defects in the setting of intestinal transplantation. In total, 250 abstracts of scientific articles were found in the databases. Studies that did not meet the criteria

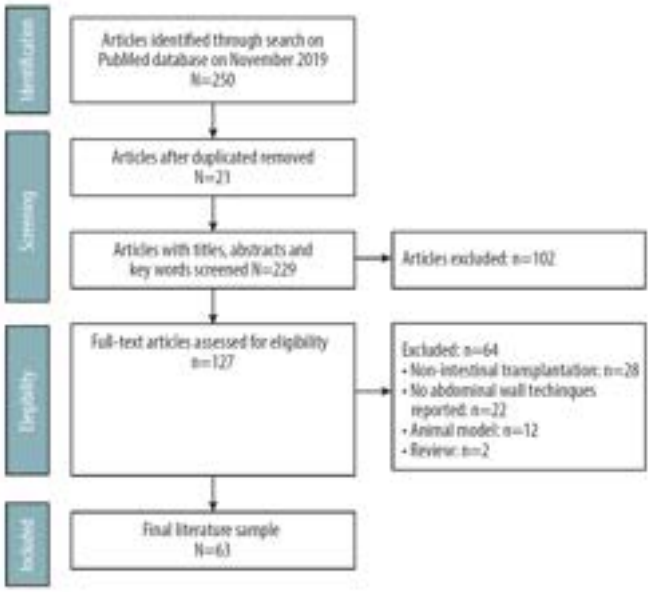

Figure 2. Study design.

for the systematic review were excluded, including duplicate studies and especially studies not meeting the parameters of relevance and explicit relationship with the investigated theme. After this step, 63 articles were included in our study, as shown in **Figure 2**.

Discussion

About 20% to 33% of patients who present with primary closure after intestinal transplantation progress to secondary dehiscence of the surgical wound [1-3,12]. To overcome the difficulty of adequate abdominal wall closure, several strategies were used: some involved the use of small grafts in the recipient and others involved the increase of the abdominal domain.

Reduced-Size Grafts

Incompatibility in size makes the primary closure of the recipient's abdominal wall one of the most important technical challenges related to intestinal transplantation. The use of pediatric donors for adult recipients or anatomical reduction of the graft are alternatives. Since the 1990s, small donors have been predominantly used for intestinal transplantation. The donor-to-recipient body weight ratio should be ideally between 1.1 and 0.76 [13], demonstrating that recipients with intestinal failure commonly have reduced weight in relation to their size. However, transplantation centers have increasingly accepted organs with considerable size incompatibility owing to the scarcity of donors that meet the ideal characteristics. The discrepancy between donors and recipients is a critical issue that significantly limits the availability of organs. In the United States, after 3 years on the intestinal transplantation waiting list, 17.6% of patients were still waiting for a donor [14]. Organ donation from larger donors would increase the availability of organs, potentially reducing waiting time. Pediatric recipients are the most affected because of the scarcity of pediatric donors. Thus, an option to prevent high mortality rates of patients on the waiting list is to consider the anatomical reduction of the intestinal graft.

The development of reduced-size intestinal grafts was aimed to increase the pool of availability of donors or isolated intestinal grafts; it is possible to overcome size differences greater than 10: 1 (body weight) between donors and recipients with this technique [15]. For liver and intestine reduced-size grafts, the use of reduction techniques [16] resulted in the use of organs from donors that were up to 5 times larger than recipients [17].

The first reduced-size graft was reported by Reyes et al [16] in 1998 (**Table 1**). The recipients were a 3-year-old boy with hepatic-intestinal insufficiency and a 63-year-old man with hepatitis C and hepatocarcinoma, both transplanted with the same adult deceased donor liver. The pediatric recipient received the left lateral hepatic section (segments II and III) in continuity with the intestine, with no need of biliary reconstruction (**Figure 3**). The remnant liver of the donor was transplanted to the adult recipient. In 1999, Xenos et al [18] described their technique for graft reduction. The technique consists of dividing the liver (left lateral section represented by segments II and III) and the small intestine (ileum) during a combined transplantation; biliary reconstruction was performed by Roux-en-Y hepaticojejunostomy.

Table 1. Graft reduction techniques.

Year	Author	N	Technique	Outcome
1998	Reyes et al	1	Pediatric: LLHS + intestine Adult: Remmant liver (Right lobe + segment IV)	Retransplantation due pancreatic leakDied
1999	Xenos et al	1	LLHS + ileumbiliary reconstruction in Roux-en-Y	Died of intestinal perforation + severe rejection
2000	Ville de Goyet et al	2	LLHS + entire small intestine, including duodenum and head of the pancreas	Hospital discharge with complete enteral feeding
2000	Delrivière et al	15	One-meter ileal graft vascularized by SMA and SMV	No outcomes reported

LLHS – left lateral hepatic section represented by segments II and III; SMA – superior mesenteric artery; SMV – superior mesenteric vein.

In 2000, de Ville de Goyet et al [17] performed transplants in 2 children with chronic intestinal insufficiency, weighing 7.6 and 9.8 kg, respectively, with a multivisceral graft from 2 donors weighing 35 kg each. Multivisceral grafts had their size reduced during bench surgery (leaving the hepatic hilum untouched) and consisted of segments II and III of the liver and entire small intestine, including the duodenum and head of the pancreas. In these cases, there was also no need for biliary reconstruction owing to the preservation of the donors' duodenum in continuity with the intestinal graft.

Also in the 2000s, 15 isolated small intestines were successfully reduced by Delrivière et al [15] by obtaining a 100-cm ileal graft vascularized by the superior mesenteric artery and vein. The technique consisted of dissecting the vascular pedicle through mesenteric transillumination. The dissection was initiated on the right side of the mesenteric pedicle, following the path of the superior mesenteric artery and superior mesenteric vein, and the branches on the right were connected and sectioned (ileocecal, right colic and medium colic arteries), except for the ileal branch, which was dissected all the way. The lymphatics of the ileal mesentery were preserved to guarantee the maintenance of lymphatic drainage. The use of the distal ileum effectively reduced the graft size due to the reduction in the size of the mesentery. During the dissection of the pedicle's left side, all venous and arterial branches that did not supply the potential graft were connected and sectioned. All adipose tissue and lymph nodes around the mesenteric pedicle were removed to reduce mesenteric volume.

Graft reduction techniques had their "golden age" until the end of the 1990s, becoming obsolete due to their potential complications, complex techniques, and unsatisfactory results. Moreover, there is a significant risk of bleeding, fistula, or stenosis of the stapled portion, and, therefore, other techniques have been preferred to facilitate abdominal wall closure. The need for finding a standard and reproducible technique favored the emergence of alternative techniques, such as components separation, tissue expanders, synthetic and biologic meshes, aponeurosis transplantation with the rectus muscle fascia [7], and even total abdominal wall transplantation [4].

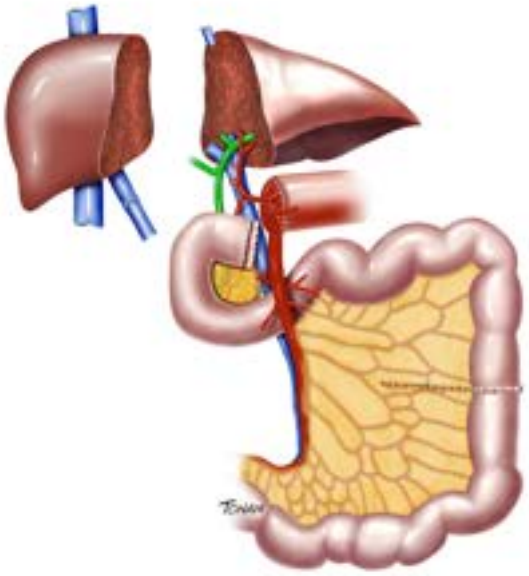

Figure 3. Reduced-size graft. Created with Adobe® Photoshop.

Tissue Expanders

The first description of tissue expanders was made by Byrd and Hobar in 1989 [19]. Currently, they have been successfully used in general, pediatric, and plastic surgery to close large defects of the skin and abdominal wall (**Figure 4**).

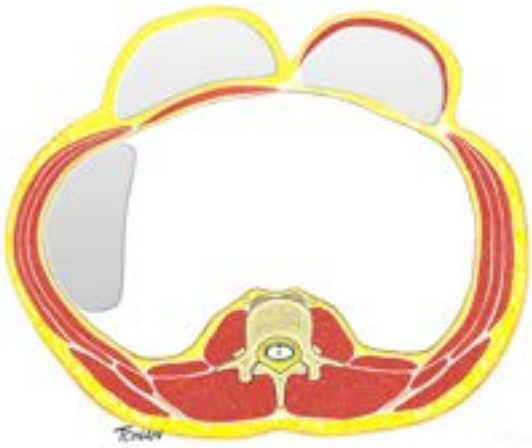

Figure 4. Expander tissue. Created with Adobe® Photoshop.

The use of tissue expanders before intestinal transplantation was first reported by Ville de Goyet et al in 2000 [17], following other authors (**Table 2**).

As in other abdominal closure techniques, tissue expanders have several potential disadvantages, such as the impossibility of predicting the date for performing the intestinal transplantation, additional exposure to anesthesia, difficulty in the healing process of malnourished patients, and complications related to gradual injection in the inflatable tissue expander [20].

Despite their versatility, tissue expanders have been associated with significant complications since the start of their use. An overall complication rate of 13% to 20% has been reported, with infection, prosthesis migration, and hematoma being most frequent [21]. The use of intraperitoneal tissue expanders can result in potentially worse complications, such as peritonitis and compression of intra-abdominal organs. The experience of using tissue expanders in patients awaiting intestinal transplantation is limited because of concerns related to the use of foreign material in critically ill patients as well as to space limitations caused by fistulas, scar tissue, and often stomata.

Component Separation

One possibility to facilitate abdominal closure after intestinal transplantation is abdominal wall component separation (CS). The first attempt to increase the capacity of closure in an abdominal defect was described in 1920 by Gibson [21] while performing relaxation incisions in the anterior fascia of the rectus abdominis muscle. A few decades later, Albanese [22] reported the fascial incision of the external oblique muscle to aid the repair of a large eventration. This surgery was repeatedly reproduced by Young [23], who modified it and described the performance of fascial incisions to relieve tension, separating the anterior and posterior sheath of the rectus abdominis muscle and then incising the lateral margin of the anterior fascia to repair epigastric hernias.

In 1990, the term "component separation" was defined by Ramirez et al [24], and the technique was widely popularized through the report of the correction of abdominal defects in 11 patients. The epigastric region was closed by approaching the left rectus abdominis, with its transverse abdominal and internal oblique muscles attached to the flaps of both the transverse abdominal and right internal oblique muscles. The left rectus abdominis was separated from its insertion in the lower rib cage, creating a rectus-pectoral flap to facilitate closure. The defect in the middle and lower abdominal wall was closed by rejoining the rectus abdominis, internal oblique, and transverse abdominal muscles to the remaining portion of the rectus

Table 2. Techniques and results of using tissue expanders.

Author	Year	n	Tissue expander site	Period	Outcome
Ville de Goyet [17]	2000	1	Pre-peritoneal	3 m	Success Primary closure using reduced graft
Alexandrides [6]	2000	1	Peritoneal	18 d	Removed due peritonitis
Marin-Gutzke [20]	2008	1	Combined	5 m	Success primary closure
Watson [21]	2013	5	Subcutaneous	3 m	3 pat. "complete graft coverage" 1 pat. still waiting IT
Vidyadharan [22]	2013	7	Subcutaneous	7 m*	7 pat. re-exploration due complications 4 pat. complete closure using reduced grafts
Weiner [23]	2014	1	Combined	10 m	Staged closure
Ceulemans [24]	2016	2	Subcutaneous	7 m 3 m	1 pat. staged closure 1 pat. Success primary closure

m – medium; pat – patient; combined , –peritoneal and retromuscular.

abdominis, internal oblique, and transverse abdominal muscles. The external oblique muscles were independently advanced, as were the overlying skin flaps. After 4 months, the patient was reassessed, and the surgical wound was fully healed. The other 10 patients also had successful correction of the abdominal defect and none of them presented postoperative complications.

Surgical dissection and CS in the avascular plane fully preserves the innervation of the rectus abdominis muscles since the intercostal nerves that innervate this muscle run deeply to the fascia of the internal oblique muscle. According to Nguyen and Shestak [25], this innervated muscle complex can be advanced up to approximately 4 cm in the upper abdomen, 8 cm in the waist region, and 3 cm in the lower abdomen on each side, allowing the surgeon to reconstruct defects up to 16 cm wide at the waistline level. A small addition of 2 cm can be obtained by separating the anterior and posterior fascia of the rectus abdominis muscle above the arcuate line [25,26]. Access to the external oblique aponeurosis usually requires significant release of the skin and subcutaneous tissue. However, the extensive release of the subcutaneous tissue sharply increases complications related to the wound, reaching rates higher than 60% [27]. In response to this problem, several variations of CS have been described, including the release of the rectus abdominis sheath alone or in combination with the release of the transverse abdominal [28] and the use of botulinum toxin injection into the oblique muscles to perform a temporary relaxation of the components [29].

Some studies, such as the one by Black et al [30], reported the experience of using CS associated with the use of prosthetic meshes to correct abdominal wall defects in the transplanted population. Of the 19 patients who underwent defect correction with CS + biologic or synthetic mesh, 31.6% presented complications, such as seroma, hematoma, abscess, and dehiscence. Scheuerlein et al [31] identified greater recurrence of the abdominal defect using CS alone than with the combination of CS and biologic mesh. They also observed a lower incidence of postoperative complications in transplanted patients when using CS in association with biologic mesh, to the detriment of using synthetic mesh. Brewer et al [32] also demonstrated an advantage in the use of biologic mesh in transplanted patients after repairing abdominal hernias in 34 patients with biologic mesh and 26 with synthetic mesh. They observed that the patients who received the biologic mesh had a lower infection rate (65.4% vs 14.7%, $P<0.05$), fewer recurrences (76.9% vs 23.5%, $P<0.05$), and less need for mesh removal (69.2% vs 11.8%, $P<0.05$) in comparison with patients who received synthetic mesh.

A study at MedStar Georgetown University Hospital by Zolper et al [33] demonstrated that the use of CS associated with the use of biological meshes can be a successful strategy in the transplant population in an immunosuppressive regimen, despite concerns about the compromised abdominal vascularization of anterior abdominals surgeries. Soft tissue intervention is crucial for abdominal wall reconstruction in that population with previous scars; in addition, achieving stable skin coverage is equally important for strength to fascial repair, as wound healing compromise leads to a cycle of recurrent hernia [34].

A relevant factor for good results of the CS technique is the need for the wall components to be intact, well vascularized, innervated, and with complacency; that is, without fibrosis from previous scars [26]. However, this is a condition often lacking in intestinal transplantation candidates, owing to multiple previous interventions. Another complication factor is the presence of stomata, since the closure of the aponeurotic defect during the colostomy/ileostomy reversal surgery provides some tension on the ipsilateral fascia of the abdominal wall.

Prosthetic Meshes

The interest of studying abdominal wall defects has existed since ancient times; the first references on the subject are from Egyptian civilization and are present in the Ebers Papyrus (1536 BC) [35]. The observation and correlation between a hernia and the weakness of the abdominal wall muscle is attributed to Galen (129-201 AD) [36]. The most recent revolution for the surgical treatment of abdominal defects emerged with the concept of tension-free surgery through the use of polypropylene mesh (**Figure 5**). Since then, the use of prostheses started with the aim of strengthening the abdominal wall, and the use of meshes was quickly disseminated [37].

Usher first used polypropylene meshes in 1959 in the United States, showing good results [38]. In Brazil, the first report was made by Felicio Falci [39] in 1969 in a series with 100 patients who underwent inguinal hernia treatment. The tension-free correction of aponeurotic defects was widespread in the 1970s, especially in publications from Lichtenstein [37,40].

Still, in the 1950s, there was a publication describing the ideal characteristics that a prosthetic material should present: it should be chemically and biologically inert, mechanically stable, non-carcinogenic, suitable for sterilization, biocompatible, and hypoallergenic [41]. It is usually not easy to obtain a mesh that meets all of these criteria. To date, several materials have been used to manufacture prosthetic meshes, including knitted polypropylene [38], commercial polyester fabric [41], nylon, stainless steel [42], cotton [43], vicryl [44], expanded polytetrafluoroethylene (PTFE) [45], ethylene terephthalate, carbon fibers [46], oxidized cellulose, polyethylene glycol, and hylan G-F20 [47]. There are currently 3 types of meshes: synthetic, composite, and biologic.

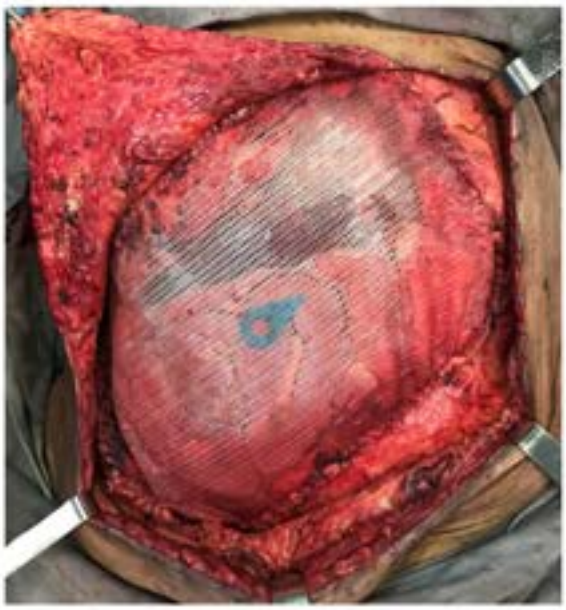

Figure 5. Prosthetic meshes. (Arsenal of the department.)

Synthetic Meshes

Synthetic meshes can be subclassified as non-absorbable and absorbable types.

Non-absorbable meshes encompasses the following mesh types: polypropylene, polyester, and expanded PTFE [48]. Polypropylene mesh is permanent, widely used, consists of mono-, double-, or multi-filaments, and is lightweight (Vypro; Ethicon) or heavyweight (Marlex). Comparatively, the heavy mesh is thicker, with smaller pores and less elasticity, also presenting increased tensile strength. All polypropylene meshes generate a vigorous foreign body reaction and produce strong repair through rapid integration into the abdominal wall. However, these same properties also make polypropylene meshes susceptible to adhesions, obstructions, formation of fistulas, retraction, and bacterial growth.

Polyethylene terephthalate (polyester) mesh is non-absorbable and is manufactured to be more malleable, less inflammatory, and more resistant to infections. Polyester meshes include Dacron (DePoy Intl, Leeds, UK), Mersilene (Ethicon), and Symbotex (Covidien, Mansfield, MA, USA).

The expanded PTFE mesh is another permanent and synthetic mesh, manufactured with 2 surfaces, 1 ventral and 1 visceral [48]. The ventral surface faces the abdominal wall and has a rough surface with large pores to facilitate incorporation, while the visceral surface faces the peritoneal content and is designed to be smoother with smaller pores to prevent adhesions, obstructions, and fistulas. PTFE meshes include Teflon (EI DuPont de Nemours and Company, Wilmington, DE, USA) and GORE-TEX (WL Gore & Associates, Wall Township, NJ, USA).

Absorbable synthetic meshes (polyglycolic acid, polyglactin) are useful for repairing hernias for a short period because they induce little inflammatory reaction before their hydrolysis and are considered to be made of unsatisfactory material for use in permanent replacement of the abdominal wall [49].

Non-absorbable meshes are preferred for repairing uncontaminated abdominal wall defects, while absorbable meshes are preferred for repairing infected abdominal wall defects until resolution of the infection; then, they can be replaced with a non-absorbable mesh. However, the mesh is a foreign body, being an important cause of peritoneal adhesion, particularly if it is used intraperitoneally. Non-absorbable meshes also present a higher risk of infection as an additional risk factor [50,51]. The ideal mesh maintains adequate and permanent occlusion of the abdominal wall defect, with low rates of infection and adherence, and does not induce fistula formation [52-54].

Composite Meshes

The second mesh category is called composite, which can be coated in the parietal or ventral surface [48]. These meshes were produced because of the increase in laparoscopic repairs of ventral hernias as well as because of the increase in open surgery complications, culminating in the removal of the polypropylene, polyester, or PTFE mesh. The composite mesh is a dual-surface material, with the ventral surface being a non-absorbable mesh to be incorporated into the abdominal wall, and the visceral surface may be coated with a temporary resistant barrier (coated composite mesh) or a permanent barrier (double-sided mesh) against adhesions. Common coated composite meshes include Proceed (Ethicon) and Sepramesh (CR Bard), while the dual-surface composite meshes are Composix (CR Bard) and DualMesh (WL Gore & Associates).

Biologic Meshes

The last mesh type is the biologic, which emerged from the need for closure of contaminated or potentially contaminated areas with meshes [48]. Introduced in the United Kingdom in the 1990s and approved by the FDA in the 2000s [55], biologic meshes allow tissue infiltration and regeneration, attracting native fibroblasts and promoting neovascularization [56,57] and serving as a matrix for re-epithelialization. This culminates into the deposit of antibiotics and defense cells on the mesh, providing the ability to resist infection in hostile environments and not requiring removal in cases of infection [58,59]. Common meshes in this category include AlloDerm and Strattice (Lifecell Corporation, Branchburg, NJ, USA), DuraDerm (CR Bard), BioDesign (Cook Medical Inc,

Bloomington, IN, USA), Tutopatch (Tutogen Medical Inc, Alachua, FL, USA), and Permacol (Medtronic, UK).

The composition of the biologic mesh is mainly of processed acellular dermal matrix derived from porcine, bovine, or human sources, making it immunologically inert. These products are supplied in non-crosslinked and crosslinked types. Crosslinking is thought to increase durability, tensile strength, and enzymatic degradation as well as to decrease bacterial contamination [59]. However, Romain et al did not observe a significant difference in hernia recurrence rates after 11 months between the groups of patients who received crosslinked and non-crosslinked porcine mesh in their series of 39 patients [59]. Although all biologic xenograft meshes provide matrices for cell growth, not all undergo similar processing techniques and, as a result, are remodeled in different ways [60].

There is no consensus on the body's reaction to different types of meshes. For example, Mulier et al [60] found that Permacol (crosslinked) and Strattice (non-crosslinked) showed endovascular growth and collagen infiltration in the host. On the other hand, Novitsky et al [61] reported that improved inflammatory response and foreign body reaction are responsible for encapsulation and poor integration in the host of crosslinked biologic meshes. In addition, Deeken et al [62] demonstrated that crosslinked materials caused greater fibrous encapsulation in the first 6 months, although the materials of the studied mesh exhibited a substantial decrease in encapsulation between 6 and 12 months, making it similar to non-crosslinked materials for 12 months.

In contaminated wounds, the rates of infection at the surgical site and recurrence between synthetic and biologic meshes were 21.5% and 13.5% and 21% to 17.8%, respectively, favoring the use of biologic mesh in this scenario [63]. In a major single-center study of 512 patients who underwent abdominal wall reconstruction using biologic mesh, the rates of hernia recurrence were reduced to 11.5% after 3 years and 14.6% after 5 years [64]. Unfortunately, biologic meshes are exceptionally expensive. A critical aspect of any intervention analysis is the cost-benefit ratio. The cost of a non-crosslinked porcine acellular skin in 2012 was approximately US \$32.40/cm^2; thus, the cost of a 25×40 cm prosthesis is in the range of US \$32 000 [65]. Comparatively, polypropylene mesh of a similar size costs approximately US \$0.15/cm2, effectively costing 100 times less than the biologic type [66].

The use of prostheses to repair abdominal wall defects has brought new problems. Although the mesh reduces the rates of hernia occurrence, it has its own set of complications; infection is one of the most devastating complications after any mesh implantation [67]. The risk of infection in correcting abdominal wall defects appears to be greater than in other clean cases; however, there is a wide variety reported in the literature, from 1% to 10% [68], depending on the type of mesh, technique, and population. Infection of prostheses in the abdominal wall can cause serious and expensive consequences, as well as a serious impact on the patient's life owing to prolonged hospitalizations, multiple reinterventions, and high social costs.

Postoperative wound infection usually appears on a surgical wound within 30 days to 1 year after surgery, with cases involving an implanted prosthesis [69-71]. Surgical site infections (SSI) remain the second most common type of health care-associated infection in Europe and the United States, with SSI accounting for 20% of all health care-associated infections in hospitalized patients [72]. The World Health Organization has shown that health care-associated infections are associated with an increase in morbidity, mortality (which may exceed 10% in certain infections) [72], hospitalization, and total costs [71]. In particular, the prolonged hospital stay for SSI presented an additional 9.7 days, and the extra hospitalization costs ranged between US \$1087 and US \$29 443 per infection [73,74]. According to the National Nosocomial Infections Surveillance System, the distribution of Tillman pathogens in surgical infections seems to have changed in the past 10 years [71,75]. The most frequently isolated bacteria are *S. aureus*, followed by coagulase-negative *Staphylococci*, *E. coli*, *E. faecalis*, *Pseudomonas aeruginosa*, *Enterobacter* spp, and *Klebsiella*. [73]

A study published in 2017 by Bueno-Lledó et al [76], including 3470 patients who underwent correction of an abdominal defect with a prosthesis, demonstrated that the use of corticosteroids or immunosuppressive drugs, surgical time greater than 180 min, and concomitant enterotomy are risk factors related to infection, abdominal defect recurrence, and need for mesh removal, conditions naturally found in intestinal transplantation. Moreover, the use of mesh can complicate future surgical approaches, specifically by limiting access to the graft for post-transplant abdominal exploration, retransplantation, or explantation.

Use of Meshes in Intestinal Transplantation

In the study by Di Benedetto et al [77] conducted between December 2001 and November 2004, 27 intestinal transplantations were reported, including 20 isolated grafts, 3 multivisceral with the liver, and 4 without the liver. Four patients who received small-intestine isolated grafts had difficulty in the abdominal wall closure, requiring prosthetic mesh; however, the 4 patients required explantation of the mesh in the first months owing to prosthesis infection.

Alexandrides et al [6] reported 8 pediatric intestinal transplantation cases; in 6 patients, the abdominal defect was treated with a PTFE mesh and in 2 patients with Silastic, both sutured

at the border of the abdominal aponeurosis. The mesh was generally replaced in a series by a smaller mesh with progressive advancement of the surrounding abdominal wall, leading to closure in steps. However, most of these patients died before the final closure. The authors strongly recommend early removal when using Silastic mesh.

This technique was performed to provide safe and temporary abdominal closure, minimize fluid and electrolyte losses, and minimize contracture of the abdominal wall [78]. On the other hand, the prolonged use of mesh with the intention of secondary healing is not recommended in adults due to the potential development of enterocutaneous fistulas and infection [79,80]. This development can be an even more difficult problem for the group of transplanted patients, who are generally immunocompromised due to the administration of anti-rejection agents, such as calcineurin inhibitors and steroids.

Thus, the delay in definitive closure increases the risk of complications. Furthermore, the use of meshes in intestinal transplantation is related to higher morbidity. Additionally, the cost of the mesh and the cost of treating associated complications have been limiting factors. [7]

Abdominal Wall Transplantation

In the last 15 years, owing to improvements in microsurgery techniques, abdominal wall transplantation has become a reality and has allowed for the restoration of the abdominal domain in complex scenarios. This type of transplantation was introduced in 1999 in the context of reconstruction of complex abdominal wall defects along with multivisceral transplantation. In their first publication, Levi et al [4] observed that approximately 20% of patients receiving intestinal transplantation or multivisceral transplantation do not have enough abdominal wall tissue for primary closure due to previous laparotomies, enterocutaneous fistulas, and ostomies [4]. Several types of abdominal wall transplantation have been described, including non-composite and non-vascularized allografts, non-composite and vascularized allografts, and composite and vascularized allografts.

Non-Composite and Non-Vascularized Allograft

This method is based on the use of both layers of the rectus abdominis muscle fascia after muscle removal [81]. The harvesting and implantation of this type of graft is a simple procedure that does not require vascular anastomoses. This method is ideal if there is a large aponeurotic defect with mobility of the skin.

The technique for graft harvesting, described by Gondolesi et al [7,81], consists of a median thoracoabdominal incision during organ harvesting. The incision is deepened to the fascia, and the subcutaneous tissue is mobilized to the lateral border of the rectus muscle. The rectus muscle, including its anterior and posterior fascia, is incised subcostally and laterally to the rectus muscle on both sides and is then excised by dividing it suprapubically. Then, it is wrapped in gauze soaked in saline solution, placed in a sterile bag with preservation solution for cold storage, and transported in a cool box with ice.

After harvesting, bench surgery becomes a fundamental step to properly separate the anterior and posterior lamina from the rectus abdominis muscles fascia and to remove the fat layer from the anterior lamina left by the entry of the perforating arteries, which must be closed with polypropylene 6-0 sutures. At the end of bench surgery, a graft consisting of a double-layered fascia is preserved in a University of Wisconsin (UW) or HTK solution and is stored at 4°C to be used at the end of the recipient's surgery. The recipient's wound should be properly prepared before closure, with a prolonged dissection of the subcutaneous tissue and skin flaps to the sites, in which the gastrojejunostomy and/or ileostomy are placed to cover the entire defect with the fascia graft. The fascia is usually fixed using 2 continuous sutures with non-absorbable thread. When skin closure is not feasible, a negative-pressure wound dressing should be placed directly on the graft [7,82].

Gondolesi et al [7] published results from 16 patients who received non-vascularized rectus abdominis muscle fascia. Abdominal wall infection developed in 7 of the 16 patients, and 3 of the affected patients did not have sufficient skin coverage over the fascia; 2 of these patients required removal of the fascia graft. Since 2009, 18 other cases have been reported. The Berlin group used the rectus abdominis muscle fascia in 5 adults, with no report of infection [81]. In the updated experience of 19 patients (9 pediatric and 10 adult) who received the fascia of the rectus abdominis muscle, Gondolesi et al [81] reported that no patient had ventral hernia in an average follow-up period of about 5 years. In their study, 12 of the 19 recipients required 23 reoperations due to local complications.

More recently, in 2019, Cassar et al [83] reported 2 cases of pediatric patients who received non-vascularized fascia grafts. In both cases, the wound was completely healed. Also in 2019, a Spanish group [84] reported 2 cases of multivisceral transplantation in adults using the non-vascularized allograft for abdominal wall closure. The first patient died with multiple infections (pneumonia and intra-abdominal collections). The second patient had no complications and presented complete incorporation of the fascia graft.

The advantages of a non-vascularized rectus abdominis' fascia graft include the fact that the grafts are potentially "non" immunogenic and that vascular anastomoses are not necessary.

The fascia of the rectus abdominis muscle is avascular, poorly cellular, and composed mainly of fibrous tissue [7], which is responsible for its low immunogenicity. Moreover, the graft can come from the same or a different organ donor, can be used on the same day of the transplantation or be preserved for up to 21 days in UW or HTK at 4°C, or can even be cryopreserved. Additional advantages are that the tissue is capable of resisting multiple reoperations and wound infections and can be replaced by another compatible graft when necessary [83]. In the long term, it is integrated with the abdominal wall and does not cause adhesions when the internal peritoneal layer is preserved. However, the literature shows that abdominal infection is associated with 44% of non-vascularized allografts [7].

Vascularized and Non-Composite Allograft

This method consists of using the posterior rectus sheath's fascia in continuity with the falciform ligament when harvesting the liver (and other organs, if there is multivisceral harvesting) [85]. Since the fascia maintains a blood supply through the falciform ligament, there are fewer infectious complications. This type of graft is indicated when there is a combined liver-intestinal transplantation or multivisceral transplantation. The falciform ligament goes inferiorly from the liver to the umbilicus and often carries an arterial branch called the hepatic falciform artery [86]. This branch comes from the hepatic artery (usually the left) and provides blood flow to the sheath of the posterior rectus abdominis muscle. This forms the anatomical basis for the use of the posterior rectus abdominis fascia as a vascularized allograft when placed together with a liver graft.

The technique for obtaining the vascularized graft consists of an incision in the midline through the skin and subcutaneous tissue, but not through the linea alba. The sheath of the anterior rectus abdominis is incised on both sides of the linea alba, and the rectus abdominis muscles along with the anterior sheath, subcutaneous tissue, and skin are displaced to expose the sheath of the posterior rectus abdominis. Parallel incisions (through the posterior sheath and peritoneum) are made in the lateral border of the rectus abdominis sheath on both sides. A lower transverse incision is made just above the umbilicus, and an upper transverse incision is made in the xiphoid area. At this point, the sheath of the posterior rectus abdominis is connected only to the falciform ligament (which is in continuity with the donor's liver). The liver is then harvested as usual in continuity with these structures [85].

Recipient hepatectomy and liver preparation in bench surgery are routinely performed. The flap from the posterior rectus abdominis sheath is inserted as an embedded flap for establishing adequate perfusion of the liver graft. In the recipient, as the incision is preferably vertical, the anterior and posterior sheaths is medially separated and sutured at the graft edges. The closure of skin is primary or in series, depending on the patient [85].

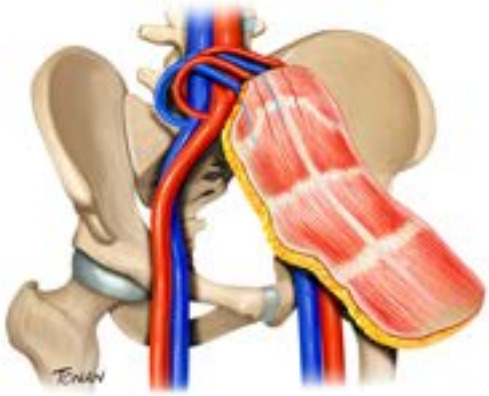

Figure 6. Abdominal wall transplantation. Created with Adobe® Photoshop.

In 2010, Agarwal et al [87] reported their experience using this technique in a 3-year-old patient. There were no complications in the abdominal wall throughout the patient's treatment. No tissue biopsies showed signs of acute rejection. Later, in 2013, Lee et al [85] reported their experience in using the sheath fascia of the vascularized posterior rectus abdominis in 4 pediatric patients in a 2-year period. At the time of publication, 3 of the 4 patients were still alive with a functioning liver and abdominal wall.

The vascularized transplantation of the abdominal wall has as a disadvantage the risk of ischemia secondary to thrombosis and graft necrosis [84]. In addition, it is necessary to alert the transplant team to harvest the sheath of the posterior rectus abdominis and the falciform ligament in continuity with the donor's liver.

Vascularized and Composite Allograft

Abdominal wall transplantation associated with intestinal transplantation was first reported in 2003 [4]. The vascularized and composite allograft of the abdominal wall comprises the peritoneum, posterior rectus abdominis sheath, both rectus abdominis muscles, anterior rectus abdominis sheath, overlapping fat and skin, and parts of the internal oblique, external oblique, and the transverse abdomen muscles (**Figure 6**). The combination of 2 highly immunogenic grafts, the intestine, and the abdominal wall (including the donor's skin) at that time represented an unknown immunological risk for allograft rejection and graft-vs-host disease [88].

Skin, as an immunogenic organ with half of its cells belonging to or related to the immune system [89,90], did not appear to be transplantable at first, but a better understanding of the immune basis of rejection [90,91] made the skin an acceptable part of a graft [92].

Pioneers in this procedure, the Miami group initially used an inverted U incision, which provided a good-sized graft for transplantation, but which can also hinder or preclude the closure of abdominal defects in donors, an important aesthetic issue [93]. In many countries, this would have a low acceptability rate with coordinators and family members of donors. The Oxford group used an elliptical, longitudinal incision over the 2 rectus abdominis muscles, leaving the pubic insertion inferiorly and the lower epigastric vessels bilaterally entering the deep surface of the graft [93]. The harvesting of abdominal organs is performed as usual and the flap of the abdominal wall is perfused with the other organs. After finishing the harvesting of organs, the detachment of the flap from the abdominal wall is completed. The vessels are divided with minimal dissection at the origin of the external iliac arteries. The abdominal wall is flushed with UW preservation solution, stored in UW solution, and placed in a cool box with ice [93].

In 2003, Levi et al [4] described transplanting an abdominal wall graft using the donor's lower epigastric vessels (maintained in continuity with femoral and iliac vessel grafts) and implanting them to the recipient's common iliac artery and vein. Subsequently, the technique was modified by Cipriani et al [94], using a microsurgical technique: the donor's epigastric pedicles were anastomosed directly with the recipient's epigastric vessels, without the need for access to the recipient's femoral and iliac vessels.

In 2014, Giele et al [95] from Oxford faced a different issue related to abdominal wall transplantation: storage and subsequent ischemia-reperfusion injury of the abdominal wall graft during the procedure was longer than 5 h. The presence of teams working at the same time on the recipient was an alternative to minimize the ischemia time, with 1 team performing the intestinal transplantation and the other remotely revascularizing the abdominal wall in the blood vessels of the recipient's forearm. The duration of the procedure was an average of 50 min (range, 30-60 min). At the end of the transplantation, the wall graft was revascularized in the abdomen.

Other groups reported series of abdominal wall transplantation [96]. In a review of 35 full-thickness vascularized abdominal wall transplantations after intestinal/multivisceral transplantations [93], the successful rate of abdominal closure after abdominal wall transplantation was very high, with 88% graft survival and no related mortality [97]; follow-up generally ranged from 6 to 7 months.

Figure 7. Abdominal wall transplantation. Created with Adobe® Photoshop.

Moreover, an advantage is that the cutaneous component of the abdominal wall can serve as an immune modulator: a recent study [93] analyzed a small cohort of 29 intestinal/multivisceral transplantations, 14 of which were combined with abdominal wall transplantation. The advantage of carrying a wall graft was demonstrated by the lower rate of intestine rejection (7% vs 27%) and lower rate (14% vs 33%) of diagnostic errors (viral infection vs rejection), followed by better survival of the intestinal graft (79% vs 60%).

Without noninvasive markers that are reliable, rejection has always been the most feared complication after intestinal transplantation. Clinical symptoms such as diarrhea, abdominal distension, and fever have often been associated and preventively considered as substitute markers for rejection [98]. The histological analysis of mucosa remains the criterion standard for detecting rejection [99], but it also creates the risk of ulceration or perforation of the graft as well as a diagnostic pitfall. Conversely, the cutaneous component of the transplanted allograft is easily accessible and can be monitored in a more consistent and less harmful way than that of the visceral organs during the rejection process [100] (**Figure 7**). Although the monitoring of small intestine rejection through the skin allograft is a fascinating hypothesis, the use of skin allograft to monitor the function of the small intestine should be considered with caution [94].

Abdominal wall transplantation appears to have some disadvantages: at the time of harvesting, the flap is disconnected

from its nerve connections located on the sides of the abdomen, resulting in the denervation of the abdominal graft. The absence of nerve stimuli leads to progressive flap hypotrophy, resulting in an abdominal wall with no muscle tone [94]. In addition, the procedure is still limited to a few transplantation centers, where the expertise of the transplant team is well integrated with the plastic surgery team. Owing to the small number of cases presented to date, it is not possible to make a definitive statement related to the best technique.

Conclusions

Expanding the abdominal domain or replacing the missing or damaged abdominal wall is one of the challenges of intestinal transplantation. Several techniques are available to overcome this issue, and whichever approach is performed, it is important to notice that they may not be mutually exclusive and that both approaches can be combined in the same recipient to ensure success of the procedure. The results obtained with these techniques have been encouraging, but a high incidence of wound complications in some reports has raised concerns. Moreover, there is no consensus among transplantation centers regarding which technique would be ideal with higher success rates and lower rates of complications.

Department and Institution Where Work Was Done

Department of Gastroenterology. Clinics Hospital of the University of São Paulo, São Paulo, Brazil.

Declaration of Figures' Authenticity

All figures submitted have been created by the authors, who confirm that the images are original with no duplication and have not been previous.

References:

1. Bond G, Reyes J, Mazariegos G, et al. The impact of positive T-cell lymphocytotoxic crossmatch on intestinal allograft rejection and survival. Transplant Proc. 2000;32(6):1197-98
2. Dudrick SJ, Wilmore DW, Vars HM, Rhoads JE. Long-term total parenteral nutrition with growth, development, and positive nitrogen balance. Surgery. 1968;64(1):134-42
3. Goulet O, Ruemmele F. Causes and management of intestinal failure in children. Gastroenterology. 2006;130(2 Suppl. 1):S16-28
4. Levi DM, Tzakis AG, Kato T, et al. Transplantation of the abdominal wall. Lancet. 2003;361(9376):2173-76
5. Ysebaert D, Duysburgh I. Prognosis of patients with non-malignant chronic intestinal failure receiving long-term home parenteral nutrition. Gastroenterology. 1995;108:1005-10. Clin Nutr. 1995;14(5):319
6. Alexandrides G, Liu P, Marshall DM, et al. Abdominal wall closure after intestinal transplantation. Plast Reconstr Surg. 2000;106(4):805-12
7. Gondolesi G, Selvaggi G, Tzakis A, et al. Use of the abdominal rectus fascia as a nonvascularized allograft for abdominal wall closure after liver, intestinal, and multivisceral transplantation. Transplantation. 2009;87(12):1884-88
8. Gupte GL, Haghighi KS, Sharif K, et al. Surgical complications after intestinal transplantation in infants and children – UK experience. J Pediatr Surg. 2010;45(7):1473-78
9. Sheth J, Sharif K, Lloyd C, et al. Staged abdominal closure after small bowel or multivisceral transplantation. Pediatr Transplant. 2012;16(1):36-40
10. Gerlach UA, Pascher A. Technical advances for abdominal wall closure after intestinal and multivisceral transplantation. Curr Opin Organ Transplant. 2012;17(3):258-67
11. Moher D, Liberati A, Tetzlaff J, et al. Preferred reporting items for systematic reviews and meta-analyses: The PRISMA statement. PLoS Med. 2009;6(7):e1000097
12. Mazariegos GV. Intestinal transplantation: Current outcomes and opportunities. Curr Opin Organ Transplant. 2009;14(5):515-21
13. Fishbein TM, Bodian CA, Miller CM. National sharing of cadaveric isolated intestinal allografts for human transplantation: A feasibility study. Transplantation. 2000;69(5):859-63
14. Smith JM, Weaver T, Skeans MA, et al. OPTN/SRTR 2018 annual data report: Intestine. Am J Transplant. 2020;20(s1):300-39
15. Debrière L, Muiesan P, Marshall M, et al. Size reduction of small bowels from adult cadaveric donors to alleviate the scarcity of pediatric size-matched organs: An Anatomical and Feasibility Study. Transplantation. 2000;69(7):1392-96
16. Reyes J, Fishbein T, Bueno J, et al. Reduced-size orthotopic composite liver-intestinal allograft. Transplantation. 1998;66(4):489-92
17. de Goyet JdV, Mitchell A, Mayer AD, et al. En bloc combined reduced-liver and small bowel transplants: From large donors to small children. Transplantation. 2000;69(4):555-59
18. Xenos ES, Khan F, Nery J, et al. Cadaveric small bowel/split liver transplantation in a child. Transpl Int. 1999;12(1):63-67
19. Byrd HS, Hobar PC. Abdominal wall expansion in congenital defects. Plast Reconstr Surg. 1989;84(2):347-52
20. Ceulemans LJ, Deferm NP, Miserez M, et al. The role of osmotic self-inflatable tissue expanders in intestinal transplant candidates. Transplant Rev (Orlando). 2016;30(4):212-17
21. Clifton MS, Heiss KF, Keating JJ, et al. Use of tissue expanders in the repair of complex abdominal wall defects. J Pediatr Surg. 2011;46(2):372-77
22. Albanese AR. [Gigantic median xipho-umbilical eventration; Method for treatment]. Rev Asoc Med Argent. 1951;65(709-710):376-78 [in Spanish]
23. Young D. Repair of epigastric incisional hernia. Br J Surg. 1961;48(211):514-16
24. Ramirez OM, Ruas E, Dellon AL. "Components separation" method for closure of abdominal-wall defects: An anatomic and clinical study. Plast Reconstr Surg. 1990;86(3):519-26
25. Nguyen V, Shestak KC. Separation of anatomic components method of abdominal wall reconstruction – clinical outcome analysis and an update of surgical modifications using the technique. Clin Plast Surg. 2006;33(2):247-57
26. Shestak KC, Edington HJ, Johnson RR. The separation of anatomic components technique for the reconstruction of massive midline abdominal wall defects: Anatomy, surgical technique, applications, and limitations revisited. Plast Reconstr Surg. 2000;105(2):731-38; quiz 739
27. Gonzalez R, Rehnke RD, Ramaswamy A, et al. Components separation technique and laparoscopic approach: A review of two evolving strategies for ventral hernia repair. Am Surg. 2005;71(7):598-605
28. den Hartog D, Eker HH, Tuinebreijer WE, et al. Isokinetic strength of the trunk flexor muscles after surgical repair for incisional hernia. Hernia. 2010;14(3):243-47
29. Oliveira LT, Essu FF, de Mesquita GHA, et al. Component separation of abdominal wall with intraoperative botulinum A presents satisfactory outcomes in large incisional hernias: a case report. Int J Surg Case Rep. 2017;41:99-104
30. Black CK, Zolper EG, Walters ET, et al. Utility of a modified components separation for abdominal wall reconstruction in the liver and kidney transplant population. Arch Plast Surg. 2019;46(5):462-69
31. Scheuerlein H, Thiessen A, Schug-Pass C, Köckerling F. What do we know about component separation techniques for abdominal wall hernia repair? Front Surg. 2018;5:24

32. Brewer MB, Rada EM, Milburn ML, et al. Human acellular dermal matrix for ventral hernia repair reduces morbidity in transplant patients. Hernia. 2011;15(2):141-45
33. Zolper EG, Black CK, Devulapalli C, et al. Long term outcomes of abdominal wall reconstruction using open component separation and biologic mesh in the liver, kidney, and small bowel transplant population. Hernia. 2020;24(3):469-79
34. Khansa I, Janis JE. Complex open abdominal wall reconstruction: Management of the skin and subcutaneous tissue. Plast Reconstr Surg. 2018;142(3 Suppl.):125s-32s
35. Lyerly MD, David C, Kim H, Sabitson MD Jr. Hernias. In: T B, editor. 13th edition. Textbook of Surgery – Biological Basis of Modern Surgical Practice: Igaku-Shoin/Saunders; 1986;1231-32
36. Restrepo JFP. Hérnias abdominais. 2a edição ed. Coelho ICU. Aparelho Digestivo – Clínica e Cirurgia: Medsi; 1996;1569-70 [in Portuguese]
37. Lichtenstein IL, Shulman AG. Ambulatory outpatient hernia surgery. Including a new concept, introducing tension-free repair. Int Surg. 1986;71(1):1-4
38. Usher FC, Ochsner J, Tuttle LL Jr. Use of marlex mesh in the repair of incisional hernias. Am Surg. 1958;24(12):969-74
39. Falci F. [Use of marlex-mesh in the therapy of inguinal hernia in adults (analysis of 100 operated cases)]. Hospital (Rio J). 1969;75(1):147-59 [in Portuguese]
40. Lichtenstein IL, Shulman AG, Amid PK, Montllor MM. The tension-free hernioplasty. Am J Surg. 1989;157(2):188-93
41. Shokry MM, Khalil IA, El-Kasapy A, et al. Multifunctional prosthetic polyester-based hybrid mesh for repairing of abdominal wall hernias and defects. Carbohydr Polym. 2019;223:115027
42. Sheen AJ. Prosthetics in hernia repair. Surg Today. 2005;35(3):196-98
43. Stephenson BM, Kingsnorth AN. Safety and sterilization of mosquito net mesh for humanitarian inguinal hernioplasty. World J Surg. 2011;35(9):1957
44. Liu L, Petro C, Majumder A, et al. The use of Vicryl mesh in a porcine model to assess its safety as an adjunct to posterior fascial closure during retromuscular mesh placement. Hernia. 2016;20(2):289-95
45. Kennedy GM, Matyas JA. Use of expanded polytetrafluoroethylene in the repair of the difficult hernia. Am J Surg. 1994;168(4):304-6
46. Mohsina A, Tamilmahan P, Mathew DD, et al. Biomaterials for hernia repair in animals: A review. Adv Anim Vet. 2014;2(4S):48-54
47. Altinli E, Sümer A, Köksal N, et al. Prevention of adhesion to prosthetic mesh: Comparison of oxidized generated cellulose, polyethylene glycol and hylan GF 20. Ulus Travma Acil Cerrahi Derg. 2011;17(5):377-82
48. Cevasco M, Itani KWF. Ventral hernia repair with synthetic, composite, and biologic mesh: Characteristics, indications, and infection profile. Surg Infect. 2012;13(4):209-15
49. Lamb JP, Vitale T, Kaminski DL. Comparative evaluation of synthetic meshes used for abdominal wall replacement. Surgery. 1983;93(5):643-48
50. Tyrell J, Silberman H, Chandrasoma P, et al. Absorbable versus permanent mesh in abdominal operations. Surg Gynecol Obstet. 1989;168(3):227-32
51. Baykal A, Onat D, Rasa K, et al. Effects of polyglycolic acid and polypropylene meshes on postoperative adhesion formation in mice. World J Surg. 1997;21(6):579-82; discussion 582-83
52. LeBlanc KA, Bellanger D, Rhynes KV 5th, et al. Tissue attachment strength of prosthetic meshes used in ventral and incisional hernia repair. A study in the New Zealand White rabbit adhesion model. Surg Endosc. 2002;16(11):1542-46
53. Greene MA, Mullins RJ, Malangoni MA, et al. Laparotomy wound closure with absorbable polyglycolic acid mesh. Surg Gynecol Obstet. 1993;176(3):213-18
54. Jenkins SD, Klamer TW, Parteka JJ, Condon RE. A comparison of prosthetic materials used to repair abdominal wall defects. Surgery. 1983;94(2):392-98
55. Schembari E, Santangelo A, Pesce A, et al. Biological mesh combined with topical negative pressure therapy in complex abdominal wounds: A short series and a review of the literature. Wounds. 2019;32(4):93-100
56. Rosen MJ. Biologic mesh for abdominal wall reconstruction: A critical appraisal. Am Surg. 2010;76(1):1
57. Smart NJ, Marshall M, Daniels IR. Biological meshes: A review of their use in abdominal wall hernia repairs. Surgeon. 2012;10(3):159-71
58. Bachman S, Ramshaw B. Prosthetic material in ventral hernia repair: How do I choose? Surg Clin North Am. 2008;88(1):101-12, ix
59. Romain B, Story F, Meyer N, et al. Comparative study between biologic porcine dermal meshes: Risk factors of postoperative morbidity and recurrence. J Wound Care. 2016;25(6):320-25
60. Muller KE, Nguyen AH, Delaney JP, Marquez S. Comparison of Permacol™ and Strattice™ for the repair of abdominal wall defects. Hernia. 2011;15(3):315-19
61. Novitsky YW, Orenstein SB, Kreutzer DL. Comparative analysis of histopathologic responses to implanted porcine biologic meshes. Hernia. 2014;18(5):713-21
62. Deeken CR, Melman L, Jenkins ED, et al. Histologic and biomechanical evaluation of crosslinked and non-crosslinked biologic meshes in a porcine model of ventral incisional hernia repair. J Am Coll Surg. 2011;212(5):880-88
63. Bondre IL, Holihan JL, Askenasy EP, et al. Suture, synthetic, or biologic in contaminated ventral hernia repair. J Surg Res. 2016;200(2):488-94
64. Garvey PB, Giordano SA, Baumann DP, et al. Long-term outcomes after abdominal wall reconstruction with acellular dermal matrix. J Am Coll Surg. 2017;224(3):341-50
65. Chatterjee A, Krishnan NM, Rosen JM. Complex ventral hernia repair using components separation with or without synthetic mesh: a cost-utility analysis. Plast Reconstr Surg. 2014;133(1):137-46
66. Hiles M, Briggs CM. The overall cost of complex ventral hernia repair with biological grafts. Gen Surg News. 2010;37(12):24-25
67. Krpata DM, Blatnik JA, Novitsky YW, Rosen MJ. Evaluation of high-risk, comorbid patients undergoing open ventral hernia repair with synthetic mesh. Surgery. 2013;153(1):120-25
68. Brown RH, Subramanian A, Hwang CS, et al. Comparison of infectious complications with synthetic mesh in ventral hernia repair. Am J Surg. 2013;205(2):182-87
69. Quyn AJ, Johnston C, Hall D, et al. The open abdomen and temporary abdominal closure systems – historical evolution and systematic review. Colorectal Dis. 2012;14(8):e429-38
70. Mees J, Mardin WA, Senninger N, et al. Treatment options for postoperatively infected abdominal wall wounds healing by secondary intention. Langenbecks Arch Surg. 2012;397(8):1359-66
71. Bagnall NM, Vig S, Trivedi P. Surgical-site infection. Surgery (Oxford). 2009;27(10):426-30
72. Klevens RM, Edwards JR, Richards CL, et al. Estimating health care-associated infections and deaths in U.S. hospitals, 2002. Public Health Rep. 2007;122(2):160-66
73. World Health Organization. Global guidelines for the prevention of surgical site infection: World Health Organization; 2016
74. Scott RD. The direct medical costs of healthcare-associated infections in US hospitals and the benefits of prevention. Center for Disease Control and Prevention. 2009
75. Mangram AJ, Horan TC, Pearson ML, et al. Guideline for prevention of surgical site infection, 1999. Centers for Disease Control and Prevention (CDC) Hospital Infection Control Practices Advisory Committee. Am J Infect Control. 1999;27(2):97-132; quiz 133-34; discussion 96
76. Bueno-Lledó J, Torregrosa-Gallud A, Sala-Hernandez A, et al. Predictors of mesh infection and explantation after abdominal wall hernia repair. Am J Surg. 2017;213(1):50-57
77. Di Benedetto F, Lauro A, Masetti M, et al. Use of prosthetic mesh in difficult abdominal wall closure after small bowel transplantation in adults. Transplant Proc. 2005;37(5):2272-74
78. Mansberger AR Jr., Kang JS, Beebe HG, Le Flore I. Repair of massive acute abdominal wall defects. J Trauma. 1973;13(9):766-74
79. Voyles CR, Richardson JD, Bland KI, et al. Emergency abdominal wall reconstruction with polypropylene mesh: Short-term benefits versus long-term complications. Ann Surg. 1981;194(2):219-23
80. Fansler RF, Taheri P, Cullinane C, et al. Polypropylene mesh closure of the complicated abdominal wound. Am J Surg. 1995;170(1):15-18
81. Gondolesi GE, Aguirre NF. Techniques for abdominal wall reconstruction in intestinal transplantation. Curr Opin Organ Transplant. 2017;22(2):135-41
82. Farinelli PA, Rubio JS, Padin JM, et al. Use of nonvascularized abdominal rectus fascia after liver, small bowel, and multiorgan transplantation: Long-term follow-up of a single-center series. Transplant Proc. 2017;49(8):1810-14
83. Cassar N, Cortes-Cerisuelo M, Bambridge C, et al. The difficult abdominal closure after paediatric intestinal transplantation: Use of abdominal rectus muscle fascia and literature review. Pediatr Transplant. 2019;23(5):e13473
84. Justo I, Manrique A, Calvo J, et al. Abdominal wall transplantation in organ transplantation: Our experience. Cir Esp. 2019;97(5):247-53

85. Lee JC, Olaitan OK, Lopez-Soler R, et al. Expanding the envelope: The posterior rectus sheath – liver vascular composite allotransplant. Plast Reconstr Surg. 2013;131(2):209e-18e
86. Michels NA. Newer anatomy of the liver and its variant blood supply and collateral circulation. Am J surg. 1966;112(3):337-47
87. Agarwal S, Dorafshar AH, Harland RC, et al. Liver and vascularized posterior rectus sheath fascia composite tissue allotransplantation. Am J Transplant. 2010;10(12):2712-16
88. Selvaggi G, Levi DM, Cipriani R, et al. Abdominal wall transplantation: surgical and immunologic aspects. Transplant Proc. 2009;41(2):521-22
89. Seneschal J, Clark RA, Gehad A, et al. Human epidermal Langerhans cells maintain immune homeostasis in skin by activating skin resident regulatory T cells. Immunity. 2012;36(5):873-84
90. Starzl R, Brandacher G, Lee WPA, et al. Review of the early diagnoses and assessment of rejection in vascularized composite allotransplantation. Clin Dev Immunol. 2013;2013:402980
91. Schneeberger S, Morelon E, Landin L, Committee EC. Vascularized composite allotransplantation: A member of the transplant family? Transplantation. 2012;93(11):1088-91
92. Sarhane KA, Khalifian S, Ibrahim Z, et al. Diagnosing skin rejection in vascularized composite allotransplantation: Advances and challenges. Clin Transplant. 2014;28(3):277-85
93. Giele H, Vaidya A, Reddy S, Vrakas G, Friend P. Current state of abdominal wall transplantation. Curr Opin Organ Transplant. 2016;21(2):159-64
94. Cipriani R, Contedini F, Santoli M, et al. Abdominal wall transplantation with microsurgical technique. Am J Transplant. 2007;7(5):1304-7
95. Giele H, Bendon C, Reddy S, et al. Remote revascularization of abdominal wall transplants using the forearm. Am J Transplant. 2014;14(6):1410-16
96. Haveman JW, Tempelman TM, Hofker HS, et al. [First combined intestinal and abdominal wall transplantation in the Netherlands]. Ned Tijdschr Geneeskd. 2016;160:A9788 [in Dutch]
97. Berli JU, Broyles JM, Lough D, et al. Current concepts and systematic review of vascularized composite allotransplantation of the abdominal wall. Clin Transplant. 2013;27(6):781-89
98. Sudan D. Long-term outcomes and quality of life after intestine transplantation. Curr Opin Organ Transplant. 2010;15(3):357-60
99. Ruiz P. Updates on acute and chronic rejection in small bowel and multivisceral allografts. Curr Opin Organ Transplant. 2014;19(3):293-302
100. Gerlach UA, Vrakas G, Sawitzki B, et al. Abdominal wall transplantation: skin as a sentinel marker for rejection. Am J Transplant. 2016;16(6):1892-900

APÊNDICE D

ARTIGO SUBMETIDO PARA PUBLICAÇÃO – EM REVISÃO

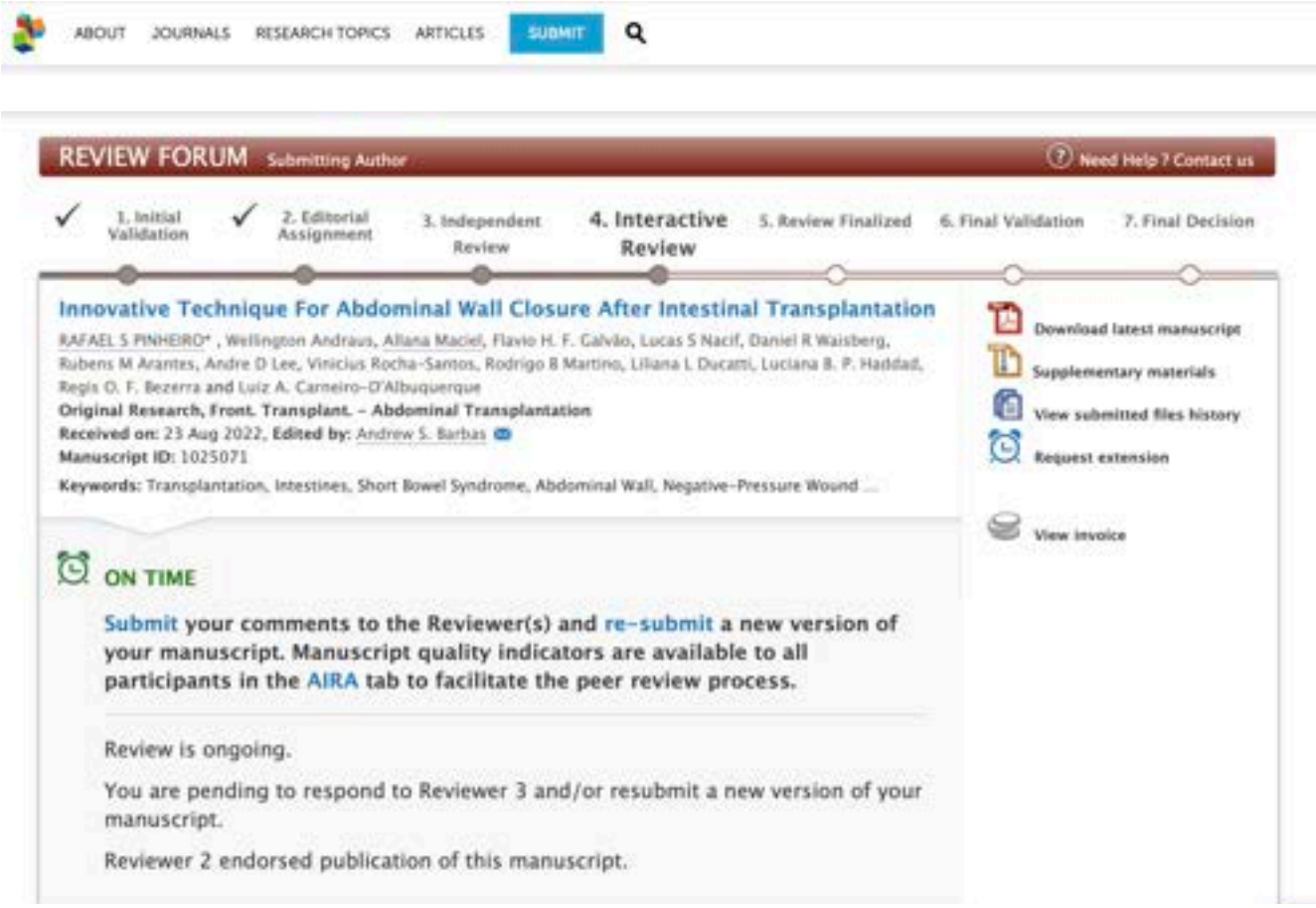

Innovative Technique For Abdominal Wall Closure After Intestinal Transplantation

RAFAEL S. PINHEIRO[1*], Wellington Andraus[1], Allana Maciel[1], Flavio H. Galvão[1], Lucas S. Nacif[1], Daniel R. Waisberg[1], Rubens M. Arantes[1], Andre D. Lee[1], Vinicius Rocha-Santos[1], Rodrigo B. Martino[1], Liliana L. Ducatti[1], Luciana B. Haddad[1], Regis O. Bezerra[1], Luiz A. Carneiro-D'Albuquerque[1]

[1]Clinical Hospital, Faculty of Medicine, University of São Paulo, Brazil

Submitted to Journal:
Frontiers in Transplantation

Specialty Section:
Abdominal Transplantation

Article type:
Original Research Article

Manuscript ID:
1025071

Received on:
23 Aug 2022

Journal website link:
www.frontiersin.org

In review

Conflict of interest statement

The authors declare that the research was conducted in the absence of any commercial or financial relationships that could be construed as a potential conflict of interest

Author contribution statement

WA, RSP and ACF have made substantial contributions to conception and design, acquisition and interpretation of data; have been involved in drafting and revising the manuscript.
FHFG and DRW have made substantial contributions to acquisition, analysis and interpretation of data; have been involved in drafting and revising the manuscript.
ADL, RMA and LSN have made substantial contributions to design, analysis and interpretation of data; have been involved in and revising the manuscript.
VRS and RBM have made substantial contributions to analysis and interpretation of data.
LD have made substantial contributions to acquisition, interpretation of data; have been involved in drafting the manuscript.
LACD and FHFG have been involved in revising critically for important intellectual content.
LACD has been involved in revising the manuscript critically for important intellectual content, and have given final approval of the version to be published.

In review

Keywords

Transplantation, Intestines, Short Bowel Syndrome, Abdominal Wall, Negative-Pressure Wound Therapy, Hernia, Abdominal

Abstract

Word count: 185

isolated intestinal transplantation (IT) is indicated in cases of intestinal failure (IF) in the absence of severe liver dysfunction. Short bowel syndrome (SBS) is the most frequent IF etiology, and due to the absence or considerable reduction of intestinal loops in the abdominal cavity in these patients, there is atrophy and muscle retraction of the abdominal wall, leading to loss of abdominal domain and elasticity and preventing the primary closure of the abdominal wall. The aim of this study is to describe an innovative technique for closure of the abdominal wall after IT without using prostheses. Methods: Four patients underwent IT with impossibility of primary closure of the abdominal wall. We describe a novel technique, associating a series of vacuum-assisted closure dressings, components separation and relaxation incisions. Results: All patients presented a successful closure of the abdominal wall with the described technique, with no complications related to the abdominal wall. Conclusion: the innovative technique proved to be safe, effective and reproducible, being an option for abdominal wall closure after IT. Employing this technique in a greater number of cases is necessary to confirm these results.

Contribution to the field

The research provides one more option for abdominal wall closure in bowel and multivisceral transplantation, as this is a major challenge in this type of organ transplant.

Ethics statements

Studies involving animal subjects
Generated Statement: No animal studies are presented in this manuscript.

Studies involving human subjects
Generated Statement: The studies involving human participants were reviewed and approved by CAPPESQ. The patients/participants provided their written informed consent to participate in this study.

Inclusion of identifiable human data
Generated Statement: No potentially identifiable human images or data is presented in this study.

Data availability statement

Generated Statement: The original contributions presented in the study are included in the article/supplementary material, further inquiries can be directed to the corresponding author/s.

In review

Innovative Technique For Abdominal Wall Closure After Intestinal Transplantation

Rafael S. Pinheiro[1]; Wellington Andraus*[1]; Allana C. Fortunato[1]; Flavio H. F. Galvão[1]; Lucas S. Nacif[1]; Daniel R. Waisberg[1]; Rubens M. Arantes[1]; Andre D. Lee[1]; Vinicius Rocha-Santos[1]; Rodrigo B Martino[1]; Liliana Ducatti[1]; Luciana Bertocco de Paiva Haddad[1]; Regis O F Bezerra[2]; Luiz Augusto Carneiro-D'Albuquerque[1]

1 - Disciplina de Transplante de Figado e Orgaos do Aparelho Digestivo, Departamento de Gastroenterologia, Hospital das Clinicas HCFMUSP, Faculdade de Medicina, Universidade de Sao Paulo, Sao Paulo, SP, BR

2- Departamento de Radiologia, Instituto do Cancer do Estado de São Paulo, Faculdade de Medicina, Universidade de Sao Paulo, Sao Paulo, SP BR.

*Corresponding author: Wellington Andraus, wellingtonandraus@gmail.com

Address: Rua Eneas Carvalho de Aguiar, 255, Instituto Central, Cerqueira Cesar, São Paulo, SP, CEP 05403-000. 9º andar, Sala do transplante de fígado

Tel.: + 55 11 2661-3323; Cel.: +55 11 98211-8909

In review

Abbreviations

HC-FMUSP: Hospital das Clínicas of the Medical School of the University of São Paulo

IF: Intestinal failure

IT: intestinal transplantation

SBS: Short bowel syndrome

VAC: Vacuum-assisted closure (VAC)

Word count: 2,602

Authors' Contributions

WA, RSP and ACF have made substantial contributions to conception and design, acquisition and interpretation of data; have been involved in drafting and revising the manuscript.

FHFG and DRW have made substantial contributions to acquisition, analysis and interpretation of data; have been involved in drafting and revising the manuscript.

ADL, RMA and LSN have made substantial contributions to design, analysis and interpretation of data; have been involved in and revising the manuscript.

VRS and RBM have made substantial contributions to analysis and interpretation of data.

LD have made substantial contributions to acquisition, interpretation of data; have been involved in drafting the manuscript.

LACD and FHFG have been involved in revising critically for important intellectual content.

LACD has been involved in revising the manuscript critically for important intellectual content, and have given final approval of the version to be published.

Disclosure: There is no actual or potential conflicts of interest by any of the authors.

Funding: There is no financial support related to the content of this study.

In review

Abstract

Background*:* isolated intestinal transplantation (IT) is indicated in cases of intestinal failure (IF) in the absence of severe liver dysfunction. Short bowel syndrome (SBS) is the most frequent IF etiology, and due to the absence or considerable reduction of intestinal loops in the abdominal cavity in these patients, there is atrophy and muscle retraction of the abdominal wall, leading to loss of abdominal domain and elasticity and preventing the primary closure of the abdominal wall. The aim of this study is to describe an innovative technique for closure of the abdominal wall after IT without using prostheses. **Methods***:* Four patients underwent IT with impossibility of primary closure of the abdominal wall. We describe a novel technique, associating a series of vacuum-assisted closure dressings, components separation and relaxation incisions. **Results**: All patients presented a successful closure of the abdominal wall with the described technique, with no complications related to the abdominal wall. **Conclusion**: the innovative technique proved to be safe, effective and reproducible, being an option for abdominal wall closure after IT. Employing this technique in a greater number of cases is necessary to confirm these results.

Key Words: transplantation; intestines; short bowel syndrome; abdominal wall; Negative-Pressure Wound Therapy; hernia, abdominal

In review

Introduction

In intestinal transplantation (IT) the main organ to be transplanted is the small intestine, which can be performed in combination with other organs. The type of transplantation depends on the underlying disease, the quality of other abdominal organs, the presence of liver disease and the number of previous abdominal surgical procedures. Isolated intestinal transplantation (IT) is indicated in cases of intestinal failure (IF) in the absence of severe liver dysfunction.

Short bowel syndrome (SBS) is the most frequent IF etiology, accounting for 35 to 75% of cases.(1, 2) Due to the absence or considerable reduction of intestinal loops in the abdominal cavity, these patients present atrophy and muscle retraction of the abdominal wall, leading to loss of abdominal domain and elasticity. This complication is an aggravating factor in IT, since it prevents the primary closure of the abdominal wall. Moreover, graft edema after revascularization tends to worsen the difficulty in achieving tension-free primary closure.(3) A forced attempt of closing the wall can result in compartment syndrome and ischemia with consequent graft necrosis and high morbimortality.(4)

Several techniques for trying to solve the problem of abdominal wall closure have already been proposed, ranging from elementary techniques, such as component separation, to complex technique of abdominal wall transplantation; however, all these techniques potentially present severe complications that put at risk the survival of both the graft and the patient. Successful closure in this chronically ill and highly immunosuppressed population proved to be very important in order to decrease the risk of infections, fistulas, mycotic aneurysms, as well as to improve the survival of grafts and patients.(5)

In review

The aim of our study is to propose an innovative technique for abdominal wall closure that is easy to perform, reproducible and that reduces complications related to the abdominal wall in patients after IT.

Methods

Our study was carried out at the Hospital das Clínicas of the Medical School of the University of São Paulo (HC-FMUSP) by the Transplantation Division of Liver and Digestive Tract Organs, from December 2017 to February 2021.

Four patients underwent Isolated IT due to SBS and their abdominal wall closure was performed in series with the novel technique described in our study. All patients presented severe reduction of the abdominal cavity with severe fibrosis and wall atrophy due to multiple previous surgical procedures and could not undergo tension-free primary closure without using prosthesis.

The studied variables were: age, gender, number of surgical procedures, days required for complete closure of the cavity and quantification of the increase in the abdominal cavity. To quantify the progress of the cavity expansion, we performed a tomographic comparison of the measurements of both anteroposterior distance and intra-peritoneal area in the corresponding coronal section, before and after the IT, with the abdominal cavity already completely closed. The reference points for measurements were the anterior face of the vertebral body at the level of L3 vertebra up to the umbilical scar's skin. Intra-peritoneal area was measured in cm^2 and the difference between pre and post IT values were shown in percentage.

All the patients included in our study signed the informed consent form.

Our study was approved by the HC-FMUSP research ethics committee, opinion no. 3,730,175.

In review

Description of the technique

Vacuum-assisted closure (VAC) dressing is applied in the transplantation day, at the end of the procedure, as follows: coverage of all abdominal viscera with a sterile multi-perforated plastic (figure 1a); insertion of cross-linked polyurethane foam with 400 to 600 μm pores over the plastic coverage in order to cover the aponeurotic defect (figure 1b); coverage of incision, foam and adjacent skin with meticulously coupled plastic adhesive strips, in order to cover external holes (gastrostomy/duodenostomy/ileostomy); position the negative pressure device on the foam and connect to the continuous vacuum pump (figure 1c). The patient is then referred to the ICU.

Within 48-72 hours after the transplantation, a new surgical procedure is performed for sterile removal of previous dressing. At this moment, a wide components separation of the abdominal wall is performed, freeing the anterior sheath of both the rectus abdominis and external oblique muscles bilaterally from subcutaneous fat and skin (figure 2a). Then, relaxation incisions are made in the anterior sheath of the rectus abdominis muscle (figure 2b). Both aponeurosis and tension-free edges of the skin are sutured with non-absorbable thread and separated stitches (figure 2c). In addition, some separated “U” stitches are performed on the aponeurosis and skin in order to approximate the edges and guide the vacuum force for posterior closure. To prevent lacerations, the skin is protected by hydrocolloid plaques (figure 2D), followed by new VAC dressing.

Thereafter, new procedures are carried out every 48-72 hours in order to suture the tension-free edges of the skin and aponeurosis. If there is still an aponeurotic defect, new approximation stitches in both skin and aponeurosis, as well as a new

In review

vacuum dressing, are performed. This step is repeated until achieving full primary closure of the abdominal defect (Figure 3a and 3B). If the previous relaxation incisions are already healed, new ones are performed in different locations.

There is a recommendation of only preoperative fasting preceding the surgical procedure. During the intervals, the patient receives enteral nutrition according to the nutritional goal, without calorie and protein loss.

6 months after the transplantation, ileostomy take down was successfully performed.

Results

The four patients in our study were male, with ages ranging from 19 to 45 years old. The mean number of procedures for changing the dressings was 3.6 ± 2 and the mean period of reoperations per patient was 15 ± 11.2 days. No patient presented complications related to the closure of the abdominal wall during the period of changing dressings or after complete healing.

Three of the four patients who underwent the described technique had both graft and patient survival rate of 100% in 1 year and did not progress with hernias, dehiscence, surgical site infection or any other complications related to the abdominal wall. Despite the great detachment promoted by the components separation, no patient evolved with seroma or subcutaneous collections after complete closure and vacuum removal. The fourth patient is still in the recent postoperative period; however, 10 days after the IT, this patient has already successfully reached aponeurosis closure and is currently using vacuum only in the skin.

In review

In all cases, diet was reintroduced before the complete closure of the abdominal wall. All patients received an early postoperative diet and were stimulated with motor physical therapy and ambulation during the interval between surgical procedures.

Three patients underwent intestinal transit reconstruction with removal of the ileostomy 6 months after complete closure of the abdominal wall. In this procedure, adhesions between the intestinal loops and the abdominal wall were not observed. Computed tomographies demonstrated significant gain in abdominal domain after transplantation in comparison to pre IT scans. (Figure 4a-d). The patients' pre-transplantation median of anteroposterior distance was 63.2 mm (min: 29 mm and max: 73.3 mm) and the median after abdominal wall closure was 98.8 mm (min: 90 mm and max: 124.4mm), showing a considerable increase. Regarding the abdominal cavity area in the corresponding coronal cut, postoperative increase was 226%, 138% and 55%.

In review

Discussion

The technique proposed by us in our study is innovative, safe and has the potential to be reproducible in most patients undergoing IT. It has three important benefits: resolving defects in both skin and aponeurosis, dismissing the use of prosthetic meshes and performing efficient drainage of the abdomen and subcutaneous tissue, thus reducing the risk of collections.

When primary closure is not possible, there are several strategies that have been described for reconstructing the abdominal wall after an IT. The main approaches focus on reducing the volume of the graft or expanding the abdominal cavity.(4) Reducing the volume of the graft can be achieved using small donors(6) or

anatomical reduction of the graft's size through bench surgery(7), mainly in pediatric transplants, in order to avoid high mortality rates in the waiting list(8). However, reduced-size grafts are related to high rates of complications. In addition, due to a high scarcity of organs, the use of small donors in adults is less frequent. Thus, techniques for increasing the abdominal cavity are preferred.

Techniques vary in complexity, use of prostheses and postoperative morbidity. Techniques such as components separation, use of absorbable meshes, use of non-absorbable meshes, use of tissue-engineered skin equivalents, acellular dermal matrix, skin grafts, and transplantation of abdominal wall(9) and of aponeurosis, have been described.

The closure of the abdominal wall after graft implantation in the IT presents some aggravating factors, since many patients have a chronic reduction of the abdominal cavity. In patients with successful primary closure after IT, about 20 to 33% progress with secondary dehiscence of the surgical wound, leading to complications such as eviscerations, fistulas and infections.(10-12) The existing techniques for abdominal wall closure involve prostheses made of synthetic or biological materials, which not only generate high costs, as also increase the risk of complications. This is especially due to the fact that the mesh is in direct contact with the loops, increasing the risk of adhesions and fistulas. Moreover, in the context of severe immunosuppression and ileostomy close to the surgical wound (since the abdominal wall is reduced), the use of a prosthetic mesh provides an additional risk.

Abdominal wall transplantation, as an alternative technique for abdominal wall closure after IT, increases the complexity of the procedure, extending the time of intestinal graft ischemia.(13) In addition, this procedure puts the patient at high

In review

immunological risk, since the skin is one of the most immunogenic organs and presents a higher chance of rejection.(14) This graft must be vascularized with both arterial and venous epigastric anastomoses, that are at risk of complications.(15) The isolated aponeurosis transplantation has an increased risk of failure due to the lower vascularization of this type of graft.(4) Moreover, both the isolated aponeurosis transplantation and the use of prosthetic mesh do not solve the problem of skin closure.

The VAC technique for abdominal wall closure is used for critically ill patients, particularly those with complex surgical procedures, such as trauma victims who have undergone damage control surgery, patients with severe intra-abdominal infections, acute mesenteric ischemia, abdominal compartment syndrome and necrotic infections of the abdominal wall.(16)

In this VAC technique, the interaction of foam with tissue under negative pressure results in macro and micro deformations that stimulate wound granulation and increase the production of pro-angiogenic growth factor, accelerating the healing.(17) In addition, it contributes to the reduction of systemic inflammation and damage to abdominal organs, decreases bacterial colonization and improves collagen deposition in the wound.(18, 19) In 2001, it was evidenced that the dressing under negative pressure causes a centripetal force that results in the approximation of the wound edges.(20) Cheatham *et al.(21)* concluded that the VAC technique is associated with high rates of abdominal closure in 30 days, as well as with lower morbimortality. VAC reduces the need for medical and nursing care, especially in patients who have an excessive amount of abdominal secretion. Studies with level of evidence and grading of recommendation 1A(22) and 2A(23) suggest dressing changes every 48 to 72 hours, providing significant comfort not

In review

only to patients, but also for the healthcare teams. An additional benefit is the continuous suction of the abdominal cavity, which prevents the formation of intra-abdominal collections. These collections frequently irritate the diaphragmatic muscles and can cause pleural effusions and pain. Thus, the patient may present a faster and more effective respiratory and motor recovery.

The technique proposed in our study consists of a combination of VAC with components separation and a series of relaxation incisions. It is an easily reproducible technique that does not use synthetic prostheses or biological materials, allowing the assessment of the graft at each reoperation. As a result, there is less chance of adhesions among intestinal loops and the loops with abdominal wall, and there is the optimization of drainage of the abdominal cavity in the first postoperative days. Changing the VAC dressing does not interfere with intestinal peristalsis, thus not preventing the reintroduction of an enteral diet immediately after the procedure. During intervals between procedures, ambulation is possible without difficulty, since the negative pressure device is mobile and easily carried.

The vacuum's fistulization potential is a possible criticism regarding the use of the proposed technique. This risk would be even greater in the first postoperative days, since the anastomoses are still fresh and not yet healed. However, several publications have evidenced the advantages of VAC therapy in abdomens that present impossibility of primary closure, emphasizing the low risk of developing intestinal fistula. The presence of peri-anastomosis secretion probably causes inflammation, or possible infectious focus, that is more related to the anastomosis fistula than to the negative pressure applied by the vacuum. In a series of 112 patients, only 5 (4.5%) developed fistula: one pancreatic, one gastric and three in

In review

the small bowell.(24) In 2005, Kaplan *et al.(25)* evidenced that VAC is a satisfactory technique for temporary closure of the abdominal cavity, being related to the occurrence of complications, such as fistulas, in only 2.6% of cases. Rao *et al.* evaluated 29 patients with abdominal closure with VAC, in which 14 of these patients had intestinal anastomosis and 15 did not. Three of the patients with anastomosis developed intestinal fistula, although the location of the fistula was different from the location of the suture. In the remaining patients without intestinal suture, three also developed enteric fistula. Thus, the study suggests that continuous negative pressure does not predispose to the occurrence of anastomosis' fistula.(26) A systematic review and meta analysis published by Atema *et.al(27)* identified 74 studies describing 78 series of patients, comprising 4,358 patients in total; 3,461 (79%) of them had impossibility of abdominal closure due to non-traumatic causes. The highest rate of fistulas was observed in the association of abdominal closure with mesh (17.2%, CI 95% 9.3–29.5%, χ^2 p= 0.012, I^2= 66%), while the association of VAC with fascial traction showed the lowest weighted rate of fistula (5.7%, CI 95% 2.2–14.1%, χ^2 p= <0.001, I^2= 79%). Therefore, intra-abdominal complications resulting from VAC therapy are not frequent.(28) The most reported complication rates in the literature are related to the previous comorbidities of patients and to skin irritation due to the use of the adhesive(29). In addition, departments that perform a great volume of IT, such as Georgetown University, have already used VAC on the IT day as a tool to reduce initial edema after revascularization, as well as to enable the implantation of smaller meshes in a second moment, with no reports of intestinal fistulas.

One of the limitations of our study was the low number of patients. Future studies with a greater number of cases will probably have new characteristics to evaluate

In review

and will contribute to a better assessment of the technique. In addition, not all patients will be eligible for complete closure using the technique that associates component separation with VAC; however, the resulting abdominal defect will be much smaller. The negative aspect of our technique is the need for surgical reoperations, which can prolong the hospital stay.

Our experience associating component separation, relaxation incisions and VAC proved to be effective in three of the four cases after a 12-month follow-up with 100% survival rate; none of the patients presented complications related to the closure of the abdominal wall. The fourth patient is still in a recent postoperative period.

Conclusion

The technique described in our study is safe, effective and affordable, being an additional possibility for abdominal wall closure after IT. In addition to being an easily reproducible technique, it allows a series of graft evaluations and early diagnosis of possible complications.

In review

REFERENCES

1. Fishbein TM, Kaufman SS, Florman SS, Gondolesi GE, Schiano T, Kim-Schluger L, et al. Isolated intestinal transplantation: proof of clinical efficacy. Transplantation. 2003;76(4):636-40.
wenty-seven consecutive intestinal and multivisceral transplants in adult patients: a 4-year clinical experience. Transplant Proc. 2005;37(6):2679-81.
3. Ysebaert D, Duysburgh I. Prognosis of patients with non-malignant chronic intestinal failure receiving long-term home parenteral nutrition. Gastroenterology 1995; 108:1005-10. Clin Nutr. 1995;14(5):319.

4. Gondolesi G, Selvaggi G, Tzakis A, Rodríguez-Laiz G, González-Campaña A, Fauda M, et al. Use of the abdominal rectus fascia as a nonvascularized allograft for abdominal wall closure after liver, intestinal, and multivisceral transplantation. Transplantation. 2009;87(12):1884-8.
5. Sheth J, Sharif K, Lloyd C, Gupte G, Kelly D, de Ville de Goyet J, et al. Staged abdominal closure after small bowel or multivisceral transplantation. Pediatr Transplant. 2012;16(1):36-40.
6. Fryer JP. Intestinal transplantation: current status. Gastroenterol Clin North Am. 2007;36(1):145-59, vii.
7. Nery JR, Weppler D, DeFaria W, Liu P, Romero R, Tzakis AG. Is the graft too big or too small? Technical variations to overcome size incongruity in visceral organ transplantation. Transplant Proc. 1998;30(6):2640-1.
8. de Ville de Goyet J, Mitchell A, Mayer AD, Beath SV, McKiernan PJ, Kelly DA, et al. En block combined reduced-liver and small bowel transplants: from large donors to small children. Transplantation. 2000;69(4):555-9.
9. Grevious MA, Iqbal R, Raofi V, Beatty E, Oberholzer J, Cohen M, et al. Staged approach for abdominal wound closure following combined liver and intestinal transplantation from living donors in pediatric patients. Pediatr Transplant. 2009;13(2):177-81.
10. Bond G, Reyes J, Mazariegos G, Wu T, Schaefer N, Demetris J, et al. The impact of positive T-cell lymphocytotoxic crossmatch on intestinal allograft rejection and survival. Transplant Proc. 2000;32(6):1197-8.
11. Dudrick SJ, Wilmore DW, Vars HM, Rhoads JE. Long-term total parenteral nutrition with growth, development, and positive nitrogen balance. 1968. Nutr Hosp. 2001;16(6):287-92; discussion 6-7. P
12. Mazariegos GV. Intestinal transplantation: current outcomes and opportunities. Curr Opin Organ Transplant. 2009;14(5):515-21.
13. Giele H, Vaidya A, Reddy S, Vrakas G, Friend P. Current state of abdominal wall transplantation. Curr Opin Organ Transplant. 2016;21(2):159-64.
14. Starzl R, Brandacher G, Lee WP, Carbonell J, Zhang W, Schnider J, et al. Review of the early diagnoses and assessment of rejection in vascularized composite allotransplantation. Clin Dev Immunol. 2013;2013:402980.
15. Cassar N, Cortes-Cerisuelo M, Bambridge C, Ali A, Heaton N, Vilca-Melendez H. The difficult abdominal closure after paediatric intestinal transplantation: Use of abdominal rectus muscle fascia and literature review. Pediatr Transplant. 2019;23(5):e13473.
16. D'Hondt M, Devriendt D, Van Rooy F, Vansteenkiste F, D'Hoore A, Penninckx F, et al. Treatment of small-bowel fistulae in the open abdomen with topical negative-pressure therapy. Am J Surg. 2011;202(2):e20-4.
17. Trueman P, Flack S, Loonstra A, Hauser T. The feasibility of using V.A.C. Therapy in home care patients with surgical and traumatic wounds in the Netherlands. Int Wound J. 2008;5(2):225-31.
18. Goverman J, Yelon JA, Platz JJ, Singson RC, Turcinovic M. The "Fistula VAC," a technique for management of enterocutaneous fistulae arising within the open abdomen: report of 5 cases. J Trauma. 2006;60(2):428-31; discussion 31.
19. Kubiak BD, Albert SP, Gatto LA, Snyder KP, Maier KG, Vieau CJ, et al. Peritoneal negative pressure therapy prevents multiple organ injury in a chronic porcine sepsis and ischemia/reperfusion model. Shock. 2010;34(5):525-34.
20. LFN F, LUCAS L, VRS V, CASTAN M, MRP S. O uso de curativos a vácuo como tratamento intermediário no trauma complexo de extremidade: experiência clínica e padronização técnica. Arquivos Catarinenses de Medicina. 2010;39(2).
21. Cheatham ML, Demetriades D, Fabian TC, Kaplan MJ, Miles WS, Schreiber MA, et al. Prospective study examining clinical outcomes associated with a negative pressure wound therapy system and Barker's vacuum packing technique. World J Surg. 2013;37(9):2018-30.
In review

22. Gäddnäs F, Saarnio J, Ala-Kokko T, Laurila J, Koivukangas V. Continuous retention suture for the management of open abdomen: a high rate of delayed fascial closure. Scand J Surg. 2007;96(4):301-7.
23. Gracias VH, Braslow B, Johnson J, Pryor J, Gupta R, Reilly P, et al. Abdominal compartment syndrome in the open abdomen. Arch Surg. 2002;137(11):1298-300.
24. Barker DE, Kaufman HJ, Smith LA, Ciraulo DL, Richart CL, Burns RP. Vacuum pack technique of temporary abdominal closure: a 7-year experience with 112 patients. J Trauma. 2000;48(2):201-6; discussion 6-7.
25. Bovill E, Banwell PE, Teot L, Eriksson E, Song C, Mahoney J, et al. Topical negative pressure wound therapy: a review of its role and guidelines for its use in the management of acute wounds. Int Wound J. 2008;5(4):511-29.
26. Rao M, Burke D, Finan PJ, Sagar PM. The use of vacuum-assisted closure of abdominal wounds: a word of caution. Colorectal Dis. 2007;9(3):266-8.
27. Atema JJ, Gans SL, Boermeester MA. Systematic review and meta-analysis of the open abdomen and temporary abdominal closure techniques in non-trauma patients. World J Surg. 2015;39(4):912-25.
28. Miller PR, Meredith JW, Johnson JC, Chang MC. Prospective evaluation of vacuum-assisted fascial closure after open abdomen: planned ventral hernia rate is substantially reduced. Ann Surg. 2004;239(5):608-14; discussion 14-6.
29. Leijnen M, Steenvoorde P, van Doorn L, Zeillemaker AM, da Costa SA, Oskam J. Does VAC increase the risk of venous thromboembolism? J Wound Care. 2007;16(5):211-2.

In review

LEGENDS

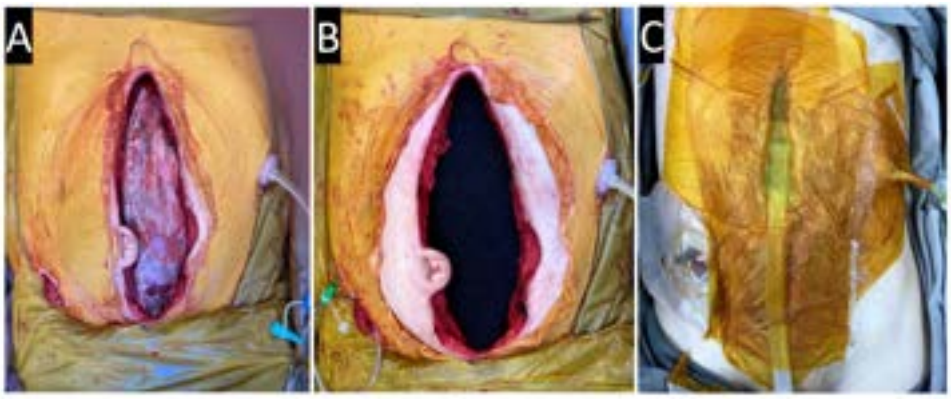

Fig. 1 (a): Sterile multi-perforated plastic covering the viscera; (b) Polyurethane foam over the multi-perforated plastic coverage. (c) Vacuum created with the aid of plastic films.

In review

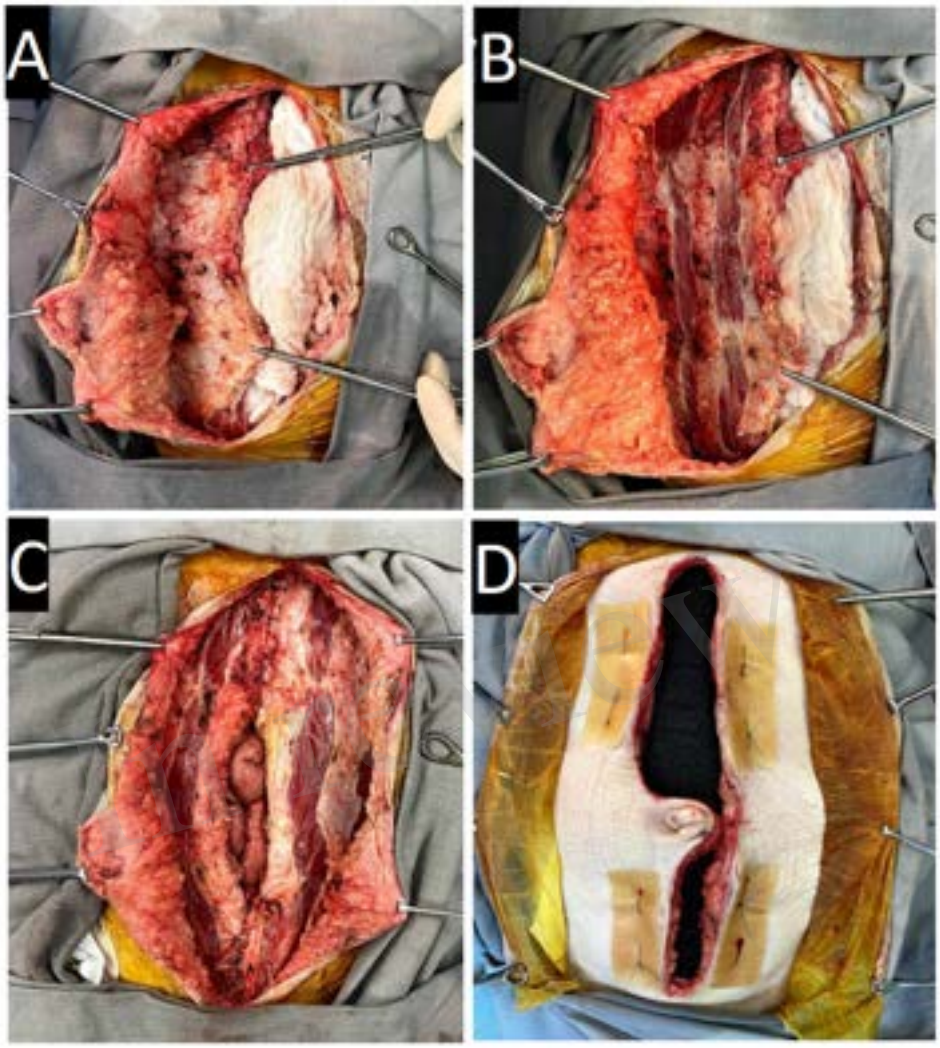

Fig. 2 (a): Components separation. (b) Relaxation incisions. (c) Approximation of edges with non-absorbable stitches. (d) Stitches for guiding the vacuum, protected by hydrocolloid

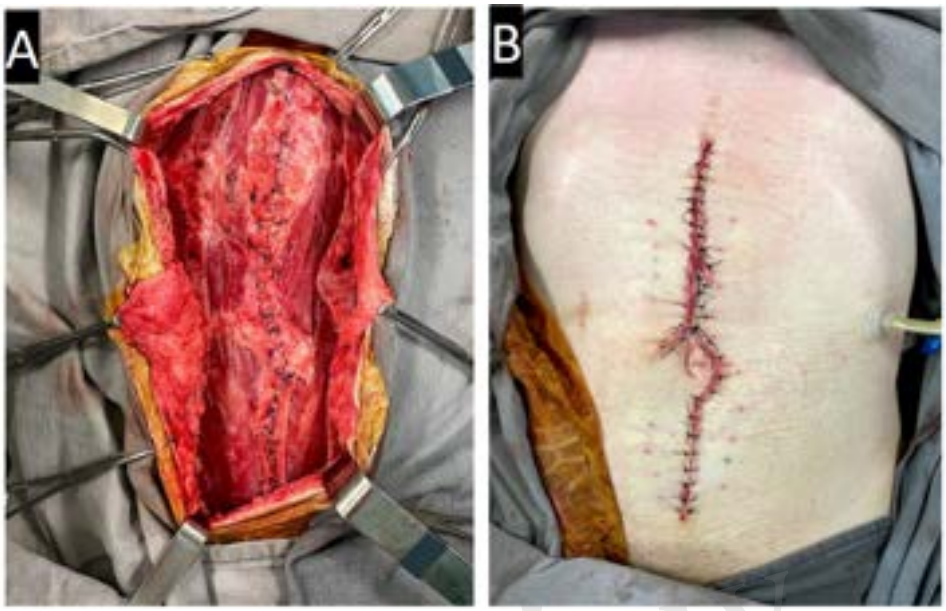

Fig. 3 (a): Full closure of the aponeurotic defect. (b): Full closure of the skin.

During the interval between surgical procedures, motor physical therapy and early ambulation are encouraged. Since the negative pressure device is mobile, the patient can easily move it around with the help of a mobile support, such as an intravenous infusion pump.

In review

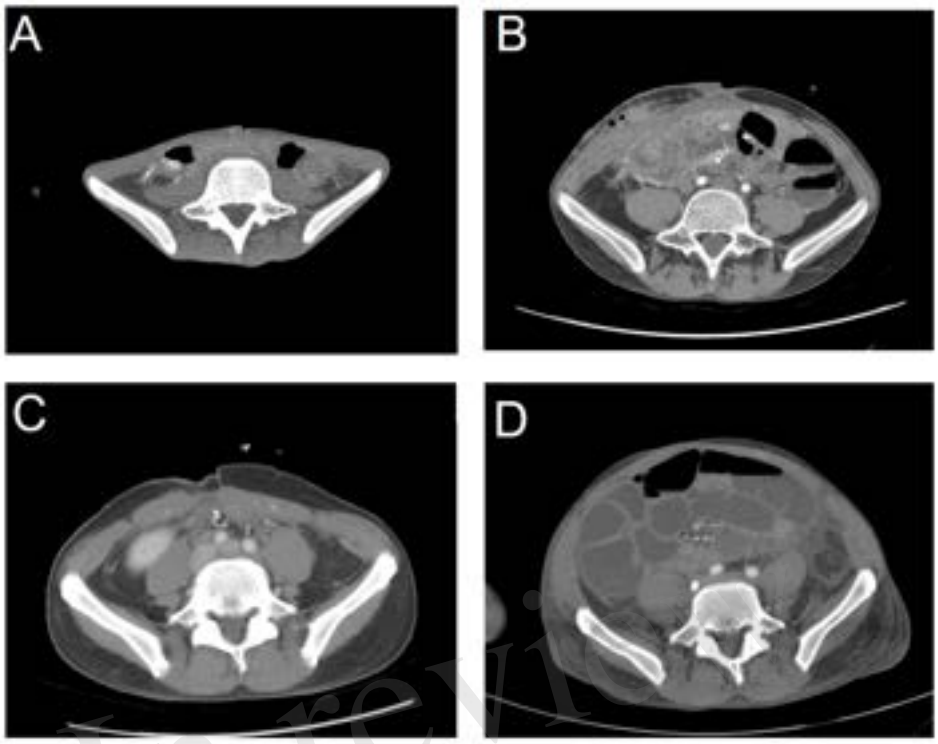

Fig. 4 (a and c): CT before IT. (b and d): CT after IT, showing a significant increase of the abdominal area.

In review