UNIVERSIDADE DE SÃO PAULO
FACULDADE DE ODONTOLOGIA DE BAURU

MICHELLE DE CAMPOS SORIANI AZEVEDO

The role of VIP (*vasoactive intestinal peptide*) and PACAP (*pituitary adenylate cyclase-activating polypeptide*) in M2 polarization and the impact on the alveolar bone healing process

Papel de VIP (*vasoactive intestinal peptide*) e PACAP (*pituitary adenylate cyclase-activating polypeptide*) na polarização M2 e seu impacto no processo de reparo ósseo alveolar

BAURU
2019

MICHELLE DE CAMPOS SORIANI AZEVEDO

The role of VIP (vasoactive intestinal peptide) and PACAP (pituitary adenylate cyclase-activating polypeptide) in M2 polarization and the impact on the alveolar bone healing process

Papel de VIP (vasoactive intestinal peptide) e PACAP (pituitary adenylate cyclase-activating polypeptide) na polarização M2 e seu impacto no processo de reparo ósseo alveolar

Tese constituída por artigos apresentada à Faculdade de Odontologia de Bauru da Universidade de São Paulo para obtenção do título de Doutora em Ciências no Programa de Ciências Odontológicas Aplicadas, na área de concentração Biologia Oral.

Orientador: Prof. Dr. Gustavo Pompermaier Garlet

BAURU

2019

Azevedo, Michelle de Campos Soriani

The role of VIP (vasoactive intestinal peptide) and PACAP (pituitary adenylate cyclase-activating polypeptide) in M2 polarization and the impact on the alveolar bone healing process / Michelle de Campos Soriani Azevedo – Bauru, 2019.
225p. : il. ; 31cm.

Tese (Doutorado) – Faculdade de Odontologia de Bauru. Universidade de São Paulo

Orientador: Prof. Dr. Gustavo Pompermaier Garlet

Comitê de Ética no Ensino e Pesquisa em Animais da FOB-USP
Protocolo nº: 0001/2016
Data: 15/03/2016

ERRATA

FOLHA DE APROVAÇÃO

DEDICATÓRIA

Dedico este trabalho...

À uma menininha de 9 anos, que um dia acordou dizendo que seria “cientista”...

AGRADECIMENTOS ESPECIAIS

Em especial agradeço,

A **Deus**, por se fazer presente em todos os dias de minha vida, e pelas pessoas que tem colocado ao meu lado durante essa caminhada.

Ao meu orientador **Prof. Dr. Gustavo Pompermaier Garlet (Chefe)**, por quem tenho imenso apreço. Agradeço pela confiança depositada em mim antes e durante a execução desse trabalho, pela oportunidade de fazer parte de sua equipe de pesquisa, por toda partilha científica, por sua dedicação e ativa participação em nossos projetos e principalmente por sua amizade. Obrigada por ser meu exemplo, não só como profissional, mas também como pessoa. “Quando crescer, quero ser igual a você...”

À querida **Profa. Dra. Ana Paula Fávaro Trombone Garlet**, por ter me dado a oportunidade de iniciar na pesquisa científica e ter permanecido comigo me auxiliando e ensinando até hoje, e a quem tenho o enorme privilégio de contar com o carinho, amizade e infinita bondade.

Às “meninas osteoimuno” (**Pri, Angel, Andréia, Carol, Jé** e Rafa) e ao **André,** companheiros de laboratório, pelos quais tenho um carinho imenso e sou extremamente grata por toda ajuda e partilha científica durante a execução desse trabalho. Sem vocês tudo teria sido muito mais difícil.

Ao Instituto Lauro de Souza Lima **(ILSL),** por ter sido meu “berço científico” e por manter sempre abertas suas portas, assim como o carinho de todos os seus **funcionários** e **ex-funcionários**, pela partilha e auxílio durante a execução desse trabalho.

Aos meus pais, **José Roberto e Vasni** pela minha vida, por zelar e me ajudar da melhor maneira possível, por estar sempre presente vibrando por cada uma das minhas conquistas. Eu amo vocês!

À minha irmã, **Mariana** por quem tenho o maior amor do mundo. Por ser a materialização do meu desejo de companhia e desde então minha melhor amiga. Agradeço por estar comigo em todos os momentos com sua alegria contagiante e motivação.

Aos **nossos filhotes**, por me proporcionarem momentos de amor e paz, e por fazerem de nossa casa um verdadeiro lar.

Aos meus sogros **Clélio e Ana** e ao meu cunhado **Gú,** a quem sou muito grata pelo auxílio e compreensão.

Aos companheiros de departamento **Rafael, Nádia, Natália, Rodrigo, Paulinha, Suelen, Vinícius, Luan, Ana Carolina, Ever, Danizinha, Ricardo** e **Luciana**, pela convivência diária e pelo crescimento que cada um proporcionou.

Aos **colegas de disciplinas,** pela amizade, troca de conhecimentos e por todo companheirismo durante as aulas.

Às técnicas do laboratório de Histologia, **Tânia, Dani e Paty** pelos serviços prestados.

À **Profa. Dra. Alexandra Ivo de Medeiros**, a aluna **Ana Campos Codo**, e demais alunos e funcionários do Laboratório de Imunologia da Faculdade de Ciências Farmacêuticas da UNESP da Araraquara pelo auxílio com os experimentos.

À nossa secretária **Tê**, por sua eficiência, auxílio, cuidado e carinho com todos.

Aos meus amigos **Pri e Fabinho**, por todos os anos de amizade, por todo apoio, por compartilhar os momentos de dificuldade e principalmente as horas felizes, sempre torcendo por mim.

E principalmente,

Ao meu marido, **Danilo** por quem eu sou completamente apaixonada. Obrigada por estar ao meu lado desde sempre, por seu caráter irretocável, sua bondade e principalmente por seu amor. Obrigada por compartilhar comigo todos os desafios dessa trajetória, por seu apoio, sua compreensão, dedicação e admiração, sem você nada disso teria sido possível. Te amo!

Enfim, todo meu carinho e mais sincera gratidão a todos aqueles que de alguma forma participaram para a conclusão deste sonho...

...Muito obrigada a todos!

AGRADECIMENTOS INSTITUCIONAIS

Ao **Prof. Dr. Vahan Agopyan**, magnífico reitor da Universidade de São Paulo;

Ao **Prof. Dr. Antonio Carlos Hernandes,** excelentíssimo senhor vice-reitor da Universidade de São Paulo;

Ao **Prof. Dr. Pedro Vitoriano de Oliveira**, excelentíssimo Secretário Geral da Universidade de São Paulo;

Ao **Prof. Dr. Carlos Ferreira dos Santos**, senhor diretor da Faculdade de Odontologia de Bauru da Universidade de São Paulo;

Ao **Prof. Dr. Guilherme dos Reis Pereira Janson,** senhor vice-diretor da Faculdade de Odontologia de Bauru da Universidade de São Paulo;

Ao **Prof. Dr. José Henrique Rubo,** excelentíssimo prefeito do Campus da Faculdade de Odontologia de Bauru da Universidade de São Paulo;

Ao **Profa. Dra. Izabel Regina Fischer Rubira de Bullen**, excelentíssima Presidente da Pós-graduação da Faculdade de Odontologia de Bauru da Universidade de São Paulo;

À Fundação de Amparo à Pesquisa do Estado de São Paulo **(FAPESP)** pela bolsa concedida (Processo nº 2015/25618-2) e por todas as oportunidades que me proporcionou.

Ao Programa de Aperfeiçoamento ao Ensino **(PAE)** da Universidade de São Paulo, pelo auxílio e pela oportunidade de integração e troca de conhecimento com os alunos da Disciplina de Histologia II do curso de Odontologia da FOB/USP.

Aos **professores** e **funcionários** da Faculdade de Odontologia de Bauru FOB/USP, por todo ensinamento transmitido e auxílio sempre pronto. Em especial aos professores do Departamento de Histologia, Prof. Dr. Gerson Francisco de Assis, Profa. Dra. Camila Rodini de Oliveira Pegoraro e Prof. Dr. Rumio Taga.

O presente trabalho foi realizado com apoio da Coordenação de Aperfeiçoamento de Pessoal de Nível Superior – Brasil **(CAPES)** – Código de Financiamento 001, nos primeiros 4 meses de execução.

"Talvez não cheguei aonde planejei ir. Mas cheguei, sem querer, aonde meu coração queria chegar, sem que eu o soubesse."

Rubem Alves

RESUMO

RESUMO

Este estudo avaliou o papel de VIP (vasoactive intestinal peptide) e PACAP (pituitary adenylate cyclase activating polypeptide) na modulação da resposte imune e inflamatória associada ao tecido ósseo, utilizando modelos de reparo ósseo alveolar e lesões periapicais em camundongos C57Bl/6. Com relação ao reparo, grupos submetidos à exodontia, mantidos em condições controle ou tratados com VIP, antiVIP, PACAP e antiPACAP, foram avaliados por meio de análises microtomográficas (µCT), histomorfométricas, imunohistoquímicas e moleculares. Os resultados de µCT não demonstram diferença entre os grupos VIP e antiVIP em relação ao controle, enquanto análises histomorfométricas, demonstraram menor densidade de tecido conjuntivo no grupo antiVIP, assim como menor densidade de fibras colágenas e fibroblastos associada a uma maior densidade de matriz óssea e osteoclastos nos grupos VIP e antiVIP; associadas e uma menor contagem de células F4/80+, CD80+, VIP+ e PACAP+, aumento de CD206+, e alterações na expressão de fatores de crescimento, marcadores imunológicos e de reparo tecidual. Nos grupos tratados com PACAP e antiPACAP, a análise por µCT mostrou aumento do volume ósseo para PACAP e na espessura das trabéculas nos grupos PACAP e antiPACAP, enquanto a análise histomorfométrica mostrou aumento de fibras colágenas e diminuição de fibroblastos para o grupo PACAP, assim como diminuição na densidade de osteoblastos e osteoclastos. O grupo antiPACAP mostrou diminuição de osteoblastos e maior concentração de células inflamatórias. A análise imunohistoquímica demonstrou que os grupos PACAP e antiPACAP apresentaram em geral menor contagem de células F4/80+, CD80+, VIP+ e PACAP+ e um aumento na contagem de CD206+, seguido pela expressão alterada de fatores de crescimento, marcadores imunológicos e de reparo. De forma geral, observou-se que a administração de VIP e PACAP resultou em um processo mais rápido do reparo com maior densidade óssea ao final do período, associada a uma polarização preferencial da resposta para o perfil M2. Com relação ao modelo de osteólise inflamatória crônica, camundongos submetidos a indução de lesões periapicais, mantidos em condições controle ou tratados com VIP, foram avaliados por meio de análises histomorfométricas, celulares e moleculares. A expressão de VIP foi maior nos granulomas periapicais, apresentando associação positiva com fatores

imunorreguladores e inversa correlação com mediadores pró-inflamatórios. O tratamento com VIP resultou no controle da lesão, associado a uma resposta anti-inflamatória relacionada a respostas do tipo Th1, Th17 e osteoclastogênica, mostrando-se dependente da migração de Treg e independente de IL-4. Desta forma nossos resultados mostram que VIP e/ou PACAP, estão associados a uma atividade anti-inflamatória e que os tratamentos resultam na atenuação da progressão da lesão e melhoraram o processo de reparo ósseo associados a uma resposta imunossupressora. De forma geral pode-se concluir que neuropeptídios, como VIP e PACAP, apresentam uma ação reguladora da resposta imune e inflamatória associada ao tecido ósseo, e que a magnitude de tal regulação parece ser dependente da natureza do processo inflamatório.

Palavras-chave: VIP. PACAP. TECIDO ÓSSEO. MIGRAÇÃO CELULAR. INFLAMAÇÃO

ABSTRACT

ABSTRACT

The role of VIP (vasoactive intestinal peptide) and PACAP (pituitary adenylate cyclase-activating polypeptide) in M2 polarization and the impact on the alveolar bone healing process

This study evaluated the role of VIP (vasoactive intestinal peptide) and PACAP (pituitary adenylate cyclase activating polypeptide) in modulating immune and inflammatory response associated with bone tissue using alveolar bone repair models and periapical lesions in C57Bl/6 mice. Regarding repair, groups submitted to extraction, maintained under control or treated with VIP, antiVIP, PACAP and antiPACAP were evaluated by microtomography (µCT), histomorphometric, immunohistochemical and molecular analysis. The µCT results showed no difference between VIP and antiVIP groups in relation to control, whereas histomorphometric analyzes showed lower connective tissue density in antiVIP group, as well as lower density of collagen fibers and fibroblasts associated with higher bone matrix and osteoclasts density in the VIP and antiVIP groups; associated with a lower F4/80+, CD80+, VIP+ and PACAP+, increased CD206+ cell count, changing the expression of growth factors, immunological and tissue repair markers. In the PACAP and antiPACAP-treated groups, µCT analysis showed increased bone volume for PACAP and trabecular thickness in the PACAP and antiPACAP groups, while histomorphometric analysis showed increased collagen fibers and fibroblasts and decreased in the density of osteoblasts and osteoclasts in the PACAP group. The antiPACAP group showed decreased osteoblasts and higher concentration of inflammatory cells. Immunohistochemical analysis showed that the PACAP and antiPACAP groups in general had lower F4/80+, CD80+, VIP+ and PACAP+ and an increase in CD206+ cell counts, followed by altered expression of growth factors, immune and repair markers. In general, it was observed that administration of VIP and PACAP resulted in a faster repair process with higher bone density at the end of the period, associated with a preferential polarization of response to the M2 profile. Regarding the chronic inflammatory osteolysis model, mice submitted to induction of periapical lesions, maintained under control conditions or treated with VIP, were evaluated by histomorphometric, cellular and molecular analyzes. VIP expression

was higher in periapical granulomas, presenting a positive association with immunoregulatory factors and inverse correlation with pro-inflammatory mediators. Treatment with VIP resulted in lesion control associated with an anti-inflammatory response related to Th1, Th17 and osteoclastogenic responses, which was dependent on Treg migration and independent of IL-4. Thus our results show that VIP and/or PACAP are associated with anti-inflammatory activity and that treatments result in attenuation of lesion progression and improved bone repair process associated with an immunosuppressive response. In general, it can be concluded that neuropeptides, such as VIP and PACAP, have a regulatory action on immune and inflammatory response associated with bone tissue, and that the magnitude of such regulation seems to be dependent on the nature of the inflammatory process.

Key-words: VIP. PACAP. BONE TISSUE. CELL MOVEMENT. INFLAMMATION**.**

TABLE OF CONTENTS

1 INTRODUCTION

1 INTRODUCTION

The bone tissue is a connective and mineralized tissue that forms the bones. The bones are rigid and resistant structures that form the skeleton, having the functions of support, protection and locomotion, as well reserve of minerals. This tissue is constituted by cells called osteoblasts, osteoclasts and osteocytes, and by the bone matrix, that correspond to the mineralized extracellular material (JUNQUEIRA; CARNEIRO, 2017). Despite its inert aspect, this tissue is an extremely dynamic structure that grows and remains throughout the all life of the organism, having a high capacity for remodeling (DATTA et al., 2008; KATCHBURIAN; ARANA, 2017).

In the oral cavity, the bone tissue plays an important role in the support of the teeth, forming the alveolar processes and the alveolar bone, a dynamic tissue where the fibers of the periodontal ligament are inserted, that quickly responds to stimuli, induces the formation and the tissue resorption (KATCHBURIAN; ARANA, 2017; NANCI, 2013; NEWMAN et al., 2012).

The bone metabolism is maintained under strict control in a process called "coupled bone formation", in which the interaction between biochemical signals generated and transmitted between bone cells interconnects the process of resorption to subsequent bone new formation, allowing the renewal of bone tissue with no functional alterations (BEHL et al., 2008; CHAN; DUQUE, 2002; HOROWITZ et al., 2001; LLOYD et al., 2009; MCCAULEY; NOHUTCU, 2005; ROSCHGER et al., 2008).

Thus, the development, homeostasis and repair capacity of bone tissue depend on the dynamic balance of osteoblast activity and osteoclast reabsorption (KARSENTY; WAGNER, 2002). Due to this remodeling property, the bone tissue exhibits high regeneration capacity when injured. Thus, bone fractures and small defects produced by pathology or trauma, such as tooth extraction, has the ability to repair, with the production of a new bone tissue, with morphofunctional characteristics similar to the original one (Al-AQL et al., 2008; DIMITRIOU; TSIRIDIS; GIANNOUDIS, 2005; PHILLIPS, 2005; TSIRIDIS; UPADHYAY; GIANNOUDIS, 2007).

However, despite such capacity, more extensive defects or associated with certain systemic alterations, present their delayed repair, or even, are not repaired (CORMACK; HAM, 1987). In the oral cavity, the bone changes are highly prevalent, including periodontal and periapical lesions, post-exodontic alterations such as

alveolitis, or even more rare but highly clinically important lesions such as central giant cell lesions, and others (SILVA et al., 2005).

Although these lesions present distinct etiologies, such lesions are characterized by an imbalance of bone homeostasis, which may be due to the influence of microbial, inflammatory, genetic and/or endocrine factors on bone cells (FUKUMOTO; MARTIN, 2009; NICKS et al., 2009). In fact, the control of bone metabolism, in physiological and in response to changes, is influenced by several local and systemic factors, especially the association of the immune with the skeletal systems, called osteoimmunology (BEHL et al., 2008; DATTA et al., 2008; HERMAN; KRÖNKE; SCHETT, 2008; LORENZO; HOROWITZ; CHOI, 2008; RAUNER; SIPOS; PIETSCHMANN, 2007; TAKAYANAGI, 2005, 2007).

The interaction between the immune system and the bones is based on the interference in the bone remodeling process by the mediators, produced by the cells of the immune system: while inflammatory mediators inhibit the activity of osteoblasts and potentiate the activity of osteoclasts, anti-inflammatory mediators have the opposite effect (GARLET et al., 2006, 2007). The best characterized example of such interaction is the production of RANKL (NF-κB activation receptor ligand responsible for the differentiation and activation of osteoclasts through binding to RANK receptor) by activated T lymphocytes, which affect the balance between RANKL and OPG (osteoprotegerin, which as a decoy soluble receptor, inhibits bone resorption by preventing the interaction between RANK and RANKL), usually kept under strict control by osteoblasts. In fact, under physiological conditions, osteoblasts play an important role in the regulation of the RANK/RANKL/OPG system, but the interference of leukocytes and their products on such control can decisively influence tissue homeostasis (GARLET et al., 2006; HERMAN; KRÖNKE; SCHETT, 2008; KATAGIRI; TAKAHASHI, 2002; LORENZO; HOROWITZ; CHOI, 2008; RAUNER; SIPOS; PIETSCHMANN, 2007; TAKAYANAGI, 2007; TEITELBAUM, 2000; WADA et al., 2006).

Despite important advances in the field of osteoimmunology, details of the interaction between the immune and bone systems are still scarce, and the vast majority of studies have focused on the influence of cells and mediators, as well as on role of the immune system in the activation of osteoclasts and in the process of bone resorption, especially in rheumatoid arthritis, myeloma and periodontal disease (ANG et al., 2009; LI et al., 2007; THEILL; BOYLE; PENNINGER, 2002).

A common point within these models is that they do not allow the study of the possible influence of the immune system in subsequent the bone formation, so little is known about possible influences of the interaction between the bone and immune system in the process of bone formation and repair.

It is important to emphasize that even in conditions considered homeostatic, inflammatory mechanisms are extremely relevant in the process of bone repair, participating in the process of angiogenesis, formation and removal of granulation tissue and subsequent formation of bone tissue (CARANO; FILVAROFF, 2003; CARDOSO et al., 2009; KANCZLER; OREFFO, 2008; KANYAMA et al., 2003; POLETI, 2009; RODRIGUES, 2007; WEISS et al., 2009). The use of a mice model in alveolar bone repair after incisor exodontia (VIEIRA et al., 2015) to study of such events, allows the clarification of the mechanisms involved in the regulation of bone tissue during alveolar repair in homeostatic conditions (KORPI et al., 2009; TOMOMATSU et al., 2009).

In mice, the alveolar bone healing process has the same sequence of events previously described in humans and rats (BODNER et al., 1993; CARDOSO, 2009; ELSUBEIHI; HEERSCHE, 2004; POLETI, 2009; RODRIGUES, 2007), presenting only a variation in the chronology of the repair process, characteristic of murine metabolism (BODNER et al., 1993; ELSUBEIHI; HEERSCHE, 2004; KORPI et al., 2009; WITTE; BARBUL, 1997). The alveolar repair process initially depends on the formation of a blood clot within the alveolus, which at the end of the first day is covered by a fibrin network; gradually this clot undergoes invasion of fibroblasts associated with proliferation of endothelial cells, giving rise to new blood vessels that form part of a highly organized granulation tissue, together with fibroblasts in intense proliferation that actively synthesize collagen. In the sequence, osteoblasts found inside the alveolus synthesize an osteoid matrix that mineralizes bone trabeculae. Thus the granulation tissue is gradually replaced by bone tissue and the alveolar repair is completed when the alveolus is thoroughly filled by newly formed bone tissue and the alveolar crest remodeled, providing a dynamic osteoclastic-osteoblastic equilibrium, and the new bone will be able to withstand new stimuli (CARDOSO, 2009; ELSUBEIHI; HEERSCHE, 2004; POLETI, 2009; RODRIGUES, 2007). In humans, this occurs around 210 days after exodontia (CARVALHO; OKAMOTO, 1987), which in the experimental models is equivalent to 28 days in rats and 21 days in mice (BODNER et

al., 1993; CARDOSO, 2009; ELSUBEIHI; HEERSCHE, 2004; POLETI, 2009; RODRIGUES, 2007).

Although the exact mechanisms involved in the bone healing process from the point of view of local immunoregulation are not known yet, tissue repair studies generally point to certain cell types as key components in such a process. Within these cell types, we can highlight the important role of macrophages in bone repair (JANEWAY; MEDZHITOV, 2002; MORRISSETTE; GOLD; ADEREM, 1999).

While classically considered as pro-inflammatory cells, macrophages may present distinct functional phenotypes, termed M1 and M2 (MARTINEZ et al., 2008; MOSSER; EDWARDS, 2008). The original definition of M1 and M2 macrophage is derived from the influence of Th1 and Th2-type cytokines (EDHOLM; RKOO; ROBERT, 2017; MILLS et al., 2000), which results in dichotomous phenotypes of the cytokine-stimulated macrophages. The exposure of macrophages to pro-inflammatory and Th1 stimuli, such as IFN-γ, TNF-α or LPS presence, results in the classic activation, characterized by an inflammatory phenotype and termed M1. The M1 macrophages are characterized by the increased production of MMP9, FGF, IL-8, TNF-α, IL-6, IL-1β and iNOS, and the high expression of CCR7, CD80 and HLADR receptors (MARTINEZ et al., 2008; MOSSER; EDWARDS, 2008).

On the other hand, macrophages can also develop a M2 regulatory and/or repairing phenotype in response to IL-4, in a process called alternative activation, associated with the control of tissue response and repair (MARTINEZ et al., 2008; MOSSER; EDWARDS, 2008; MURRAY; WYNN, 2011; SHI; PAMER, 2011; SICA; MANTOVANI, 2012). The M2 macrophages utilize arginase to convert L-arginine to L-ornithine, a precursor for polyamines and proline components of collagen, an important component in tissue repair (EDHOLM; RKOO; ROBERT, 2017; JETTEN et al., 2014; MILLS, 2001). M2 macrophages are characterized by the high expression of CD163, CD206, MDC, MRC1 receptors and factors such as CCL22, CCL18, IL-10, TGF-β1, PDGF, TIMPs, and Arg-1 and Fizz-1(LISI et al., 2014; MOSSER; EDWARDS, 2008; MURRAY; WYNN, 2011; SANSON; DISTEL; FISHER, 2013; SHI; PAMER, 2011; SICA; MANTOVANI, 2012; SPILLER et al., 2014; ZHOU et al., 2014).

Accordingly, in relation to general tissue repair, studies show that this process involves an initial M1 polarization that typical shift toward a pro-wound healing phenotype M2 (GAFFNEY et al., 2017; SINDRILARU; SCHARFFETTER-KOCHANEK, 2013). While there are few studies specifically focused in bone repair,

considering may directly or indirectly interference of macrophages with differentiation and activity of bone cells (ALEXANDER et al., 2011; GRAVES; COCHRAN, 2003; TAKAYANAGI, 2005, 2007), along bone healing process, the immune response initially results in the production of pro-inflammatory cytokines associated with the predominance of M1 macrophages, followed by the subsequent production of anti-inflammatory factors and the transition to the M2 profile dominance (GAFFNEY et al., 2017). Importantly, M1 to M2 transition have been described as an important component of healing process, also associated with the inflammation resolution at healing sites. Accordingly, a persistent or non-resolving inflammatory response is usually described to impair healing (DE SENY et al., 2016).

The macrophage polarization theoretically occurs in the response site, it is believed that the local microenvironment has a determining role in the polarization of macrophages that migrate to the response sites. Among the factors that could lead to M1 and M2 polarization, the primary obvious target would be IFNγ and IL-4, originally described as inducing such polarization (MOSSER; EDWARDS, 2008; MURRAY; WYNN, 2011; SHI; PAMER, 2011; SICA; MANTOVANI, 2012). However, previous results from our group (VIEIRA et al., 2015), demonstrate that such cytokines expression in the repair sites is low, which can be justified by the preponderantly innate immunity nature of the response, which result in a relative absence of T cells in such sites (MOSSER; EDWARDS, 2008; MURRAY; WYNN, 2011; SHI; PAMER, 2011; SICA; MANTOVANI, 2012; VIEIRA et al., 2015).

Many neurotransmitters, neuropeptides and cytokines produced in parallel by nerve fibers and immune cells have been shown to be potential modulators of immune functions (ABAD; TAN, 2018; WINDING; WILTINK; FOGED, 1997). Among the major mediators, cytokines are not the only peptides capable of promoting or inhibiting immunologic processes. In addition, an increasing number of neuropeptides may be able to modulate the immune system (SAID, 1998). However, some factors may act as local mediators of M2 polarization, including VIP (vasoactive intestinal peptide) and PACAP (pituitary adenylate cyclase-activating polypeptide). In fact, previous studies have demonstrated that VIP, as well as of PACAP, act as macrophages "deactivators" (DELGADO; POZO; GANEA, 2004; GANEA; DELGADO, 2001b; KOFF; DUNEGAN, 1985); considering that such studies were performed prior to the description of the functional subtypes M1 and M2; the characteristics described in the studies for the "deactivating" macrophages are compatible with the conversion of the macrophages

phenotype from M1 to M2 (MARTINEZ; GORDON, 2014). In this context, VIP is a neuropeptide capable of performing a broad spectrum of biological functions, including the modulation of both innate and adaptive immunity, being able to down-regulate pro-inflammatory factors in immune-mediated diseases (GANEA; DELGADO, 2001b; JIANG et al., 2016; VILLANUEVA-ROMERO et al., 2018).

Regarding the focus of this study, VIP is a neuropeptide composed of 28 amino acids, belonging to a family of peptides, of which we can also highlight PACAP, which presents 68% homology with VIP and is presented in two forms, PACAP27 and PACAP38 (dominant) (MUTT, 1988; REFAI et al., 1999; REUBI, 2003; VIRGOLINI et al., 1996). Expressed in the nervous, endocrine and immune systems (including thymocytes, macrophages and lymphocytes), in addition to different somatic tissues (CUTZ et al., 1978; MARTINEZ et al., 1999) VIP and PACAP are capable of influencing the physiological regulation of various systems such as the endocrine and immune system by functions including vasodilation and immunoregulation (GOZES; FURMAN, 2003).

The receptors of VIP are called VPAC1 and VPAC2 (both with high affinity for VIP and PACAP) and in turn PAC1, the PACAP receptor, exhibit selective affinity only for the same (HARMAR et al., 1998, 2004; REUBI, 2003). In most cell types, including osteoblasts, PACAP appears as a more effective stimulator in the formation of cAMP than VIP (LUNDBERG et al., 2001; MUKOHYAMA et al., 2000); and PACAP is able to regulate several physiological processes including cell migration the same way that VIP (COCHAUD et al., 2010).

Even with the large number of cells potentially producing VIP and PACAP, studies related to their function in the bone system are scarce (JONES et al., 2004; JUHÁSZ et al., 2015; NAGATA et al., 2009; PERSSON; LERNER, 2011; SANDOR et al., 2014). The intrinsic activity of VIP occurs in the N-terminal portion and the responsibility for binding the receptors rely on by the C-terminal portion. The elimination of the N-terminal sequence reduces peptide affinity by the receptors and progressively their efficacy, for example, the VIP2-28, VIP3-28 and VIP4-28 fragments are partial agonists with progressive decrease of the intrinsic activity, whereas the fragment VIP10-28 is considered an antagonist (GOURLET et al., 1997). In the case of PACAP, one of the most important PAC1 receptor antagonists is known as PACAP6-38; this fragment does not have the first five amino acids in its N-terminal portion and is also identified as a receptor antagonist (JUHÁSZ et al., 2015).

A common dialogue between nervous, immune, and bone systems, during normal or pathological conditions, produces cytokines capable of broad interaction, promoting cross-talk between common mediators. In this context, PACAP and VIP are highly related neuropeptides; nerve fibers and immune cells present in bone tissue are a source of VIP and PACAP where both are involved the regulation of bone metabolism by local release into tissue (ABAD; TAN, 2018; WINDING; WILTINK; FOGED, 1997). Acting as a potent anti-inflammatory mediator capable of inhibiting the activation of macrophages and T lymphocytes, VIP can also be characterized as a "Th2 profile cytokine" (DELGADO; GANEA, 2001), with the capacity to regulate pro- and anti-inflammatory mediators (GOZES; FURMAN, 2003), as well the expression of costimulatory molecules such as B7-2 (CD86), preferentially modulating the promotion of Th2 type responses (DELGADO; GANEA, 2001; GOMARIZ et al., 2001), promoting the inhibition of osteoclasts; however some studies also describe a more efficient activity of osteoclasts when treated with VIP (RANSJÖ et al., 2000). Activation of VIP receptors expressed on osteoblasts (BJURHOLM et al., 1992; HOHMANN; LEVINE; TASHJIAN, 1983; LUNDBERG et al., 2001) leads to an increased activity and expression of mRNA for ALP, as well as an increased mineralization (LERNER; PERSSON, 2008), promoting the induction of collagen and decreased activity and formation of osteoclasts (DELGADO et al., 2001).

In addition to VIP effects on bone cells function, depending on the activation of osteoclasts and recruitment of progenitor cells (MUKOHYAMA et al., 2000; SUDA; UDAGAWA; N, 2002), VIP plays an important role in the formation and activation of the osteoclasts, being associated with a decrease in mRNA for RANKL, demonstrating not only the ability to inhibit osteoclastogenesis, through the expression of its receptors in stromal cells / osteoblasts, but also through a direct effect on osteoclast progenitor cells (LERNER; PERSSON, 2008). Furthermore, studies have demonstrated a protective effect on experimentally induced bone destruction in arthritis, where the decrease in levels of cytokines such as IL-1, IL-6, IL-11, IL-17 and TNF-α has been observed, and in the proportion of RANKL/OPG, mainly by increasing OPG levels, whereas IL-4 and IL-10 levels were high (LERNER; PERSSON, 2008; WANG et al., 2007). This capacity is due to the inhibitory action in the main signaling cascades, common to the expression of several pro-inflammatory mediators modifying Th responses (ABAD; TAN, 2018), also being able to negatively regulate co-stimulatory signals such as CD80 and CD86 from macrophages in different levels (GANEA;

DELGADO, 2001a) inhibiting phagocytic activity, the production of free radicals, adhesion and migration of macrophages and neutrophils. In this context, VIP is also able to negatively regulate iNOS expression and subsequent release of nitric oxide, and in parallel increasing IL-10 production, and the inhibition of TLRs (GONZALEZ-REY; CHORNY; DELGADO, 2007).

In this context, the identification of the presence of VIP and PACAP in bone repair sites reinforces their potential involvement, acting on the polarization of a pro-wound healing profile or subsidizing the cells polarization in these sites depending on the conditions of repair or illness. It is also important to consider the potential immunoregulatory role of neuropeptides in distinct environments, such as chronic inflammatory osteolytic lesions, such as periapical lesions.

The bacterial infection of the root canal system triggers a complex host inflammatory immune response at periapex, which ultimately determine the outcome of periapical lesions (GRAVES; OATES; GARLET, 2011). Pro-inflammatory mediators and certain helper (Th) subsets, such as Th1 and Th17 cells, can independently or cooperatively mediate the breakdown of soft and mineralized tissues at periapex by locally increasing the proteolytic activity and bone resorption mechanisms, while theoretically limits the local tissue repair (ARAUJO-PIRES et al., 2014a; COLIĆ et al., 2009; GRAVES; OATES; GARLET, 2011). Conversely, immunoregulatory mechanisms, involving mesenchymal stem cells (MSCs), Th2 and Tregs, can be activated throughout lesion development to counteract the pro-inflammatory and tissue destructive pathways, limiting further tissue destruction and even stimulating healing (FRANCISCONI et al., 2016, 2018; GRAVES; OATES; GARLET, 2011). Indeed, both MSCs, Th2 and Tregs are essential elements of immunoregulatory response that naturally takes place in experimental periapical lesions over time, which results in the switch of lesions phenotype into inactive/non-progressive state (FRANCISCONI et al., 2016, 2018; SOUZA-MOREIRA et al., 2011). Importantly, human periapical lesions support the protective role of such cellular subsets at periapex (FRANCISCONI et al., 2016; GANEA; RODRIGUEZ; DELGADO, 2003). However, the factors involved in the activation of MSCs and Tregs, which leads to the switch in the lesion's phenotype, remains unclear.

In this context, VIP (vasoactive intestinal peptide) have been described as a potent immunoregulatory molecule, which can also influence the biology of bone and immune cells (GANEA; RODRIGUEZ; DELGADO, 2003; SOUZA-MOREIRA et al.,

2011), as previously mentioned. However, at this point, it is important to consider that the chronic inflammatory osteolytic milieu that characterizes periapical lesions significantly differ in its nature when compared with the transitory inflammatory infiltrate observed in alveolar bone healing sites. Indeed, while innate immunity elements prevail in bone healing sites, the chronic nature of periapical lesions results in a marked involvement of adaptive immunity in the lesions pathogenesis. Indeed, as previously mentioned, diverse T cell subsets can be present in periapical environment, and the differential Th polarization/commitment can define the outcome of periapical lesions.

In this framework, VIP immunoregulatory properties over leukocytes can exceed the putative targeting of macrophages that allegedly takes place in bone healing sites, since the presence of distinct T helper subsets in periapical lesions results in additional targets to VIP in this environment. Indeed, VIP can inhibit Th1 and Th17 cells while boosting Th2 and Tregs activity (ARAUJO-PIRES et al., 2014b; GANEA; RODRIGUEZ; DELGADO, 2003; ÖZDEMIR et al., 2019; SOUZA-MOREIRA et al., 2011), reinforcing its potential regulatory action in periapical lesions. In periapical lesions context, scarce previous studies describe the expression of VIP in chronic periapical lesions, in levels inversely proportional to lesion size (AZUERO-HOLGUIN et al., 2003; CAVIEDES-BUCHELI et al., 2007). Additionally, intracanal calcium hydroxide resulted in increased VIP levels, suggesting its potential involvement in periapical healing (ÖZDEMIR et al., 2019).

However, the few studies to date only suggest a theoretical immunoregulatory role for VIP in periapical environment, which remains to be confirmed in a cause-and-effect way. Therefore, in this study we investigated the patterns of VIP expression in human and experimental periapical lesions, as well the effect of recombinant VIP therapy in experimental lesions outcome. Additionally, the potential involvement of Th2 and Tregs in the immunoregulatory effects of VIP were investigated.

As this point, we present here three articles on the subject, aiming to determine the role of VIP and PACAP in the M2 polarization and the impact on the subsequent alveolar bone repair process (Articles 1 and 2), as well as verify its expression and the role of VIP in periapical lesions in addition to its potential regulatory role treatment in experimental model (Article 3).

The first article (in preparation), presents the VIP involvement in the alveolar bone healing process.

The second article (in preparation), presents the PACAP involvement in the alveolar bone healing process.

And finally the third article (in press), presents the results of the investigation (in a cause-and-effect manner) the potential involvement of VIP in the development of human and experimental periapical lesions.

2 ARTICLES

2 ARTICLES

The articles presented in this thesis were written according to the instructions and guidelines for article submission of the corresponding journals

- Article 2.1 – VIP modulatory effects in macrophages during the process of alveolar bone healing.

- Article 2.2 – PACAP modulatory capacity during the experimental alveolar bone healing process.

- Article 2.3 – Vasoactive intestinal peptide (VIP) immunoregulatory role at the periapex: associative and mechanistic evidences from human and experimental periapical lesions (in press).

Article 2.1

VIP modulatory effects in macrophages during the process of alveolar bone healing

Michelle de Campos Soriani Azevedo[1]
Angélica Cristina Fonseca[1]
Priscila Maria Colavite[1]
Jéssica Lima Melchiades[1]
André Petenucci Tabanez[1]
Ana Campos Codo[2]
Alexandra Ivo de Medeiros[2]
Ana Paula Favaro Trombone[3]
Gustavo Pompermaier Garlet[1]

1 Department of Biological Sciences, Bauru School of Dentistry, University of São Paulo, Bauru, SP, Brazil
2 Department of Immunology, Universidade Estadual Paulista (UNESP), School of Pharmaceutical Sciences, Araraquara, SP, Brazil
3 Department of Health Science, UNISAGRADO, Bauru, SP, Brazil

Conflicts of interest: The authors deny any conflicts of interest.

***Corresponding author:**
Gustavo Pompermaier Garlet
Bauru School of Dentistry (FOB/USP) - Department of Biological Sciences
Al. Octávio Pinheiro Brisola, 9-75 - CEP 17012-901 – Bauru - SP - Brazil
Phone +55 (14) 3235-8274 - Fax +55 (14) 3223-4679
Email: garletgp@usp.br

ABSTRACT

Host inflammatory immune response have been described as an essential step of bone healing process. In this context, immunoregulatory molecules that consequently modulate inflammatory cell migration, and the subsequent bone repair, have been considered as potential targets for improving bone repair. This study aim evaluate the experimental role of the immunoregulatory molecule VIP (Vasoactive Intestinal Peptide) in the process of alveolar bone healing in C57Bl/6 (WT) mice. Experimental groups, submitted to tooth extraction and maintained under control conditions or treated with VIP and VIP antagonist (GRF 1-29, antiVIP); evaluated by microtomographic (µCT), histomorphometric, immunohistochemical and molecular analysis at 0, 3, 7 and 14 days to quantify tissue repair and host response indicators at the repair site. The µCT results show no significant difference between the VIP and antiVIP groups in relation to hyperdense regions compared to the control group. Histomorphometric analysis showed a faster formation of connective tissue in the treated groups compared to the control, as well as increased bone matrix and osteoclast density in the VIP and antiVIP groups. Inflammatory cell counts/density were higher in the treated groups compared to the control group; immunohistochemical analyzes demonstrate that VIP and antiVIP groups had a lower F4/80+, CD80+, VIP+ and PACAP+ cell count and an increase in CD206+ cells, followed by verification of altered expression of growth factors, bones and immunological markers. Our results, in turn, suggest that the increase of CD206+ in the early periods of the bone repair process modulates the natural course of healing, promoting the decrease in CD80+ cell migration/polarization, and resulting in the increase in the new formed bone observed in VIP and antiVIP groups. The treatments, enhanced the M2 response was able to positively modulate the initial M1 response without eliminating it, which can be observed by bone formation within the alveoli, suggesting compensatory mechanisms, or a change in cell profile, to restore.

Keywords: VIP, Bone healing, M2 macrophages, osteoimmunology

INTRODUCTION

Bone is an extremely dynamic tissue that provides mechanical support, protection and serves as a mineral reservoir. Bone properties are closely related to its high remodeling capacity, which allows its adaptation to mechanical stimuli, mobilization of mineral components and confers to the bone a significant healing capacity, as the result of the cooperative action of bone formative and resorptive cells. Indeed, a dynamic interplay between osteoblasts, osteocytes and osteoclasts is required to maintain bone homeostasis and function. Importantly, bone cells are susceptible to the influence of numerous endocrine and immune systems derived factors, which can influence bone homeostasis and its capacity to respond to injury (1–3).

Regarding the interaction between bone and immune systems, bone healing depends on a transitory inflammatory process, where innate immune system cells allegedly are mobilized to injury site to remove cell or matrix debris and to regulate tissue repair. Although the exact mechanisms involved in the bone healing process from the local immunoregulation viewpoint remains unknown, tissue repair studies generally point to macrophages as key components in such a process (4,5). While classically considered as proinflammatory cells, macrophages may present distinct functional phenotypes, termed M1 and M2 (6,7). The original definition of M1 and M2 macrophage is derived from the effects of prototypic Th1 and Th2 cytokines (8,9) over macrophages. The differentiation that occurs in the presence of IFN-γ, TNF-α or LPS presence, results in an inflammatory phenotype called M1. On the other hand, macrophages can also develop a regulatory and/or repairing phenotype in response to IL-4, called M2, and thus act in the control of tissue response and repair (6,7,10–12). During the healing, M2 macrophages utilize arginase to convert L-arginine to L-ornithine, a precursor components of collagen, also angiogenic and growth factors that are important components in tissue repair (8,13,14).

Interestingly, general tissue repair usually involves an initial M1 polarization that typically shifts toward a pro-wound healing phenotype M2 over time (15,16). While there are few studies specifically focused in the potential role of macrophages subsets in bone repair (17–20) the immune response at bone injury sites initially involves the predominance of proinflammatory cytokines associated with the presence of M1 macrophages, followed by the subsequent production of anti-inflammatory factors and

the transition to an M2 profile dominance (15). Importantly, M1 to M2 transition have been described as an important component of healing process, also associated with the inflammation resolution at healing sites, being a persistent or non-resolving inflammatory response associated with impaired healing (21).

Considering that the macrophage polarization occurs in the response site, the local microenvironment theoretically has a determining role in the polarization of macrophages that migrate to the response sites.

Among the factors that could control M1 and M2 polarization along bone healing, it would be natural to suggest a possible involvement of IFNγ and IL-4, the cytokines originally described as inducers of such polarization (7,10–12). However, we must consider that macrophage polarization occurs in the response site local microenvironment, and previous studies demonstrate that such cytokines expression in the repair sites is low, possibly due the preponderantly innate immunity nature of the response, which result in a relative absence of T cells in such sites(22).

In this context, recent studies have been demonstrated that other molecules are capable of modulating macrophages polarization, such as the VIP-PACAP system. PACAP (pituitary adenylate cyclase activating polypeptide) and VIP (vasoactive intestinal peptide) are described are highly homologous peptides (68% homology), which once produced/released by local innervation or activated immune cells present immunoregulatory properties over multiple cell types, including macrophages and bone cells, via its binding to specific receptors VPAC1 and VPAC2, both with high affinity for VIP and PACAP; and PAC1, an exclusive PACAP receptor (23).

Focusing specifically on VIP, this important neuropeptide is expressed in the nervous and other somatic tissues, and in endocrine and immune systems (24,25), influencing/regulating distinct physiological functions (26). Remarkably, VIP broad spectrum of biological functions includes the modulation of both innate and adaptive immunity, being able to down-regulate pro-inflammatory factors in multiple immune-mediated diseases (27–29). This immunoregulatory capacity is due to the inhibitory actions in signaling cascades involved in the production of several pro-inflammatory mediators and in the development Th responses (30), negatively regulate co-stimulatory signals such as CD80 and CD86 from macrophages in different levels (31).

The presence of nerve fibers immunoreactive for VIP in the bone suggests the involvement of this neuropeptide in the local bone cell metabolism regulation (32). Indeed, VIP affects both osteoblasts and osteoclasts through regulation of cell activity and expression of osteotropic factors, including IL-6 and the RANK/RANKL/OPG system, suggesting that VIP may have a role in bone metabolic processes by acting as a fine tuner of bone cell function through a neuro-osteological interplay (33–36). Additionally, VIP presents the capacity to regulate pro and anti-inflammatory mediators (26) and to increase ALP mRNA expression and activity, and increase mineralization (33), and to decrease osteoclasts formation and activity (31).

In addition, VIP effects on bone cells function, depending on the activation of osteoclasts and recruitment of progenitor cells (37,38), playing an important role in the formation and activation of the osteoclasts, being associated with a decrease in mRNA for RANKL, demonstrating not only the ability to inhibit osteoclastogenesis, through the expression of its receptors in stromal cells/osteoblasts, but also through a direct effect on osteoclast progenitor cells (33). Furthermore, studies have demonstrated a protective effect of VIP in bone associated inflammation (33), where the decrease in levels of cytokines such as IL-1, IL-6, IL-11, IL-17 and TNF-α has been observed such as by increasing OPG levels; whereas IL-4 and IL-10 levels were higher such as the inhibition of TLRs, while in parallel decrease the iNOS expression and subsequent release of nitric oxide (33,39–41).

Therefore, the aim of this study was to determine the role of VIP treatment in mice due to a possible M2 polarization and its impact in the process of alveolar bone healing, as well investigate the potential mechanisms by which this factor exerts this control.

MATERIALS AND METHODS

Animals

The experimental groups consisted of 8-week-old wild type (WT) mice acquired from Ribeirão Preto Medical School (FMR/USP) breeding facility, maintained during the experimental period in the Department of Biological Sciences of FOB/USP facility. During the study period, the mice were fed with standard sterile solid feed of mice (Nuvital, Curitiba, PR, Brazil) and sterile water. The experimental protocol was

approved by the Institutional Committee for Care and Animal Use and by Guide for the Care and Use of Laboratory Animals (CEEPA-FOB/USP, process # 001/2016).

Experimental Protocol and mice tooth extraction model

Male and female (on the same proportion) C57BL/6 wild type (WT) mice, were treated (experimental groups) or not (control group) with VIP (Sigma Aldrich – Catalog number V6130 - 0.05mg/kg IP, 24/24h) or VIP Antagonist-GRF 1-29 (Sigma Aldrich – Catalog number SCP0260; 0.05mg/kg IP, 24/24h), beginning 1 day prior to the upper right incisor extraction and throughout the experimental periods (0, 3, 7 and 14 days post tooth extraction), subsequently, were anesthetized by intramuscular administration of 80mg/kg of ketamine chloride (Dopalen, Agribrans Brasil Ltda) and 160mg/kg of xylazine chloride (Anasedan, Agribrands Brasil Ltda) in the proportion 1:1 according to the animal body mass. In the end of the experimental periods, animals were killed with an excessive dose of anesthetic and the maxillae were collected (N=5 group/time) for microtomographic (µCT), and then prepared for histomorphometry, immunohistochemical and collagen birefringence analysis or submitted to molecular analysis by Real Time PCR Array (N=4 group/time).

Micro-computed tomography (µCT) assessment

The samples were scanned by the Skyscan 1174 System (Skyscan, Kontich, Belgium), at 50 kV, 800 µA, with a 0.5 mm aluminum filter and 15% beam hardening correction, ring artifacts reduction, 180 degrees of rotation and exposure range of 1 degree. Images were captured with 1304 x 1024 pixels and a resolution of 14µm pixel size. Projection images were reconstructed using the NRecon software and three-dimensional images obtained by the CT-Vox software. Morphological parameters of trabecular bone microarchitecture were assessed using the CTAn software in accordance with the recommended guidelines (42). A cylindrical region of interest (ROI) with an axis length of 3 mm and diameter of 1mm was determined by segmenting the trabecular bone located from the coronal to apical thirds. Measurements included the tissue volume (TV), bone volume (BV) bone volume fraction (BV/TV, %), trabecular thickness (Tb.Th, mm), trabecular number (Tb.N, mm), and trabecular separation (Tb.Sp) (22,42–44).

Histomorphometric analysis

Serial sections (8 semi-serial sections of each maxilla, with a 5 µm thickness for each section) were obtained using a microtome (Leica RM2255, Germany) and stained with HE (hematoxylin and eosin). Morphometric measurements were performed by a single calibrated investigator with a binocular light microscope (Olympus Optical Co., Tokyo, Japan) using a 100x immersion objective and a Zeiss kpl 8X eyepiece containing a Zeiss II integration grid (Carl Zeiss Jena GmbH, Jena, Germany) with 10 parallel lines and 100 points in a quadrangular area. The grid image was successively superimposed on approximately 13 histological fields per histological section, comprised of all tooth sockets from the coronal limit adjacent to the gingival epithelium until the lower apical limit. For each animal/socket, sections from the medial were evaluated. In the morphometric analysis, points were counted coinciding with the images of the following components of the alveolar socket: clot, inflammatory cells, blood vessels, fibroblasts, collagen fibers, bone matrix, osteoblasts, osteoclasts and other components (empty space left by extracellular liquid and bone marrow); similar to previous descriptions (22,44–47). The results were presented as the mean of volume density for each evaluated structure.

Collagen birefringence analysis

The Picrosirius-polarization stain method and the quantification of birefringent fibers were performed to assess the structural changes in the newly formed bone trabeculae matrix, based on the birefringence of the collagen fiber bundles as previously described (22,44,48,49). Serial sections (8 semi-serial sections of each maxilla) with 5µm thickness were cut and stained by Picrosirius Red; all sections were stained simultaneously to avoid variations due to possible differences in the staining process. Picrosirius Red-stained sections were analyzed through a polarizing lens coupled to a binocular inverted microscope (Leica DM IRB/E), and all images were captured with the same parameters (the same light intensity and angle of the polarizing lens 90° to the light source). AdobePhotoshopCS6 software was used to delimit the region of interest (alveolar area comprised of new tissue with the external limit comprised of the alveolar wall). The quantification of the intensity of birefringence brightness was performed using the AxioVision4.8 software (CarlZeiss, Oberkochen, Germany). For quantification, the images were binarized for definition of the green, yellow and red color spectra, and the quantity of each color pixels^2 corresponding to the total area

enclosed in the alveoli were measured. Mean values of 4 sections from each animal were calculated in pixels^2.

Immunohistochemistry analysis

Histological sections were deparaffinized following standard procedures. For antigen retrieval, citrate buffer solution was used in a steamer (96/98°C, 30'). After that, the material was incubated with 3% Hydrogen Peroxidase Block (Spring Bioscience Corporation, CA, USA) and subsequently with 7% NFDM to block serum proteins. The histological sections from of all groups were incubated with Ly6g-Gr1 polyclonal antibody - sc-168490 (Santa Cruz Biotechnology, Santa Cruz, CA, USA), F4/80 (A-19) polyclonal antibodies - sc-26642 (Santa Cruz Biotechnology, Santa Cruz, CA, USA), B7-1 CD80 (H-208) monoclonal antibody - sc-9091 (Santa Cruz Biotechnology, Santa Cruz, CA, USA), CD206 (C-20) polyclonal antibody - sc-34577 (Santa Cruz Biotechnology, Santa Cruz, CA, USA), VIP (M19) polyclonal antibody - sc-7841 (Santa Cruz Biotechnology, Santa Cruz, CA, USA), PACAP (C-19) polyclonal antibody - sc-7840 (Santa Cruz Biotechnology, Santa Cruz, CA, USA), CD3-E (M-20) polyclonal antibody (sc-1127) (Santa Cruz Biotechnology, Santa Cruz, CA, USA) at manufacturer's indication concentrations for 1 hour at room temperature. The identification of antigen–antibody reaction was performed using 3-3'-diaminobenzidine (DAB) and counter-staining with Mayer's hematoxylin. Positive controls were assessed in mouse spleen for positive Gr1, F4/80, CD80, CD206, CD3, PACAP and VIP receptors. The analysis of immunolabeled cells was performed by a single calibrated investigator with a binocular light microscope (Olympus Optical Co., Tokyo, Japan) using a 100x immersion objective. The quantitative analysis for the different markers was performed throughout the alveolar extension. The absolute number of immunolabeled cells was obtained to calculate the mean for each section.

Real Time PCR array reactions

Real Time PCR array reactions were performed as previously described (50,51). In short, extraction of total RNA from the remaining alveolus was performed with the RNeasy Plus kit (Qiagen Inc, Valencia, CA) according to the manufacturers' instructions. The integrity of the RNA samples was verified by analyzing 1µl of total RNA in a 2100Bioanalyzer (Agilent Technologies, Santa Clara, CA) according to the

manufacturers' instructions, and the complementary DNA (cDNA) was synthesized using 1mg of RNA through a reverse transcription reaction QuantiTect Rev Transcription kit (Qiagen Inc, Valencia, CA). Real Time PCR array was performed in a Viia7 instrument (Thermo Fisher Scientific, Carlsbad, CA) using a custom panel containing targets "Wound Healing" (PAMM-121), "Inflammatory cytokines and receptors" (PAMM-011) and "Osteogenesis" (PAMM-026) (SABiosciences, Frederick, MD) for gene expression profiling. Real Time PCR array data were analyzed by the RT^2 profiler PCR Array Data Analysis online software (SABiosciences, Frederick, MD) for normalizing the initial geometric mean of three constitutive genes (GAPDH, ACTB, Hprt1) and subsequently normalized by the control group, and expressed as fold change relative to the control group; as previously described (44).

Statistical analysis

Data were presented as means ± SD, initially the data distribution were tested by the Kolmogorov-Smirnov normality test. The statistical significance inside the group was analyzed by Kruskal-Wallis followed by Dunn posttest or by Mann-Whitney test, while the statistical significance between periods was analyzed by Student's t tests. Both were performed with Graph-Pad Prism 7.0 software (GraphPad Software Inc, San Diego, CA). Real Time PCR array data were analyzed by the Mann-Whitney test followed by Benjamini-Hochberg test. Values of $p< 0.05$ were considered statistically significant.

RESULTS

Analysis of bone microarchitecture parameters by micro-computed tomography (µCT)

After the surgeries, maxillae samples from control and experimental groups, were compared based on experimental time (0, 3, 7- and 14-days post-exodontia), using three-dimensional reconstruction by CT-Vox software (Bruker, Billerica, Massachusetts, EUA). In all groups evaluated, it was observed that in the immediate period after extraction the alveolus was completely empty, with absence of hyperdense areas. Corroborating with previous studies based on the microtomographic analysis (45,52), we verified that the alveolar bone repair occurred in a centripetal manner, becoming confluent until filling the entire extension of the alveolus (Figure 1). Three

and seven days after the surgical procedure the presence of discrete regions of bone neoformation close to the cortical bone was observed, following to the central region. At 14 days, a well-evident bone new formation was observed, with a trabeculae formation in the central region, without differences between the groups (Figure 1). The characteristics of bone microarray was performed employing the CTAn software (Bruker, Billerica, Massachusetts, EUA), and the following parameters were considered: bone volume (BV mm^3), tissue volume (TV mm^3), percentage of bone in relation to total tissue volume (BV/TV %), trabeculae thickness (Tb.Th mm), number of trabeculae (Tb.N 1/mm) and separation of trabeculae (Tb.Sp mm) (Figure 2). In the VIP and VIP Antagonist (antiVIP) groups, as well in the control group, was observed that during the periods, there was a progressive increase in bone volume (Figure 2B), percentage of bone in relation to total tissue volume (Figure 2C), trabeculae thickness (Figure 2D) and in the number of trabeculae (Figure 2E) and as expected, it occurred a decrease in the separation of the trabeculae (Figure 2F), following the expected kinetics of the evolution in the process of alveolar bone healing. When the experimental time were compared between to the groups, there was no statistically significant variation in the µCT analysis. Importantly, no significant differences were observed in healing features in males and females, used in equivalent numbers in the experiments (data not shown).

Comparative histomorphometric analysis

Connective tissue, clot and other structures

Based on the histomorphometric analysis, our results corroborate with the microtomographic findings, showing a similar pattern in the bone healing process between the control and the treated groups (Figure 3). On the other hand, when the total area of connective tissue was measured, a significant difference was observed between the control and the antiVIP groups in the 7-days experimental period, showing a little density of connective tissue in the treated group. Regarding the kinetics of the healing, the control and the treated groups showed a progressive increase of the connective tissue starting in 3 to 7 days followed by a decrease in 14 days in the analyzed groups (Figure 4A). Considering the density of the collagen fibers (Figure 4B), the same pattern was observed in the antiVIP treated group, with a significant smaller density of the fibers in the group. About the density of fibroblasts occupied area (Figure 4C), in the control and in the VIP groups were observed an increase in 3 to 7

days, followed by a decrease in 14 days. However, unlike the two other groups, in the group treated with antiVIP the density of fibroblasts was significant decreased in the period of 7 days, being like the control and the VIP groups in relation to the decrease observed at 14 days.

Regarding the blood vessels area density, similar to previous mentioned parameters about the kinetics, the area occupied by blood vessels increased gradually from 3 to 14 days, with a significant difference between the VIP treated group compared to the control group in the 3-days experimental period, being smaller in the treated group (Figure 4D). As regards the area of inflammatory infiltrate, when the control and the VIP groups were compared a little similar kinetics could be observed. In relation to kinetics, was observed in all groups an increase between the periods 0 to 3 days, but in the group that received the antiVIP the density was significant higher in 7 days opposite to what occurs when the control and the VIP treated group was compared. After this initial process, in 14-day period, as was expected, was observed a decrease in the density of inflammatory cells in all analyzed groups (Figure 4E).

Analyzing the blood clot density, was observed that there was no difference between control and the groups that received treatment presenting a similar kinetics in all groups, starting with a peak of blood clot in 0-day followed by an intense decrease (Figure 4F). In relation to the parameter called “other structures”, was not observed differences between the groups. This parameter refers to the empty spaces occupied by interstitial fluid, which gradually decreased over the periods in all groups evaluated, with no significant difference between the groups (Figure 4G).

Bone tissue structures

In this parameter, the bone tissue was represented by bone matrix, osteoblasts and osteoclasts (Figure 5A). In relation to the kinetics, the groups presented the same pattern, with a progressive increase and a higher density in the 14 days period for all evaluated groups with no significant differences between groups. In the individual analysis of the components, was observed that amount of new formed bone matrix was higher in the animals treated with antiVIP when compared to the animals of the control group and treated with VIP in the 7 days period, this result confirms the reason for the decrease in connective tissue observed in the same group in this period. When

the 14-days period was compared a significant increase were observed in the VIP treated group in relation to the control and the antiVIP treated groups (Figure 5B).

Regarding the area density occupied by osteoblasts, there was no significant differences when the groups were compared, however an increase at 7 and 14 days in the group treated with antiVIP was observed in relation to the control and the VIP groups, being smaller in the VIP group (Figure 5C). To conclude the bone elements analysis, we observed that the density of osteoclasts was significant smaller in the antiVIP group when compared to the control group in the period of 7 days and was increased in the antiVIP and VIP groups in the period of 14 days. In its turn, in relation to the kinetics, it was observed an expected increase only in the period of 14 days verified in all the groups, showing the beginning of the tissue remodeling process (Figure 5D).

Collagen birefringence analysis

For birefringence analysis, was verified comparatively the formation and maturation of the collagen matrix in the evaluated groups, through collagen fibers stained by Picrosirius Red and analyzed under polarized (Figure 6A) and non-polarized (Figure 6B) light. In the categorization of color spectra, birefringent fibers within the green color spectrum are related to a less organized and immature matrix. In contrast to these, fibers with a color spectrum varying from yellow to red are related to a matrix with a higher degree of organization and maturation (49,53).

Regarding the quantitative analysis of birefringence of the total area (pixels^2) of the collagen fibers present in the alveoli, was observed that the number of pixels had a progressive increase in relation to the periods in all groups with a significant difference in the periods of 7 and 14 days, respectively when compared the control and VIP-treated group (Figure 6C). Regarding the percentage of pixels representing the birefringent fibers in the green, yellow and red, about the total of quantified pixels in each period, it was observed that the kinetics of the production and maturation of the collagen fibers occurred in a decreasing way for the green fibers and increasing form for the red fibers, the yellow fibers in turn remain in a smaller quantification that follows during all the periods during the course of the repair process being this pattern observed in all the analyzed groups (Figure 6D). Thus, it was observed that the three-

color spectra were arranged to form the bone matrix of the new formed trabeculae in all groups analyzed along the bone repair with no statistical differences.

Immunohistochemistry analysis of Ly6g-Gr1, F4/80$^+$, CD80-B7-1$^+$, CD206$^+$, CD3$^+$, PACAP$^+$ and VIP$^+$ cells

In order to verify the influence of macrophages and another inflammatory cells in the healing site, the immunolabeling was performed to F4/80, CD80 (B7-1), CD206, CD3 and GR1(Ly6g) targets (Figure 7). In addition, VIP and PACAP markers (Figure 8) were included to verify the cell production of these neuropeptides during the healing process, as well to verify the efficiency of the antagonist in the receptors VPAC1 and VPAC2. Analyzing each marker separately, how a marker for undifferentiated macrophages (M0) was used the F4/80 target. For this marker, the number of immunostained cells was in general superior in the control group when compared with treated groups, presenting a significant higher number of stained cells in the period of 7 and 14 days compared with the treated groups (Figure 9A).

Considering CD80$^+$ cells (M1 macrophages), a decreasing number of immunolabelled cells from 3 days in the control group was observed which cannot be observed in the treated groups. In addition, a small number of cells was observed in all periods in relation to the control with significant differences in the period of 3 days to the antiVIP treated group and 3 and 7 days to the VIP treated group. Also, a significant difference between the AntiVIP and the VIP was observed in 3 days, being higher the number of cells stained in the group that received the treatment with VIP (Figure 9B).

For CD206$^+$ immunolabeled cells (M2 macrophages) was observed a progressive increase in control group. In treated groups the number of cells immunostained was higher compared to the control with the highest number verified in the AntiVIP treated group being the increase significant in the periods of 3 and 7 days and in the VIP treated group there was a significant increase in 7 and 14 days in comparison with the control group, in the other hand occurs a decrease in 14 days to both treated groups unlike that observed in the control group (Figure 9C).

For the GR1 target, in the control group the highest number of cells was observed in 3 days gradually decreasing in 7 and 14 days. For the group treated with AntiVIP, no significant differences were observed when compared to the control group, in its turn;

in the VIP-treated group, the number of positive cells was significant higher at 7 days when compared with the control and with the antiVIP-treated group (Figure 9D).

When CD3-labeled cells were analyzed, in the control group the number of labeled cells was similar in all periods being a few greater in 14 days. In the antiVIP-treated group the number of positive cells was lower in the 3 and 7 days, but higher in 14 days when compared with the control group. In the group treated with VIP the kinect was also similar to the control group, but marked cells were more observed at 3 and 14 days in relation to the control group with no significant differences between groups (Figure 9E).

In the cells labeled for VIP, the expression of positive cells was higher in the control group compared to the antiVIP and VIP groups, with a significant higher number of cells immunolabelled in 3 and 7 days (Figure 10A). Due to their homology with VIP, cells labeled for PACAP were also evaluated in this study. For PACAP, the number of positive cells immunolabelled in the control group was significant higher in the period of 3 days when compared to the treated groups, and significant decreased in the 14 days compared to the VIP-treated group. Besides that, there was a significant decrease in the group treated with VIP when compared to antiVIP-treated group (Figure 10B).

Molecular analysis using Real Time PCR Array

The gene expression of several molecules involved in inflammatory response and bone healing, considering growth factors, immunological/inflammatory markers, extracellular matrix and bone markers was investigated employing a pool of samples from 0, 3, 7- and 14-days periods analyzed using Real Time PCR array (Figure 11). Among several growth factors, the expression of BMP7, Fgf2 and TGFβ1 were down regulated in the antiVIP group when compared with the control group, at the same time as the VEGFA expression was down regulated in both the antiVIP group and the VIP-treated group in relation to the control group. Considering the immunological markers analyzed (cytokines, chemokines, chemokine receptors and inflammatory mediators) the expression of IL-1b was down regulated in the VIP group while IL-17, FIZZ, CXCR1, CXCR3, CX3CL1 and CCL20 were up regulated in the same group; in the meantime, the antiVIP-treated group was down regulated to CCL20. In respect to IL-6, TNF, CCR2, CCR5, CCL2, CCL5 and CCL12 both were down regulated to VIP and

antiVIP and up regulated to ARG and IL-10 to the same groups. Subsequently, the extracellular matrix markers, Col1a2, CD34, CD146 and ALP were up regulated in the bone healing process in the antiVIP-treated group; while MMP13 and CTSK were up regulated for both the antiVIP and VIP-treated groups. In the same time, MMP1a and MMP2 were down regulated in the antiVIP and VIP groups. Regarding to MMP8 and MMP13, both were up regulated in VIP-treated group and down regulated to PHEX (a late bone formation marker) to the same group.

DISCUSSION

During the healing process, several orchestrated events contributes to the repair success. Among the main events, the inflammatory immune response depends on interactions between bone, immune and nervous systems, promoting a cascade of common mediators (54). However, the exact role of inflammatory immune response in bone healing and its association with neurotrophic factors is still unclear and most studies have focused on the influence of cells and immunological mediators on osteoclast activation and on the bone resorption process (55,56). In our study, we observed that the VIP administration and inhibition results in a statistically significant increase of newly formed bone and associated with an increase in anti-inflammatory profile along the repair process.

In the view of the unexpected similar outcomes of recombinant VIP administration and VIP receptors (VPAC1 and VPAC2) inhibition, and the predominance of studies based in VIP administration instead of inhibition in the literature, we will initially will discuss how recombinant VIP affects alveolar bone healing outcome. In order to consider the possible sources of VIP interference in bone healing outcome, this discussion will follow the kinetics of bone repair events and its associated readouts/markers investigated in this study.

Considering the bone formation as the main healing readout, μCT demonstrate that were no statistically significant differences between VIP-treated group and the control group in any of the evaluated periods. However, histomorphometric analyzes revealed significant differences in healing parameters. Regarding to the bone tissue

components, the bone matrix and osteoclasts density were significantly increased in VIP group when compared with the control.

It is known that immediately after the exodontia, the first stage of the repair process consists in the formation and subsequent maturation of the blood clot. Such a process initiates a series of cellular and molecular events that gradually result in the establishment of granulation tissue and the inflammatory process, so that the organized clot serves as a provisional framework to the invasion of constitutive cells, leukocytes and formation of new blood capillaries (22,57,58). In respect to the clotting and connective tissue elements, no differences were observed between the VIP and control groups in the histomorphometric analysis. Conversely, birefringence analysis demonstrate a no significant increase in the total pixels in the VIP-treated group in the periods of 7 and 14 days, suggesting an increased collagen fibers density in this group. However, the molecular analysis did not evidenced significant variations in the collagen mRNA levels upon VIP and control group comparison. Interestingly, previous studies suggests that VIP can increase fibroblasts proliferation and collagen I synthesis in the skin (59). Additionally, the histomorphometric analysis demonstrated a decrease in blood vessels in VIP group, which is reinforced by the decreased expression of VEGFA observed in this group. Indeed, previous studies demonstrate that VIP can increase angiogenesis by the upregulation of VEGF (60,61).

Along granulation connective tissue development, its infiltration by different leukocyte subsets supposedly have a significant impact in healing process outcome. In this scenario, it is believed that inflammatory cells such as macrophages, derived from monocytes and recruited to healing sites by chemotactic mechanisms usually at the end of the acute inflammatory phase (62), play a key role in phagocytosis of clot and tissue residues, allowing the filling of the alveoli by a highly vascularized connective tissue that will support the subsequent bone formation (1,63,64).

It is important to consider that the inflammatory response and cell migration in the healing process is described to start as a pro-inflammatory response and replaced by an anti-inflammatory or healing profile over time (15). Accordingly, our results demonstrate that a progressive decrease of CD80+ cells followed by a subsequent increase of CD206+ cells was observed in the control group.

Importantly, it was observed that VIP administration resulted in a reduction of total F4/80+ and CD80+ cell counts and in the increase of CD206+ immunolabelled cells, which in theory characterizes this cells as a dominance of M2-type macrophages over M1 subset in the healing sites. Accordingly, previous studies described the potential VIP modulation for an M2 profile (27,65). Also, the molecular analysis demonstrated a decrease in the expression of CCL2/CCR2 and CCL5/CCR5, characteristically involved in macrophages chemotaxis (66). Additionally, the molecular analysis demonstrated an increased expression of IL-10, FIZZ and ARG and the decrease of IL-6, TNF and IL-1b supports the hypothesis of an increased number of M2 macrophages and an anti-inflammatory profile in the healing site in the VIP-treated group.

At this point, it is mandatory to consider that macrophages are considered one of the major targets for VIP activity, and its modulation in healing sites can directly affect the subsequent release of pro- or anti-inflammatory cytokines and growth factors important to the healing process (22,57,58). Indeed, the M2 phenotype in bone repair has been shown to be responsible for efficiently containing the inflammatory process induced by lesions, improving osteoblastic differentiation and bone regeneration and this modulation and has been explored in the development of osteoimmunomodulator biomaterials taking advantage of these characteristics in the improvement of bone regeneration in chronic inflammatory diseases (67).

Additionally, an increase in GR1 positive cells (7 days) was observed in VIP group. Interestingly, usually an inverse association is described between neutrophils and M2 macrophages, since neutrophils depletion results in increase in M2 macrophages increase and M1 reduction in healing sites, a phenotype associated with increased local fibrosis (68). Also, M2 depletion results in increase in neutrophils and M1 macrophages in scar tissue, and decreased collagen deposition (69). Importantly, while M1-M2 transition is usually described to favor bone healing, the same is true for the initial presence of neutrophils in bone injury sites (70). However, the sustained presence of neutrophils is typically considered a detrimental factor for healing outcome, being associated with exacerbated inflammation and with interferences in bone formation process (44,71). Interestingly, the increased IL-17 expression in VIP treated group may support an increased neutrophil response in this group, and also

can suggest how neutrophils could contribute to a favorable bone healing outcome, since recent studies demonstrate that IL-17 can mediate osteoblastogenesis (72,73).

It is also important to consider that in contrast to these well-defined anti-inflammatory functions, VIP supports the generation and long-term survival of Th2 cells (74), which could justify the increase of CD3 positive cells in the VIP-treated group in the period of 3 days. In this setting, there is increasing evidence that T lymphocytes play a key role in controlling endogenous regeneration, and that factors such effector/regulator and activated/naïve T cell ratios can influence bone healing outcome (75,76).

Additionally, VIP administration resulted in a significant modulation of the expression of other chemokines and their receptors, namely CXCR1, CXCR3, CCL20 and CX3CL1, previously described to play an important hole in the recruitment of inflammatory cells to the inflammation site by chemotaxis and activation of has been implicated in wound healing and interaction between receptors in response to secreted by several cell types (77–81).

Moreover, the VIP administration resulted in a decreased in the MMP1a and MMP2 expression show an important role of MMPs for inflammatory cell migration, degradation and extracellular matrix protein remodeling and angiogenesis processes (82–84) also verified by the decreased density of blood vessels in the VIP-treated group, while the CCL12 expression, associate with a specifically attracts of eosinophils, monocytes and lymphocytes (85), demonstrate a decrease in the treated group and may be a relevant factor in the lower density of VIP and PACAP positive cells. On the other hand, an increased remodeling activity and the higher bone matrix density observed in the treated group, is also supported by MMP8 and MMP13 expression corroborating with previous studies (41).

Based in our data, neuropeptides such as VIP can be added to the list of endogenous molecules that exerts significant immunoregulatory functions in bone healing process. Interestingly, VIP administration seems to result in a local modulation of VIP/PACAP system, since the VIP treatment showed a decrease in the number of VIP (3 and 7 days) and PACAP (3 days) positive cells, and an increase in $PACAP^{+}$ in the 14-days period. Therefore, was effectively compensated for by the increase in PACAP and GR1

positive cells (7 days), however the treatment with VIP did not cause higher VIP expression in the cells, although promoted a more pro-inflammatory profile as an attempt to reverse the initial anti-inflammatory environment suggested by increased CD206+ expression.

Importantly, since VIP is not expressed by osteoblastic cells, suggesting the absence of an autocrine system of VIP in osteoblasts (86), these observations suggest that activities of immune cells presents in healing site are the responsible for VIP expression and its connection to their own receptors in the osteoblasts to regulate bone metabolism. Our data are reinforced by studies that demonstrate that even in conditions of homeostasis, inflammatory mechanisms are extremely important in the bone repair process, participating in the process of angiogenesis, formation and removal of granulation tissue and subsequent formation of bone tissue (63,87–90).

Corroborating with the higher osteoclasts density, the CTSK expression was increased, suggesting the involvement of VIP in bone remodeling, resorption and osteoclastic activity (91,92). Another factor that was considered, was the high expression of Serpine1 in the VIP-treated group, that acts as a regulator of cell migration (93,94) as well in the regulation of odontoblast differentiation (95). Contrary, the significant lower level of PHEX, a protein strongly expressed in osteoblasts in ossification sites (96), could explain the lower density of osteoblasts in the VIP-treated group in the period of 7 days.

At this point, our results suggest that the increase of $CD206^+$ in the early periods of the bone repair process modulates the natural course of healing, promoting the decrease in $CD80^+$ cell migration/polarization, and perhaps increasing GR1 positive cells during the early inflammatory process and promoting the significant increase in the new formed bone observed in the VIP-treated group. Accordingly, literature data that show VIP is able to modulate several types of cells in the most different tissues (26,97).

In the end of the healing process, we observed that the initial pro-inflammatory, or a M1 response, is also necessary for a good progress of the healing process and the changes promoted by VIP-treatment accelerated the repair capacity after 14 days in the VIP-treated group. The treatment-enhanced M2 response was able to positively modulate the initial M1 response without eliminating it, which can be observed by bone

formation within the alveoli, suggesting compensatory mechanisms, or even a change in cell profile, to restore. Additionally, VIP and PACAP exert their anti-inflammatory function in several ways by direct inhibition of pro-inflammatory cytokine production such as TNF, IL-6 and IL-12 by activated macrophages; up-regulation of IL-10 production; inhibition of B7.1/B7.2 expression in activated macrophages; inhibition of IL-2 production and T-cell proliferation and inhibition of Th1 responses (74).

Regarding to the results of antiVIP-treated group, contrary to the general expectation that an antagonist would have an inverse effect of an agonist, the results were quite similar to the VIP-treated group in many aspects. Unpredictably, VIP and VIP antagonist behaved similarly in the bone healing process suggesting that common pathways, probably related to the complexity of VIP/PACAP system receptors. The [Ac-Tyr1,D-Phe2] - GRF 1-29, is widely used as an antagonist of VIP via its receptors, VPAC (98). Several studies have observed the effective potential antagonist action of the compound (99–102). However, as observed in our results, some studies verified that the VIP antagonist effect of GRF 1-29 was not effective (103,104), suggesting a partial inhibition and/or a compensatory mechanism that may be explained by the complexity of the receptors of VIP/PACAP system, which includes that similarity of the receptors pathways. Importantly, the blockade of VPAC1 and VPAC2 by a VIP antagonist does not prevent endogenous PACAP binding at the PAC1 receptor, which is characteristically more efficient in activating bone tissue responses. This fact suggests that similar results observed in both treated groups occur through activation of compensatory mechanisms in the antagonist-treated group (23).

Finally, it is also important to consider that the nature of the local inflammatory environment may directly impact the immunoregulatory properties of VIP. Indeed, the VIP modulating capacity for an M2 profile were observed more clearly in acute inflammatory processes of bone tissue (54,105,106) and cells previously stimulated for an M1 profile (107–109), or even in the dental context in previous studies of our group where the treatment with VIP in periapical lesions was analyzed (110).

To better elucidate our findings, experiments with M0 macrophages differentiated from mouse bone marrow mesenchymal cells showed that alone, both VIP and antiVIP were not able to promote macrophage profile differentiation (data not shown), suggesting that other mechanisms are directly involved in this differentiation so that it can occur

effectively. The confirmation of PAC1 receptor activation as a compensatory mechanism in the bone repair process could be demonstrated in future trials by simultaneous blockade of VPAC1, VPAC2 and PAC1.

CONCLUSION

In conclusion, the present study demonstrated an increase in the bone tissue in the VIP treated group at the endpoint. Our results demonstrate that the early repair observed in the antiVIP and VIP was associated with an increase presence of M2 macrophages and associated labels. Further studies are required to clarify the underlying mechanisms and influence of VIP along bone healing.

CONFLICT OF INTEREST

The authors deny any conflicts of interest related to this study.

ACKNOWLEDGEMENTS

The authors thank Daniele Ceolin, Patricia Germino, and Tania Cestari for their excellent technical assistance. This study was supported by grants and scholarships form FAPESP (15/24637-3, 15/25618-2)

REFERENCES

1. JUNQUEIRA LC, CARNEIRO J. Histologia Básica. 13ª. Rio de Janeiro, Brasil: Guanabara Koogan; 2017. 568 p.
2. Katchburian E, Arana V. Histologia e Embriologia oral. 4ª. Rio de Janeiro, Brasil: Guanabara Koogan; 2017. 298 p.
3. Datta HK, Ng WF, Walker JA, Tuck SP, Varanasi SS. The cell biology of bone metabolism. J Clin Pathol. 2008;61(5):577–87.

4. Janeway CA, Medzhitov R. Innate immune recognition. Annu Rev Immunol [Internet]. 2002;20:197–216. Available from: http://www.ncbi.nlm.nih.gov/pubmed/11861602

5. Morrissette N, Gold E, Aderem A. The macrophage--a cell for all seasons. Trends Cell Biol. 1999 May;9(5):199–201.

6. Martinez FO, Sica A, Mantovani A, Locati M. Macrophage activation and polarization. Front Biosci [Internet]. 2008 Jan 1;13:453–61. Available from: http://www.ncbi.nlm.nih.gov/pubmed/17981560

7. Mosser DM, Edwards JP. Exploring the full spectrum of macrophage activation. Nat Rev Immunol. 2008 Dec;8(12):958–69.

8. Edholm E-S, Rkoo KH, Robert J. Evolutionary Aspects of Macrophages Polarization. Kloc M, editor. Macrophages Origin, Functions and Biointervention. Cham: Springer International Publishing; 2017. 3–22 p. (Results and Problems in Cell Differentiation; vol. 62).

9. Mills CD, Kincaid K, Alt JM, Heilman MJ, Hill AM. M-1/M-2 macrophages and the Th1/Th2 paradigm. J Immunol [Internet]. 2000 Jun 15;164(12):6166–73. Available from: http://www.ncbi.nlm.nih.gov/pubmed/10843666

10. Murray PJ, Wynn TA. Protective and pathogenic functions of macrophage subsets. Nat Rev Immunol [Internet]. 2011 Oct 14;11(11):723–37. Available from: http://www.ncbi.nlm.nih.gov/pubmed/21997792

11. Shi C, Pamer EG. Monocyte recruitment during infection and inflammation. Nat Rev Immunol [Internet]. 2011 Oct 10;11(11):762–74. Available from: http://www.ncbi.nlm.nih.gov/pubmed/21984070

12. Sica A, Mantovani A. Macrophage plasticity and polarization: In vivo veritas. Journal of Clinical Investigation. 2012.

13. Mills CD. Macrophage arginine metabolism to ornithine/urea or nitric oxide/citrulline: a life or death issue. Crit Rev Immunol [Internet]. 2001;21(5):399–425. Available from: http://www.ncbi.nlm.nih.gov/pubmed/11942557

14. Jetten N, Verbruggen S, Gijbels MJ, Post MJ, De Winther MPJ, Donners MMPC. Anti-inflammatory M2, but not pro-inflammatory M1 macrophages promote angiogenesis in vivo. Angiogenesis [Internet]. 2014 Jan 8;17(1):109–18. Available from: http://link.springer.com/10.1007/s10456-013-9381-6

15. Gaffney L, Warren P, Wrona EA, Fisher MB, Freytes DO. Macrophages' Role in Tissue Disease and Regeneration. In: Kloc M, editor. Macrophages Origin, Functions and Biointervention. Cham: Springer International Publishing; 2017. p. 245–71. (Results and Problems in Cell Differentiation; vol. 62).

16. Sindrilaru A, Scharffetter-Kochanek K. Disclosure of the Culprits: Macrophages-Versatile Regulators of Wound Healing. Adv wound care [Internet]. 2013 Sep;2(7):357–68. Available from: http://www.ncbi.nlm.nih.gov/pubmed/24587973

17. Alexander KA, Chang MK, Maylin ER, Kohler T, Müller R, Wu AC, et al. Osteal macrophages promote in vivo intramembranous bone healing in a mouse tibial injury model. J Bone Miner Res [Internet]. 2011 Jul;26(7):1517–32. Available from: http://www.ncbi.nlm.nih.gov/pubmed/21305607

18. Graves DT, Cochran D. The contribution of interleukin-1 and tumor necrosis factor to periodontal tissue destruction. J Periodontol [Internet]. 2003 Mar;74(3):391–401. Available from: http://www.ncbi.nlm.nih.gov/pubmed/12710761

19. Takayanagi H. Inflammatory bone destruction and osteoimmunology. J Periodontal Res. 2005 Aug;40(4):287–93.

20. Takayanagi H. Osteoimmunology: shared mechanisms and crosstalk between the immune and bone systems. Nat Rev Immunol. 2007 Apr;7(4):292–304.

21. de Seny D, Cobraiville G, Leprince P, Fillet M, Collin C, Mathieu M, et al. Biomarkers of inflammation and innate immunity in atrophic nonunion fracture. J Transl Med [Internet]. 2016;14:258. Available from: http://www.ncbi.nlm.nih.gov/pubmed/27599571

22. Vieira AE, Repeke CE, Ferreira Junior S de B, Colavite PM, Biguetti CC, Oliveira RC, et al. Intramembranous bone healing process subsequent to tooth extraction

in mice: micro-computed tomography, histomorphometric and molecular characterization. PLoS One [Internet]. 2015;10(5):e0128021. Available from: http://www.ncbi.nlm.nih.gov/pubmed/26023920

23. Kaiser EA, Russo AF. CGRP and migraine: could PACAP play a role too? Neuropeptides [Internet]. 2013 Dec [cited 2018 Mar 4];47(6):451–61. Available from: http://www.ncbi.nlm.nih.gov/pubmed/24210136

24. Cutz E, Chan W, Track NS, Goth A, Said SI. Release of vasoactive intestinal polypeptide in mast cells by histamine liberators. Nature [Internet]. 1978 Oct 19;275(5681):661–2. Available from: http://www.ncbi.nlm.nih.gov/pubmed/81468

25. Martinez C, Delgado M, Abad C, Gomariz RP, Ganea D, Leceta J. Regulation of VIP production and secretion by murine lymphocytes. J Neuroimmunol [Internet]. 1999 Jan 1;93(1–2):126–38. Available from: http://www.ncbi.nlm.nih.gov/pubmed/10378876

26. Gozes I, Furman S. VIP and drug design. Curr Pharm Des [Internet]. 2003;9(6):483–94. Available from: http://www.ncbi.nlm.nih.gov/pubmed/12570811

27. Ganea D, Delgado M. Inhibitory neuropeptide receptors on macrophages. Microbes Infect [Internet]. 2001 Feb;3(2):141–7. Available from: http://www.ncbi.nlm.nih.gov/pubmed/11251300

28. Jiang W, Wang H, Li Y-S, Luo W. Role of vasoactive intestinal peptide in osteoarthritis. J Biomed Sci [Internet]. 2016 Aug 23;23(1):63. Available from: http://www.ncbi.nlm.nih.gov/pubmed/27553659

29. Villanueva-Romero R, Gutiérrez-Cañas I, Carrión M, Pérez-García S, Seoane I V, Martínez C, et al. The Anti-Inflammatory Mediator, Vasoactive Intestinal Peptide, Modulates the Differentiation and Function of Th Subsets in Rheumatoid Arthritis. J Immunol Res [Internet]. 2018;2018:6043710. Available from: http://www.ncbi.nlm.nih.gov/pubmed/30155495

30. Abad C, Tan Y-V. Immunomodulatory Roles of PACAP and VIP: Lessons from Knockout Mice. J Mol Neurosci [Internet]. 2018 Sep;66(1):102–13. Available

from: http://www.ncbi.nlm.nih.gov/pubmed/30105629

31. Delgado M, Abad C, Martinez C, Leceta J, Gomariz RP. Vasoactive intestinal peptide prevents experimental arthritis by downregulating both autoimmune and inflammatory components of the disease. Nat Med [Internet]. 2001 May;7(5):563–8. Available from: http://www.ncbi.nlm.nih.gov/pubmed/11329057

32. Winding B, Wiltink A, Foged NT. Pituitary adenylyl cyclase-activating polypeptides and vasoactive intestinal peptide inhibit bone resorption by isolated rabbit osteoclasts. Exp Physiol [Internet]. 1997 Sep;82(5):871–86. Available from: http://www.ncbi.nlm.nih.gov/pubmed/9331555

33. Lerner UH, Persson E. Osteotropic effects by the neuropeptides calcitonin gene-related peptide, substance P and vasoactive intestinal peptide. J Musculoskelet Neuronal Interact [Internet]. 2008;8(2):154–65. Available from: http://www.ncbi.nlm.nih.gov/pubmed/18622084

34. Bjurholm A, Kreicbergs A, Schultzberg M, Lerner UH. Neuroendocrine regulation of cyclic AMP formation in osteoblastic cell lines (UMR-106-01, ROS 17/2.8, MC3T3-E1, and Saos-2) and primary bone cells. J Bone Miner Res [Internet]. 1992 Sep;7(9):1011–9. Available from: http://www.ncbi.nlm.nih.gov/pubmed/1384276

35. Hohmann EL, Levine L, Tashjian AH. Vasoactive intestinal peptide stimulates bone resorption via a cyclic adenosine 3’,5’-monophosphate-dependent mechanism. Endocrinology [Internet]. 1983 Apr;112(4):1233–9. Available from: http://www.ncbi.nlm.nih.gov/pubmed/6187560

36. Lundberg P, Lundgren I, Mukohyama H, Lehenkari PP, Horton MA, Lerner UH. Vasoactive intestinal peptide (VIP)/pituitary adenylate cyclase-activating peptide receptor subtypes in mouse calvarial osteoblasts: presence of VIP-2 receptors and differentiation-induced expression of VIP-1 receptors. Endocrinology [Internet]. 2001 Jan;142(1):339–47. Available from: http://www.ncbi.nlm.nih.gov/pubmed/11145597

37. Mukohyama H, Ransjö M, Taniguchi H, Ohyama T, Lerner UH. The inhibitory effects of vasoactive intestinal peptide and pituitary adenylate cyclase-activating

polypeptide on osteoclast formation are associated with upregulation of osteoprotegerin and downregulation of RANKL and RANK. Biochem Biophys Res Commun [Internet]. 2000 Apr 29;271(1):158–63. Available from: http://www.ncbi.nlm.nih.gov/pubmed/10777696

38. Suda T, Udagawa N, N T. Cells of bone: osteoclast generation. In: Bilezikian JP, Raisz LG, Rodan GA, editors. Principles of Bone Biology. 2nd ed. Academic Press; 2002. p. 1696.

39. Wang Y, Mei Y, Bao S, Xu L. Vasoactive intestinal polypeptide enhances oral tolerance by regulating both cellular and humoral immune responses. Clin Exp Immunol [Internet]. 2007 Apr;148(1):178–87. Available from: http://www.ncbi.nlm.nih.gov/pubmed/17349016

40. Gonzalez-Rey E, Chorny A, Delgado M. Regulation of immune tolerance by anti-inflammatory neuropeptides. Nat Rev Immunol [Internet]. 2007 Jan;7(1):52–63. Available from: http://www.ncbi.nlm.nih.gov/pubmed/17186031

41. Liang Y, Chen S, Yang Y, Lan C, Zhang G, Ji Z, et al. Vasoactive intestinal peptide alleviates osteoarthritis effectively via inhibiting NF-κB signaling pathway. J Biomed Sci [Internet]. 2018 Mar 14;25(1):25. Available from: http://www.ncbi.nlm.nih.gov/pubmed/29540226

42. Bouxsein ML, Boyd SK, Christiansen BA, Guldberg RE, Jepsen KJ, Müller R. Guidelines for assessment of bone microstructure in rodents using micro-computed tomography. J Bone Miner Res [Internet]. 2010 Jul;25(7):1468–86. Available from: http://www.ncbi.nlm.nih.gov/pubmed/20533309

43. Kuroshima S, Kovacic BL, Kozloff KM, McCauley LK, Yamashita J. Intra-oral PTH administration promotes tooth extraction socket healing. J Dent Res [Internet]. 2013 Jun;92(6):553–9. Available from: http://www.ncbi.nlm.nih.gov/pubmed/23611925

44. Colavite PM, Vieira AE, Palanch Repeke CE, de Araujo Linhari RP, De Andrade RGCS, Borrego A, et al. Alveolar bone healing in mice genetically selected in the maximum (AIRmax) or minimum (AIRmin) inflammatory reaction. Cytokine [Internet]. 2019 Feb;114:47–60. Available from:

http://www.ncbi.nlm.nih.gov/pubmed/30584949

45. Scala A, Lang NP, Schweikert MT, de Oliveira JA, Rangel-Garcia I, Botticelli D. Sequential healing of open extraction sockets. An experimental study in monkeys. Clin Oral Implants Res [Internet]. 2014 Mar;25(3):288–95. Available from: http://www.ncbi.nlm.nih.gov/pubmed/23551527

46. Rodrigues MTV, Cardoso CL, Carvalho PSP de, Cestari TM, Feres M, Garlet GP, et al. Experimental alveolitis in rats: microbiological, acute phase response and histometric characterization of delayed alveolar healing. J Appl Oral Sci [Internet]. 2011 Jun;19(3):260–8. Available from: http://www.scielo.br/scielo.php?script=sci_arttext&pid=S1678-77572011000300015&lng=en&tlng=en

47. Cardoso CL, Ferreira Júnior O, Carvalho PSP de, Dionísio TJ, Cestari TM, Garlet GP. Experimental dry socket: microscopic and molecular evaluation of two treatment modalities. Acta Cir Bras [Internet]. 2011 Oct;26(5):365–72. Available from: http://www.scielo.br/scielo.php?script=sci_arttext&pid=S0102-86502011000500007&lng=en&tlng=en

48. Bossini PS, Rennó ACM, Ribeiro DA, Fangel R, Ribeiro AC, Lahoz M de A, et al. Low level laser therapy (830nm) improves bone repair in osteoporotic rats: similar outcomes at two different dosages. Exp Gerontol [Internet]. 2012 Feb;47(2):136–42. Available from: http://www.ncbi.nlm.nih.gov/pubmed/22138375

49. Garavello-Freitas I, Baranauskas V, Joazeiro PP, Padovani CR, Dal Pai-Silva M, da Cruz-Höfling MA. Low-power laser irradiation improves histomorphometrical parameters and bone matrix organization during tibia wound healing in rats. J Photochem Photobiol B Biol [Internet]. 2003 May;70(2):81–9. Available from: https://linkinghub.elsevier.com/retrieve/pii/S1011134403000587

50. Araujo LM, Ribeiro OG, Siqueira M, De Franco M, Starobinas N, Massa S, et al. Innate resistance to infection by intracellular bacterial pathogens differs in mice selected for maximal or minimal acute inflammatory response. Eur J Immunol [Internet]. 1998 Sep;28(9):2913–20. Available from:

http://www.ncbi.nlm.nih.gov/pubmed/9754578

51. Glowacki AJ, Gottardi R, Yoshizawa S, Cavalla F, Garlet GP, Sfeir C, et al. Strategies to direct the enrichment, expansion, and recruitment of regulatory cells for the treatment of disease. Ann Biomed Eng [Internet]. 2015 Mar;43(3):593–602. Available from: http://www.ncbi.nlm.nih.gov/pubmed/25245220

52. Einhorn TA, Gerstenfeld LC. Fracture healing: Mechanisms and interventions [Internet]. Vol. 11, Nature Reviews Rheumatology. 2015 [cited 2018 Mar 4]. p. 45–54. Available from: https://www.ncbi.nlm.nih.gov/pmc/articles/PMC4464690/pdf/nihms-697556.pdf

53. Montes GS, Junqueira LCU. The use of the Picrosirius-polarization method for the study of the biopathology of collagen. Mem Inst Oswaldo Cruz [Internet]. 1991;86(suppl 3):1–11. Available from: http://www.scielo.br/scielo.php?script=sci_arttext&pid=S0074-02761991000700002&lng=en&tlng=en

54. Juhász T, Helgadottir SL, Tamás A, Reglődi D, Zákány R. PACAP and VIP signaling in chondrogenesis and osteogenesis. Peptides [Internet]. 2015 Apr;66:51–7. Available from: http://www.ncbi.nlm.nih.gov/pubmed/25701761

55. Araujo-Pires AC, Biguetti CC, Repeke CE, Rodini C de O, Campanelli AP, Trombone APF, et al. Mesenchymal stem cells as active prohealing and immunosuppressive agents in periapical environment: evidence from human and experimental periapical lesions. J Endod [Internet]. 2014 Oct;40(10):1560–5. Available from: http://www.ncbi.nlm.nih.gov/pubmed/25260726

56. Glowacki AJ, Yoshizawa S, Jhunjhunwala S, Vieira AE, Garlet GP, Sfeir C, et al. Prevention of inflammation-mediated bone loss in murine and canine periodontal disease via recruitment of regulatory lymphocytes. Proc Natl Acad Sci U S A [Internet]. 2013 Nov 12;110(46):18525–30. Available from: http://www.ncbi.nlm.nih.gov/pubmed/24167272

57. Nurden A. Platelets, Inflammation And Tissue Regeneration. Thromb Haemost. 2011;105(1):s13-33.

58. Burnouf T, Goubran HA, Chen T-M, Ou K-L, El-Ekiaby M, Radosevic M. Blood-derived biomaterials and platelet growth factors in regenerative medicine. Blood Rev [Internet]. 2013 Mar 1 [cited 2018 Mar 4];27(2):77–89. Available from: http://www.ncbi.nlm.nih.gov/pubmed/23434399

59. Chéret J, Lebonvallet N, Buhé V, Carre JL, Misery L, Le Gall-Ianotto C. Influence of sensory neuropeptides on human cutaneous wound healing process. J Dermatol Sci [Internet]. 2014 Jun;74(3):193–203. Available from: http://www.ncbi.nlm.nih.gov/pubmed/24630238

60. Yang J, Shi Q-D, Song T-B, Feng G-F, Zang W-J, Zong C-H, et al. Vasoactive intestinal peptide increases VEGF expression to promote proliferation of brain vascular endothelial cells via the cAMP/PKA pathway after ischemic insult in vitro. Peptides [Internet]. 2013 Apr;42:105–11. Available from: http://www.ncbi.nlm.nih.gov/pubmed/23340020

61. Yang J, Zong CH, Zhao ZH, Hu XD, Shi QD, Xiao XL, et al. Vasoactive intestinal peptide in rats with focal cerebral ischemia enhances angiogenesis. Neuroscience [Internet]. 2009 Jun 30;161(2):413–21. Available from: http://www.ncbi.nlm.nih.gov/pubmed/19332106

62. Silva TA, Garlet GP, Lara VS, Martins W, Silva JS, Cunha FQ. Differential expression of chemokines and chemokine receptors in inflammatory periapical diseases. Oral Microbiol Immunol [Internet]. 2005 Oct;20(5):310–6. Available from: http://www.ncbi.nlm.nih.gov/pubmed/16101967

63. Cardoso CL. Análise morfométrica e molecular da alveolite induzida em ratos com diferentes modalidades de tratamento. [Bauru]: Universidade de São Paulo; 2009.

64. Poleti ML. Análise morfométrica, radiográfica e molecular do processo de reparo alveolar após a terapia fotodinâmica antimicrobiana em ratos Wistar [Internet]. [Bauru]: Universidade de São Paulo; 2009. Available from: http://www.teses.usp.br/teses/disponiveis/25/25132/tde-03072009-105031/

65. Ganea D, Delgado M. Neuropeptides as modulators of macrophage functions. Regulation of cytokine production and antigen presentation by VIP and PACAP.

Arch Immunol Ther Exp (Warsz) [Internet]. 2001;49(2):101–10. Available from: http://www.ncbi.nlm.nih.gov/pubmed/11348014

66. Palomino DCT, Marti LC. Chemokines and immunity. Einstein (Sao Paulo) [Internet]. 2013;13(3):469–73. Available from: http://www.ncbi.nlm.nih.gov/pubmed/26466066

67. Hu Z, Ma C, Rong X, Zou S, Liu X. Immunomodulatory ECM-like Microspheres for Accelerated Bone Regeneration in Diabetes Mellitus. ACS Appl Mater Interfaces [Internet]. 2018 Jan 24 [cited 2018 Mar 5];10(3):2377–90. Available from: http://www.ncbi.nlm.nih.gov/pubmed/29280610

68. Horckmans M, Ring L, Duchene J, Santovito D, Schloss MJ, Drechsler M, et al. Neutrophils orchestrate post-myocardial infarction healing by polarizing macrophages towards a reparative phenotype. Eur Heart J [Internet]. 2017;38(3):187–97. Available from: http://www.ncbi.nlm.nih.gov/pubmed/28158426

69. Klinkert K, Whelan D, Clover AJP, Leblond A-L, Kumar AHS, Caplice NM. Selective M2 Macrophage Depletion Leads to Prolonged Inflammation in Surgical Wounds. Eur Surg Res [Internet]. 2017;58(3–4):109–20. Available from: http://www.ncbi.nlm.nih.gov/pubmed/28056458

70. Kovtun A, Bergdolt S, Wiegner R, Radermacher P, Huber-Lang M, Ignatius A. The crucial role of neutrophil granulocytes in bone fracture healing. Eur Cell Mater [Internet]. 2016;32:152–62. Available from: http://www.ncbi.nlm.nih.gov/pubmed/27452963

71. Bastian OW, Croes M, Alblas J, Koenderman L, Leenen LPH, Blokhuis TJ. Neutrophils Inhibit Synthesis of Mineralized Extracellular Matrix by Human Bone Marrow-Derived Stromal Cells In Vitro. Front Immunol [Internet]. 2018;9:945. Available from: http://www.ncbi.nlm.nih.gov/pubmed/29765377

72. Croes M, Öner FC, van Neerven D, Sabir E, Kruyt MC, Blokhuis TJ, et al. Proinflammatory T cells and IL-17 stimulate osteoblast differentiation. Bone [Internet]. 2016 Mar;84:262–70. Available from: http://www.ncbi.nlm.nih.gov/pubmed/26780388

73. Wang Y, Kim J, Chan A, Whyne C, Nam D. A two phase regulation of bone regeneration: IL-17F mediates osteoblastogenesis via C/EBP-β in vitro. Bone [Internet]. 2018;116:47–57. Available from: http://www.ncbi.nlm.nih.gov/pubmed/30010083

74. Ganea D, Delgado M. Vasoactive intestinal peptide (VIP) and pituitary adenylate cyclase-activating polypeptide (PACAP) as modulators of both innate and adaptive immunity. Crit Rev Oral Biol Med [Internet]. 2002;13(3):229–37. Available from: http://www.ncbi.nlm.nih.gov/pubmed/12090463

75. Bucher CH, Schlundt C, Wulsten D, Sass FA, Wendler S, Ellinghaus A, et al. Experience in the Adaptive Immunity Impacts Bone Homeostasis, Remodeling, and Healing. Front Immunol [Internet]. 2019;10:797. Available from: http://www.ncbi.nlm.nih.gov/pubmed/31031773

76. Schlundt C, Reinke S, Geissler S, Bucher CH, Giannini C, Märdian S, et al. Individual Effector/Regulator T Cell Ratios Impact Bone Regeneration. Front Immunol [Internet]. 2019;10:1954. Available from: http://www.ncbi.nlm.nih.gov/pubmed/31475013

77. Zlotnik A, Yoshie O. The chemokine superfamily revisited. Immunity [Internet]. 2012 May 25;36(5):705–16. Available from: http://www.ncbi.nlm.nih.gov/pubmed/22633458

78. Luster AD, Unkeless JC, Ravetch J V. Gamma-interferon transcriptionally regulates an early-response gene containing homology to platelet proteins. Nature [Internet]. 1985;315(6021):672–6. Available from: http://www.ncbi.nlm.nih.gov/pubmed/3925348

79. Dufour JH, Dziejman M, Liu MT, Leung JH, Lane TE, Luster AD. IFN-gamma-inducible protein 10 (IP-10; CXCL10)-deficient mice reveal a role for IP-10 in effector T cell generation and trafficking. J Immunol [Internet]. 2002 Apr 1;168(7):3195–204. Available from: http://www.ncbi.nlm.nih.gov/pubmed/11907072

80. Angiolillo AL, Sgadari C, Taub DD, Liao F, Farber JM, Maheshwari S, et al. Human interferon-inducible protein 10 is a potent inhibitor of angiogenesis in

vivo. J Exp Med [Internet]. 1995 Jul 1;182(1):155–62. Available from: http://www.ncbi.nlm.nih.gov/pubmed/7540647

81. Booth V, Keizer DW, Kamphuis MB, Clark-Lewis I, Sykes BD. The CXCR3 binding chemokine IP-10/CXCL10: structure and receptor interactions. Biochemistry [Internet]. 2002 Aug 20;41(33):10418–25. Available from: http://www.ncbi.nlm.nih.gov/pubmed/12173928

82. Hankenson KD, Dishowitz M, Gray C, Schenker M. Angiogenesis in bone regeneration. Injury [Internet]. 2011 Jun;42(6):556–61. Available from: http://www.ncbi.nlm.nih.gov/pubmed/21489534

83. Vu TH, Werb Z. Matrix metalloproteinases: effectors of development and normal physiology. Genes Dev [Internet]. 2000 Sep 1;14(17):2123–33. Available from: http://www.ncbi.nlm.nih.gov/pubmed/10970876

84. Page-McCaw A, Ewald AJ, Werb Z. Matrix metalloproteinases and the regulation of tissue remodelling. Nat Rev Mol Cell Biol [Internet]. 2007 Mar;8(3):221–33. Available from: http://www.ncbi.nlm.nih.gov/pubmed/17318226

85. Jia GQ, Gonzalo JA, Lloyd C, Kremer L, Lu L, Martinez-A C, et al. Distinct expression and function of the novel mouse chemokine monocyte chemotactic protein-5 in lung allergic inflammation. J Exp Med [Internet]. 1996 Nov 1;184(5):1939–51. Available from: http://www.ncbi.nlm.nih.gov/pubmed/8920881

86. Togari A, Arai M, Mizutani S, Mizutani S, Koshihara Y, Nagatsu T. Expression of mRNAs for neuropeptide receptors and beta-adrenergic receptors in human osteoblasts and human osteogenic sarcoma cells. Neurosci Lett [Internet]. 1997 Sep 19;233(2–3):125–8. Available from: http://www.ncbi.nlm.nih.gov/pubmed/9350848

87. Carano RAD, Filvaroff EH. Angiogenesis and bone repair. Drug Discov Today. 2003 Nov 1;8(21):980–9.

88. Kanczler JM, Oreffo ROC. Osteogenesis and angiogenesis: the potential for engineering bone. Eur Cell Mater [Internet]. 2008 May 2;15:100–14. Available from: http://www.ncbi.nlm.nih.gov/pubmed/18454418

89. Kanyama M, Kuboki T, Akiyama K, Nawachi K, Miyauchi FM, Yatani H, et al. Connective tissue growth factor expressed in rat alveolar bone regeneration sites after tooth extraction. Arch Oral Biol. 2003 Oct;48(10):723–30.

90. Weiss S, Zimmermann G, Pufe T, Varoga D, Henle P. The systemic angiogenic response during bone healing. Arch Orthop Trauma Surg [Internet]. 2009 Jul;129(7):989–97. Available from: http://www.ncbi.nlm.nih.gov/pubmed/19037648

91. Dai J, Rabie ABM. VEGF: an essential mediator of both angiogenesis and endochondral ossification. J Dent Res [Internet]. 2007 Oct;86(10):937–50. Available from: http://www.ncbi.nlm.nih.gov/pubmed/17890669

92. Liu W, Zhang X. Receptor activator of nuclear factor-κB ligand (RANKL)/RANK/osteoprotegerin system in bone and other tissues (review). Mol Med Rep [Internet]. 2015 May;11(5):3212–8. Available from: http://www.ncbi.nlm.nih.gov/pubmed/25572286

93. Degryse B, Neels JG, Czekay R-P, Aertgeerts K, Kamikubo Y-I, Loskutoff DJ. The low density lipoprotein receptor-related protein is a motogenic receptor for plasminogen activator inhibitor-1. J Biol Chem [Internet]. 2004 May 21;279(21):22595–604. Available from: http://www.ncbi.nlm.nih.gov/pubmed/15001579

94. Kjøller L, Kanse SM, Kirkegaard T, Rodenburg KW, Rønne E, Goodman SL, et al. Plasminogen activator inhibitor-1 represses integrin- and vitronectin-mediated cell migration independently of its function as an inhibitor of plasminogen activation. Exp Cell Res [Internet]. 1997 May 1;232(2):420–9. Available from: http://www.ncbi.nlm.nih.gov/pubmed/9168821

95. Jin B, Choung P-H. Recombinant Human Plasminogen Activator Inhibitor-1 Accelerates Odontoblastic Differentiation of Human Stem Cells from Apical Papilla. Tissue Eng Part A [Internet]. 2016;22(9–10):721–32. Available from: http://www.ncbi.nlm.nih.gov/pubmed/27046084

96. Thompson DL, Sabbagh Y, Tenenhouse HS, Roche PC, Drezner MK, Salisbury JL, et al. Ontogeny of Phex/PHEX protein expression in mouse embryo and

subcellular localization in osteoblasts. J Bone Miner Res [Internet]. 2002 Feb;17(2):311–20. Available from: http://www.ncbi.nlm.nih.gov/pubmed/11811562

97. Cochaud S, Chevrier L, Meunier A-C, Brillet T, Chadéneau C, Muller J-M. The vasoactive intestinal peptide-receptor system is involved in human glioblastoma cell migration. Neuropeptides [Internet]. 2010 Oct;44(5):373–83. Available from: http://www.ncbi.nlm.nih.gov/pubmed/20638719

98. Waelbroeck M, Robberecht P, Coy DH, Camus JC, De Neef P, Christophe J. Interaction of growth hormone-releasing factor (GRF) and 14 GRF analogs with vasoactive intestinal peptide (VIP) receptors of rat pancreas. Discovery of (N-Ac-Tyr1,D-Phe2)-GRF(1-29)-NH2 as a VIP antagonist. Endocrinology [Internet]. 1985 Jun;116(6):2643–9. Available from: http://www.ncbi.nlm.nih.gov/pubmed/2859987

99. Blank MA, Kimura K, Fuortes M, Jaffe BM. VIP antagonist [N-Ac-Tyr1,D-Phe2]-GRF-(1-29)-NH2: an inhibitor of vasodilation in the feline colon. Am J Physiol [Internet]. 1990 Aug;259(2 Pt 1):G252-7. Available from: http://www.ncbi.nlm.nih.gov/pubmed/2116730

100. Liu DM, Cuevas J, Adams DJ. VIP and PACAP potentiation of nicotinic ACh-evoked currents in rat parasympathetic neurons is mediated by G-protein activation. Eur J Neurosci [Internet]. 2000 Jul;12(7):2243–51. Available from: http://www.ncbi.nlm.nih.gov/pubmed/10947803

101. Itri J, Colwell CS. Regulation of inhibitory synaptic transmission by vasoactive intestinal peptide (VIP) in the mouse suprachiasmatic nucleus. J Neurophysiol [Internet]. 2003 Sep;90(3):1589–97. Available from: http://www.ncbi.nlm.nih.gov/pubmed/12966176

102. Yang K, Trepanier CH, Li H, Beazely MA, Lerner EA, Jackson MF, et al. Vasoactive intestinal peptide acts via multiple signal pathways to regulate hippocampal NMDA receptors and synaptic transmission. Hippocampus [Internet]. 2009 Sep;19(9):779–89. Available from: http://www.ncbi.nlm.nih.gov/pubmed/19173226

103. Corbitt J, Hagerty T, Fernandez E, Morgan WW, Strong R. Transcriptional and post-transcriptional regulation of tyrosine hydroxylase messenger RNA in PC12 cells during persistent stimulation by VIP and PACAP38: differential regulation by protein kinase A and protein kinase C-dependent pathways. Neuropeptides [Internet]. 2002 Feb;36(1):34–45. Available from: http://www.ncbi.nlm.nih.gov/pubmed/12147212

104. Michalkiewicz M, Huffman LJ, Hedge GA. Lack of effect of vasoactive intestinal peptide antagonists on blood flow in the rat thyroid. Peptides [Internet]. 1991;12(6):1181–6. Available from: http://www.ncbi.nlm.nih.gov/pubmed/1815206

105. Nagata A, Tanaka T, Minezawa A, Poyurovsky M, Mayama T, Suzuki S, et al. cAMP activation by PACAP/VIP stimulates IL-6 release and inhibits osteoblastic differentiation through VPAC2 receptor in osteoblastic MC3T3 cells. J Cell Physiol [Internet]. 2009 Oct;221(1):75–83. Available from: http://www.ncbi.nlm.nih.gov/pubmed/19496170

106. Persson E, Lerner UH. The neuropeptide VIP regulates the expression of osteoclastogenic factors in osteoblasts. J Cell Biochem [Internet]. 2011 Dec;112(12):3732–41. Available from: http://www.ncbi.nlm.nih.gov/pubmed/21815197

107. Larocca L, Calafat M, Roca V, Franchi AM, Leirós CP. VIP limits LPS-induced nitric oxide production through IL-10 in NOD mice macrophages. Int Immunopharmacol [Internet]. 2007 Oct;7(10):1343–9. Available from: http://www.ncbi.nlm.nih.gov/pubmed/17673149

108. Delgado M, Munoz-Elias EJ, Gomariz RP, Ganea D. VIP and PACAP inhibit IL-12 production in LPS-stimulated macrophages. Subsequent effect on IFNgamma synthesis by T cells. J Neuroimmunol [Internet]. 1999 May 3;96(2):167–81. Available from: http://www.ncbi.nlm.nih.gov/pubmed/10337915

109. Ran W-Z, Dong L, Tang C-Y, Zhou Y, Sun G-Y, Liu T, et al. Vasoactive intestinal peptide suppresses macrophage-mediated inflammation by downregulating interleukin-17A expression via PKA- and PKC-dependent pathways. Int J Exp Pathol [Internet]. 2015 Aug;96(4):269–75. Available from:

http://www.ncbi.nlm.nih.gov/pubmed/25944684

110. Azevedo M de CS, Garlet TP, Francisconi CF, Colavite PM, Tabanez AP, Melchiades JL, et al. Vasoactive Intestinal Peptide Immunoregulatory Role at the Periapex: Associative and Mechanistic Evidences from Human and Experimental Periapical Lesions. J Endod [Internet]. 2019 Aug 8; Available from: http://www.ncbi.nlm.nih.gov/pubmed/31402064

FIGURES AND LEGENDS

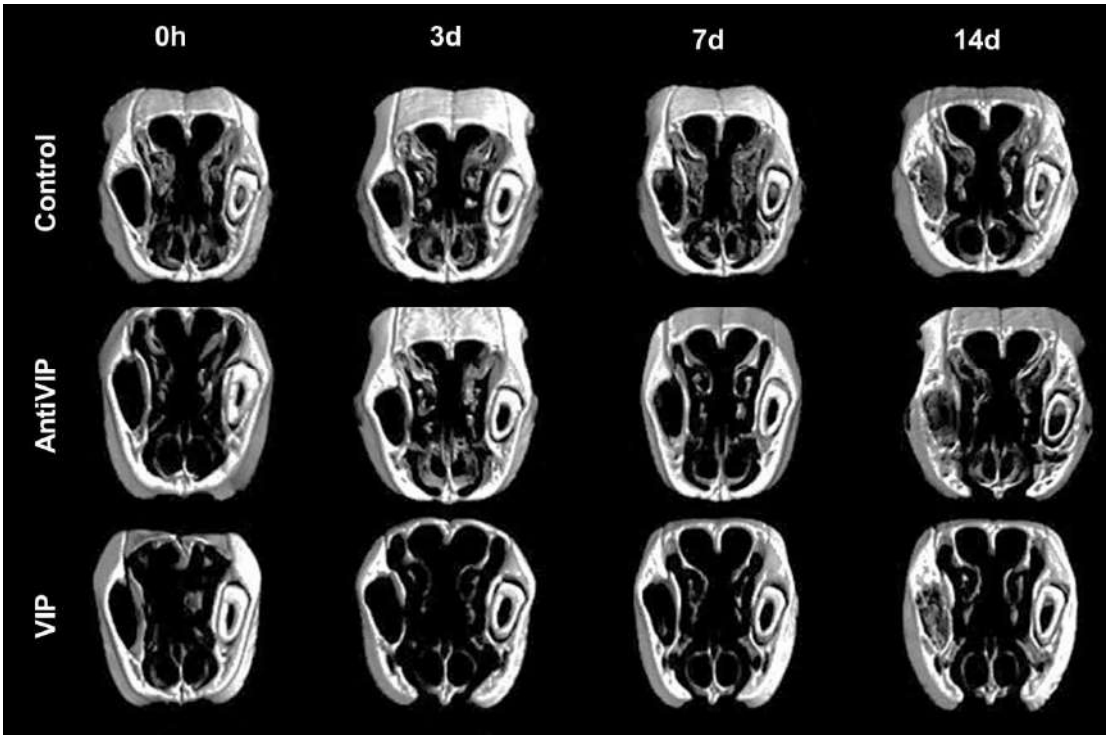

Figure 1. Three-dimensional morphological analysis by µCT of the alveolar bone healing process in mice control and treated with VIP antagonist and VIP in the periods 0, 3, 7- and 14-days post-exodontia. The images were reconstructed using the NRecon Reconstruction software and three-dimensional images obtained by the CTvox software. The maxillae were sectioned in the transversal plane.

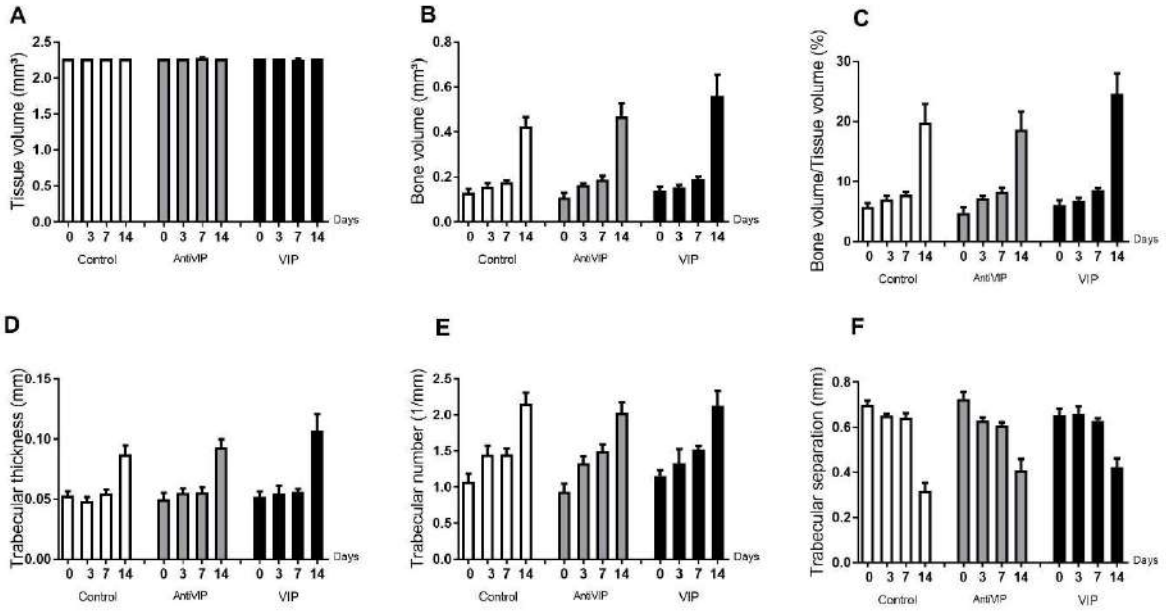

Figure 2. **Analysis of the morphological parameters of the trabecular bone microarchitecture in the dental alveoli of the control mice and treated with VIP Antagonist and VIP in the periods of 0, 3, 7- and 14-days post-exodontia.** The morphological parameters of the bone microarchitecture were evaluated using the CTAn software through a cylindrical region of interest (ROI) determined by the segmentation of the trabecular bone located from the coronal to the apical region. The analysis of bone parameters (A-F) included: Tissue volume (mm3) (A), Bone volume (mm3) (B), Bone volume in relation to tissue volume (%) (C), Trabeculae thickness (mm) (D), Number of trabeculae (1/mm) (E), Separation of trabeculae (mm) (F). The results represent the values of the mean and standard deviation in each of the periods analyzed.

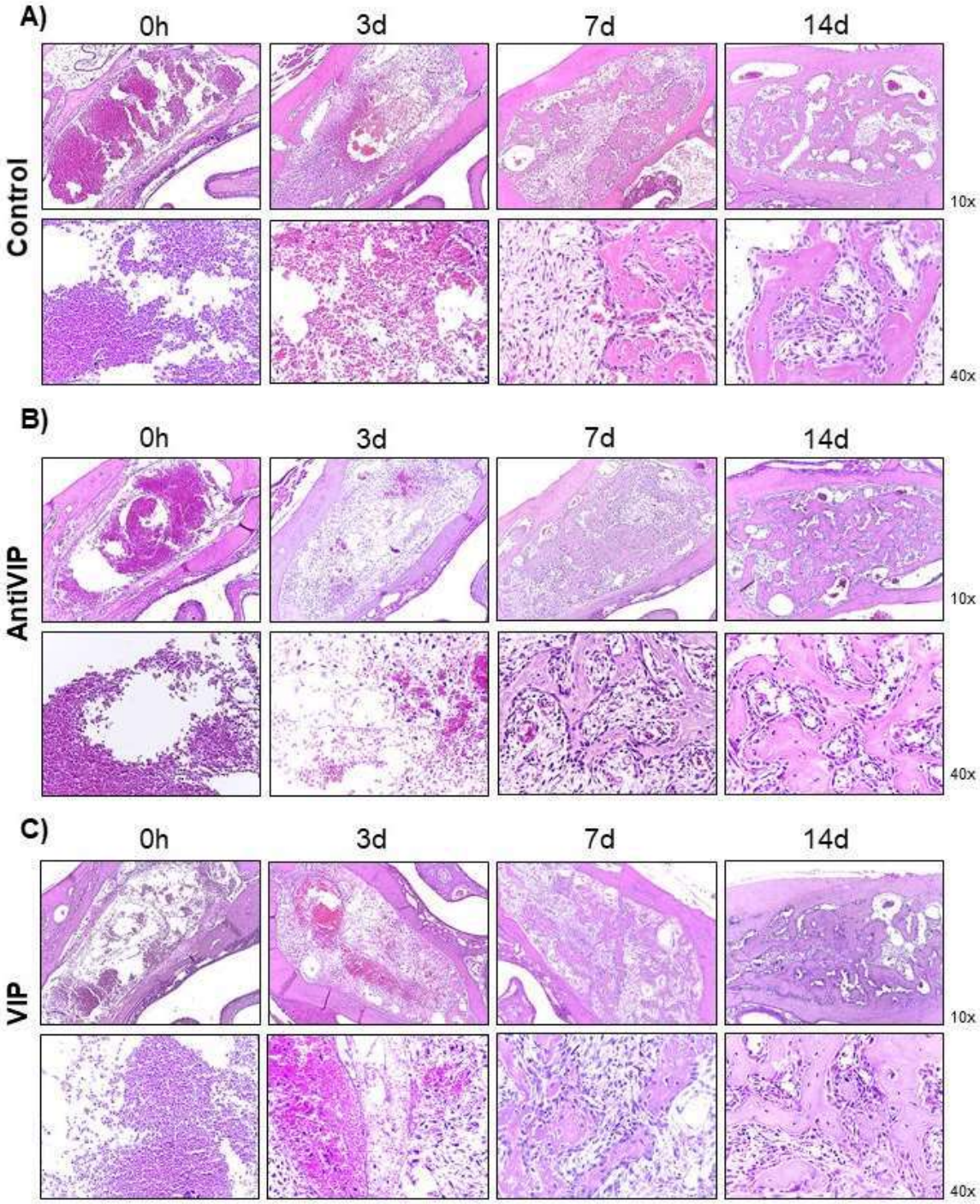

Figure 3. Histological analysis of the alveolar healing process in control mice (A) treated with VIP antagonist (B) and VIP (C), in periods of 0, 3, 7- and 14-days post-exodontia. Photomicrographs representing the average region of the dental alveolus in 10x and 40x magnification; histological sections obtained after 0, 3, 7 and 14 days after exodontia. HE stain.

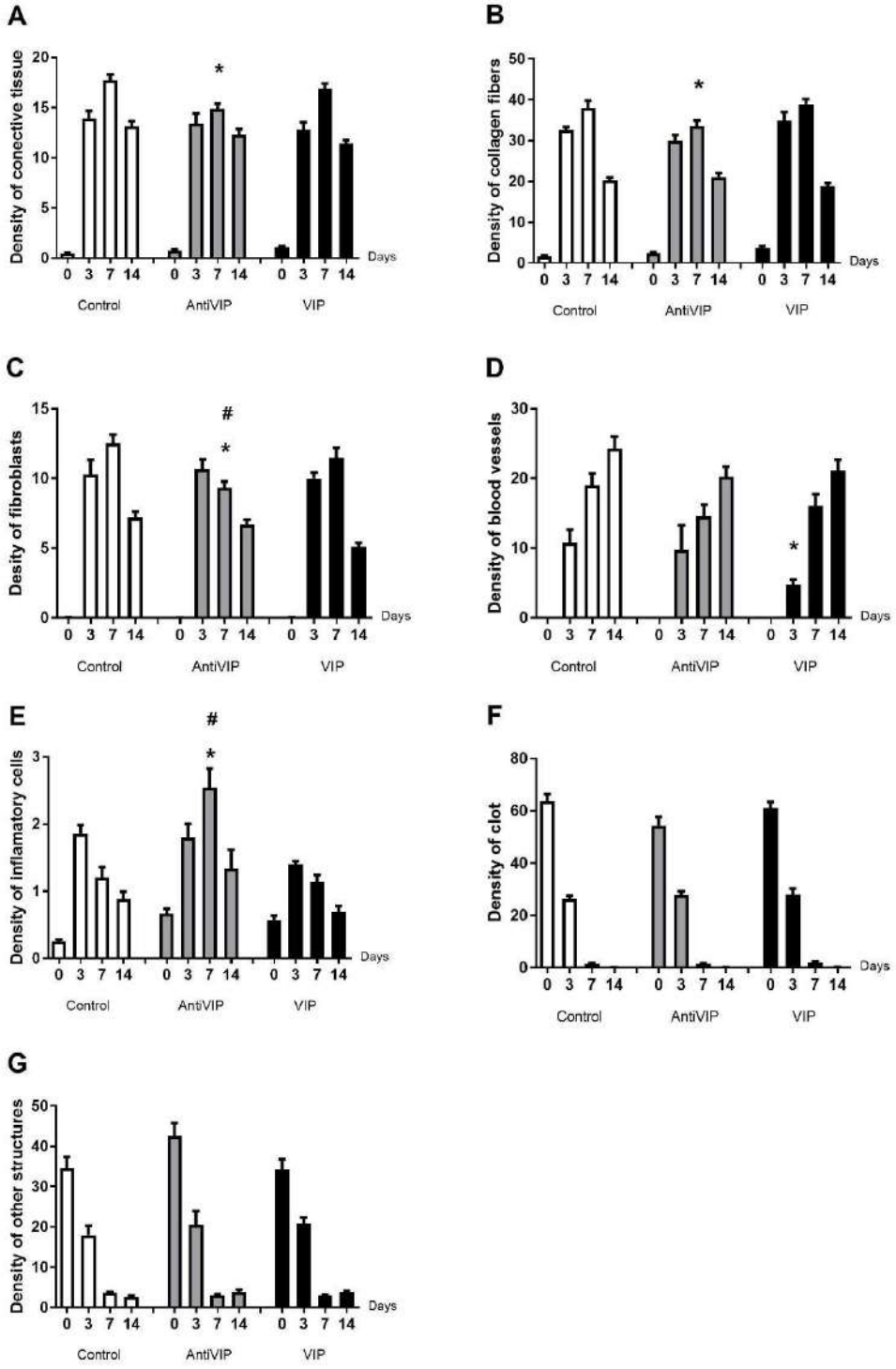

Figure 4. Comparative density analysis (%) of connective tissue (A) and its components (B-G) present in the dental alveolus of control mice and treated with VIP and VIP antagonist in periods of 0, 3, 7- and 14-days post-exodontia. Results are presented as the means of density for each structure of the alveolar socket: collagen fibers, fibroblasts, blood vessels, inflammatory cells, clot and other components (empty space left by intercellular liquid and spaces). Also, the results depict the total density of connective tissue (represented by the sum of collagen fibers, fibroblasts, blood vessels and inflammatory cells). The results represent the values of the mean and standard deviation in each of the periods analyzed (*represent the differences between the control group; #represent the difference between VIP and antiVIP group).

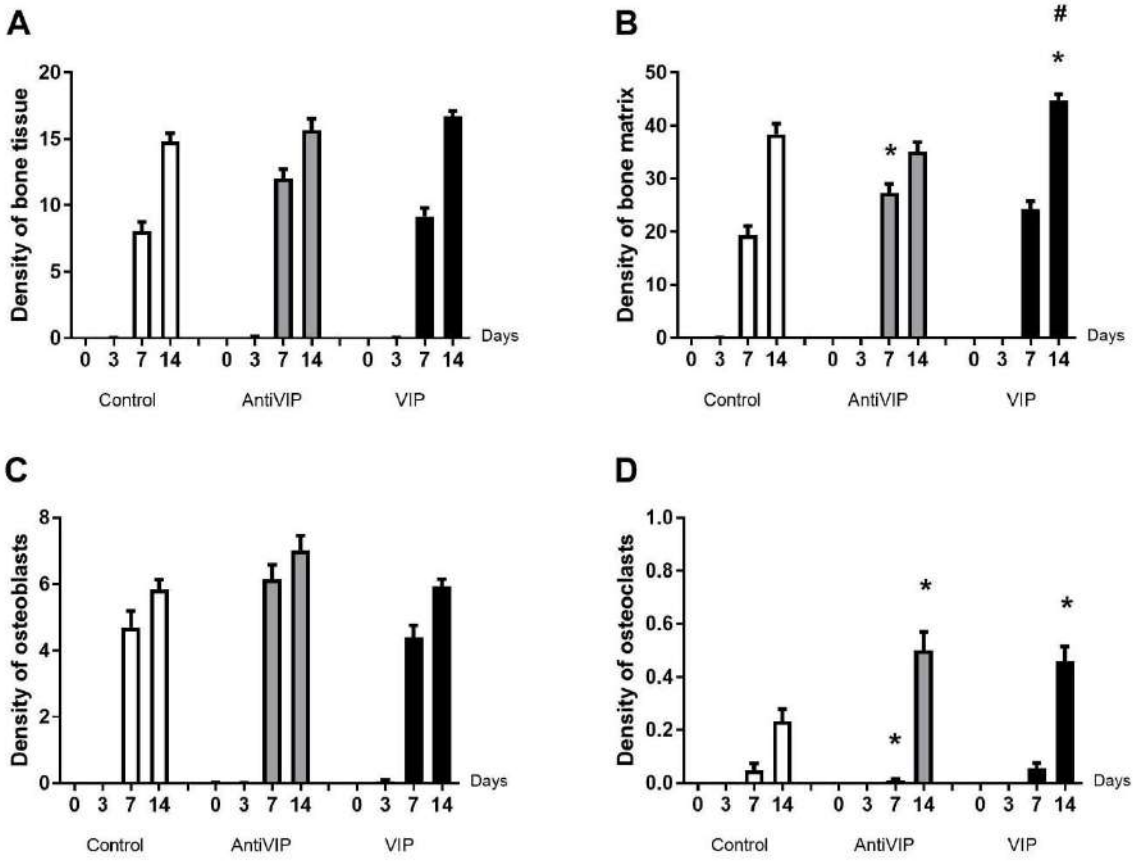

Figure 5. Comparative analysis of area density (%) of bone tissue (A) and its components (B-D) present in the dental alveoli of control mice and treated with VIP and VIP antagonist in periods of 0, 3, 7- and 14-days post-exodontia. Results are presented as the means of density for bone matrix, osteoblasts and osteoclasts. Also, the results depict the total density of bone tissue was represented by the sum of bone matrix, osteoblasts and osteoclasts. The results represent the values of the mean and standard deviation in each of the periods analyzed (*represent the differences between the control group; #represent the difference between VIP and antiVIP group).

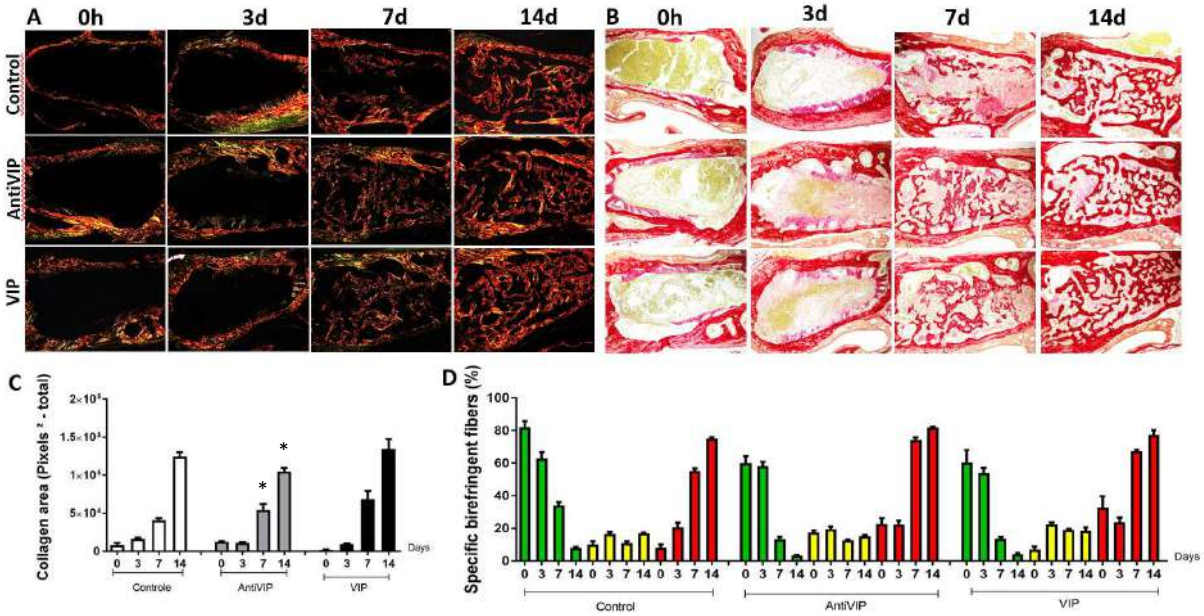

Figure 6. Analysis of birefringence of the collagen fibers present in the dental alveolus in the 0, 3, 7- and 14-days post-extraction periods, in the control, VIP antagonist and VIP groups. Photomicrographs representing the middle region of the dental alveolus, captured under polarized (A) and non-polarized light (B), showing the deposition of collagen fibers with birefringence in green, yellow and red at 0, 3, 7 and 14 days in all groups (control, VIP antagonist and VIP). Stain Picrosirius Red; 10x objective. (C) Quantitative analysis of the area (pixels^2) occupied by birefringent collagenous fibers in the dental alveoli at periods 0, 3, 7- and 14-days post-exodontia, in the control and treated with VIP antagonist and VIP. Periods of 0, 3, 7 and 14 days represented in relation to the area in pixels^2 of birefringent fibers within the green, yellow and red spectrum relative to the total area, throughout the experimental periods. The results represent the values of the mean and standard deviation in each of the periods analyzed. (D) Quantitative analysis of the area (pixels^2) occupied by birefringent collagen fibers in the dental alveolus at periods 0, 3, 7- and 14-days post-exodontia, in the control and treated animals with VIP antagonist and VIP. Periods of 0, 3, 7 and 14 days represented in relation to the area in pixels^2 of birefringent fibers within the green, yellow and red spectrum percentage to the total area, throughout the experimental periods. The results represent the values of the mean and standard deviation in each of the periods analyzed (*represent the differences between the control group).

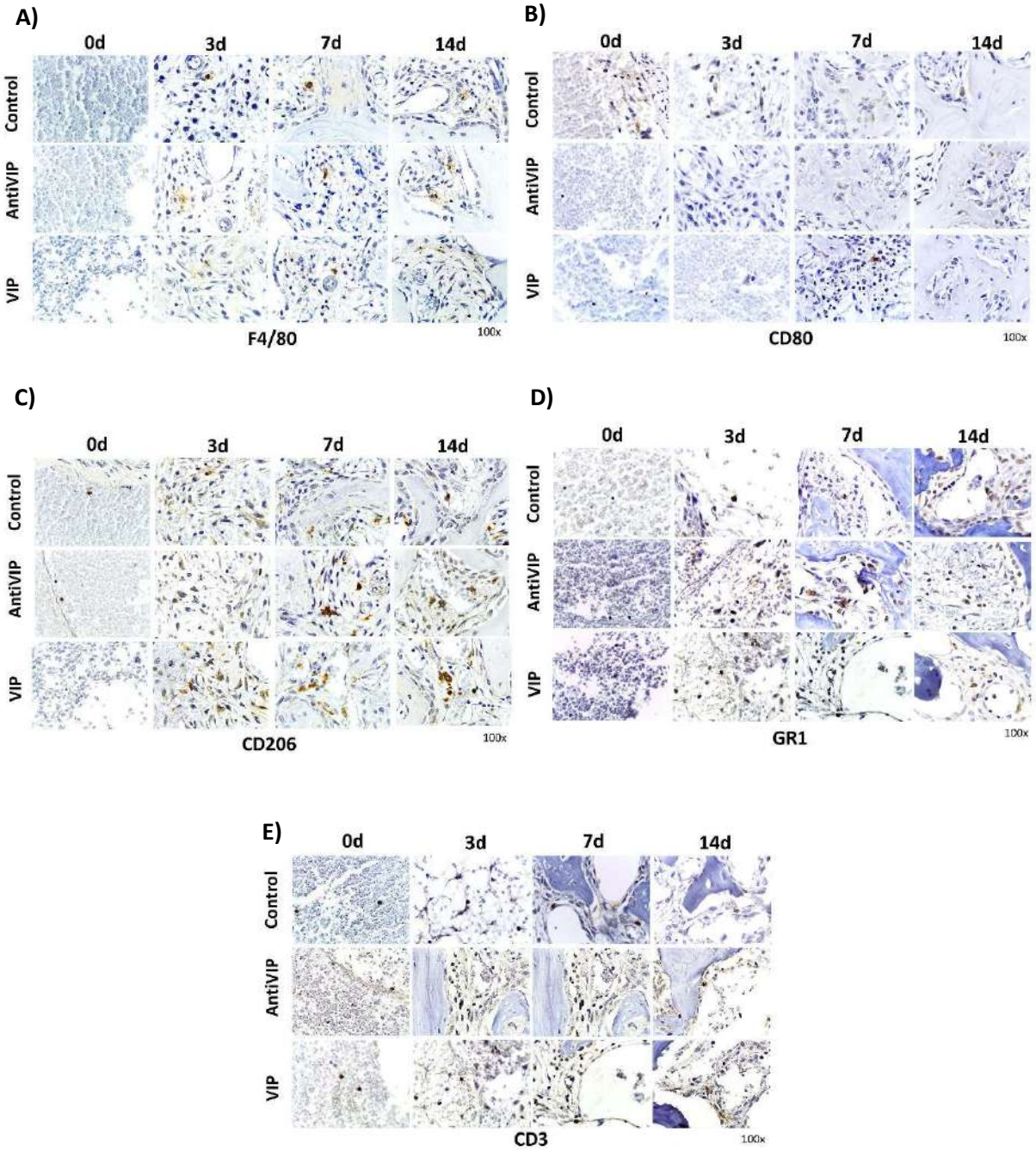

Figure 7. Immunohistochemistry analysis for (A) F4/80^{+}, (B) CD80^{+}, (C) CD206^{+}, (D) Ly6g- GR1^{+} and (E) CD3^{+}, cells present in the bone repair process in control, VIP antagonist and VIP. Representative sections from medial thirds of the socket at days 0, 3, 7 and 14 days after tooth extraction. Anti-staining Mayer's hematoxylin; objective of 100x.

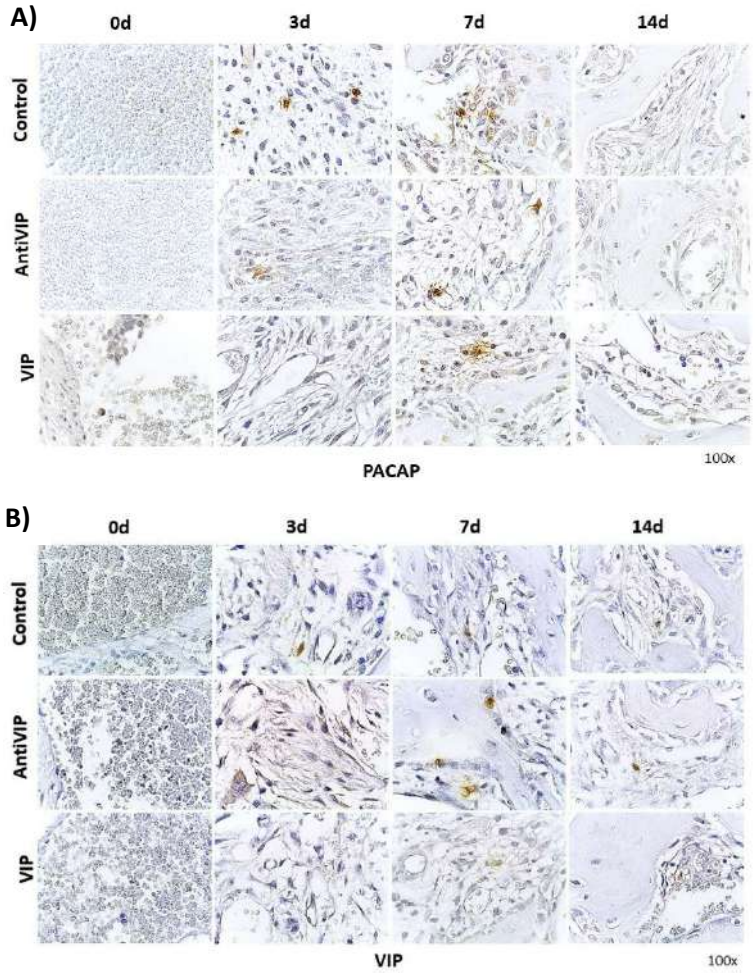

Figure 8. Immunohistochemistry analysis for (A) PACAP^{+} and (B) VIP^{+} cells present in the bone repair process in the control, VIP antagonist and VIP treated mice. Representative sections from medial thirds of the socket at days 0, 3, 7 and 14 days after tooth extraction. Anti-staining Mayer hematoxylin; objective of 100x.

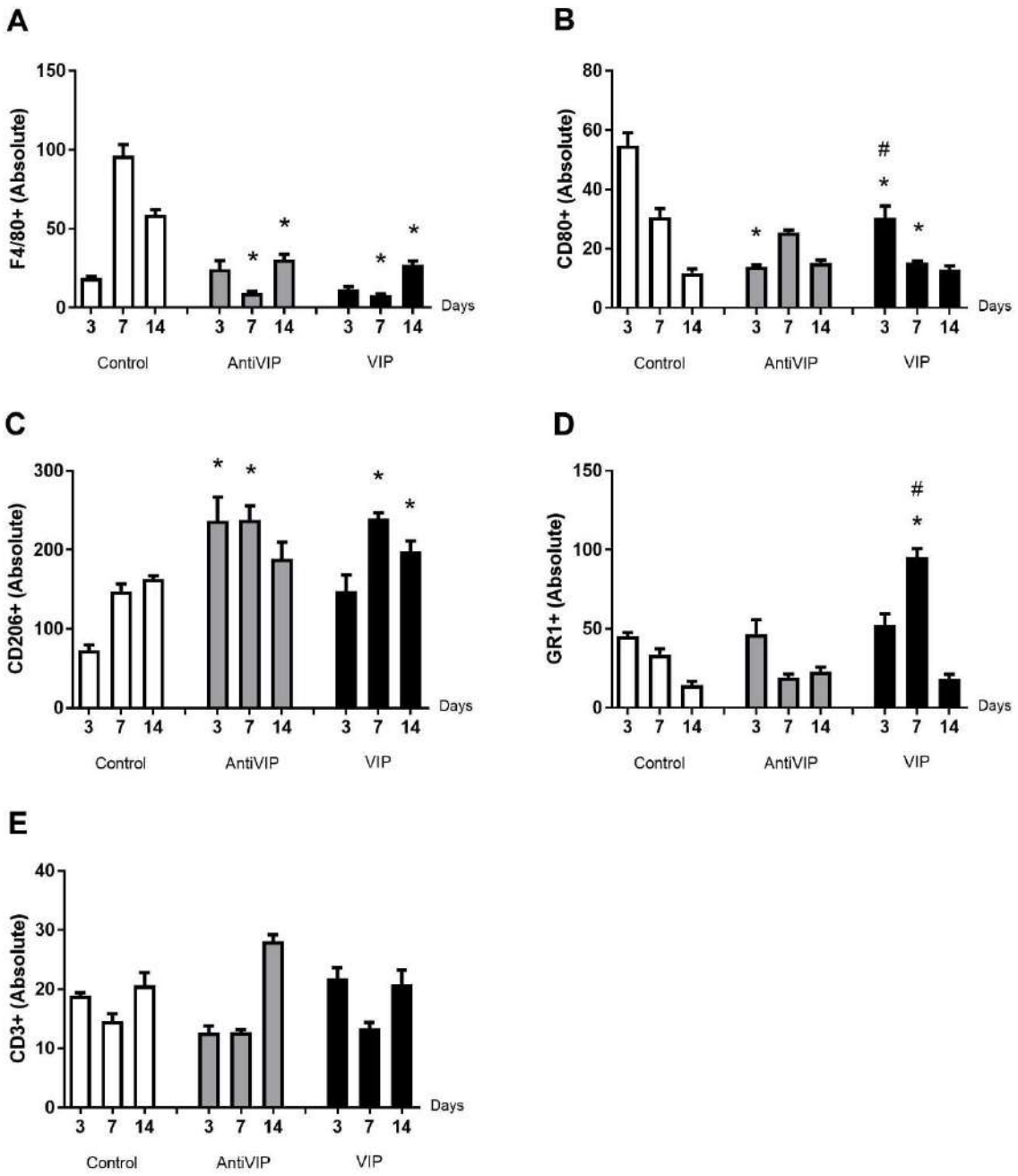

Figure 9. Analysis of inflammatory cells in the alveolar bone healing kinetics after tooth extraction in control, VIP and VIP antagonist treated mice. Immunohistochemistry quantification corresponding (A) F4/80^{+}, (B) CD80^{+}, (C) CD206^{+}, (D) Ly6g-Gr1^{+}and (E) CD3 (*represent the differences between the control group; #represent the difference between VIP and antiVIP group).

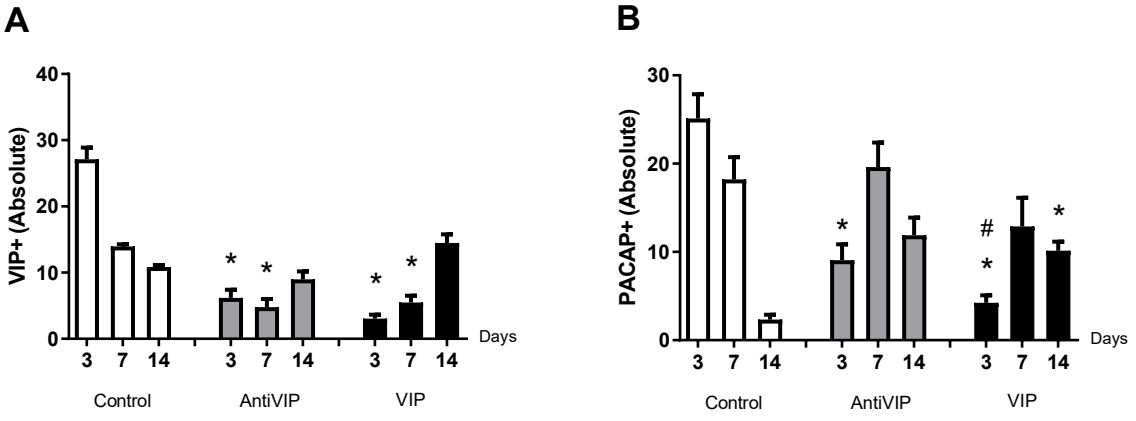

Figure 10. Analysis of inflammatory cells in the alveolar bone healing kinetics after tooth extraction in control, VIP and VIP antagonist treated mice. Immunohistochemistry quantification corresponding (A) VIP$^+$ and (B) PACAP$^+$ (*represent the differences between the control group; #represent the difference between VIP and antiVIP group).

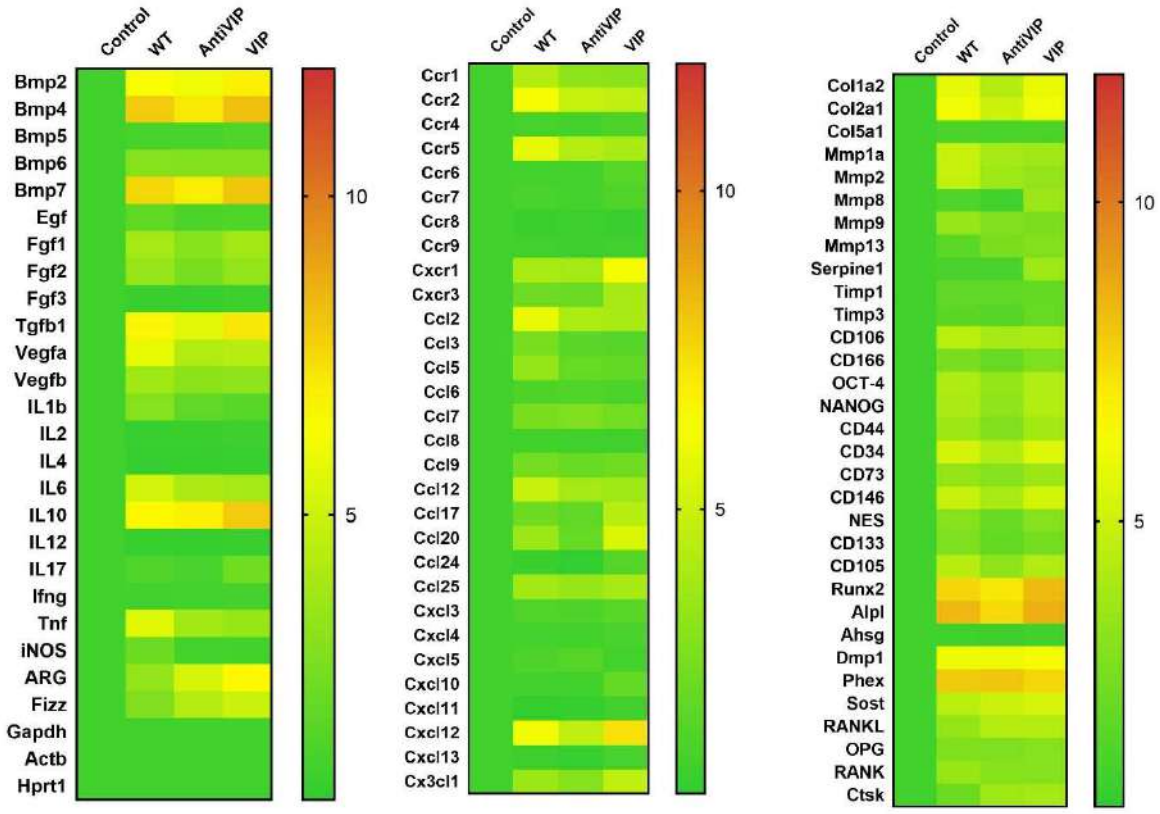

Figure 11. Molecular analysis (Real Time PCR Array) using heat map to quantify the expression of the growth factors, extracellular matrix markers, bone markers and cytokines in bone healing process among control, VIP Antagonist and VIP treated groups. Results were obtained when comparing the relative expression of the different groups norm normalized by Gapdh, Actb and Hprt1.

Article 2.2

PACAP modulatory capacity during the experimental alveolar bone healing process

Michelle de Campos Soriani Azevedo[1]
Angélica Cristina Fonseca[1]
Priscila Maria Colavite[1]
Jéssica Lima Melchiades[1]
André Petenucci Tabanez[1]
Ana Campos Codo[2]
Alexandra Ivo de Medeiros[2]
Ana Paula Favaro Trombone[3]
Gustavo Pompermaier Garlet[1]

1 Department of Biological Sciences, Bauru School of Dentistry, University of São Paulo, Bauru, SP, Brazil
2 Department of Immunology, Universidade Estadual Paulista (UNESP), School of Pharmaceutical Sciences, Araraquara, SP, Brazil
3 Department of Health Science, UNISAGRADO, Bauru, SP, Brazil

Conflicts of interest: The authors deny any conflicts of interest.

***Corresponding author:**
Gustavo Pompermaier Garlet
Bauru School of Dentistry (FOB/USP) - Department of Biological Sciences
Al. Octávio Pinheiro Brisola, 9-75 - CEP 17012-901 – Bauru - SP - Brazil
Phone +55 (14) 3235-8274 - Fax +55 (14) 3223-4679
Email: garletgp@usp.br

ABSTRACT

Host inflammatory immune response have been described as an essential step of bone healing process. In this context, immunoregulatory molecules that consequently modulate inflammatory cell migration, and the subsequent bone repair, have been considered as potential targets for improving bone repair. This study aim evaluate the experimental role of the immunoregulatory molecule PACAP (Pituitary Adenylate Cyclase Activating Polypeptide) in the process of alveolar bone healing in C57Bl/6 mice. Experimental groups, submitted to tooth extraction and maintained under control conditions or treated with PACAP and PACAP antagonist (PACAP 6-38, antiPACAP); evaluated by microtomographic (µCT), histomorphometric, immunohistochemical and molecular analysis at 0, 3, 7 and 14 days to quantify tissue repair and host response indicators at the repair site. The µCT results shows a significant increase in the PACAP and antiPACAP treated groups in relation to hyperdense regions compared to the control group. Histomorphometric analysis showed a faster formation of collagen fibers and fibloblasts in the PACAP treated group compared to the control, as well as decreased osteoblast and osteoclast density in the PACAP group. Inflammatory cell counts/density were higher in the antiPACAP treated group compared to the control group in the period of 7 days; immunohistochemical analyzes demonstrate that PACAP and antiPACAP groups had a higher CD206+ cell count and decrease in CD80+, GR1, VIP+ and PACAP+ positive cells, followed by a verification of altered expression of growth factors, bones and immunological markers. Our results, in turn, suggest that the increase of CD206+ in the early periods of the bone repair process modulates the natural course of healing, promoting the decrease in CD80+ cell migration/polarization, and resulting in the increase in the new formed bone observed in PACAP and antiPACAP groups. The treatments, enhanced the M2 response was able to positively modulate the initial M1 response without eliminating it, which can be observed by bone formation within the alveoli, suggesting compensatory mechanisms, or a change in cell profile, to restore.

Keywords: PACAP/VIP, Bone healing, M2 macrophages, osteoimmunology

INTRODUCTION

Bone is an extremely dynamic tissue that provides mechanical support and protection and serves as a mineral reservoir. Bone properties are closely related to its high capacity of remodeling, which allows the its adaptation to mechanical stimuli, mobilization of mineral components and confers to the bone a high healing capacity, as the result of the cooperative action of bone forming and resorptive cells. Indeed, a dynamic interplay between osteoblasts, osteocytes and osteoclasts is described to maintain bone homeostasis and function. Importantly, bone cells are also susceptible to the influence of numerous endocrine and immune systems derived/related factors, which can influence bone homeostasis and its capacity to respond to injury. Bone healing depends on a transitory inflammatory process, where innate immune system cells and mediators allegedly are mobilized to injury site to remove cell or matrix debris and to regulate tissue repair. Although the exact mechanisms involved in the bone healing process from the local immunoregulation viewpoint remains unknown, tissue repair studies generally point to macrophages as key components in such a process (1,2).

While classically considered as pro-inflammatory cells, macrophages may present distinct functional phenotypes, termed M1 and M2 (3,4). The original definition of M1 and M2 macrophage is derived from the Th1 and Th2 cytokines (5,6), based on the differentiation that occurs in IFN-γ, TNF-α or LPS presence, resulting in an inflammatory phenotype called M1. On the other hand, macrophages can also develop a regulatory and/or repairing phenotype, called M2, in response to IL-4, and thus act in the control of tissue response and repair (3,4,7–9). During the healing, M2 macrophages utilize arginase to convert L-arginine to L-ornithine, a precursor components of collagen, just as it acts as a producer of angiogenic and growth factors that are important components in tissue repair (5,10,11).

Therefore, in relation to general tissue repair, studies show that this process involves an initial M1 polarization that typical shift toward a pro-wound healing phenotype M2 (12,13). While there are few studies specifically focused in bone repair, considering may directly or indirectly interference of macrophages with differentiation and activity of bone cells (14–17), along bone healing process, the immune response initially results in the production of pro-inflammatory cytokines associated with the

predominance of M1 macrophages, followed by the subsequent production of anti-inflammatory factors and the transition to an M2 profile dominance (12). Importantly, M1 to M2 transition have been described as an important component of healing process, also associated with the inflammation resolution at healing sites. Accordingly, a persistent or non-resolving inflammatory response is usually described to impair healing (18).

The macrophage polarization theoretically occurs in the response site, it is believed that the local microenvironment has a determining role in the polarization of macrophages that migrate to the response sites. Among the factors that could lead to M1 and M2 polarization, the primary obvious target would be IFN-γ and IL-4 respectively, originally described as inducing such polarization (4,7–9). However, previous studies demonstrate that such cytokines expression in the repair sites is low, which can be justified by the preponderantly innate immunity nature of the response, which result in a relative absence of T cells in such sites (19).

In this context, another molecule capable of modulating macrophages polarization refers to the VIP-PACAP system. PACAP (pituitary adenylate cyclase activating polypeptide) and VIP (vasoactive intestinal peptide) are described are highly homologous peptides (68% homology), which once produced/released by local innervation or activated immune cells present immunoregulatory properties over multiple cell types, including macrophages and bone cells, via its binding to specific receptors (VPAC1 and VPAC2, both with high affinity for VIP and PACAP; and PAC1, an exclusive PACAP receptor). Focusing specifically on PACAP, it is presented in two forms, PACAP27 and PACAP38 (dominant) (20–23).

The presence of nerve fibers immunoreactive for PACAP in the bones suggests the involvement of this neuropeptide are involved in the local regulation of bone cell metabolism (24). Expressed by nervous, endocrine and immune systems (including thymocytes, macrophages and lymphocytes), in addition to different somatic tissues (25,26) PACAP are capable of influencing the physiological regulation of several systems (27), including skeletal elements (28). Additionally, PACAP can modulate the function of both innate and adaptive immunity, being stimulated macrophages theoretically one of the major PACAP targets (29). Indeed, acting via VPAC1, VPAC2 and PAC1, was described to modulate cytokines and iNOS expression by

macrophages, leading to the inhibition of pro-inflammatory cytokines and the stimulation of anti-inflammatory cytokines (30). Interestingly, previous studies describes PACAP as an macrophages "deactivator" (31–34). Considering that such studies were performed prior to the description of the functional M1 and M2 subtypes; the "deactivating" characteristics described in the studies are compatible with the M1 to M2 macrophages conversion (35).

In addition to the immunomodulatory function, PACAP is a neuropeptide with several developmental roles (28). Most cell types, including osteoblasts, responds to neuropeptides stimuli (36) and in this context, the signaling promoted by PACAP plays a pro-osteogenic role in consecutive stages of bone formation via activation of many pathways (37), and suggests that PACAP appears as an effective stimulator in cAMP activation (38,39) and its accumulation in osteoblasts propose a result of the combined activation of PACAP and VIP, regulating several signaling pathways that influence osteoblast differentiation (40) including the increased expression of BMPs and Smad1, as well as Sonic hedgehog, PATCH1 and Gli1 (37), however a few little is known about its role in bone formation *in vivo.*

In general, osteoblast differentiation is mainly regulated by BMP, WNT and Hedgehog signaling cascades. This complex mechanism involves a crosstalk via PACAP/VIP receptors, highlighting the importance of neuropeptides showing great similarity in bone formation and regeneration (40,41), including a compensatory effect in case of decrease of BMP (28). In line with this, the presence of neuropeptides was elevated after bone fracture, indicating their importance in regeneration (40). In this context, the PACAP absence can influences the molecular and biomechanical properties of the bone matrix, activating several changes in the compensatory signaling cascade (28). Therefore, the disturbance of PACAP expression implies a fragility of bone tissue, which may also indicate its possible importance in various bone formation disorders (28).

Previous studies have shown a positive regulation of PACAP and its receptors in the periodontal ligament suggesting that the lesion promotes immunological and bone remodeling reactions via PACAP/PAC1, playing a central role in the repair and restoration of periodontal function, modulating and coordinating the activities of osteoclasts and osteoblasts (42) and the treatment with PACAP increases the

deposition of inorganic matrix components *in vitro*. In addition, altered mineralization during the formation was detected in PACAP KO mice, suggesting a connection between the Ca2+ liberation in osteoblasts by PACAP, by means of extracellular accumulation during osteogenesis, in the same way that stimulates the expression of ALP (38,40). The calcitonin gene-related protein in turn, affects osteoclast function and the presence of PACAP decreases the matrix resorption and consequently Ca release by these cells (40), suggesting an essential role of the PACAP/VIP system in osteoclast differentiation or activation playing a vital role in the bone absorption (37,41,43–45).

Regarding to the receptors, previous studies show that osteoblasts express functional VPAC2 with higher binding affinity for PACAP than for VIP and that VPAC1 expression is induced during osteoblast differentiation, which may indicate a specific role for these receptors during formation bone (38).

The effects neuroendocrine or paracrine of PACAP on osteoblasts acting through receptors acts as a potent ligand (41,46) suggesting that PACAP production maybe one of many complementary autocrine/paracrine signals to initiate the cascades requisite for regeneration (47), under in vivo physiological circumstances, release of PACAP from nerve endings in the bone marrow or periosteum is also possible (48,49). On the other hand, even with low expression, the presence of PACAP was verified in osteoblast culture, suggesting the capacity of release of endogenous PACAP by osteogenic cells (37). Osteoclasts express specific VPAC1 and PACAP, but not VPAC2, binding sites that regulate bone resorption activity (41,50).

Therefore, the aim of this study was to determine the role of PACAP treatment in mice due to a possible M2 polarization and its impact in the process of alveolar bone healing, as well investigate the potential mechanisms by which this factor exerts this control.

MATERIALS AND METHODS

Animals

The experimental groups consisted of 8-week-old wild type (WT) male mice acquired from Ribeirão Preto Medical School (FMR/USP) breeding facility, maintained during the experimental period in Department of Biological Sciences of FOB/USP facility.

During the study period, the mice were fed with standard sterile solid ration of mice (Nuvital, Curitiba, PR, Brazil) and sterile water. The experimental protocol was approved by the Institutional Committee for Care and Animal Use and by Guide for the Care and Use of Laboratory Animals (CEEPA-FOB/USP, process # 001/2016).

Experimental Protocol and mice tooth extraction model

Mice C57BL/6 wild type, treated (experimental groups) or not (control group) with PACAP (Bachem - Catalog number H-8430 - 0.05mg/kg IP, 24/24h) or PACAP6-38 (PACAP Antagonist) - (Bachem – Catalog number H-2734; 0.05mg/kg IP, 24/24h), beginning 1 day prior to the upper right incisor extraction and until the end of the experimental periods (0, 3, 7 and 14 days post tooth extraction), subsequently, were anesthetized by intramuscular administration of 80mg/kg of ketamine chloride (Dopalen, Agribrans Brasil LTDA) and 160mg/kg of xylazine chloride (Anasedan, Agribrands Brasil LTDA) in the proportion 1:1 according to the animal body mass. In the end of the experimental periods, animals were killed with excessive dose of anesthetic and the maxillae were collected (N=5 group/time) for microtomographic (µCT), and prepared to histomorphometry, immunohistochemical and collagen birefringence analysis, other than these (N=4 group/time) were submitted to molecular analysis by Real Time PCR Array.

Micro-computed tomography (µCT) assessment

The samples were scanned by the Skyscan 1174 System (Skyscan, Kontich, Belgium), at 50 kV, 800 µA, with a 0.5 mm aluminum filter and 15% beam hardening correction, ring artifacts, reduction, 180 degrees of rotation and exposure range of 1 degree. Images were captured with 1304 x 1024 pixels and a resolution of 14µm pixel size. Projection images were reconstructed using the NRecon software and three-dimensional images obtained by the CT-Vox software. Morphological parameters of trabecular bone microarchitecture were assessed using the CTAn software in accordance with the recommended guidelines (51). A cylindrical region of interest (ROI) with an axis length of 3mm and diameter of 1mm was determined by segmenting the trabecular bone located from the coronal to apical thirds. Measurements included the tissue volume (TV), bone volume (BV) bone volume fraction (BV/TV, %), trabecular thickness (Tb.Th, mm), trabecular number (Tb.N, mm), and trabecular separation (Tb.Sp) (19,51–53).

Histomorphometric analysis

Serial sections (8 semi-serial sections of each maxilla, with a 5 µm thickness for each section) were stained with HE (hematoxylin and eosin). Morphometric measurements were performed by a single calibrated investigator with a binocular light microscope (Olympus Optical Co., Tokyo, Japan) using a 100x immersion objective and a Zeiss 8X eyepiece containing a Zeiss II integration grid (Carl Zeiss Jena GmbH, Jena, Germany) with 10 parallel lines and 100 points in a quadrangular area. The grid image was successively superimposed on approximately 13 histological fields per histological section, comprised of all tooth sockets from the coronal limit adjacent to the gingival epithelium until the lower apical limit. For each animal/socket, sections from the medial were evaluated. In the morphometric analysis, points were counted coinciding with the images of the following components of the alveolar socket: clot, inflammatory cells, blood vessels, fibroblasts, collagen fibers, bone matrix, osteoblasts, osteoclasts and other components (empty space left by intercellular liquid or bone marrow); similar to previous descriptions (19,53–56). The results were presented as the mean of volume density for each evaluated structure.

Collagen birefringence analysis

The Picrosirius-polarization method and quantification of birefringent fibers were performed to assess the structural changes in the newly formed bone trabeculae matrix based on the birefringence of the collagen fiber bundles, as previously described (19,53,57,58). Serial sections (8 semi serial sections of each maxilla) with 5µm thickness were cut and stained with Picrosirius Red stain; all sections were stained simultaneously to avoid variations due to possible differences in the staining process. Picrosirius Red-stained sections were analyzed through a polarizing lens coupled to a binocular inverted microscope (Leica DM IRB/E), and all images were captured with the same parameters (the same light intensity and angle of the polarizing lens 90° to the light source). AdobePhotoshopCS6 software was used to delimit the region of interest (alveolar area comprised of new tissue with the external limit comprised of the alveolar wall). The quantification of the intensity of birefringence brightness was performed using the AxioVision 4.8 software (CarlZeiss, Oberkochen, Germany). For quantification, the images were binarized for definition of the green, yellow and red color spectra, and the quantity of each color pixels^2 corresponding to the total area

enclosed in the tooth socket were measured. Mean values of 4 sections from each animal were calculated in pixels^2.

Immunohistochemistry analysis

Histological sections were deparaffinized following standard procedures. For antigen retrieval, citrate buffer solution was used in a steamer (96/98°C, 30'). After that, the material was incubated with 3% Hydrogen Peroxidase Block (Spring Bioscience Corporation, CA, USA) and subsequently incubated with 7% NFDM to block serum proteins. The histological sections from of all groups were incubated with Ly6g-Gr1 polyclonal antibody - sc-168490 (Santa Cruz Biotechnology, Santa Cruz, CA, USA), F4/80 (A-19) polyclonal antibodies - sc-26642 (Santa Cruz Biotechnology, Santa Cruz, CA, USA), B7-1 (H-208) monoclonal antibody - sc-9091 (Santa Cruz Biotechnology, Santa Cruz, CA, USA), CD206 (C-20) polyclonal antibody - sc-34577 (Santa Cruz Biotechnology, Santa Cruz, CA, USA), PACAP (C-19) polyclonal antibody - sc-7840 (Santa Cruz Biotechnology, Santa Cruz, CA, USA), VIP (M19) polyclonal antibody - sc-7841 (Santa Cruz Biotechnology, Santa Cruz, CA, USA), CD3-E (M-20) polyclonal antibody (sc-1127) (Santa Cruz Biotechnology, Santa Cruz, CA, USA) at 1:50 concentrations for 1 hour at room temperature. The identification of antigen–antibody reaction was performed using 3-3'-diaminobenzidine (DAB) and counter-staining with Mayer's hematoxylin. Positive controls were assessed in mouse spleen for positive Ly6g-Gr1, F4/80, CD80-B7-1, CD206, CD3, VIP and PACAP receptors. The analysis of immunolabeled cells was performed by a single calibrated investigator with a binocular light microscope (Olympus Optical Co., Tokyo, Japan) using a 100x objective. The quantitative analysis for the different markers was performed throughout the alveolar extension. The absolute number of immunolabeled cells was obtained to calculate the mean for each section.

Real Time PCR array reactions

Real Time PCR array reactions were performed as previously described (59,60). In resume, the extraction of total RNA from the remaining alveolus was performed with the RNeasy Plus kit (Qiagen Inc, Valencia, CA) according to the manufacturers' instructions. The integrity of the RNA samples was verified by analyzing 1µl of total RNA in a 2100Bioanalyzer (Agilent Technologies, Santa Clara, CA) according to the

manufacturers' instructions, and the complementary DNA (cDNA) was synthesized using 1mg of RNA through a reverse transcription reaction QuantiTect Rev Transcription kit (Qiagen Inc, Valencia, CA). Real Time PCR array was performed in a Viia7 instrument (Thermo Fisher Scientific, Carlsbad, CA) using a custom panel containing targets "Wound Healing" (PAMM-121), "Inflammatory cytokines and receptors" (PAMM-011) and "Osteogenesis" (PAMM-026) (SABiosciences, Frederick, MD) for gene expression profiling. Real Time PCR array data were analyzed by the RT^2 profiler PCR Array Data Analysis online software (SABiosciences, Frederick, MD) for normalizing the initial geometric mean of three constitutive genes (GAPDH, ACTB, Hprt1) and subsequently normalized by the control group, and expressed as fold change relative to the control group; as previously described (53).

Statistical analysis

Data were presented as means ± SD, initially the data distribution were tested by the Kolmogorov-Smirnov normality test. The statistical significance inside the group was analyzed by Kruskal-Wallis followed by Dunn's posttest or by Mann-Whitney test, while the statistical significance between periods was analyzed by Student's t test. Both were performed with Graph-Pad Prism 7.0 software (GraphPad Software Inc, San Diego, CA). Real Time PCR array data were analyzed by the Mann-Whitney test followed by Benjamini-Hochberg test. Values of $p< 0.05$ were considered statistically significant.

RESULTS

Analysis of bone microarchitecture parameters by micro-computed tomography (µCT)

After the surgeries, maxillae samples from the control and the experimental groups were compared based on experimental time (0, 3, 7 and 14 post-exodontia), using three-dimensional reconstruction by CT-Vox software (Bruker, Billerica, Massachusetts, EUA). Corroborating with previous studies based on the microtomographic analysis (19,53), we verified that the alveolar bone repair occurred in a centripetal manner, becoming confluent until filling the entire extension of the alveolus (Figure 1). The characteristics of bone microarray were evaluated employing the CTAn software (Bruker, Billerica, Massachusetts, EUA), and the following

parameters were considered: bone volume (BV mm³), tissue volume (TV mm³), percentage of bone in relation to total tissue volume (BV/TV %), trabeculae thickness (Tb.Th mm), number of trabeculae (Tb.N 1/mm) and separation of trabeculae (Tb.Sp mm) (Figure 2). In the PACAP and PACAP antagonist (antiPACAP) groups also in the control group, it was observed that during the experimental periods, there was an increase in the bone volume, expressive in the 14-days period for all groups, with a significant increase between the PACAP and the control groups (Figure 2B); the progressive increase pattern was also observed to the percentage of bone in relation to total tissue volume for all groups, with no significant differences between them (Figure 2C). Regarding to the trabeculae thickness (Figure 2D), significant increases were observed in the antiPACAP and PACAP groups compared to the control group in 14 days; in the same way, the number of trabeculae were a progressive increased in the all groups evaluated with no significant differences between them (Figure 2E). As expected, there was a decrease in the separation of the trabeculae in 14-days, following the expected kinetics of evolution in the process of alveolar bone healing (Figure 2 F); when the groups were compared, with no statistically significant variation between them in the µCT analysis.

Comparative histomorphometric analysis

Connective tissue, clot and other structures

Regarding to histological analysis (Figure 3), our histomorphometric results corroborate with the microtomographic findings, in according to the parameters for the bone healing process between the control and the treated groups. When the analysis was performed, the total area of connective tissue was considered with no significant differences between groups. Regarding the kinetics of healing, the control and the treated groups showed a progressive increase of the connective tissue, starting in 3 to 7 days followed by a decrease in 14 days, with no significant differences among the groups (Figure 4A). Considering the density of collagen fibers, similar to the previous parameter, there was a progressive increase, starting in 3 days followed by a decrease in 14 days; compared to the control group, a significant difference was observed in the PACAP group with an increase in 3-days period (Figure 4B). About the fibroblast's density, in the control and in the antiPACAP groups, were observed a progressive increase in 3 to 7 days, followed by a decrease in 14 days, with no significate differences between them. However, in the group treated with PACAP the density of

fibroblasts was higher in 3 days with a decreased in the 7 to 14-days periods. In addition, for the PACAP group, significant differences were observed in relation to the control group in 14 days and between the treated groups in the 7-days period (Figure 4C).

About the density of blood vessel area, there was no significant differences between the groups. In relation to kinetics, the area occupied by blood vessels increased gradually from 3 to 14 days (Figure 4D). In relation to the inflammatory infiltrate area, when the control and the PACAP groups were compared a similar kinetic could be observed. In the group that received the antiPACAP treatment in its turn, the density of inflammatory infiltrate was higher in 7 days when compared with the control group. After this initial process, in 14-day period, as was expected, was observed a decrease in the density of inflammatory cells in all groups analyzed with no differences between them (Figure 4E).

Analyzing the blood clot density, was observed that there was no difference between control and the groups that received treatment presenting a similar kinetics in all groups, starting with a peak of blood clot in 0-day, followed by an intense decrease very similar in all analyzed groups (Figure 4F). Regarding to the parameter called “other structures”, no differences between the groups were observed. In relation to the kinetic of the healing process, this parameter referred to the empty spaces occupied by interstitial fluid, which decreased over the periods in all groups (Figure 4G).

Bone tissue

In this parameter, total bone structures were represented by bone matrix, osteoblasts and osteoclasts. In reference to the kinetic, the groups presented the same pattern to bone tissue and bone matrix parameters, with a progressive increase between the periods, and a higher density in the period of 14 days in all groups with no significant differences observed between groups (Figure 5A,B).

Regarding the comparison of area occupied by osteoblasts, an increase was found in the treated groups at 7 days when compared with the control group, and an opposite pattern was observed in the 14-day period when the same groups were compared with a significant decrease in both treated groups compared to the control group (Figure 5C). Finalizing the histomorphometric analysis, was observed that the osteoclasts’

density was smaller in antiPACAP treated group than in control and PACAP groups in the period of 7 days and significant higher in the control and the antiPACAP groups when compared to the PACAP group in 14-day (Figure 5D). In turn, the increase in osteoclasts' density observed in the 14-day period for all groups showed the beginning of the tissue remodeling process.

Collagen birefringence analysis

For birefringence analysis, was verified comparatively the formation and maturation of the collagen matrix in the evaluated groups, through collagen fibers stained by Picrosirius Red and analyzed under a polarized light. In the categorization of color spectra, birefringent fibers within the green color spectrum are related to a less organized and immature matrix. In contrast to these, fibers with a color spectrum varying from yellow to red are related to a matrix with a higher degree of organization and maturation (19,53,58,61).

Regarding the quantitative analysis of birefringence of the total area (pixels^2) of the collagen fibers present in the alveoli, we observed that the number of pixels had a progressive increase in relation to the periods in all groups, with significant differences in the treated groups when compared with the control group in the periods of 7 and 14 days, without differences between the PACAP and antiPACAP (Figure 6C).

Regarding the percentage of pixels representing the birefringent fibers in the green, yellow and red, about the total of quantified pixels in each period, it was observed that the kinetics of the production and maturation of the collagen fibers occurred in a decreasing way for the green fibers and increasing form for the yellow and red fibers. In antiPACAP and PACAP groups, red fibers were increased in 7-days period compared with the control group, in a quantity similar to that observed in 14 days. However, the yellow fibers in turn remain in a smaller quantification that follows during all the periods during the healing process and showed with a little increase in treated groups. Thus, it was observed that the three-color spectra were arranged to form the bone matrix of the new formed trabeculae in all groups analyzed along the bone repair, without statistical difference between them (Figure 6D).

Immunohistochemistry analysis of F4/80$^+$, CD80(B7-1)$^+$, CD206$^+$, Gr1(Ly6g)$^+$, CD3$^+$, PACAP$^+$ and VIP$^+$ cells

In order to verify the influence of macrophages and another inflammatory cells in the repair site, the immunolabeling was performed to F4/80, CD80 (B7-1), CD206, CD3 and GR1(Ly6g) targets (Figure 7). In addition, PACAP and VIP markers (Figure 8) were included to verify the cell production of these neuropeptides during the healing process, as well to verify the efficiency of the antagonist in the receptor PAC1. Analyzing each marker separately, as a marker for undifferentiated macrophages (M0) was selected the F4/80 target. Considering this marker, the number of immunostained cells was in general greater in control group when compared with the treated groups, presenting a higher cell number in the period of 7 days to all groups analyzed. Significant differences were observed in the antiPACAP treated group in the periods of 3, 7 and 14 days; being higher in 3-days and smaller in 7 and 14-days compared to the control group. Regarding to the PACAP treated group, in the 7-days period there was a decreased in relation to the control, and also was smaller in relation to antiPACAP when the 3-days period was analyzed (Figure 9A).

About CD80$^+$ cells (M1 macrophages), in the 3-days period the density was higher to positive cells and a decreasing number of immunolabelled cells was observed in the control group, with a similar kinect in the treated groups. In addition, fewer cells was observed in all periods in relation to the control group. In the treated groups, a significant decrease was observed for all periods evaluated, except 14 days, when were compared to the control group. Additionally, in the period of 3 days, there was a significant difference between the groups antiPACAP and PACAP being smaller in antiPACAP group (Figure 9B).

In CD206 immunolabeled cells (M2 macrophages), was observed a progressive increase during the experimental period in the control group. In the antiPACAP treated group, the number of cells immunostained was significant higher compared to the control in 3 and 7 days, becoming similar in 14-days period, with a significant increase when compared with the PACAP in 3 days. A similar increase happened in the PACAP treated group in 3 days when compared with the control group, however the number of cells remained similar in the subsequent 7- and 14-day periods (Figure 9C).

Regarding to GR1 target, the highest number of positive cells was observed in 3 days gradually decreasing in 7 and 14 days for all evaluated groups. About the antiPACAP treated group, a significant decreased was observed in 7 and 14 days, when compared with the control group; and was also smaller when the antiPACAP and the PACAP were compared in the period of 7 days. In the group treated with PACAP, the number of positive cells was higher in 3 and 7 days, when compared with control and PACAP groups and statistically decreased in the 14 days when correlated with the control group (Figure 9D).

When CD3-labeled cells were analyzed, in the control group the number of labeled cells was similar in all experimental periods. About the group treated with antiPACAP, a significant decrease was observed in 3 and 14-days period in comparison with the control group. In the group treated with PACAP, no differences were attended (Figure 9E).

Due to their homology with PACAP, cells labeled for VIP were also evaluated. The expression of positive cells was increased in the control group, with a higher number of cells immunolabelled in 3 days. In the treated groups the expression was lower in all periods when were compared with the control group, except in 14 days. Also, in a comparative analysis between the antiPACAP and the PACAP groups, a significant difference could be observed between them in the period of 7 days (Figure 10A). In relation to PACAP positive cells, in the control group the highest number was observed in the 3-days period, followed by a decrease in 7 and 14 days. Regarding the antiPACAP group, a significant increase was observed in the 14 days period, compared to the control group. In its turn, the PACAP treated group, showed significant increase in 14 days; and a decreased number of positive cell in 3 and 7 days, when compared with the control group. Additionally, significant differences were attended between the antiPACAP and PACAP groups in relation to 3 days. In these periods, although in the PACAP the number of positive cells was lower in 3-days, and the opposite was verified when the group that received antiPACAP treatment was compared (Figure 10B).

Molecular analysis using PCR Array

The gene expression of several molecules involved in inflammatory response and bone healing, including growth factors, immunological/inflammatory markers, extracellular matrix and bone markers were investigated employing a pool of samples from 0, 3, 7- and 14-days periods, analyzed using Real Time PCR array (Figure 11). Among several growth factors, the expression of BMP2 and BMP6 were up regulated in both the antiPACAP and the PACAP-treated groups in relation to the control group, while BMP4 and TGFβ1 were up regulated only in the group that was treated with PACAP. At the same time, the VEGFA expression was down regulated in the antiPACAP group. Considering the immunological markers analyzed (cytokines, chemokines, chemokine receptors and inflammatory mediators) the expression of IL-1b, TNF, CCR2, CCR5 and CCL2, were down regulated, while ARG was up regulated in both the antiPACAP and PACAP groups, as soon as IL-6, CCR1 and CCL5 was down regulated in the group treated with PACAP, while FIZZ and CCL7 was up regulated in the antiPACAP group; in the meantime, the antiPACAP-treated group was down regulated to IL-10 while the PACAP was up regulated to the same, as soon as CCL17, CXCL10 and CX3CL1 in the PACAP group. About, CCL20 it was down regulated in the antiPACAP treated group. Subsequently, the extracellular matrix markers, Col1a2, MMP8, Serpine1, CD34, DMP1, SOST1 and OPG were up regulated in the bone healing process in the PACAP-treated group; while Col2a1, Runx2 and ALP were up regulated for both the antiPACAP and PACAP-treated groups. In the same time, MMP1a, MMP2 and CD73 were down regulated in the antiPACAP and the PACAP groups. Regarding to MMP13 and CTSK, both were up regulated in PACAP-treated group.

DISCUSSION

During the healing process, several orchestrated events contributes to the repair success. Among the main events, the inflammatory immune response depends on interactions between bone, immune and nervous systems, promoting a cascade of common mediators (40). However, the exact role of inflammatory immune response in bone healing and its association with neurotrophic factors is still unclear and most

studies have focused on the influence of cells and immunological mediators on osteoclast activation and on the bone resorption process (62,63).

In our study, we observed that the PACAP administration and inhibition results in a statistically significant increase of newly formed bone and associated with an increase in anti-inflammatory profile along the repair process. The main differences in relation to the evaluated bone parameters occurred in the final of healing period (14 days) and throughout the repair process observed in the majority of immune cells markers analyzed, which suggests that the events in the osteoimmune interaction and the participation of PACAP as a bone response modulator occurs in all periods of healing.

In the view of the unexpected similar outcomes of recombinant PACAP administration and PACAP receptor (PAC1) inhibition, and the predominance of studies based in PACAP administration instead of inhibition in the literature, we will initially will discuss how recombinant PACAP affects alveolar bone healing outcome. In order to consider the possible sources of VIP interference in bone healing outcome, this discussion will follow the kinetics of bone repair events and its associated readouts/markers investigated in this study.

Based on results obtained by PACAP-treated group, considering the bone formation as the main healing readout, the µCT analysis showed statistically significant differences between the PACAP-treated and control groups in the period of 14 days in relation to the bone matrix volume and the trabecular thickness number, which was increased in the PACAP group; consequently the trabecular separation between them was smaller. Complementary, histomorphometric analyzes revealed significant differences in bone healing parameters. Specifically, the density of osteoblasts and osteoclasts were lower in the PACAP group in the period of 14 days, suggesting a faster healing process in response to PACAP administration. In this sense, the inhibition of the osteoclasts density provided by the treatment with PACAP, corroborating with previous studies that showed specific receptors to VIP and PACAP in these cells (41,50), and the increased expression of OPG and the decrease in CTSK, characteristic markers of bone remodeling and osteoclastic activity (64,65), in the treated group reinforces this evidences.

Regarding to the expression of bone markers and growth factors, the treatment with PACAP demonstrated a significant increase in TGFβ1, BMP2, BMP4 and BMP6 in the treated group. Interestingly, the simultaneous PACAP and BMP activation was demonstrated to promote the chemotaxis and differentiation of mesenchymal cells (19), promoting the activation of transcription factors such as Smad1 and Runx2 (40), and the production of ALP, Collagen I, Osterix, Osteocalcin and Osteopontin, essential to proper bone neoformation (28).

In agreement, our results demonstrate an increase in the expression of ALP, Runx2, Col1a2 and Col2a in the group that received the PACAP treatment. Many BMPs have important roles in bone and neuronal development, and the ability for these BMPs to augment and suppress selected peptide expression may be one element of that complex developmental program. The expression of PACAP when facilitated due to the low availability of BMPs promotes an increased PACAP production and may be one of many complementary autocrine/paracrine signals to initiate cascades required for regeneration (47). Additionally, PACAP administration resulted in increased expression of DMP1, important factor in the bone mineralization (66); SOST, a maturation bone marker (54) and Serpine1, involved in various functions, such as regulation of degradation of the extracellular matrix, cell migration, apoptosis, and differentiation (67), suggesting an increased remodeling activity and faster healing process compared to the control group.

In relation to the histological findings, during the healing process was observed the formation of a blood clot, which is succeeded by the formation of a fibrin network, followed by formation of a granulation tissue and subsequent replacement by new bone tissue filling the alveolus as previous described (19). In this context, the significant differences between the control and the PACAP-treated groups related to the connective tissue was observed in the increased density of collagen fibers in the period of 3 days in PACAP group, supported by the gene expression data. Another element significantly altered in the treated group was the fibroblasts' density, which was decreased in the period of 14 days compared to the control group which, once again suggesting that an accelerated repair in the PACAP group.

This fact can be suggest by the analysis of the yellow and red fiber density slightly higher in the PACAP group, confirmed by the histomorphometric analysis of the

connective tissue, being represented by the parameters of collagen fibers and fibroblasts for PACAP-treated group. Then the increased density observed in 7 days in PACAP group for mature collagen fibers (red) can also be confirms by the histomorphometric analysis of the collagen fibers in the same period.

An increased remodeling activity is also suggested by increased MMP8 expression in the PACAP-treated group; on the other hand, decreased in MMP1a, MMP2 and MMP13 expression show an important role of MMPs for inflammatory cell migration and angiogenesis processes (68–70).

Regarding the profile of immune cells and the expression of immunological factors observed during the repair process in the treated group, its suggest that the events in which PACAP participates influencing subsequent events in the late periods. Regarding to the immunological parameters, was observed that the treatment with the PACAP favors an anti-inflammatory response based on the increase in CD206+ cells observed in the initial healing process, suggesting that a change toward a dominant M2 profile favors the t early repair in the PACAP-treated group.

We also observed a change in the natural course of repair in relation to macrophage migration in the treated group presenting a different kinetics compared to the control group, showing a significant lower in the F4/80+ and CD80+ cell density. Accordingly, an increased expression of IL-10, ARG and TGFβ1, in parallel with the decrease in IL-1b, IL-6 and TNF levels, reinforces the hypothesis of a boosted M2-type response in PACAP group.

At this point, it is mandatory to consider that macrophages are considered one of the major targets for PACAP activity, and its modulation in healing sites can directly affect the subsequent release of pro- or anti-inflammatory cytokines and growth factors important to the healing process. Neuropeptides, such as VIP and PACAP, can be added to the list of endogenous anti-inflammatory molecules. VIP and PACAP exert their anti-inflammatory function in several ways by direct inhibition of pro-inflammatory cytokine production such as TNF, IL-6 and IL-12 by activated macrophages; up-regulation of IL-10 production; inhibition of B7.1/B7.2 expression in activated macrophages; inhibition of IL-2 production and T-cell proliferation and inhibition of Th1 responses (29).

However, the decrease in the expression of CCL2/CCR2 and CCL5/CCR5 (chemokines/receptors, characteristically involved in macrophages chemotaxis) (71) and the increase in GR1 positive cells, followed by the increased expression of CX3CL1 (responsible for leukocyte extravasation by cell adhesion, including neutrophils and monocytes), CXCR1 (receptor expressed on neutrophils, monocytes, T lymphocytes, dendritic cells, eosinophils, basophils and mast cells) and CXCR3 (receptor for CXCL10, inducer of calcium mobilization) (72), observed in PACAP group, shows that not only macrophages suffer the action of PACAP during the healing process.

Interestingly, usually an inverse association is described between neutrophils and M2 macrophages, since neutrophils depletion results in increase in M2 macrophages increase and M1 reduction in healing sites, a phenotype associated with increased local fibrosis (73). Also, M2 depletion results in increase in neutrophils and M1 macrophages in scar tissue, and decreased collagen deposition (74). Importantly, while M1-M2 transition is usually described to favor bone healing, the same is true for the initial presence of neutrophils in bone injury sites (75). However, the sustained presence of neutrophils is typically considered a detrimental factor for healing outcome, being associated with exacerbated inflammation and with interferences in bone formation process (53,76).

Additionally, the balance in the expression of chemokines and receptors revealed an increase in CCL17 (induces T cell chemotaxis through interaction with CCR4 (77); however the expression of CCR1, critical for the recruitment of effector immune cells to the site of inflammation (78), was decreased in the same group. Considering the immunological markers analyzed its mediators playing an important hole in the recruitment of inflammatory cells to the inflammation site by chemotaxis and activation of has been implicated in wound healing and interaction between receptors in response to secreted by several cell types (79–83). These data once again reinforce the idea that the increase in CD206 and GR1 positive cells and the decrease in CD80, F4/80, VIP and PACAP may have been controlled by PACAP treatment by chemokines and specific receptors.

Other important factors in cell migration and heal environment characteristics are the markers, CD34 that indicates the presence of stem cell in many tissue (84) increased in the treated group, and CD73, a marker of lymphocyte differentiation (85,86) with a decreased expression in the same group. The inverse expression of these markers suggest the presence of undifferentiated cells that migrate during the healing process forming a granulation tissue as well as the low CD73 expression suggests that the CD3 positive cells observed in this group are not differentiated lymphocytes reinforcing the idea that the PACAP treatment was capable of polarizing macrophages to an M2 profile in the healing site T-cell independent .

Regarding to the results observed in the antiPACAP-treated group, contrary to the overall expectations, the results were quite similar to the PACAP-treated group in some aspects. Unexpectedly, PACAP agonist and antagonist resulted in similar modulation of host response and the bone healing readouts. During the repair, the PACAP and the antiPACAP group had significant differences in the density of osteclasts that was lower in the group treated with PACAP, suggesting an inhibition in the osteoclastc activity promoted by the treatment. A difference was also observed in the fibroblasts density which was higher in the group treated with antiPACAP. Other differences between the treated groups were in the inflammatory cells number, that was smaller of F4/80, VIP and PACAP positive cells and higher of CD80 and GR1 in the PACAP treated group. At the end of the healing process, we observed that an initial pro-inflammatory response is necessary for a good progress of the repair process and that even with the changes promoted in the inflammatory response through treatment with PACAP and antiPACAP the repair capacity is not compromised, or even accelerated in the both groups, which can be observed by bone formation inside the alveoli, suggesting compensatory mechanisms, or even a change in cell profile, to restore itself.

The putative PACAP/VIP receptor may tentatively be defined best as a PAC1 receptor, based on the receptor kinetics and second messenger. The equal affinities, within an order of magnitude, for PACAP and VIP to the receptor, combined with the indication of an increase in $Ca2^{+}$ in some stromal cells upon stimulation by neuropeptide, is at present consistent with data for the VPAC2. Combined with the presence of nerve fibers immunoreactive for VIP in the bone repair site, suggests that VIP and PACAP,

are involved in the local regulation of bone cell metabolism (24), verified in our results by positive immunostaining cells for VIP and PACAP at the repair site.

The antagonist PACAP(6-38) has been described as the most potent antagonist of the PAC1 receptor in a cAMP stimulation (87). Several studies have observed the effective potential antagonist of the compound, especially studies using the culture of the most varied cell lines in its methodology (88–92). In addition, nerve stimulation studies (93) and *in vivo* behavioral studies (94,95) also observed the antagonistic effect of PACAP6-38. However, some *in vivo* studies verified that the peptide fragment PACAP(6–38) was not able to provide the antagonist effect (96), suggesting a partial inhibition, without being able to inhibit the stimulating action of VIP while PACAP receptor binding is spared (97), similarly studies have observed that PACAP-inducing capacity was sensitive to blockade by the PACAP 6-38 antagonist, but not by a VIP antagonist (98).

The unexpected similarity in the PACAP agonist and antagonists may be explained by the complexity of the receptors of VIP/PACAP system, which includes that similarity of the receptors pathways. The blockade of the VPAC1, VPAC2 and PAC1 receptors, which bind VIP and PACAP-38 with varying affinities. Compared to PACAP, VIP binds to PAC1 with lower affinity. Another isoform of PACAP, PACAP-27 can also bind all three receptors promoting a binding of endogenous PACAP with these receptors (99,100) and which suggests a compensatory mechanism *in vivo*.

In the case of the treatments performed in this study, the block of PAC1 by means of an PACAP6-38 antagonist, which does not prevent the binding of PACAP in VPAC1 and VPAC2 receptors, which, although less efficient in the activation of responses in the bone tissue was able to present similar results for the two treated groups, inferring the activation pathways through compensatory mechanisms in the group treated with the antagonist which can be explain the discrete disorganization observed by a qualitative morphometric analysis in the antiPACAP-treated group suggested by the lower expression in some growth factors and bone markers and apparently this interference also influences the process of bone remodeling and the efficient M2 polarization.

Additionally, experiments with M0 macrophages differentiated from mouse bone marrow mesenchymal cells showed that alone, both PACAP and antiPACAP were not able to promote macrophage profile differentiation (data not shown), suggesting that different mechanisms also are involved in this modulation so that it can occur effectively. The confirmation of VPAC1 and VPAC2 receptor activation as a tentative of a compensatory mechanism in the bone repair process could be demonstrated in future trials by simultaneous blockade of VPAC1, VPAC2 and PAC1.

CONCLUSION

In summary, the present study demonstrated an increase in the bone tissue in the treated groups at the endpoint. In conclusion, our results demonstrate that the early repair observed in the antiPACAP and PACAP was associated with an increase presence of M2 macrophages and associated labels. Further studies are required to clarify the underlying mechanisms and influence of PACAP along bone healing.

CONFLICT OF INTEREST

The authors deny any conflicts of interest related to this study.

ACKNOWLEDGEMENTS

The authors thank Daniele Ceolin, Patricia Germino, and Tânia Cestari for their excellent technical assistance. This study was supported by grants and scholarships form FAPESP (15/24637-3, 15/25618-2).

REFERENCES

1. Janeway CA, Medzhitov R. Innate immune recognition. Annu Rev Immunol [Internet]. 2002;20:197–216. Available from: http://www.ncbi.nlm.nih.gov/pubmed/11861602
2. Morrissette N, Gold E, Aderem A. The macrophage--a cell for all seasons. Trends Cell Biol. 1999 May;9(5):199–201.

3. Martinez FO, Sica A, Mantovani A, Locati M. Macrophage activation and polarization. Front Biosci [Internet]. 2008 Jan 1;13:453–61. Available from: http://www.ncbi.nlm.nih.gov/pubmed/17981560

4. Mosser DM, Edwards JP. Exploring the full spectrum of macrophage activation. Nat Rev Immunol. 2008 Dec;8(12):958–69.

5. Edholm E-S, Rkoo KH, Robert J. Evolutionary Aspects of Macrophages Polarization. Kloc M, editor. Macrophages Origin, Functions and Biointervention. Cham: Springer International Publishing; 2017. 3–22 p. (Results and Problems in Cell Differentiation; vol. 62).

6. Mills CD, Kincaid K, Alt JM, Heilman MJ, Hill AM. M-1/M-2 macrophages and the Th1/Th2 paradigm. J Immunol [Internet]. 2000 Jun 15;164(12):6166–73. Available from: http://www.ncbi.nlm.nih.gov/pubmed/10843666

7. Murray PJ, Wynn TA. Protective and pathogenic functions of macrophage subsets. Nat Rev Immunol [Internet]. 2011 Oct 14;11(11):723–37. Available from: http://www.ncbi.nlm.nih.gov/pubmed/21997792

8. Shi C, Pamer EG. Monocyte recruitment during infection and inflammation. Nat Rev Immunol [Internet]. 2011 Oct 10;11(11):762–74. Available from: http://www.ncbi.nlm.nih.gov/pubmed/21984070

9. Sica A, Mantovani A. Macrophage plasticity and polarization: In vivo veritas. Journal of Clinical Investigation. 2012.

10. Mills CD. Macrophage arginine metabolism to ornithine/urea or nitric oxide/citrulline: a life or death issue. Crit Rev Immunol [Internet]. 2001;21(5):399–425. Available from: http://www.ncbi.nlm.nih.gov/pubmed/11942557

11. Jetten N, Verbruggen S, Gijbels MJ, Post MJ, De Winther MPJ, Donners MMPC. Anti-inflammatory M2, but not pro-inflammatory M1 macrophages promote angiogenesis in vivo. Angiogenesis [Internet]. 2014 Jan 8;17(1):109–18. Available from: http://link.springer.com/10.1007/s10456-013-9381-6

12. Gaffney L, Warren P, Wrona EA, Fisher MB, Freytes DO. Macrophages' Role in Tissue Disease and Regeneration. In: Kloc M, editor. Macrophages Origin, Functions and Biointervention. Cham: Springer International Publishing; 2017. p. 245–71. (Results and Problems in Cell Differentiation; vol. 62).

13. Sindrilaru A, Scharffetter-Kochanek K. Disclosure of the Culprits: Macrophages-Versatile Regulators of Wound Healing. Adv wound care [Internet]. 2013 Sep;2(7):357–68. Available from: http://www.ncbi.nlm.nih.gov/pubmed/24587973

14. Alexander KA, Chang MK, Maylin ER, Kohler T, Müller R, Wu AC, et al. Osteal macrophages promote in vivo intramembranous bone healing in a mouse tibial injury model. J Bone Miner Res [Internet]. 2011 Jul;26(7):1517–32. Available from: http://www.ncbi.nlm.nih.gov/pubmed/21305607

15. Graves DT, Cochran D. The contribution of interleukin-1 and tumor necrosis factor to periodontal tissue destruction. J Periodontol [Internet]. 2003

Mar;74(3):391–401. Available from: http://www.ncbi.nlm.nih.gov/pubmed/12710761

16. Takayanagi H. Inflammatory bone destruction and osteoimmunology. J Periodontal Res. 2005 Aug;40(4):287–93.

17. Takayanagi H. Osteoimmunology: shared mechanisms and crosstalk between the immune and bone systems. Nat Rev Immunol. 2007 Apr;7(4):292–304.

18. de Seny D, Cobraiville G, Leprince P, Fillet M, Collin C, Mathieu M, et al. Biomarkers of inflammation and innate immunity in atrophic nonunion fracture. J Transl Med [Internet]. 2016;14:258. Available from: http://www.ncbi.nlm.nih.gov/pubmed/27599571

19. Vieira AE, Repeke CE, Ferreira Junior S de B, Colavite PM, Biguetti CC, Oliveira RC, et al. Intramembranous bone healing process subsequent to tooth extraction in mice: micro-computed tomography, histomorphometric and molecular characterization. PLoS One [Internet]. 2015;10(5):e0128021. Available from: http://www.ncbi.nlm.nih.gov/pubmed/26023920

20. Mutt V. Vasoactive intestinal polypeptide and related peptides. Isolation and chemistry. Ann N Y Acad Sci [Internet]. 1988;527:1–19. Available from: http://www.ncbi.nlm.nih.gov/pubmed/3133967

21. Virgolini I, Raderer M, Kurtaran A, Angelberger P, Yang Q, Radosavljevic M, et al. 123I-vasoactive intestinal peptide (VIP) receptor scanning: update of imaging results in patients with adenocarcinomas and endocrine tumors of the gastrointestinal tract. Nucl Med Biol [Internet]. 1996 Aug;23(6):685–92. Available from: http://www.ncbi.nlm.nih.gov/pubmed/8940711

22. Refai E, Jonsson C, Andersson M, Jacobsson H, Larsson S, Kogner P, et al. Biodistribution of liposomal 131I-VIP in rat using gamma camera. Nucl Med Biol [Internet]. 1999 Nov;26(8):931–6. Available from: http://www.ncbi.nlm.nih.gov/pubmed/10708307

23. Reubi JC. Peptide receptors as molecular targets for cancer diagnosis and therapy. Endocr Rev [Internet]. 2003 Aug;24(4):389–427. Available from: http://www.ncbi.nlm.nih.gov/pubmed/12920149

24. Winding B, Wiltink A, Foged NT. Pituitary adenylyl cyclase-activating polypeptides and vasoactive intestinal peptide inhibit bone resorption by isolated rabbit osteoclasts. Exp Physiol [Internet]. 1997 Sep;82(5):871–86. Available from: http://www.ncbi.nlm.nih.gov/pubmed/9331555

25. Cutz E, Chan W, Track NS, Goth A, Said SI. Release of vasoactive intestinal polypeptide in mast cells by histamine liberators. Nature [Internet]. 1978 Oct 19;275(5681):661–2. Available from: http://www.ncbi.nlm.nih.gov/pubmed/81468

26. Martinez C, Delgado M, Abad C, Gomariz RP, Ganea D, Leceta J. Regulation of VIP production and secretion by murine lymphocytes. J Neuroimmunol [Internet]. 1999 Jan 1;93(1–2):126–38. Available from: http://www.ncbi.nlm.nih.gov/pubmed/10378876

27. Gozes I, Furman S. VIP and drug design. Curr Pharm Des [Internet]. 2003;9(6):483–94. Available from: http://www.ncbi.nlm.nih.gov/pubmed/12570811

28. Józsa G, Szegeczki V, Pálfi A, Kiss T, Helyes Z, Fülöp B, et al. Signalling Alterations in Bones of Pituitary Adenylate Cyclase Activating Polypeptide (PACAP) Gene Deficient Mice. Int J Mol Sci [Internet]. 2018 Aug 27;19(9). Available from: http://www.ncbi.nlm.nih.gov/pubmed/30150589

29. Ganea D, Delgado M. Vasoactive intestinal peptide (VIP) and pituitary adenylate cyclase-activating polypeptide (PACAP) as modulators of both innate and adaptive immunity. Crit Rev Oral Biol Med [Internet]. 2002;13(3):229–37. Available from: http://www.ncbi.nlm.nih.gov/pubmed/12090463

30. Leceta J, Gomariz RP, Martinez C, Abad C, Ganea D, Delgado M. Receptors and transcriptional factors involved in the anti-inflammatory activity of VIP and PACAP. Ann N Y Acad Sci [Internet]. 2000;921:92–102. Available from: http://www.ncbi.nlm.nih.gov/pubmed/11193883

31. Koff WC, Dunegan MA. Modulation of macrophage-mediated tumoricidal activity by neuropeptides and neurohormones. J Immunol [Internet]. 1985 Jul;135(1):350–4. Available from: http://www.ncbi.nlm.nih.gov/pubmed/2582037

32. Ganea D, Delgado M. Inhibitory neuropeptide receptors on macrophages. Microbes Infect [Internet]. 2001 Feb;3(2):141–7. Available from: http://www.ncbi.nlm.nih.gov/pubmed/11251300

33. Ganea D, Delgado M. Neuropeptides as modulators of macrophage functions. Regulation of cytokine production and antigen presentation by VIP and PACAP. Arch Immunol Ther Exp (Warsz) [Internet]. 2001;49(2):101–10. Available from: http://www.ncbi.nlm.nih.gov/pubmed/11348014

34. Delgado M, Pozo D, Ganea D. The significance of vasoactive intestinal peptide in immunomodulation. Pharmacol Rev [Internet]. 2004 Jun;56(2):249–90. Available from: http://www.ncbi.nlm.nih.gov/pubmed/15169929

35. Martinez FO, Gordon S. The M1 and M2 paradigm of macrophage activation: time for reassessment. F1000Prime Rep [Internet]. 2014;6:13. Available from: http://www.ncbi.nlm.nih.gov/pubmed/24669294

36. Lerner UH, Lundberg P, Ransjö M, Persson P, Håkanson R. Helodermin, helospectin, and PACAP stimulate cyclic AMP formation in intact bone, isolated osteoblasts, and osteoblastic cell lines. Calcif Tissue Int [Internet]. 1994 Apr;54(4):284–9. Available from: http://www.ncbi.nlm.nih.gov/pubmed/7914821

37. Juhász T, Matta C, Katona É, Somogyi C, Takács R, Hajdú T, et al. Pituitary adenylate cyclase-activating polypeptide (PACAP) signalling enhances osteogenesis in UMR-106 cell line. J Mol Neurosci [Internet]. 2014 Nov;54(3):555–73. Available from: http://www.ncbi.nlm.nih.gov/pubmed/25112418

38. Lundberg P, Lundgren I, Mukohyama H, Lehenkari PP, Horton MA, Lerner UH. Vasoactive intestinal peptide (VIP)/pituitary adenylate cyclase-activating peptide

receptor subtypes in mouse calvarial osteoblasts: presence of VIP-2 receptors and differentiation-induced expression of VIP-1 receptors. Endocrinology [Internet]. 2001 Jan;142(1):339–47. Available from: http://www.ncbi.nlm.nih.gov/pubmed/11145597

39. Mukohyama H, Ransjö M, Taniguchi H, Ohyama T, Lerner UH. The inhibitory effects of vasoactive intestinal peptide and pituitary adenylate cyclase-activating polypeptide on osteoclast formation are associated with upregulation of osteoprotegerin and downregulation of RANKL and RANK. Biochem Biophys Res Commun [Internet]. 2000 Apr 29;271(1):158–63. Available from: http://www.ncbi.nlm.nih.gov/pubmed/10777696

40. Juhász T, Helgadottir SL, Tamás A, Reglődi D, Zákány R. PACAP and VIP signaling in chondrogenesis and osteogenesis. Peptides [Internet]. 2015 Apr;66:51–7. Available from: http://www.ncbi.nlm.nih.gov/pubmed/25701761

41. Jones KB, Mollano A V, Morcuende JA, Cooper RR, Saltzman CL. Bone and brain: a review of neural, hormonal, and musculoskeletal connections. Iowa Orthop J [Internet]. 2004;24:123–32. Available from: http://www.ncbi.nlm.nih.gov/pubmed/15296219

42. Nonaka S, Kitaura H, Kimura K, Ishida M, Takano-Yamamoto T. Expression of pituitary adenylate cyclase-activating peptide (PACAP) and PAC1 in the periodontal ligament after tooth luxation. Cell Mol Neurobiol [Internet]. 2013 Oct;33(7):885–92. Available from: http://www.ncbi.nlm.nih.gov/pubmed/23801193

43. Nagata A, Tanaka T, Minezawa A, Poyurovsky M, Mayama T, Suzuki S, et al. cAMP activation by PACAP/VIP stimulates IL-6 release and inhibits osteoblastic differentiation through VPAC2 receptor in osteoblastic MC3T3 cells. J Cell Physiol [Internet]. 2009 Oct;221(1):75–83. Available from: http://www.ncbi.nlm.nih.gov/pubmed/19496170

44. Persson E, Lerner UH. The neuropeptide VIP regulates the expression of osteoclastogenic factors in osteoblasts. J Cell Biochem [Internet]. 2011 Dec;112(12):3732–41. Available from: http://www.ncbi.nlm.nih.gov/pubmed/21815197

45. Lerner UH, Persson E. Osteotropic effects by the neuropeptides calcitonin gene-related peptide, substance P and vasoactive intestinal peptide. J Musculoskelet Neuronal Interact [Internet]. 2008;8(2):154–65. Available from: http://www.ncbi.nlm.nih.gov/pubmed/18622084

46. Kovacs CS, Chik CL, Li B, Karpinski E, Ho AK. Pituitary adenylate cyclase-activating peptide stimulates cyclic AMP accumulation in UMR 106 osteoblast-like cells. J Endocrinol [Internet]. 1996 May;149(2):287–95. Available from: http://www.ncbi.nlm.nih.gov/pubmed/8708540

47. Pavelock KA, Girard BM, Schutz KC, Braas KM, May V. Bone morphogenetic protein down-regulation of neuronal pituitary adenylate cyclase-activating polypeptide and reciprocal effects on vasoactive intestinal peptide expression. J Neurochem [Internet]. 2007 Feb;100(3):603–16. Available from: http://www.ncbi.nlm.nih.gov/pubmed/17181550

48. Braas KM, Schutz KC, Bond JP, Vizzard MA, Girard BM, May V. Microarray analyses of pituitary adenylate cyclase activating polypeptide (PACAP)-regulated gene targets in sympathetic neurons. Peptides [Internet]. 2007 Sep;28(9):1856–70. Available from: http://www.ncbi.nlm.nih.gov/pubmed/17512639

49. Strange-Vognsen HH, Arnbjerg J, Hannibal J. Immunocytochemical demonstration of pituitary adenylate cyclase activating polypeptide (PACAP) in the porcine epiphyseal cartilage canals. Neuropeptides [Internet]. 1997 Apr;31(2):137–41. Available from: http://www.ncbi.nlm.nih.gov/pubmed/9179866

50. Ransjö M, Lie A, Mukohyama H, Lundberg P, Lerner UH. Microisolated mouse osteoclasts express VIP-1 and PACAP receptors. Biochem Biophys Res Commun [Internet]. 2000 Aug 2;274(2):400–4. Available from: http://www.ncbi.nlm.nih.gov/pubmed/10913350

51. Bouxsein ML, Boyd SK, Christiansen BA, Guldberg RE, Jepsen KJ, Müller R. Guidelines for assessment of bone microstructure in rodents using micro-computed tomography. J Bone Miner Res [Internet]. 2010 Jul;25(7):1468–86. Available from: http://www.ncbi.nlm.nih.gov/pubmed/20533309

52. Kuroshima S, Kovacic BL, Kozloff KM, McCauley LK, Yamashita J. Intra-oral PTH administration promotes tooth extraction socket healing. J Dent Res [Internet]. 2013 Jun;92(6):553–9. Available from: http://www.ncbi.nlm.nih.gov/pubmed/23611925

53. Colavite PM, Vieira AE, Palanch Repeke CE, de Araujo Linhari RP, De Andrade RGCS, Borrego A, et al. Alveolar bone healing in mice genetically selected in the maximum (AIRmax) or minimum (AIRmin) inflammatory reaction. Cytokine [Internet]. 2019 Feb;114:47–60. Available from: http://www.ncbi.nlm.nih.gov/pubmed/30584949

54. Scala A, Lang NP, Schweikert MT, de Oliveira JA, Rangel-Garcia I, Botticelli D. Sequential healing of open extraction sockets. An experimental study in monkeys. Clin Oral Implants Res [Internet]. 2014 Mar;25(3):288–95. Available from: http://www.ncbi.nlm.nih.gov/pubmed/23551527

55. Rodrigues MTV, Cardoso CL, Carvalho PSP de, Cestari TM, Feres M, Garlet GP, et al. Experimental alveolitis in rats: microbiological, acute phase response and histometric characterization of delayed alveolar healing. J Appl Oral Sci [Internet]. 2011 Jun;19(3):260–8. Available from: http://www.scielo.br/scielo.php?script=sci_arttext&pid=S1678-77572011000300015&lng=en&tlng=en

56. Cardoso CL, Ferreira Júnior O, Carvalho PSP de, Dionísio TJ, Cestari TM, Garlet GP. Experimental dry socket: microscopic and molecular evaluation of two treatment modalities. Acta Cir Bras [Internet]. 2011 Oct;26(5):365–72. Available from: http://www.scielo.br/scielo.php?script=sci_arttext&pid=S0102-86502011000500007&lng=en&tlng=en

57. Bossini PS, Rennó ACM, Ribeiro DA, Fangel R, Ribeiro AC, Lahoz M de A, et al. Low level laser therapy (830nm) improves bone repair in osteoporotic rats:

similar outcomes at two different dosages. Exp Gerontol [Internet]. 2012 Feb;47(2):136–42. Available from: http://www.ncbi.nlm.nih.gov/pubmed/22138375

58. Garavello-Freitas I, Baranauskas V, Joazeiro PP, Padovani CR, Dal Pai-Silva M, da Cruz-Höfling MA. Low-power laser irradiation improves histomorphometrical parameters and bone matrix organization during tibia wound healing in rats. J Photochem Photobiol B Biol [Internet]. 2003 May;70(2):81–9. Available from: https://linkinghub.elsevier.com/retrieve/pii/S1011134403000587

59. Araujo LM, Ribeiro OG, Siqueira M, De Franco M, Starobinas N, Massa S, et al. Innate resistance to infection by intracellular bacterial pathogens differs in mice selected for maximal or minimal acute inflammatory response. Eur J Immunol [Internet]. 1998 Sep;28(9):2913–20. Available from: http://www.ncbi.nlm.nih.gov/pubmed/9754578

60. Glowacki AJ, Gottardi R, Yoshizawa S, Cavalla F, Garlet GP, Sfeir C, et al. Strategies to direct the enrichment, expansion, and recruitment of regulatory cells for the treatment of disease. Ann Biomed Eng [Internet]. 2015 Mar;43(3):593–602. Available from: http://www.ncbi.nlm.nih.gov/pubmed/25245220

61. Montes GS, Junqueira LCU. The use of the Picrosirius-polarization method for the study of the biopathology of collagen. Mem Inst Oswaldo Cruz [Internet]. 1991;86(suppl 3):1–11. Available from: http://www.scielo.br/scielo.php?script=sci_arttext&pid=S0074-02761991000700002&lng=en&tlng=en

62. Araujo-Pires AC, Francisconi CF, Biguetti CC, Cavalla F, Aranha AMF, Letra A, et al. Simultaneous analysis of T helper subsets (Th1, Th2, Th9, Th17, Th22, Tfh, Tr1 and Tregs) markers expression in periapical lesions reveals multiple cytokine clusters accountable for lesions activity and inactivity status. J Appl Oral Sci [Internet]. 2014;22(4):336–46. Available from: http://www.ncbi.nlm.nih.gov/pubmed/25141207

63. Glowacki AJ, Yoshizawa S, Jhunjhunwala S, Vieira AE, Garlet GP, Sfeir C, et al. Prevention of inflammation-mediated bone loss in murine and canine periodontal disease via recruitment of regulatory lymphocytes. Proc Natl Acad Sci U S A [Internet]. 2013 Nov 12;110(46):18525–30. Available from: http://www.ncbi.nlm.nih.gov/pubmed/24167272

64. Dai J, Rabie ABM. VEGF: an essential mediator of both angiogenesis and endochondral ossification. J Dent Res [Internet]. 2007 Oct;86(10):937–50. Available from: http://www.ncbi.nlm.nih.gov/pubmed/17890669

65. Liu W, Zhang X. Receptor activator of nuclear factor-κB ligand (RANKL)/RANK/osteoprotegerin system in bone and other tissues (review). Mol Med Rep [Internet]. 2015 May;11(5):3212–8. Available from: http://www.ncbi.nlm.nih.gov/pubmed/25572286

66. Toyosawa S, Oya K, Sato S, Ishida K. [Osteocyte and DMP1]. Clin Calcium [Internet]. 2012 May;22(5):713–20. Available from:

http://www.ncbi.nlm.nih.gov/pubmed/22549196

67. Czekay R-P, Wilkins-Port CE, Higgins SP, Freytag J, Overstreet JM, Klein RM, et al. PAI-1: An Integrator of Cell Signaling and Migration. Int J Cell Biol [Internet]. 2011;2011:562481. Available from: http://www.ncbi.nlm.nih.gov/pubmed/21837240

68. Hankenson KD, Dishowitz M, Gray C, Schenker M. Angiogenesis in bone regeneration. Injury [Internet]. 2011 Jun;42(6):556–61. Available from: http://www.ncbi.nlm.nih.gov/pubmed/21489534

69. Page-McCaw A, Ewald AJ, Werb Z. Matrix metalloproteinases and the regulation of tissue remodelling. Nat Rev Mol Cell Biol [Internet]. 2007 Mar;8(3):221–33. Available from: http://www.ncbi.nlm.nih.gov/pubmed/17318226

70. Vu TH, Werb Z. Matrix metalloproteinases: effectors of development and normal physiology. Genes Dev [Internet]. 2000 Sep 1;14(17):2123–33. Available from: http://www.ncbi.nlm.nih.gov/pubmed/10970876

71. Palomino DCT, Marti LC. Chemokines and immunity. Einstein (Sao Paulo) [Internet]. 2013;13(3):469–73. Available from: http://www.ncbi.nlm.nih.gov/pubmed/26466066

72. Murphy PM, Baggiolini M, Charo IF, Hébert CA, Horuk R, Matsushima K, et al. International union of pharmacology. XXII. Nomenclature for chemokine receptors. Pharmacol Rev [Internet]. 2000 Mar;52(1):145–76. Available from: http://www.ncbi.nlm.nih.gov/pubmed/10699158

73. Horckmans M, Ring L, Duchene J, Santovito D, Schloss MJ, Drechsler M, et al. Neutrophils orchestrate post-myocardial infarction healing by polarizing macrophages towards a reparative phenotype. Eur Heart J [Internet]. 2017;38(3):187–97. Available from: http://www.ncbi.nlm.nih.gov/pubmed/28158426

74. Klinkert K, Whelan D, Clover AJP, Leblond A-L, Kumar AHS, Caplice NM. Selective M2 Macrophage Depletion Leads to Prolonged Inflammation in Surgical Wounds. Eur Surg Res [Internet]. 2017;58(3–4):109–20. Available from: http://www.ncbi.nlm.nih.gov/pubmed/28056458

75. Kovtun A, Bergdolt S, Wiegner R, Radermacher P, Huber-Lang M, Ignatius A. The crucial role of neutrophil granulocytes in bone fracture healing. Eur Cell Mater [Internet]. 2016;32:152–62. Available from: http://www.ncbi.nlm.nih.gov/pubmed/27452963

76. Bastian OW, Croes M, Alblas J, Koenderman L, Leenen LPH, Blokhuis TJ. Neutrophils Inhibit Synthesis of Mineralized Extracellular Matrix by Human Bone Marrow-Derived Stromal Cells In Vitro. Front Immunol [Internet]. 2018;9:945. Available from: http://www.ncbi.nlm.nih.gov/pubmed/29765377

77. Yoshie O, Matsushima K. CCR4 and its ligands: from bench to bedside. Int Immunol [Internet]. 2015 Jan;27(1):11–20. Available from: http://www.ncbi.nlm.nih.gov/pubmed/25087232

78. Zimmermann HW, Sterzer V, Sahin H. CCR1 and CCR2 antagonists. Curr Top

Med Chem [Internet]. 2014;14(13):1539–52. Available from: http://www.ncbi.nlm.nih.gov/pubmed/25159163

79. Zlotnik A, Yoshie O. The chemokine superfamily revisited. Immunity [Internet]. 2012 May 25;36(5):705–16. Available from: http://www.ncbi.nlm.nih.gov/pubmed/22633458

80. Luster AD, Unkeless JC, Ravetch J V. Gamma-interferon transcriptionally regulates an early-response gene containing homology to platelet proteins. Nature [Internet]. 1985;315(6021):672–6. Available from: http://www.ncbi.nlm.nih.gov/pubmed/3925348

81. Dufour JH, Dziejman M, Liu MT, Leung JH, Lane TE, Luster AD. IFN-gamma-inducible protein 10 (IP-10; CXCL10)-deficient mice reveal a role for IP-10 in effector T cell generation and trafficking. J Immunol [Internet]. 2002 Apr 1;168(7):3195–204. Available from: http://www.ncbi.nlm.nih.gov/pubmed/11907072

82. Angiolillo AL, Sgadari C, Taub DD, Liao F, Farber JM, Maheshwari S, et al. Human interferon-inducible protein 10 is a potent inhibitor of angiogenesis in vivo. J Exp Med [Internet]. 1995 Jul 1;182(1):155–62. Available from: http://www.ncbi.nlm.nih.gov/pubmed/7540647

83. Booth V, Keizer DW, Kamphuis MB, Clark-Lewis I, Sykes BD. The CXCR3 binding chemokine IP-10/CXCL10: structure and receptor interactions. Biochemistry [Internet]. 2002 Aug 20;41(33):10418–25. Available from: http://www.ncbi.nlm.nih.gov/pubmed/12173928

84. Sidney LE, Branch MJ, Dunphy SE, Dua HS, Hopkinson A. Concise review: evidence for CD34 as a common marker for diverse progenitors. Stem Cells [Internet]. 2014 Jun;32(6):1380–9. Available from: http://www.ncbi.nlm.nih.gov/pubmed/24497003

85. Antonioli L, Pacher P, Vizi ES, Haskó G. CD39 and CD73 in immunity and inflammation. Trends Mol Med [Internet]. 2013 Jun;19(6):355–67. Available from: http://www.ncbi.nlm.nih.gov/pubmed/23601906

86. Bono MR, Fernández D, Flores-Santibáñez F, Rosemblatt M, Sauma D. CD73 and CD39 ectonucleotidases in T cell differentiation: Beyond immunosuppression. FEBS Lett [Internet]. 2015 Nov 14;589(22):3454–60. Available from: http://www.ncbi.nlm.nih.gov/pubmed/26226423

87. Robberecht P, Gourlet P, De Neef P, Woussen-Colle MC, Vandermeers-Piret MC, Vandermeers A, et al. Structural requirements for the occupancy of pituitary adenylate-cyclase-activating-peptide (PACAP) receptors and adenylate cyclase activation in human neuroblastoma NB-OK-1 cell membranes. Discovery of PACAP(6-38) as a potent antagonist. Eur J Biochem [Internet]. 1992 Jul 1;207(1):239–46. Available from: http://www.ncbi.nlm.nih.gov/pubmed/1321043

88. Robberecht P, Gourlet P, De Neef P, Woussen-Colle MC, Vandermeers-Piret MC, Vandermeers A, et al. Receptor occupancy and adenylate cyclase activation in AR 4-2J rat pancreatic acinar cell membranes by analogs of pituitary adenylate cyclase-activating peptides amino-terminally shortened or modified at

position 1, 2, 3, 20, or 21. Mol Pharmacol [Internet]. 1992 Aug;42(2):347–55. Available from: http://www.ncbi.nlm.nih.gov/pubmed/1325033

89. Kojro E, Postina R, Buro C, Meiringer C, Gehrig-Burger K, Fahrenholz F. The neuropeptide PACAP promotes the alpha-secretase pathway for processing the Alzheimer amyloid precursor protein. FASEB J [Internet]. 2006 Mar;20(3):512–4. Available from: http://www.ncbi.nlm.nih.gov/pubmed/16401644

90. Dickinson T, Fleetwood-Walker SM, Mitchell R, Lutz EM. Evidence for roles of vasoactive intestinal polypeptide (VIP) and pituitary adenylate cyclase activating polypeptide (PACAP) receptors in modulating the responses of rat dorsal horn neurons to sensory inputs. Neuropeptides [Internet]. 1997 Apr;31(2):175–85. Available from: http://www.ncbi.nlm.nih.gov/pubmed/9179871

91. Ohno F, Watanabe J, Sekihara H, Hirabayashi T, Arata S, Kikuyama S, et al. Pituitary adenylate cyclase-activating polypeptide promotes differentiation of mouse neural stem cells into astrocytes. Regul Pept [Internet]. 2005 Mar 15;126(1–2):115–22. Available from: http://www.ncbi.nlm.nih.gov/pubmed/15620424

92. Leyton J, Gozes Y, Pisegna J, Coy D, Purdom S, Casibang M, et al. PACAP(6-38) is a PACAP receptor antagonist for breast cancer cells. Breast Cancer Res Treat [Internet]. 1999 Jul;56(2):177–86. Available from: http://www.ncbi.nlm.nih.gov/pubmed/10573110

93. Lénárd L, Lázár Z, Benkó R, Szigeti R, Báthori Z, Tóth GK, et al. Inhibitory effect of PACAP(6-38) on relaxations induced by PACAP, VIP and non-adrenergic, non-cholinergic nerve stimulation in the guinea-pig taenia caeci. Naunyn Schmiedebergs Arch Pharmacol [Internet]. 2000 May;361(5):492–7. Available from: http://www.ncbi.nlm.nih.gov/pubmed/10832602

94. Adamik A, Telegdy G. Effects of pituitary adenylate cyclase polypeptide (PACAP) on extinction of active avoidance learning in rats: involvement of neurotransmitters. Regul Pept [Internet]. 2005 Apr 15;127(1–3):55–62. Available from: http://www.ncbi.nlm.nih.gov/pubmed/15680470

95. Telegdy G, Adamik A. Neurotransmitter-mediated anxiogenic action of PACAP-38 in rats. Behav Brain Res [Internet]. 2015 Mar 15;281:333–8. Available from: http://www.ncbi.nlm.nih.gov/pubmed/25543171

96. Boni LJ, Ploug KB, Olesen J, Jansen-Olesen I, Gupta S. The in vivo effect of VIP, PACAP-38 and PACAP-27 and mRNA expression of their receptors in rat middle meningeal artery. Cephalalgia [Internet]. 2009 Aug;29(8):837–47. Available from: http://www.ncbi.nlm.nih.gov/pubmed/19220306

97. Lázár Z, Shahbazian A, Benkó R, Tóth G, Penke B, Barthó L, et al. PACAP-(6-38) inhibits the effects of vasoactive intestinal polypeptide, but not PACAP, on the small intestinal circular muscle. Eur J Pharmacol [Internet]. 2001 Nov 16;431(2):259–64. Available from: http://www.ncbi.nlm.nih.gov/pubmed/11728434

98. Jiang Q, Ko WKW, Lerner EA, Chan KM, Wong AOL. Grass carp somatolactin: I. Evidence for PACAP induction of somatolactin-alpha and -beta gene

expression via activation of pituitary PAC-I receptors. Am J Physiol Endocrinol Metab [Internet]. 2008 Aug;295(2):E463-76. Available from: http://www.ncbi.nlm.nih.gov/pubmed/18523122

99. Kaiser EA, Russo AF. CGRP and migraine: could PACAP play a role too? Neuropeptides [Internet]. 2013 Dec [cited 2018 Mar 4];47(6):451–61. Available from: http://www.ncbi.nlm.nih.gov/pubmed/24210136

100. Harmar AJ, Fahrenkrug J, Gozes I, Laburthe M, May V, Pisegna JR, et al. Pharmacology and functions of receptors for vasoactive intestinal peptide and pituitary adenylate cyclase-activating polypeptide: IUPHAR review 1. Br J Pharmacol [Internet]. 2012 May;166(1):4–17. Available from: http://www.ncbi.nlm.nih.gov/pubmed/22289055

FIGURES AND LEGENDS

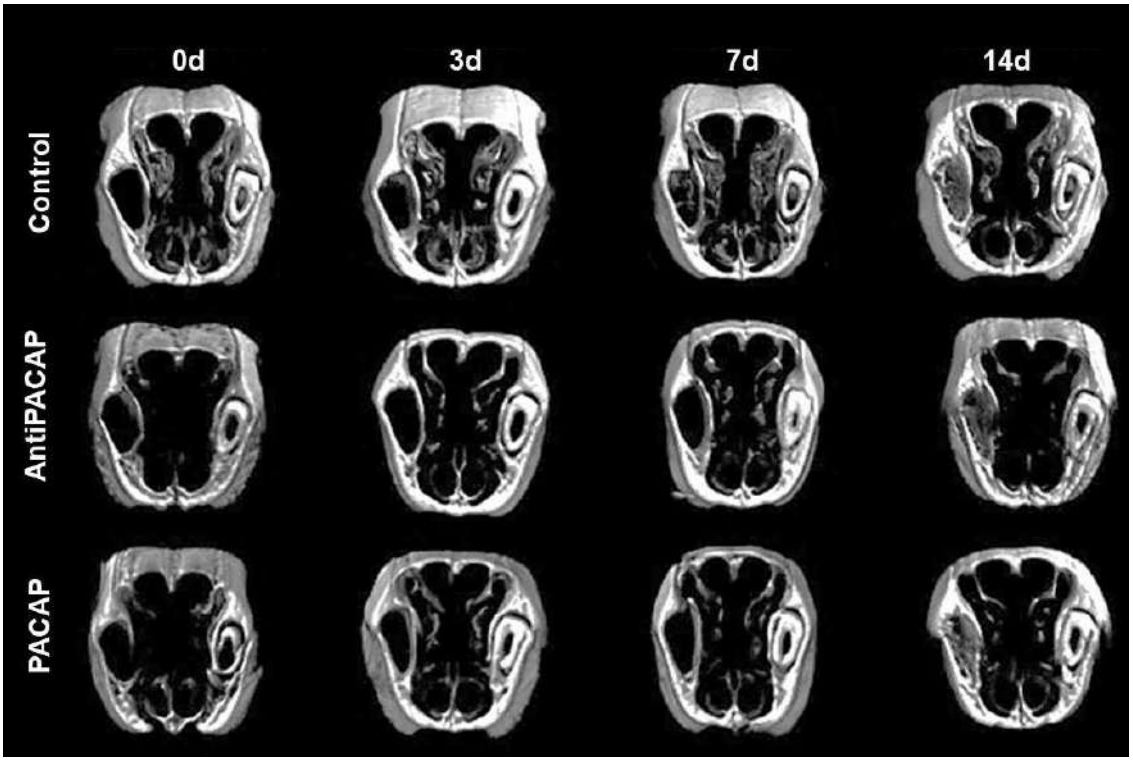

Figure 1. Three-dimensional morphological analysis by µCT of the alveolar bone healing process in mice control and treated with PACAP antagonist and PACAP groups in the periods 0, 3, 7- and 14-days post-exodontia. The images were reconstructed using the NRecon Reconstruction software and three-dimensional images obtained by the CTvox software. The maxillae were sectioned in the transversal plane.

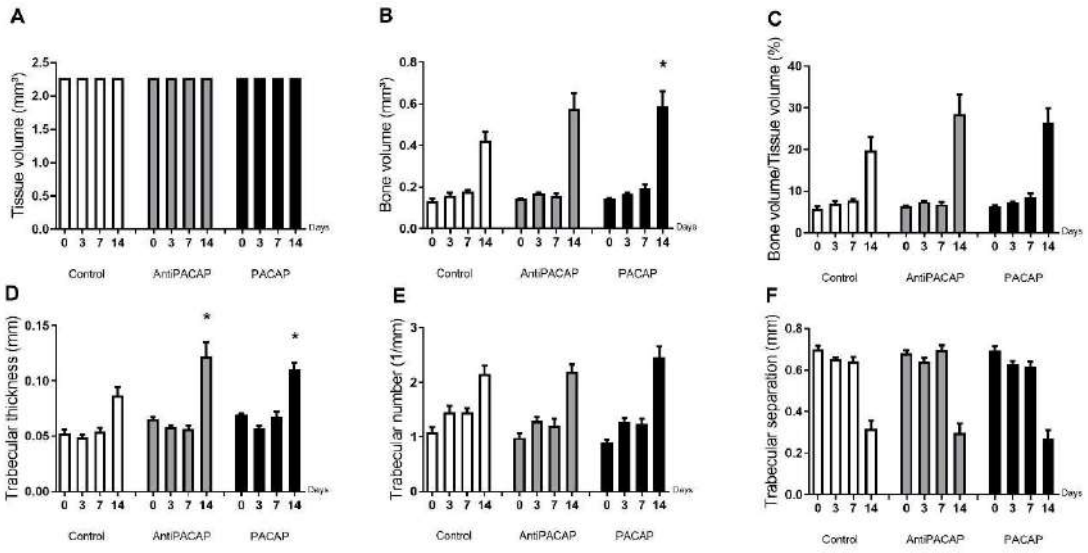

Figure 2. **Analysis of the morphological parameters of the trabecular bone microarchitecture in the dental alveolus of the control mice and treated with PACAP antagonist and PACAP in the periods of 0, 3, 7- and 14-days post-exodontia.** The morphological parameters of the bone microarchitecture were evaluated using the CTAn software through a cylindrical region of interest (ROI) determined by the segmentation of the trabecular bone located from the coronal to the apical region. The analysis of bone parameters (A-F) included: Tissue volume (mm3) (A), Bone volume (mm3) (B), Bone volume in relation to tissue volume (%) (C), Trabeculae thickness (mm) (D), Number of trabeculae (1/mm) (E), Separation of trabeculae (mm) (F). The results represent the values of the mean and standard deviation in each of the periods analyzed (*represent the differences between the control group).

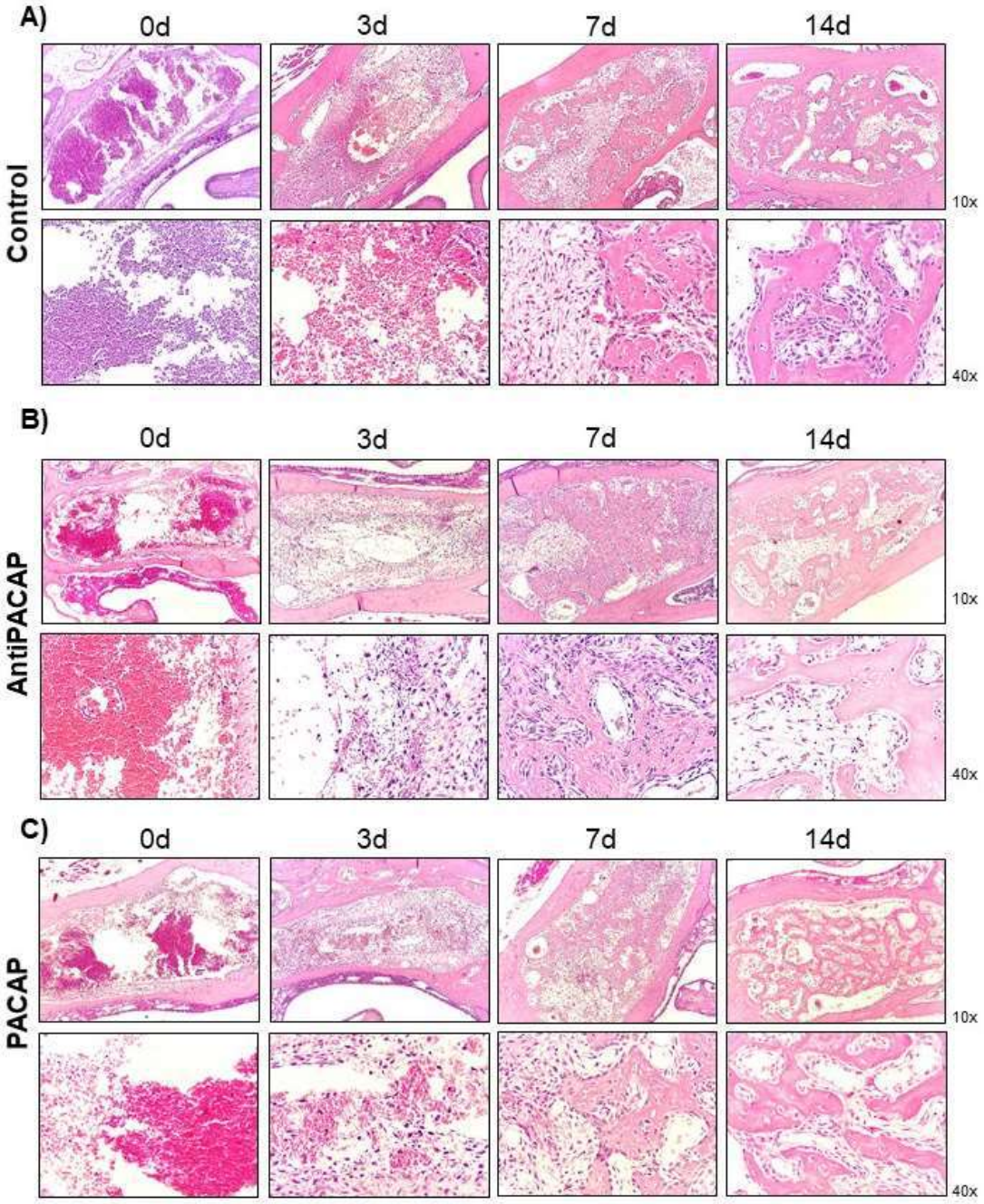

Figure 3. Histological analysis of the alveolar healing process in control mice (A) or treated with PACAP antagonist (B) and PACAP (C), in periods of 0, 3, 7- and 14-days post-exodontia. Photomicrographs representing the average region of the dental alveolus in 10x and 40x magnification; histological sections obtained after 0, 3, 7 and 14 days after exodontia, stained in HE.

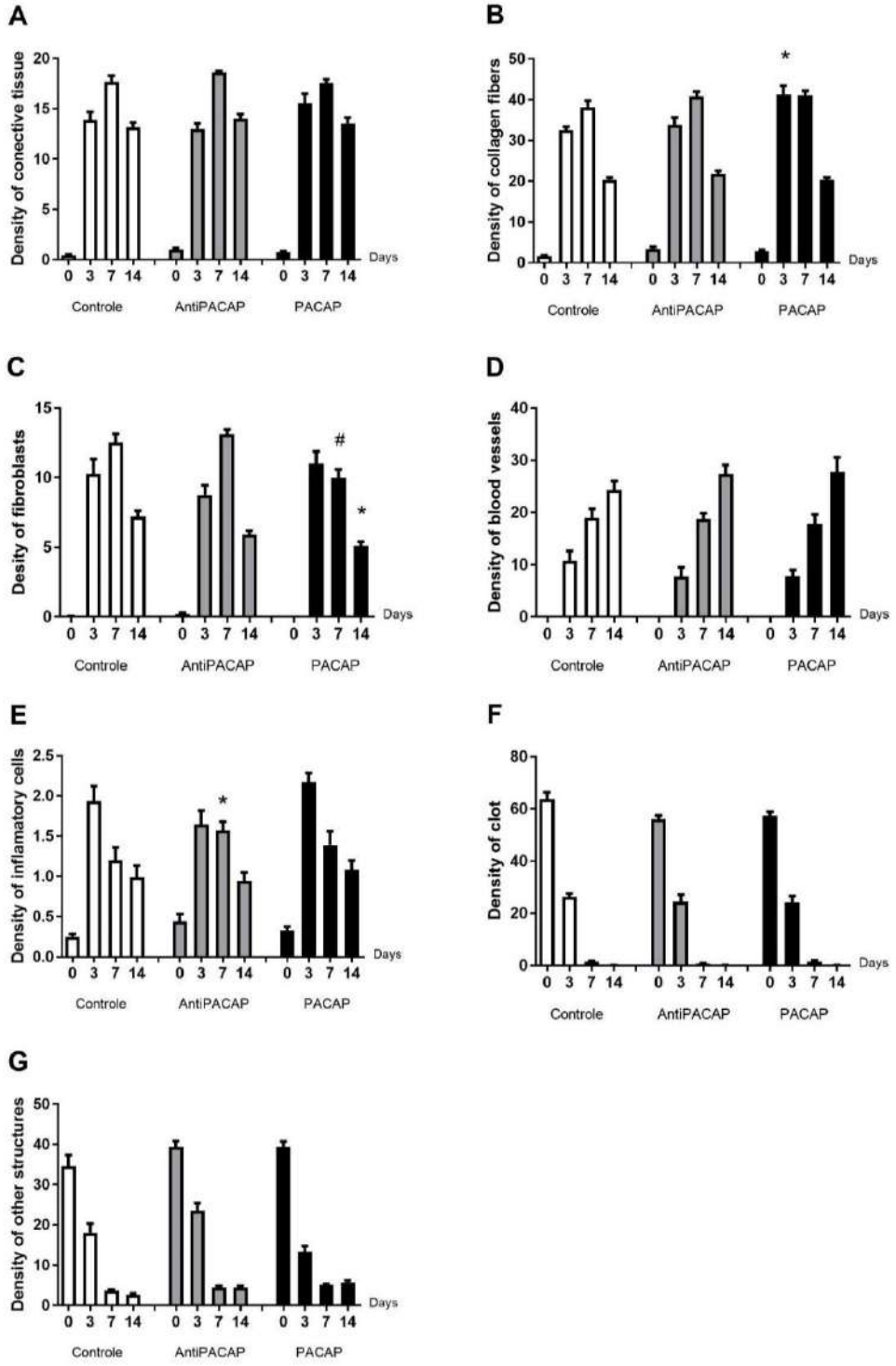

Figure 4. Comparative density analysis of connective tissue (A) and its components (B-G) present in the dental alveolus of control mice and treated with PACAP and PACAP antagonist in periods of 0, 3, 7- and 14-days post-exodontia. Results are presented as the means of density for each structure of the alveolar socket: collagen fibers, fibroblasts, blood vessels, inflammatory cells, clot and other components (empty space left by intercellular liquid and spaces). Also, the results depict the total density of connective tissue (represented by the sum of collagen fibers, fibroblasts, blood vessels and inflammatory cells) The results represent the values of the mean and standard deviation in each of the periods analyzed (*represent the differences between the control group; #represent the difference between PACAP and antiPACAP group).

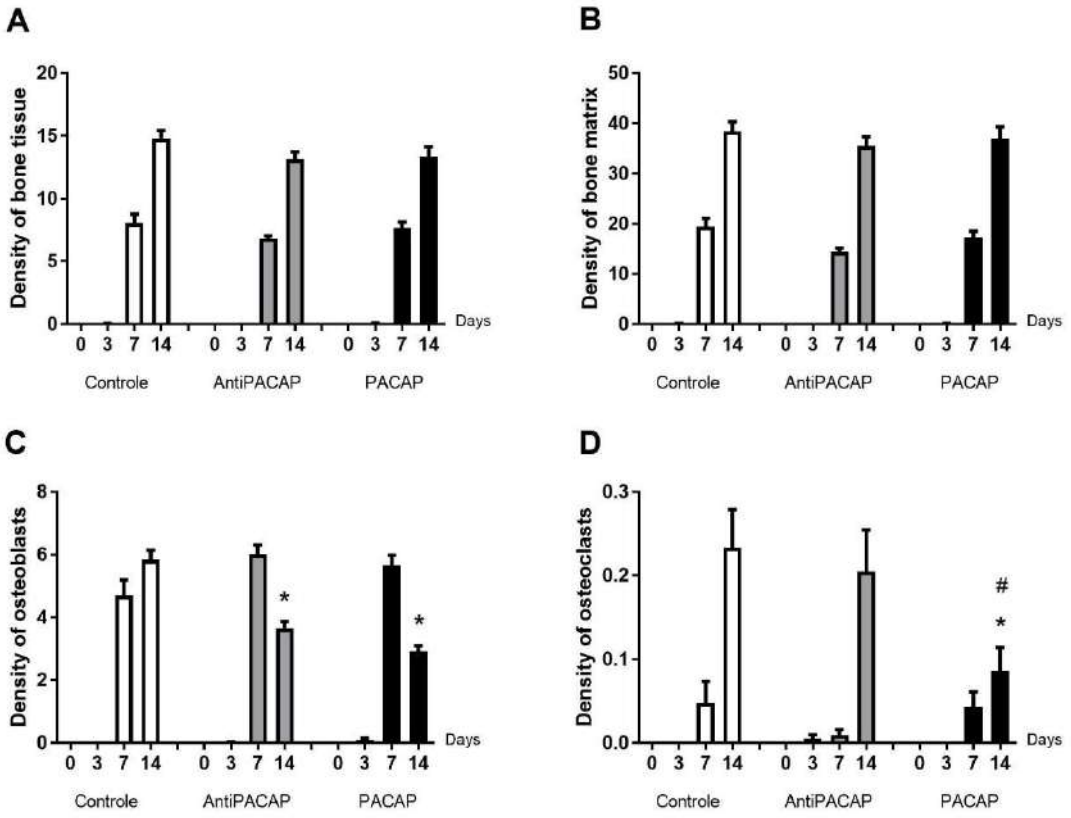

Figure 5. Comparative analysis of area density of bone tissue (A) and its components (B-D) present in the dental alveoli of control mice and treated with PACAP and PACAP antagonist in periods of 0h, 3, 7- and 14-days post-exodontia. Results are presented as the means of density for bone matrix, osteoblasts and osteoclasts. Also, the results depict the total density of bone tissue was represented by the sum of bone matrix, osteoblasts and osteoclasts. The results represent the values of the mean and standard deviation in each of the periods analyzed (*represent the differences between the control group; #represent the difference between PACAP and antiPACAP group).

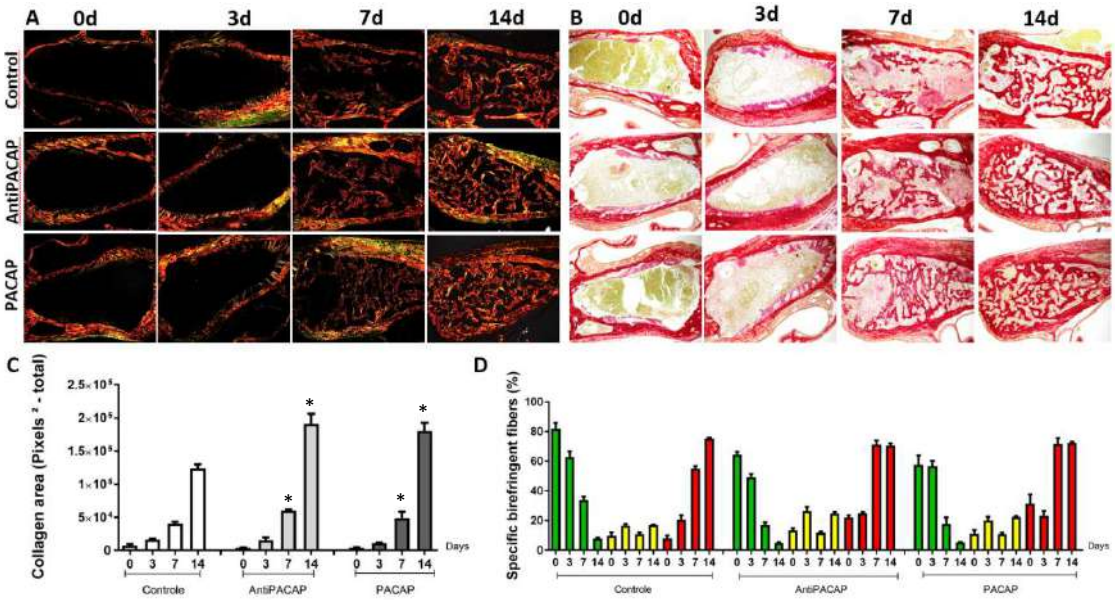

Figure 6. Analysis of birefringence of the collagen fibers present in the dental alveolus in the 0, 3, 7- and 14-days post-extraction periods, in the Control, PACAP antagonist and PACAP groups. Photomicrographs representing the middle region of the dental alveolus, captured under polarized (A) and non-polarized light (B), showing the deposition of few collagen fibers with birefringence in green, yellow and red at 0, 3, 7 and 14 days in all groups (Control, PACAP antagonist and PACAP). Coloring Picrosirius Red; 10x objective. (C) Quantitative analysis of the total area (pixels^2) occupied by birefringent collagenous fibers in the dental alveoli at periods 0, 3, 7- and 14-days post-exodontia, in the control and animals treated with PACAP Antagonist and PACAP. Periods of 0, 3, 7 and 14 days represented in relation to the area in pixels^2 of birefringent fibers within the green, yellow and red spectrum relative to the total area, throughout the experimental periods. The results represent the values of the mean and standard deviation in each of the periods analyzed. (D) Quantitative analysis of the area percentage of pixels^2 occupied by birefringent collagenous fibers in the dental alveolus at periods 0, 3, 7- and 14-days post-exodontia, in the control and PACAP antagonist and PACAP treated animals with. Periods of 0, 3, 7 and 14 days represented in relation to the area in pixels^2 of birefringent fibers within the green, yellow and red spectrum percentage to the total area, throughout the experimental periods. The results represent the values of the mean and standard deviation in each of the periods analyzed (*represent the differences between the control group).

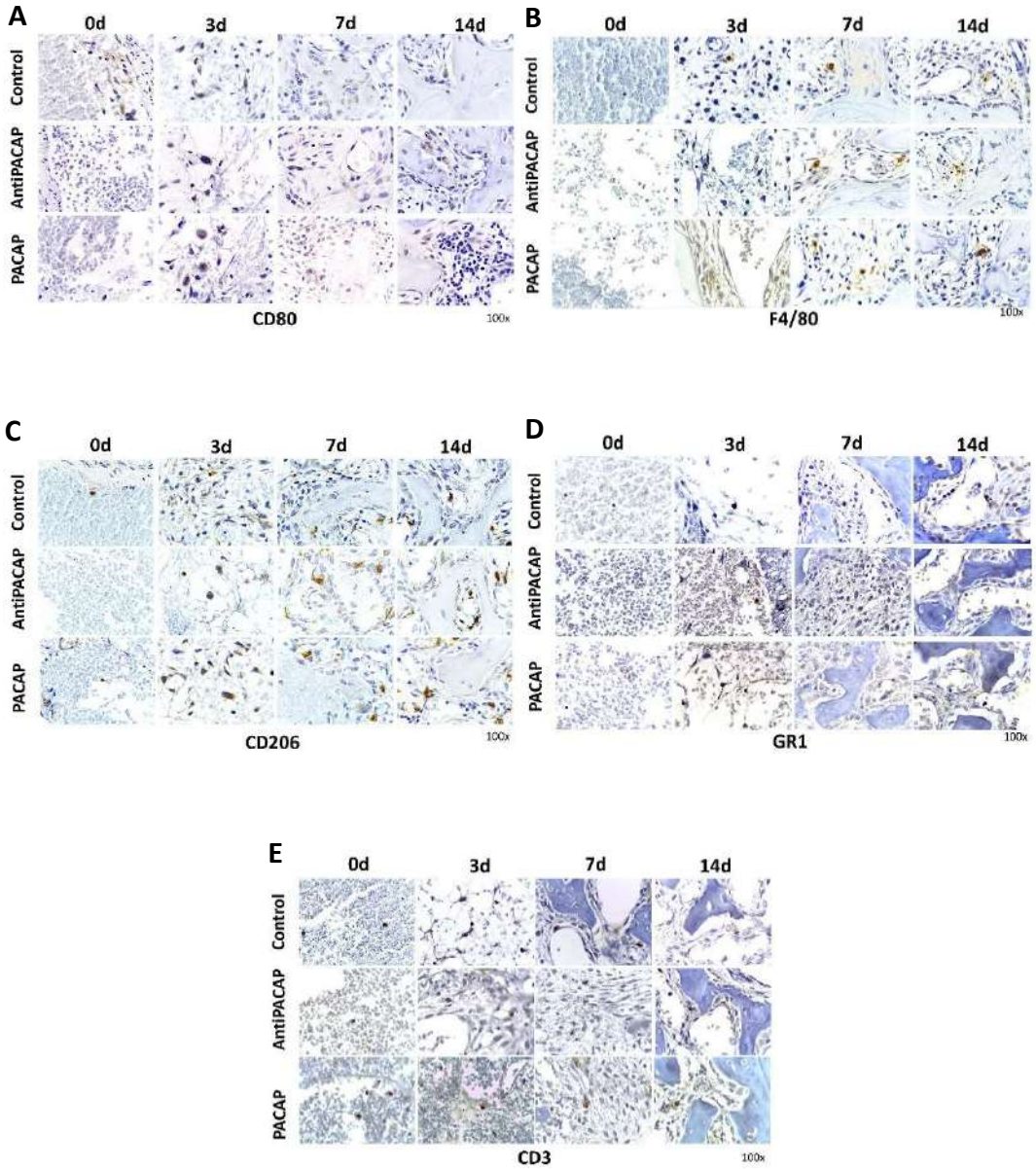

Figure 7. Immunohistochemistry analysis for (A) F4/80^{+}, (B) CD80^{+}, (C) CD206^{+}, (D) Ly6g- GR1^{+} and (E) CD3^{+}, cells present in the bone repair process in control, PACAP antagonist and PACAP. Representative sections from medial thirds of the socket at days 0, 3, 7 and 14 days after tooth extraction. Anti-staining Mayer's hematoxylin; objective of 100x.

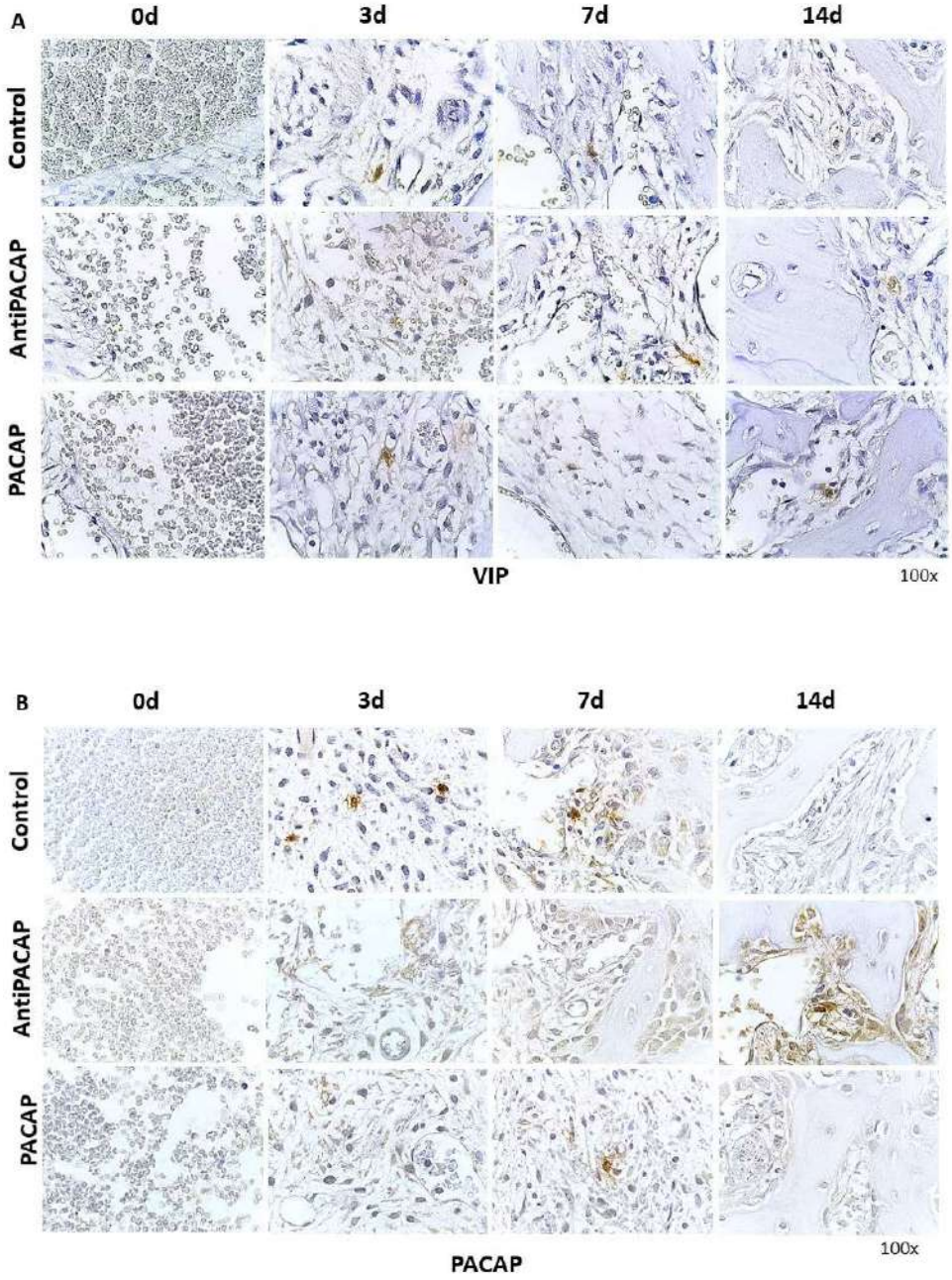

Figure 8. Immunohistochemistry analysis for (A) VIP$^+$ and (B) PACAP$^+$ cells present in the bone repair process in the control, PACAP antagonist and PACAP treated mice. Representative sections from medial thirds of the socket at days 0, 3, 7 and 14 days after tooth extraction. Anti-staining Mayer hematoxylin; objective of 100x.

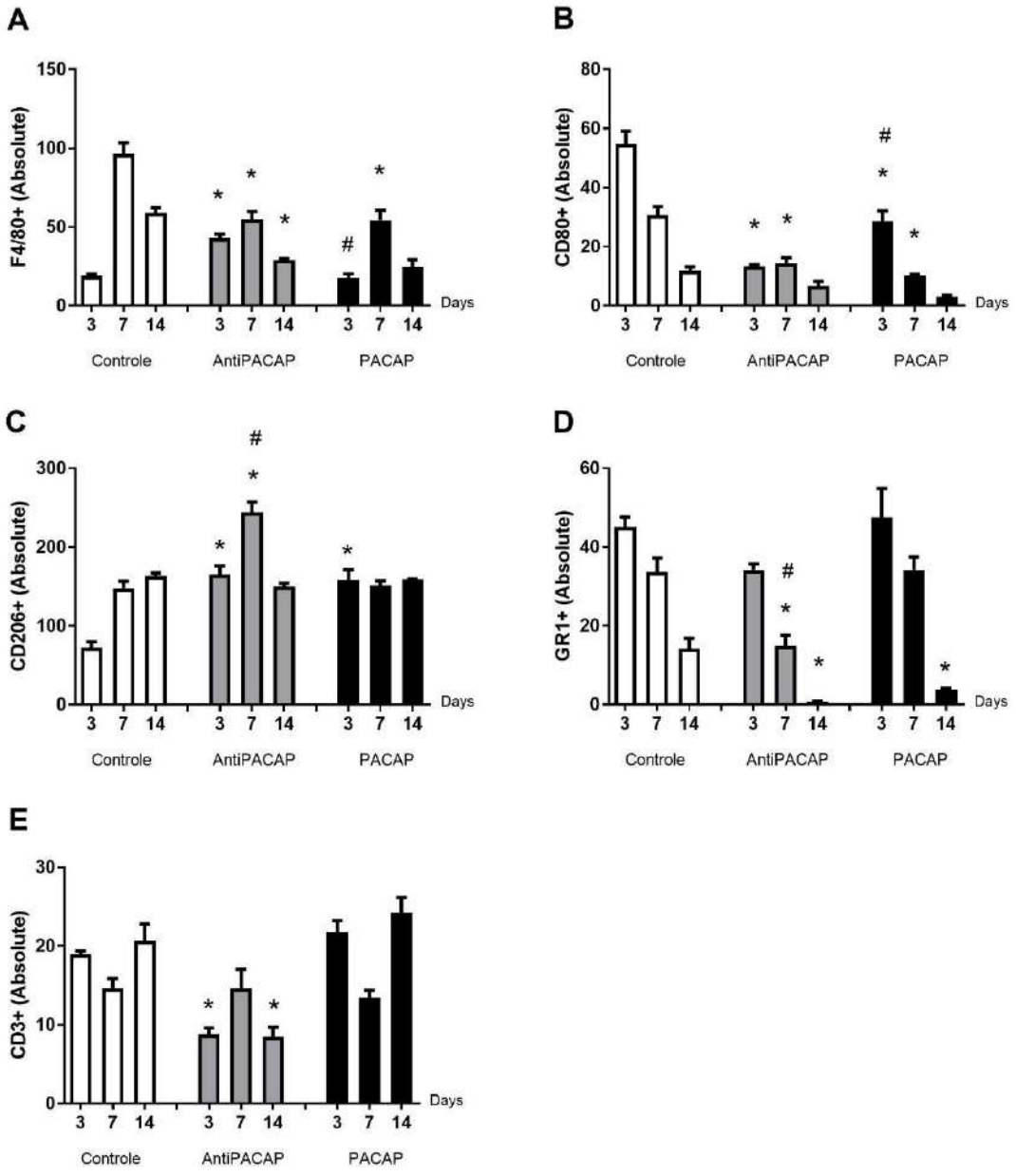

Figure 9. Analysis of inflammatory cells in the alveolar bone healing kinetics after tooth extraction in control, PACAP and PACAP Antagonist treated mice. Immunohistochemistry quantification corresponding (A) F4/80^{+}, (B) CD80^{+}, (C) CD206^{+}, (D) Ly6g-Gr1^{+} and (E) CD3 (*represent the differences between the control group; #represent the difference between PACAP and antiPACAP group).

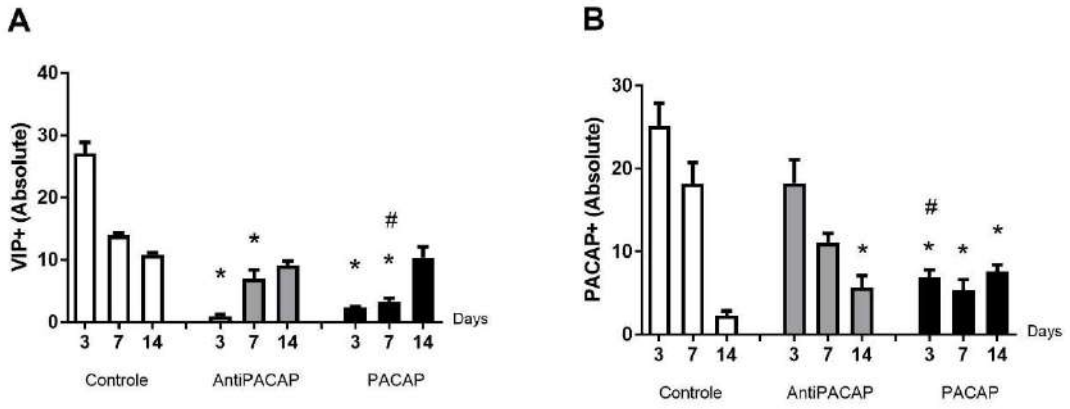

Figure 10. Analysis of inflammatory cells stained by VIP (A) and PACAP (B) in the alveolar bone healing kinetics after tooth extraction in control, PACAP and PACAP antagonist treated mice. (*represent the differences between the control group; #represent the difference between PACAP and antiPACAP group).

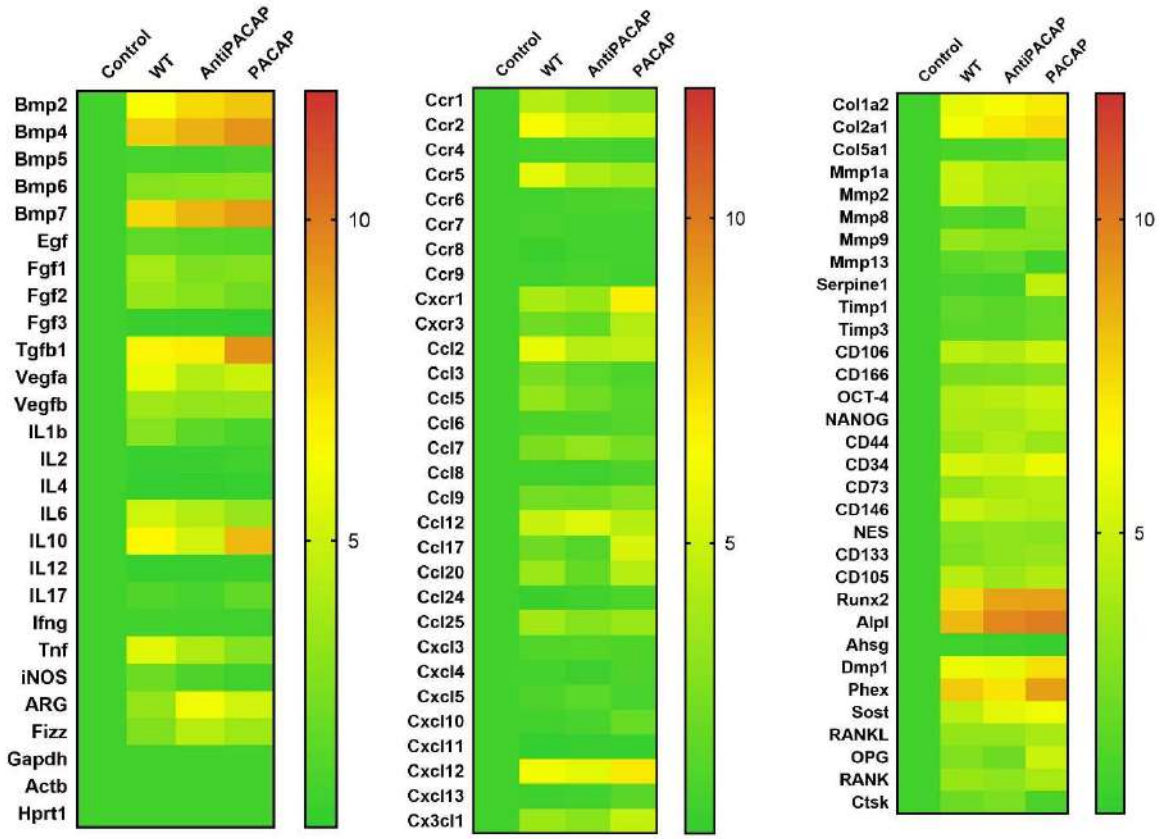

Figure 11. Molecular analysis (PCR Array) using Heat map to quantify the expression of the growth factors, extracellular matrix and bone markers and cytokines in bone healing process among control, PACAP antagonist and PACAP treated group post tooth extraction. Results were obtained when comparing the relative expression of the different groups to the normalizing control.

Article 2.3

Vasoactive intestinal peptide (VIP) immunoregulatory role at the periapex: associative and mechanistic evidences from human and experimental periapical lesions.

Michelle de Campos Soriani Azevedo (1),
Thiago Pompermaier Garlet (2)
Carolina Favaro Francisconi(1),
Priscila Maria Colavite (1),
André Petenuci Tabanez (1),
Jessica Lima Melchiades (1),
Ana Paula Favaro Trombone (3),
Charles Sfeir (5,6,7),
Steven Little (7,8),
Renato Menezes Silva (4),
Gustavo Pompermaier Garlet (1)

1. School of Dentistry of Bauru, University of São Paulo, Department of Biological Sciences; Bauru, SP, Brazil
2. State University of Ponta Grossa (UEPG), Department of Structural and Molecular Biology and Genetics, Ponta Grossa, Brazil;
3. Universidade do Sagrado Coração (USC); Bauru, SP, Brazil
4. Department of Endodontics, School of Dentistry, University of Texas Health Science Center at Houston
5. Center for Craniofacial Regeneration, University of Pittsburgh, Pittsburgh, PA, USA
6. Department of Periodontics and Preventive Dentistry, School of Dental Medicine, University of Pittsburgh, Pittsburgh, PA, USA.
7. McGowan Institute for Regenerative Medicine, University of Pittsburgh, Pittsburgh, PA, USA.
8. Department of Chemical and Petroleum Engineering, University of Pittsburgh, Pittsburgh,PA, USA

Keywords: Apical lesions; vasoactive intestinal peptide; regulatory T cells; cytokines; T helper; wound healing.

Conflicts of interest: The authors deny any conflicts of interest.

***Corresponding author:**
Gustavo Pompermaier Garlet
Bauru School of Dentistry (FOB/USP) - Department of Biological Sciences
Al. Octávio Pinheiro Brisola, 9-75 - CEP 17012-901 – Bauru - SP - Brazil
Phone +55 (14) 3235-8274 - Fax +55 (14) 3223-4679
Email: garletgp@usp.br

Abstract

Introduction: The balance between host pro-inflammatory immune response and counteracting anti-inflammatory and reparative responses supposedly determine the outcome of periapical lesions. In this scenario, the vasoactive intestinal peptide (VIP) may exert a protective role due its prominent immunoregulatory capacity. In this study, we investigated (in a cause-and-effect manner) the potential involvement of VIP in the development of human and experimental periapical lesions.

Methods: Periapical granulomas (N=124) and control samples (N=48) were comparatively assessed for VIP and multiple immunological/activity markers expression through Real Time PCR. Experimental periapical lesions (C57Bl/6 WT mice) were evaluated regarding endogenous VIP expression correlation with lesions development, and the effect of recombinant VIP therapy in lesions outcome. CCR4KO and IL4KO strains, and anti-GITR inhibition, were used to test the involvement of Tregs and Th2 cells in VIP-mediated effects.

Results: VIP expression was prevalent in periapical granulomas than in controls, presenting a positive association with immunoregulatory factors and an inverse association/correlation with pro-inflammatory mediators and RANKL/OPG ratio. Endogenous VIP expression upregulation was temporally associated with lesions immunoregulation and decline of bone loss. VIP therapy in mice prompted the arrest of lesions development, being associated with an anti-inflammatory and pro-reparative response that limits pro-inflammatory, Th1, Th17 and osteoclastogenic response in the periapex. VIP protective effect was dependent of Tregs migration and activity, and independent of IL-4.

Conclusion: Our results demonstrate that VIP overexpression in human and experimental periapical lesions is associated with lesions inactivity, and that VIP therapy result in the attenuation of experimental lesion progression associated with immunosuppressive response involving Tregs.

Keywords: Apical lesions; vasoactive intestinal peptide; regulatory T cells; cytokines; T helper; wound healing.

INTRODUCTION

The bacterial infection of the root canal system triggers a complex host inflammatory immune response, which ultimately determine the outcome of periapical lesions (1). Pro-inflammatory mediators and certain helper (Th) subsets, such as Th1 and Th17 cells, can independently or cooperatively mediate the breakdown of soft and mineralized tissues at periapex by locally increasing the proteolytic activity and bone resorption mechanisms (1–3).

Conversely, immunoregulatory mechanisms, involving mesenchymal stem cells (MSCs), Th2 and Tregs, can be activated throughout lesion development to counteract the pro-inflammatory and tissue destructive pathways, limiting further tissue destruction and even stimulating healing (1,4,5). Indeed, both MSCs, Th2 and Tregs are essential elements of immunoregulatory response that naturally takes place in experimental periapical lesions over time, which results in the switch of lesions phenotype into inactive/non-progressive state (4–6). Importantly, human periapical lesions support the protective role of such cellular subsets at periapex (4,7). However, the factors involved in the activation of MSCs and Tregs, which leads to the switch in the lesion's phenotype, remains unclear.

In this context, VIP (vasoactive intestinal peptide) have been described as a potent immunoregulatory molecule, which can also influence the biology of bone cells, via its widespread expressed VPAC1 e VPAC2 receptors (6,7). Indeed, VIP can inhibit Th1 and Th17 cells while boosting Th2 and Tregs activity (6–9), reinforcing its potential regulatory action in periapical lesions. In periapical lesions context, scarce previous studies describe the expression of VIP in chronic periapical lesions, in levels inversely proportional to lesion size (10,11). Additionally, intracanal calcium hydroxide resulted in increased VIP levels, suggesting its potential involvement in periapical healing (8).

However, the few studies to date only suggest a theoretical immunoregulatory role for VIP in periapical environment, which remains to be definitely confirmed in a cause-and-effect way. Therefore, in this study we investigated the patterns of VIP expression in human and experimental periapical lesions, as well the effect of recombinant VIP therapy in experimental lesions outcome. Additionally, the potential involvement of Th2 and Tregs in the immunoregulatory effects of VIP were investigated.

MATERIALS AND METHODS

Human periapical granulomas - This study was approved by the USP Institutional Review Board and comply with the Declaration of Helsinki. Subjects were patients (26–59-years-old; average 38.5) with periapical lesions, characterized radiographically as rarefaction lesions with the disappearance of the periodontal ligament space and discontinuity of the lamina dura; patients were referred to endodontic surgery after conventional root canal treatment had failed (12,13). Patients with medical conditions requiring the use of systemic modifiers of bone metabolism or other assisted drug therapy (i.e. systemic antibiotics, anti-inflammatory, hormonal therapy) during the last 6 months before initiation of the study, patients with pre-existing conditions such as periodontal disease, and pregnant or lactating women were excluded from the study. Periapical lesions were divided into 2 roughly similar fragments and stored in formalin (to histopathology) and RNALater (Thermo Fisher Scientific, Waltham, Massachusetts, EUA) (to molecular analysis). Only cases of periapical granulomas (n=124), represented by the presence of capillaries, inflammatory cells, fibroblasts, collagen, and macrophages and without the presence of an epithelial lining, were selected for the study; periapical cysts, in which cavities were further developed and lined by stratified squamous epithelium, or with the presence of proliferated epithelial strands, were excluded (12,14). Healthy periodontal ligament tissue samples (n=48) obtained from the periapex of premolars extracted for orthodontic purposes (patients aged 18–25 years) comprised the control specimens.

Experimental periapical lesions & treatments - Periapical lesion induction and quantification were performed as previously described (4,15). All animal experiments comply with the ARRIVE and NIH care and use of laboratory animals' guidelines. C57Bl/6 mice were anesthetized, and both right and left mandibular first molars dental pulp exposed (carbide bur, slow-speed handpiece) and inoculated with 1x106 (CFU) of each endodontic pathogen (*P. gingivalis* [ATCC33277], *P. nigrescens* [ATCC33563], *A. viscosus* [ATCC91014] and *F. nucleatum* [ATCC10953]) inoculation (4,5). Each experimental group were comprised by 10 (C57Bl/6, WT) mice/time point, resulting in 20 samples (both right and left molars), with 5 samples per group/time point for microscopic analysis, 5 for molecular (Real Time PCR), 5 for protein (ELISA) and 5 for cellular (flow cytometry) assays. Experimental groups comprising C57Bl/6 mice were

divided according to each treatment: Control (no lesion induction, no VIP treatment); Lesion (lesion induction, no VIP treatment); VIP (lesion induction, treated with recombinant VIP, Sigma; 0.1mg/kg/day, injected IP immediately after pulp exposure and subsequently until the last time point) (16); Saline (lesion induction, treated with Saline; following the same protocol described to VIP, data now shown). To address Tregs and Th2 involvement in VIP-mediated responses, and supplementary experiment was performed with C57Bl/6 (WT), CCR4KO (which presents in impaired Tregs migration) and IL4KO (which presents impaired Th2 response) mice (4,17), with the following groups: Control, Lesion and VIP (as described above) performed in WT, CCR4KO and IL4KO mice strains, and anti-GITR (treatment with purified mAb anti-GITR, 500µg/mice IP injection) and anti-GITR + VIP (combining both treatments), preformed only in WT mice. In this experimental setting each experimental group were comprised by 5 animals (10 samples) per group/time point, 5 samples for microscopic and 5 for molecular (Real Time PCR) assays. This study comprised a total of 215 mice. Animals were euthanized by cervical displacement and samples were prepared for histomorphometric analysis (right molars) or molecular/cellular (left molars) analysis. Results are depicted as the area of periapical space, measured in HE stained longitudinal 5-mm-thick sections by using ImageJ (NIH, Bethesda, MD), being the area increase over time representative of lesion development. The evolution of lesion development was calculated as fold increase in periapical space area within the 0–3, 3–7, 7–14, and 14–21 time point intervals (18).

Gene Expression and ELISA – Real Time PCR array reactions were performed as previously described (4). The extraction of total RNA from periapical tissues was performed with RNeasy (Qiagen Inc, Valencia, CA), followed by integrity analysis with 2100Bioanalyzer (Agilent Technologies, Santa Clara, CA) and complementary DNA synthesis (QuantiTectRT Kit, Qiagen Inc, Valencia, CA) all performed according to the manufacturers' instructions. Real Time PCR array was performed in a Viia7 instrument (Thermo Fisher Scientific, Waltham, Massachusetts, EUA) using inventoried optimized TaqMan primers/probes sets (Thermo Fisher Scientific, Waltham, Massachusetts, EUA) for human samples, and a custom panel for gene expression profiling (SABiosciences, Frederick, MD) for murine samples, analyzed by the RT2profiler software (SABiosciences, Frederick, MD) for normalizing target genes expression levels by constitutive genes (GAPDH, ACTB, Hprt1) and the respective controls. Gene

expression levels are expressed as fold change relative to the control group; as previously described (4). Measurements of cytokines IL-10, TGFβ1, TNF and RANKL in periapical lesions was performed by ELISA; as previously described (4,5), by commercially available kits (R&D Systems, Minneapolis, USA); results are expressed as picograms of cytokine (±SD) per milligram of periapical tissue.

Isolation and analysis of leukocytes from periapical tissues - Isolation and characterization of lesions Tregs were performed as described previously (4,5). Whole periapical tissues of molars apex were proteolytically processed using Medimachine (BDBiosciences, San Diego, CA, USA); followed by cell viability analysis (Trypan blue) and quantification (Neubauer chamber). Cells were incubated with optimal dilution of CD4, IFN-γ, IL17, IL4 and FOXp3 fluorochrome-conjugated antibodies (BDBiosciences, San Diego, CA, USA) and then analyzed by flow cytometry (FACScan and CellQuest; BDBiosciences, San Diego, CA, USA). Results represent the number of cells ± SD in the periapical tissues of each mouse, normalized by the tissue weight.

Statistical analysis - Data are presented as means ± SD, and the statistical significance between the groups was analyzed by Mann-Whitney or Kruskal-Wallis/Dunn's (GraphPadPrism 7.0, GraphPad Software Inc., San Diego, CA). PCRarray data was analyzed by the Mann-Whitney test followed by Benjamini-Hochberg test. Values of $P<0.05$ were considered statistically significant.

RESULTS

VIP expression in human and experimental periapical lesions and correction with the gene expression profile

VIP expression was significantly higher in the periapical granulomas lesions than controls (Fig. 1A). When human samples were categorized based in VIP expression levels into tertiles, VIP levels were positively associated with OPG, IL-4, IL-9, IL-10, FOXp3 and TGFβ1 expression, and inversely associated with RANKL, TNF, IFN, IL-17A, IL-21 and RANKL/OPG ratio (Fig.1B). Additional stratification of human samples based in RANKL/OPG ratio into tertiles, reiterate the opposite association between VIP levels and RANKL ratio (Fig.1C); and results in a very high match (91%) between the low VIP tertile with theoretical lesions activity based in RANKL/OPG ratio

(Fig.1C)(3,9,19). A similar profile of VIP expression was observed in experimental lesions, being the initial low VIP expression associated with the lesions progressive/active stage, characterized by the high expression of pro-inflammatory, proteolytic and osteoclastogenic elements, followed by the VIP upregulation in the non-progressive/inactive stage characterized by the prevalence of anti-inflammatory and healing mediators (Fig.2, Fig.3).

Modulation of experimental periapical lesions outcome by VIP

The administration of the recombinant VIP at 3d time point resulted in the early expression of endogenous VIP expression (analyzed at mRNA expression levels to avoid possible interference of exogenous VIP administered at protein state) and in the arrest of lesions progression (Fig.2). Accordingly, VIP treatment resulted in the early downregulation of pro-inflammatory, proteolytic and osteoclastogenic mediators and in the increase of anti-inflammatory and healing mediators (Fig.3). Similarly, ELISA analysis confirmed that VIP mediate the upregulation of IL-10 and TGFβ in the lesions of in parallel with TNF and RANKL downregulation (Fig.3). From the cellular viewpoint, VIP treatment limited the influx of CD4+IFNg+ and CD4+IL17+ cells and increased CD4+IL4+ counts in periapical area (Fig.4). VIP treatment also resulted in an early expression of CCL22 at periapex and preempted CD4+FOXp3+ cells influx (Fig.4). Importantly, the protective effect of VIP treatment was found to be dependent of Tregs function, being ineffective upon parallel Tregs inhibition with anti-GITR treatment, or in CCR4KO mice, which presents impaired Tregs migration (4,17). Conversely, VIP protective effect was IL4-independent, as demonstrated in IL4KO mice (Fig.4).

DISCUSSION

The balance between the host pro-inflammatory immune response and the counteracting anti-inflammatory and reparative responses seems to determine the outcome of periapical lesions (20). In this context, VIP appears as a potential immunoregulatory factor that could participate of the protective response at the periapex (6,7). Therefore, in this study we investigated the patterns of VIP expression in human and experimental periapical lesions, as well the effect of recombinant VIP therapy in experimental lesions outcome. Our results demonstrate that VIP expression was higher in the periapical granulomas lesions than controls, being positively

associated with the expression of anti-inflammatory and healing markers (i.e. OPG, IL-4, IL-9, IL-10, FOXp3 and TGFB1). Accordingly, a previous study describes the expression of VIP in human periapical lesions with an inverse correlation with lesions size (10,11). Additionally, the stratification of human samples based into tertiles based in VIP and/or RANKL/OPG ratio, reveals that VIP presents an inverse/opposite correlation with RANKL/OPG. It is important to mention that the low VIP tertile comprise the lesions with a RANKL/OPG ratio compatible with theoretical lesion activity, as previously suggested based in the comparison with RANKL/OPG patterns in sites with known active bone resorption (3,15,16,19,21). Indeed, a minor (14.28%) fraction of intermediate VIP expression quartile presents the active lesions signature (3,15,16,19,21), suggesting that even a moderate VIP expression can exert a significant immunoregulatory role at periapical environment.

While the human lesions derived data is transversal, the longitudinal analysis of experimental lesions development kinetics offer additional insights into VIP role in lesions pathogenesis. Our data demonstrate that VIP upregulation is temporally associated with the acquisition of a gene expression signature similar to that observed in inactive experimental lesions, and to be associated with a significantly reduced rate of bone resorption progression along the downregulation of pro-inflammatory, proteolytic and osteoclastogenic elements in parallel with the upregulation of anti-inflammatory and healing-related molecules. Such activity/inactivity features are in accordance with previous descriptions of experimental lesions development kinetics (4,21,22). Therefore, experimental lesions evolution pattern supports the human data, suggesting that VIP can limits lesions development and conceivably promote tissue healing. Accordingly, intracanal calcium hydroxide resulted in increased VIP levels, reinforcing VIP potential protective and pro-reparative capacity (8).

Analyzing the patterns of gene expression in human and experimental lesions, it becomes evident the association between VIP and certain T cell subsets with protective roles in periapical lesions pathogenesis, such as Th2 and Tregs. Accordingly, VIP was described to potentiate Th2 and Tregs activity, and to consequently limit the Th1 and Th17 responses (6,7,23,24), which could collectively account for the arrest of lesions progression associated with VIP levels. Indeed, the increase in VIP levels is temporally associated with the conversion/switch of the experimental lesion from active into inactive phenotype (4,21,22). Also, VIP

upregulation is temporally associated with the raise of Th2 and Tregs response, both functionally associated with the attenuation of the progression of these lesions (4,21,22), suggesting that VIP could act as trigger of protective Th responses at periapical environment, as described in other chronic inflammation models (25,26). In order to test if VIP actually contribute to periapical lesions inactivity and to healing response in a cause-and-effect manner, mice was treated with recombinant VIP starting at 3d time point, when the endogenous expression of VIP in the lesions is still very low. Our results demonstrate that VIP treatment prompted the arrest of lesions progression and resulted in a molecular signature compatible with inactive lesions profile (13,27), which was reinforced by the ELISA analysis. Accordingly, VIP was described to arrest experimental arthritis progression, which share some immunopathological features with periapical lesions (25,28).

Looking for possible mechanisms underlying VIP protective function in periapical milieu, we observed that VIP treatment limited the infiltration of potentially pathogenic Th1 and Th17 cells in the lesions (1), in accordance with the association described for the endogenous VIP expression kinetics with lesions profile. Also, VIP induced the early expression of endogenous VIP and the chemokine CCL22 in the lesions, prompted Tregs influx into the periapical area and increased Th2 cells counts in the lesions. Accordingly, CCL22 was described to mediate Tregs migration to periapex via CCR4 receptor, and to consequently arrest lesions progression (17). Additionally, IL-4 production by Th2 cells was described to induce CCL22 expression (17), as part of the protective IL-4/CCL22/CCR4 pathway. Additional experiments confirmed the involvement of Tregs in the VIP-protective effect, since the inhibition of Tregs migration (in CCR4KO mice) or activity (with anti-GITR) abrogated the protection in VIP treated mice. Accordingly, human lesions data support the VIP-Tregs connection hypothesis in the view of a very significant correlation observed between the VIP and Tregs markers FOXp3, IL-10 and TGFβ1 (data not shown). As previously mentioned, the synergy between VIP and Tregs in immunoregulation process was described in other inflammatory conditions (29). However, despite the increase in Th2 cells migration due VIP therapy, VIP protective effect was IL4-independent, as demonstrated in IL4KO mice (Fig.4). While some studies describe a Th2-inducing effect of VIP (30), others describe that VIP can inhibit IL-4 transcription, highlighting the complexity of such interplay (31–33). As previously mentioned, IL-4 protective effects involves the

induction of CCL22, which allows the Tregs migration via CCR4 (17). Nevertheless, since our data demonstrate that VIP prompted CCL22 expression, it may overcome the IL-4 absence. Accordingly, VIP was described to induce the CCL22 expression (34). Additionally, the local release of recombinant CCL22 was found to overcome the overcome IL-4 deficiency by a direct induction of Tregs migration (17), and to promote Treg migration when applied in the root canal system, and to consequently arrest lesions progression (4).

Importantly, while the exact source of VIP, originally described as a neuropeptide, at periapical environment remains to be established, increasing evidences support the immunoregulatory properties of nervous system (35). Indeed, while neuroimmune interactions, mediated by different neuropeptides were initially described as pro-inflammatory, have been demonstrated to be quite more complex and to operate towards restoring homeostasis by controlling the duration and intensity of inflammation through multiple mechanisms (35). Accordingly, VIP have been demonstrated to be a "neuroimmunopeptide" with a broad spectrum of immunoregulatory functions and as a potential pharmacological target to the clinical management of inflammatory conditions (35,36).

Therefore, considering the associative and mechanistic demonstrations derived from human and experimental periapical lesion, it is possible to conclude that VIP presents an active immunoregulatory action at periapical environment, acting in Treg-dependent manner to switch active periapical lesions into an inactivity phenotype, which may comprise a potential therapeutic strategy for periapical lesions clinical management.

CONCLUSION

Our results demonstrate that VIP presents an active immunoregulatory action in periapical granuloma pathogenesis. From the mechanistic viewpoint, VIP induces Treg chemoattraction to the periapical area is mediated by the induction of CCL22. Treatments based in the delivery of VIP at periapical area, as part of an intracanal medicament used between appointments or delivered before obturation, potentially can be clinically explored as an complementary (to routine cleaning and shaping procedures) strategy to maximize tissue repair at the periapical region.

ACKNOWLEDGMENTS

The authors would like to thank Daniele Ceolin, Patricia Germino and Tania Cestari for their excellent technical assistance. This study was supported by grants and scholarships form FAPESP (15/25618-2, 15/24637-3), NIH-NIDCR (1R01DE021058-01 and 1R56DE021058-01), CNPq and CAPES. The authors deny any conflicts of interest related to this study.

FIGURES LEGENDS

Figure 1. Patterns of VIP and immunological, bone and healing markers expression in human periapical lesions. Total RNA was extracted from periapical granulomas (N=124) and periodontal ligament control samples (N=48), and levels of VIP and immunological, bone and healing markers were quantitatively measured by Real Time PCR TaqMan system. A) Control samples and periapical granulomas were comparatively evaluated regarding the VIP and immunological, bone and healing markers; *P<0.05 unpaired t-test, control versus lesions. B) Periapical granulomas were submitted to a tertile stratification based in the VIP expression levels. The tertiles with low to high VIP are designated as T1 (low), T2 (intermediate) and T3 (high), and were compared in regards to the expression of immunological, bone and healing markers; Kruskal Wallis/Dunns post-test, *P<0.05 T1 vs T2, #P<0.05 T1 vs T3, +P<0.05 T2 vs T3. C) Periapical granulomas were submitted to a tertile stratification based in the RANKL/OPG ratio. The tertiles with low to high RANKL/OPG ratio are designated as T1 (low), T2 (intermediate) and T3 (high), and were compared in regards to the expression of immunological, bone and healing markers; Kruskal Wallis/Dunns post-test, *P<0.05 T1 vs T2, #P<0.05 T1 vs T3, +P<0.05 T2 vs T3. Still in C panel, the theoretical categorization of the lesion into active or inactive profile based in RANKL/OPG ratio was applied and depicted in the lower end of the figure with dotted lines; *P<0.05 unpaired t-test active vs inactive lesions, depicted in the right side of the graph.

Figure 2. VIP expression kinetics and its impact on the periapical bone loss and in VIP endogenous expression in experimental periapical lesions in mice. Periapical lesion induction (pulp exposure and bacterial inoculation) was performed in C57Bl/6 mice; experimental groups were divided according to each treatment: Control (no lesion treatment); VIP (lesion induction, treated with recombinant VIP, Sigma; 0.1mg/kg/day, injected IP immediately after pulp exposure and subsequently until the last time point) (16); Saline (lesion induction, treated with Saline, data now shown) (A). Samples from experimental and control groups were collected for histomorphometric (N=5/group/time point) and molecular analysis (N=5/group/time point), and evaluated for: (B) VIP expression in WT untreated mice measured quantitatively by Real Time PCR TaqMan system; (C) kinetics of periapical lesion development from 0 to 21d in control and VIP treated mice, presented as periapical space area (mm^2) increase; (D) modulation of endogenous VIP expression by VIP treatment measured quantitatively by Real Time PCR TaqMan system; (E) correlation between VIP expression and the lesion evolution index

(evolution of lesion development was calculated as fold increase in periapical space area within the 0–3, 3–7, 7–14, and 14–21 time point intervals). In A different letters represent statistically significant differences among the different time points within its respective groups (P<0.05; One-way ANOVA, Bonferroni post-test); asterisks (*) represent statistically significant differences (P<0.05; Mann-Whitney test) vs control in each time point. In B and C asterisks (*) represent statistically significant differences (P<0.05; Mann-Whitney test) vs control in each time point, and the hashtag (#) represent statistically significant differences (P<0.05; Mann-Whitney test) between the lesion and VIP group in each time point. In D, linear regression analysis values are depicted.

Figure 3. Effects of VIP treatment in the expression and production of healing and inflammatory/immunological markers in experimental periapical lesions in mice. Periapical lesion induction (pulp exposure and bacterial inoculation) was performed in C57Bl/6 mice; experimental groups were divided according to each treatment: control (no lesion induction, no VIP treatment); Lesion (lesion induction, no VIP treatment); VIP (lesion induction, treated with recombinant VIP, Sigma; 0.1mg/kg/day, injected IP immediately after pulp exposure and subsequently until the last time point) (16); Saline (lesion induction, treated with Saline, data now shown). Samples from experimental and control groups were analyzed regarding the expression of wound healing-related genes and inflammatory and immunological-related markers at 7d (A) and 14d (B) time points (N=5/group/time point), by RealTimePCR TaqMan system, and (C) cytokine levels in periapical lesions, measured by ELISA, presented as cytokine pg/mg of periapical tissue (N=5/group/time point). In A and B, the expression of all factors analyzed was significantly different in the lesions (treated or not with VIP) when compared to the controls; #P<0.05 lesion vs VIP (Mann-Whitney test); in C #P<0.05 lesion vs VIP (Mann-Whitney test).

Figure 4. Effects of VIP treatment in the influx of Th subsets and CCL22 expression in experimental periapical lesions in mice, and involvement of Tregs and Th2 cells in VIP-mediated protection against lesions development. Periapical lesion induction (pulp exposure and bacterial inoculation) was performed in C57Bl/6 mice; experimental groups were divided according to each treatment: Control (no lesion induction, no VIP treatment); Lesion (lesion induction, no VIP treatment); VIP (lesion induction, treated with recombinant VIP, Sigma; 0.1mg/kg/day, injected IP immediately after pulp exposure and subsequently until the last time point) (16); Saline (lesion induction, treated with Saline, data now shown). Samples from the different experimental groups strains from control and experimental groups(N=5/group/time point) were collected and evaluated for: (A) Th1 (CD4+IFNγ+), (B) Th17 (CD4+IL17+), (C) Th2 (CD4+IL4+) and (D) Tregs (CD4+FOXp3+) cells count in periapical tissues of WT and VIP treated mice, analyzed by flow cytometry at 0, 3, 7, 14 and 21 days post infection; depicted as the cell number x104. To address Tregs and Th2 involvement in VIP-mediated responses, and supplementary experiment was performed with C57Bl/6 (WT), CCR4KO (which presents in impaired Tregs migration) and IL4KO (which presents impaired Th2 response) mice (4,17), with the following groups: Control, Lesion and VIP (as described above) performed in WT, CCR4KO and IL4KO mice strains, and anti-GITR (treatment with purified mAb anti-GITR, 500µg/mice IP injection) and anti-GITR

+VIP (combining both treatments), preformed only in WT mice (E). Samples (N=5/group/time point) were collected and evaluated for: (F) periapical lesion development, presented as periapical space area (mm2) increase after lesions induction; and (G) kinetics of CCL22 expression and its modulation by VIP treatment, measured quantitatively by Real Time PCR TaqMan system. In A-D asterisks (*) represent statistically significant differences (P<0.05; Mann-Whitney test) vs control in each time point, and the hashtag (#) represent statistically significant differences (P<0.05; Mann-Whitney test) between the lesion and VIP group in each time point. In F, (*) represent statistically significant differences (P<0.05; Mann-Whitney test) vs control and the hashtag (#) represent statistically significant differences (P<0.05; Mann-Whitney test) between the lesion and VIP groups; in G, asterisks (*) represent statistically significant differences (P<0.05; Mann-Whitney test) vs control in each time point, (#) represent statistically significant differences (P<0.05; Mann-Whitney test) between the lesion (untreated) and VIP treated groups in each strain.

REFERENCES

1. Graves DT, Oates T, Garlet GP. Review of osteoimmunology and the host response in endodontic and periodontal lesions. J Oral Microbiol. 2011; 17;3.

2. Čolić M, Gazivoda D, Vučević D, Vasilijić S, Rudolf R, Lukić A. Proinflammatory and immunoregulatory mechanisms in periapical lesions. Mol Immunol. 2009; 47(1):101-13.

3. Araujo-Pires AC, Francisconi CF, Biguetti CC, Cavalla F, Aranha AMF, Letra A, et al. Simultaneous analysis of T helper subsets (Th1, Th2, Th9, Th17, Th22, Tfh, Tr1 and Tregs) markers expression in periapical lesions reveals multiple cytokine clusters accountable for lesions activity and inactivity status. J Appl Oral Sci. 2014;22(4):336-46.

4. Francisconi CF, Vieira AE, Biguetti CC, Glowacki AJ, Trombone APF, Letra A, et al. Characterization of the Protective Role of Regulatory T Cells in Experimental Periapical Lesion Development and Their Chemoattraction Manipulation as a Therapeutic Tool. J Endod. 2016;42(1):120-6.

5. Francisconi CF, Vieira AE, Azevedo MCS, Tabanez AP, Fonseca AC, Trombone APF, et al. RANKL Triggers Treg-Mediated Immunoregulation in Inflammatory Osteolysis. J Dent Res. 2018;97(8):917-927.

6. Souza-Moreira L, Campos-Salinas J, Caro M, Gonzalez-Rey E. Neuropeptides as pleiotropic modulators of the immune response. Neuroendocrinology. 2011;94(2):89-

7. Ganea D, Rodriguez R, Delgado M. Vasoactive intestinal peptide and pituitary adenylate cyclase-activating polypeptide: players in innate and adaptive immunity. Cell Mol Biol (Noisy-le-grand). 2003;49(2):127-42.

8. Özdemir MB, Karataş E, Albayrak M, Bayır Y. Effect of intracanal medicaments on matrix metalloproteinase-9 and vasoactive intestinal peptide secretion in periapical lesions of re-treated canals: a randomized controlled clinical study. Clin Oral Investig. 2018;15;1– 8.

9. Araujo-Pires AC, Biguetti CC, Repeke CE, Rodini C de O, Campanelli AP, Trombone APF, et al. Mesenchymal stem cells as active prohealing and immunosuppressive agents in periapical environment: evidence from human and experimental periapical lesions. J Endod. 2014;40(10):1560-5.

10. Caviedes-Bucheli J, Azuero-Holguín MM, Moreno GC, González IL, Mateu E, Salazar JF, et al. Vasoactive intestinal peptide receptor expression in chronic periapical lesions. Int Endod J. 2007;40(7):521-5.

11. Azuero-Holguin MM, Leal-Fernandez MC, Restrepo-Mejia LM, Velandia-Daza G, Guzman-Quimbayo F, Urquiza-Martinez M. Identification and Quantification of Vasoactive Intestinal Peptide in Periradicular Lesions. J Endod. 2003;29(9):557-8.

12. Cavalla F, Biguetti C, Jain S, Johnson C, Letra A, Garlet GP, et al. Proteomic Profiling and Differential Messenger RNA Expression Correlate HSP27 and Serpin Family B Member 1 to Apical Periodontitis Outcomes. J Endod. 2017;43(9):1486-1493.

13. Garlet GP, Horwat R, Ray HL, Garlet TP, Silveira EM, Campanelli AP, et al. Expression Analysis of Wound Healing Genes in Human Periapical Granulomas of Progressive and Stable Nature. J Endod. 2012;38(2):185-90.

14. Menezes R, Garlet TP, Trombone APF, Repeke CE, Letra A, Granjeiro JM, et al. The potential role of suppressors of cytokine signaling in the attenuation of inflammatory reactio n and alveolar bone loss associated with apical periodontitis. J Endod. 2008;34(12):1480-4.

15. Fukada SY, Silva TA, Saconato IF, Garlet GP, Ávila-Campos MJ, Silva JS, et al. iNOS -derived Nitric Oxide Modulates Infection-stimulated Bone Loss. J Dent Res. 2008;87(12):1155-9.

16. Delgado M, Abad C, Martinez C, Leceta J, Gomariz RP. Vasoactive intestinal peptide prevents experimental arthritis by downregulating both autoimmune and inflammatory components of the disease. Nat Med. 2001;7(5):563-8.

17. Araujo-Pires AC, Vieira AE, Francisconi CF, Biguetti CC, Glowacki A, Yoshizawa S, et al. IL- 4/CCL22/CCR4 axis controls regulatory T-cell migration that suppresses inflammatory bone loss in murine experimental periodontitis. J Bone Miner Res. 2015;30(3).

18. Aranha AMF, Repeke CE, Garlet TP, Vieira AE, Campanelli AP, Trombone APF, et al. Evidence supporting a protective role for Th9 and Th22 cytokines in human and experimental periapical lesions. J Endod. 2013;39(1):83–7.

19. Menezes R, Garlet TP, Letra A, Bramante CM, Campanelli AP, Figueira R de C, et al. Differential patterns of receptor activator of nuclear factor kappa B ligand/osteoprotegerin expression in human periapical granulomas: possible association with progressive or stable nature of the lesions. J Endod. 2008;34(8):932-8.

20. Walker KF, Lappin DF, Takahashi K, Hope J, Macdonald DG, Kinane DF. Cytokine expression in periapical granulation tissue as assessed by immunohistochemistry. Eur J Oral Sci. 2000;108(3):195–201.

21. Mukohyama H, Ransjö M, Taniguchi H, Ohyama T, Lerner UH. The Inhibitory Effects of Vasoactive Intestinal Peptide and Pituitary Adenylate Cyclase-Activating Polypeptide on Osteoclast Formation Are Associated with Upregulation of Osteoprotegerin and Downregulation of RANKL and RANK. Biochem Biophys Res Commun. 2000; 271(1):158- 63.

22. Linden GJ, Mullally BH, Burden DJ, Lamey PJ, Shaw C, Ardill J, et al. Changes in vasoactive intestinal peptide in gingival crevicular fluid in response to periodontal treatment. J Clin Periodontol. 2002;29(6):484–9.

23. Leceta J, Gomariz RP, Martinez C, Carrión M, Arranz A, Juarranz Y. Vasoactive intestinal peptide regulates Th17 function in autoimmune inflammation. Neuroimmunomodulation. 2007;14(3–4):134–8.

24. Tan Y-V, Abad C, Wang Y, Lopez R, Waschek J. VPAC2 (vasoactive intestinal peptide receptor type 2) receptor deficient mice develop exacerbated experimental autoimmune

encephalomyelitis with increased Th1/Th17 and reduced Th2/Treg responses. Brain Behav Immun. 2015;44:167-175.

25. Deng S, Xi Y, Wang H, Hao J, Niu X, Li W, et al. Regulatory effect of vasoactive intestinal peptide on the balance of Treg and Th17 in collagen-induced arthritis. Cell Immunol. 2010;265(2):105–10.

26. Tan Y-V, Waschek JA. Targeting VIP and PACAP Receptor Signalling: New Therapeutic Strategies in Multiple Sclerosis. ASN Neuro. 2011; 6;3(4).

27. Garlet GP. Destructive and Protective Roles of Cytokines in Periodontitis: A Re-appraisal from Host Defense and Tissue Destruction Viewpoints. J Dent Res. 2010;89(12):1349- 63.

28. Villanueva-Romero R, Gutiérrez-Cañas I, Carrión M, Pérez-García S, Seoane I V., Martínez C, et al. The Anti-Inflammatory Mediator, Vasoactive Intestinal Peptide, Modulates the Differentiation and Function of Th Subsets in Rheumatoid Arthritis. J Immunol Res. 2018; 6043710.

29. Tan Y-V, Abad C, Lopez R, Dong H, Liu S, Lee A, et al. Pituitary adenylyl cyclase-activating polypeptide is an intrinsic regulator of Treg abundance and protects against experimental autoimmune encephalomyelitis. Proc Natl Acad Sci U S A. 2009;10;106(6):2012-7.

30. Delgado M, Leceta J, Gomariz RP, Ganea D. Vasoactive intestinal peptide and pituitary adenylate cyclase-activating polypeptide stimulate the induction of Th2 responses by up-regulating B7.2 expression. J Immunol. 1999;1;163(7):3629-35.

31. Tang H, Welton A, Ganea D. Neuropeptide Regulation of Cytokine Expression: Effects of VIP and Ro 25–1553. J Interferon Cytokine Res. 1995;15(11):993-1003.

32. Jiang X, Wang H-Y, Yu J, Ganea D. VIP1 and VIP2 Receptors but not PVR1 Mediate the Effect of VIP/PACAP on Cytokine Production in T Lymphocytes. Ann N Y Acad Sci. 1998;865:397-407.

33. Tang H, Sun L, Xin Z, Ganea D. Down-regulation of Cytokine Expression in Murine Lymphocytes by PACAP and VIP. Ann N Y Acad Sci. 1996;805:768-78.

34. Delgado M, Gonzalez-Rey E, Ganea D. VIP/PACAP preferentially attract Th2 effectors through differential regulation of chemokine production by dendritic cells. FASEB J. 2004;18(12):1453-5.

35. Quatrini L, Vivier E, Ugolini S. Neuroendocrine regulation of innate lymphoid cells. Immunol Rev. 2018;286(1):120-136.

36. Kabata H, Artis D. Neuro-immune crosstalk and allergic inflammation. J Clin Invest. 2019 4(130):1475-1482

Figure 1

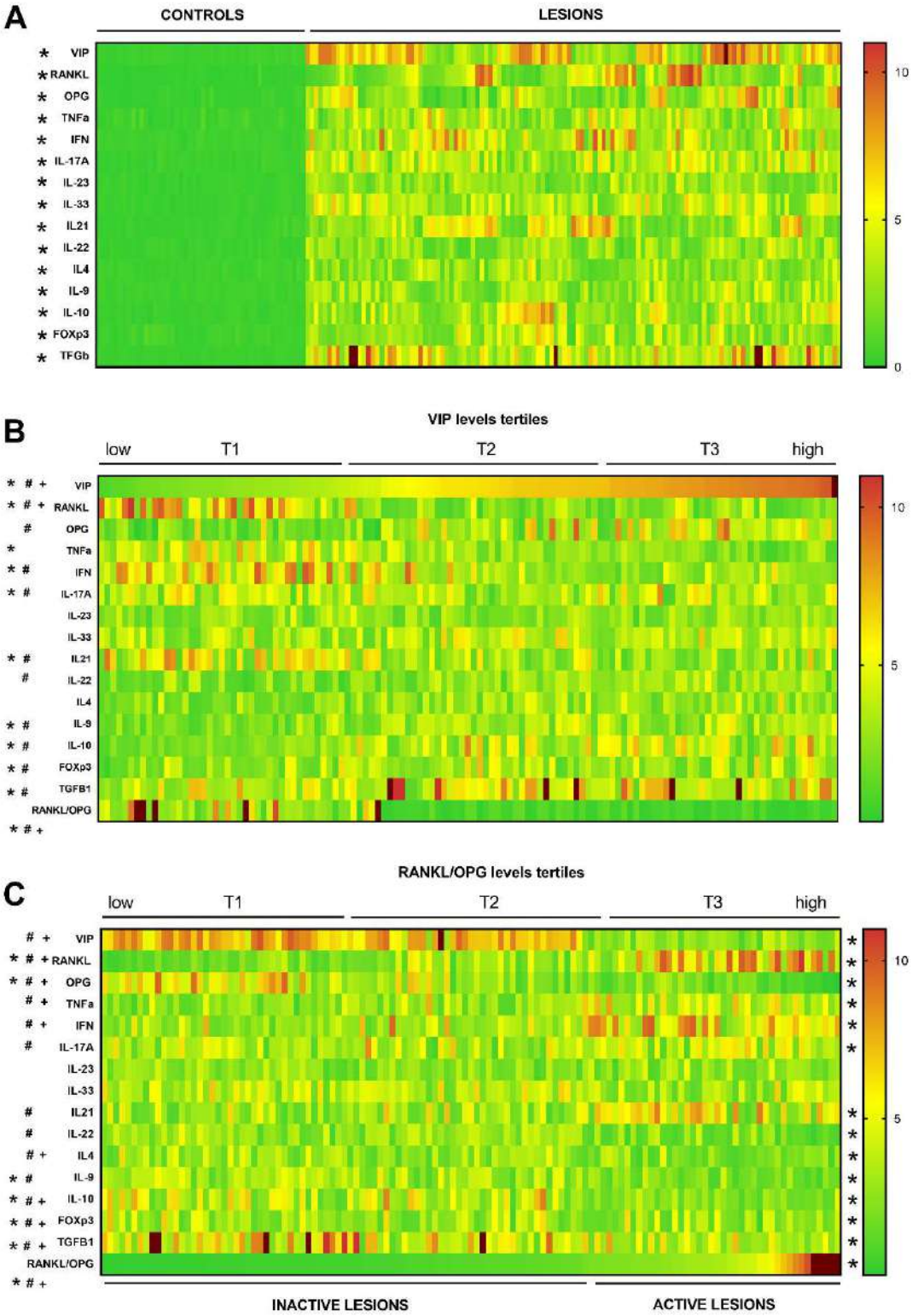
A
CONTROLS
LESIONS
VIP
RANKL
OPG
TNFa
IFN
IL-17A
IL-23
IL-33
IL21
IL-22
IL4
IL-9
IL-10
FOXp3
TFGb
10
5
0
B
VIP levels tertiles
low
T1
T2
T3
high
VIP
RANKL
OPG
TNFa
IFN
IL-17A
IL-23
IL-33
IL21
IL-22
IL4
IL-9
IL-10
FOXp3
TGFB1
RANKL/OPG
10
5
C
RANKL/OPG levels tertiles
low
T1
T2
T3
high
VIP
RANKL
OPG
TNFa
IFN
IL-17A
IL-23
IL-33
IL21
IL-22
IL4
IL-9
IL-10
FOXp3
TGFB1
RANKL/OPG
10
5
INACTIVE LESIONS
ACTIVE LESIONS

Figure 2

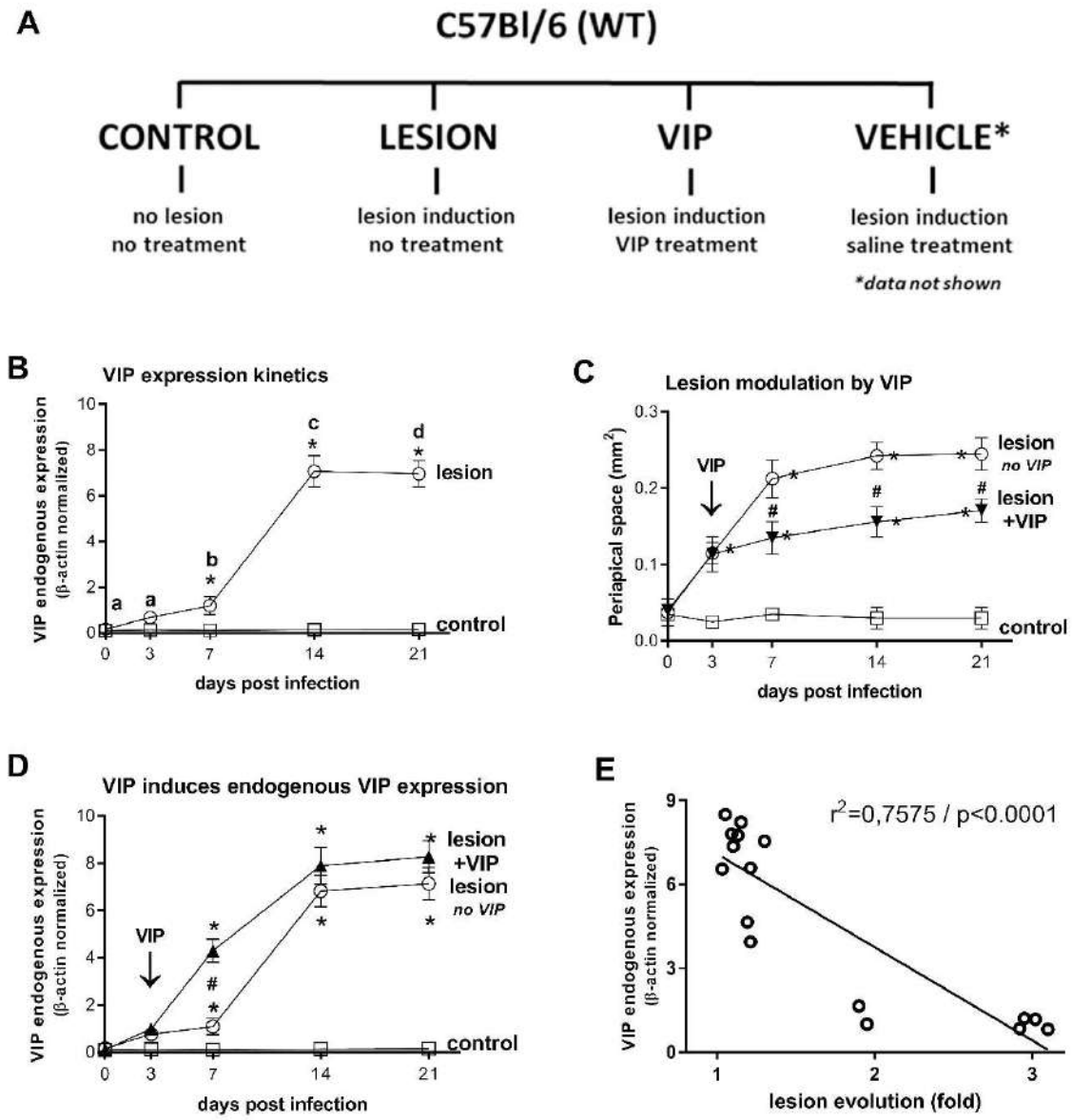
A
C57Bl/6 (WT)
CONTROL
LESION
VIP
VEHICLE*
no lesion
no treatment
lesion induction
no treatment
lesion induction
VIP treatment
lesion induction
saline treatment
*data not shown
B
VIP expression kinetics
VIP endogenous expression (β-actin normalized)
lesion
control
days post infection
C
Lesion modulation by VIP
Periapical space (mm²)
VIP
lesion no VIP
lesion +VIP
control
days post infection
D
VIP induces endogenous VIP expression
VIP endogenous expression (β-actin normalized)
VIP
lesion +VIP
lesion no VIP
control
days post infection
E
r²=0,7575 / p<0.0001
VIP endogenous expression (β-actin normalized)
lesion evolution (fold)

Figure 3

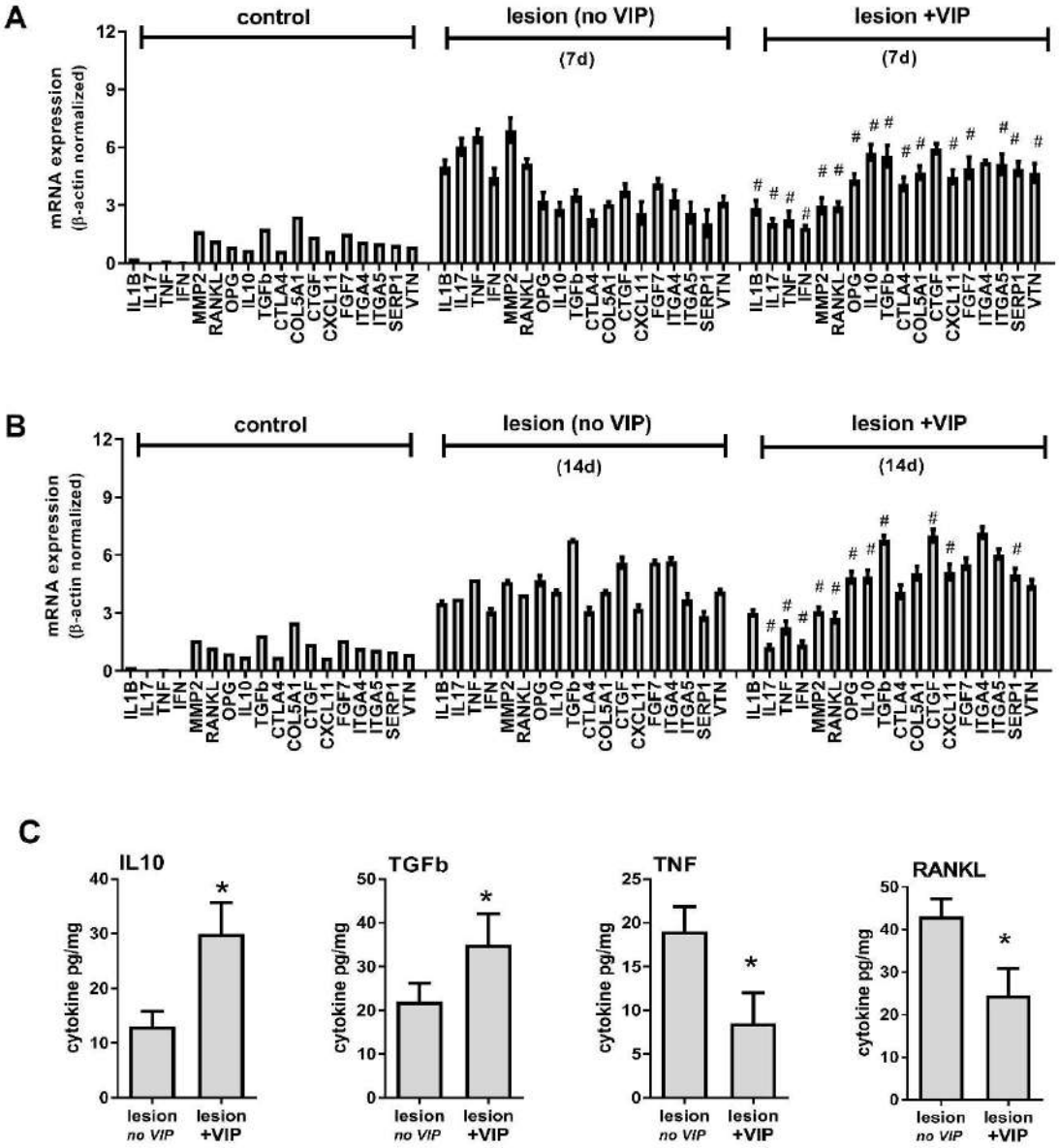
A
control
lesion (no VIP)
(7d)
lesion +VIP
(7d)
mRNA expression
(β-actin normalized)
IL1B
IL17
TNF
IFN
MMP2
RANKL
OPG
IL10
TGFb
CTLA4
COL5A1
CTGF
CXCL11
FGF7
ITGA4
ITGA5
SERP1
VTN
B
control
lesion (no VIP)
(14d)
lesion +VIP
(14d)
mRNA expression
(β-actin normalized)
C
IL10
TGFb
TNF
RANKL
cytokine pg/mg
lesion
no VIP
lesion
+VIP

Figure 4

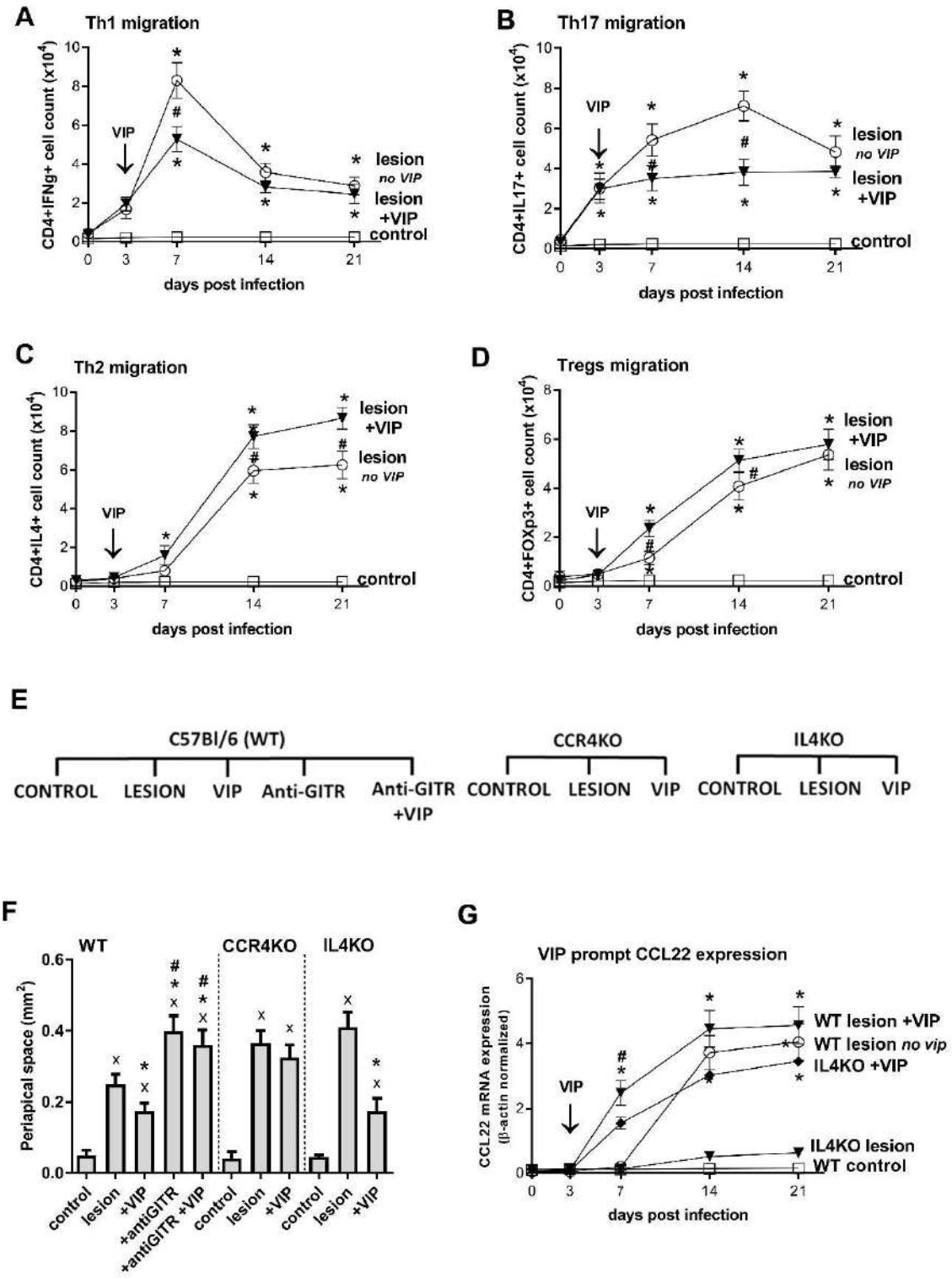
A
Th1 migration
CD4+IFNg+ cell count (x10⁴)
VIP
lesion
no VIP
lesion
+VIP
control
days post infection
B
Th17 migration
CD4+IL17+ cell count (x10⁴)
VIP
lesion
no VIP
lesion
+VIP
control
days post infection
C
Th2 migration
CD4+IL4+ cell count (x10⁴)
VIP
lesion
+VIP
lesion
no VIP
control
days post infection
D
Tregs migration
CD4+FOXp3+ cell count (x10⁴)
VIP
lesion
+VIP
lesion
no VIP
control
days post infection
E
C57Bl/6 (WT)
CONTROL
LESION
VIP
Anti-GITR
Anti-GITR +VIP
CCR4KO
CONTROL
LESION
VIP
IL4KO
CONTROL
LESION
VIP
F
WT
CCR4KO
IL4KO
Periapical space (mm²)
control
lesion
+VIP
+antiGITR
+antiGITR +VIP
control
lesion
+VIP
control
lesion
+VIP
G
VIP prompt CCL22 expression
CCL22 mRNA expression (β-actin normalized)
VIP
WT lesion +VIP
WT lesion no vip
IL4KO +VIP
IL4KO lesion
WT control
days post infection

Graphical Abstract (for review)

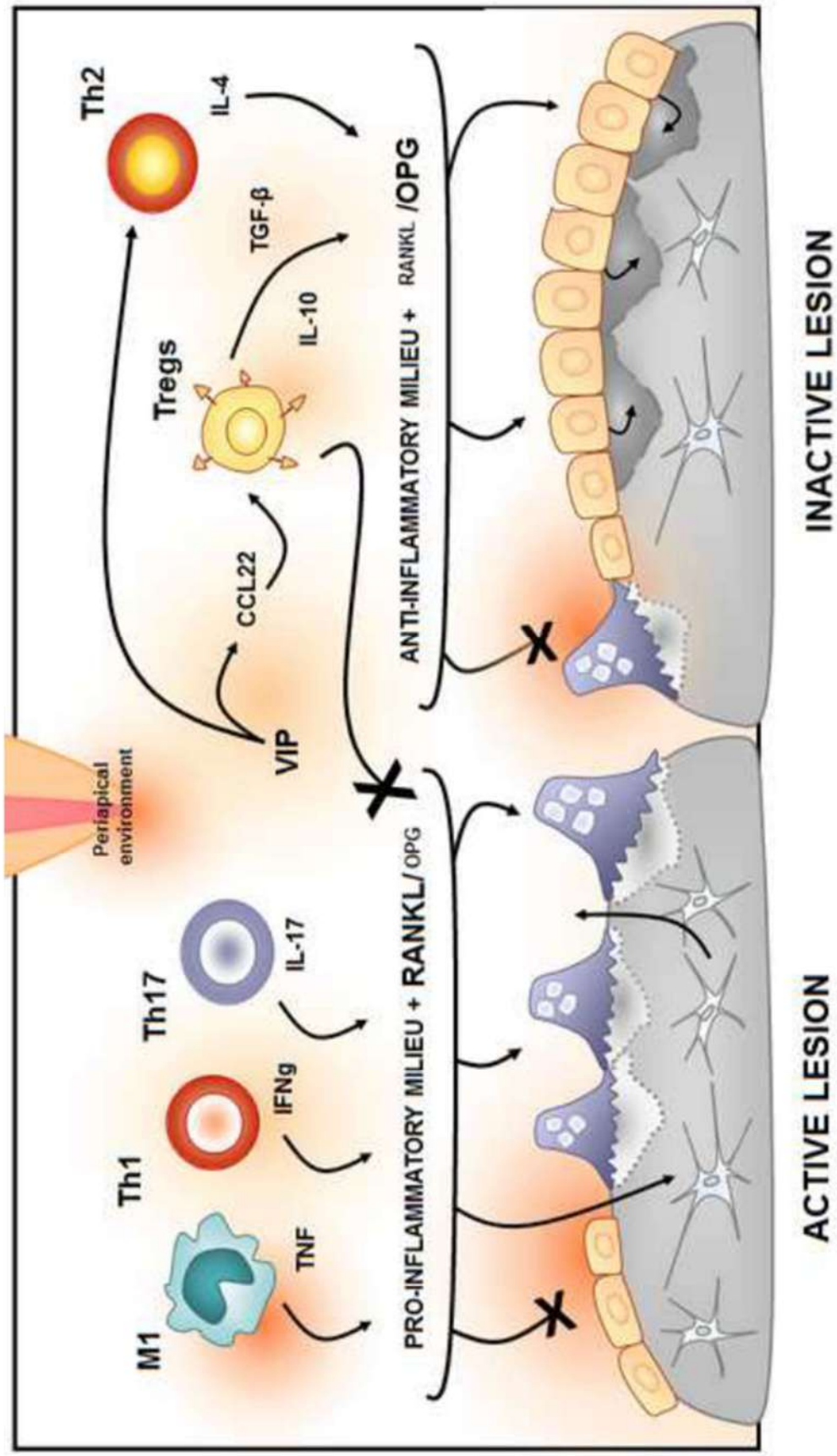

3 DISCUSSION

3 DISCUSSION

The balance between the host pro-inflammatory immune response and the counteracting anti-inflammatory and reparative responses seems to determine the course of the healing process (WALKER et al., 2000). During the healing process, several orchestrated events contributes to the repair success. Among the main events, the inflammatory immune response depends on interactions between bone, immune and nervous systems, promoting a cascade of common mediators (JUHÁSZ et al., 2015). However, the exact role of inflammatory immune response in bone healing and its association with neurotrophic factors is still unclear and most studies have focused on the influence of cells and immunological mediators on osteoclast activation and on the bone resorption process (ARAUJO-PIRES et al., 2014b; GLOWACKI et al., 2013). In our study, we observed that the VIP and PACAP administration and inhibition results in a statistically significant increase of newly formed bone and associated with an increase in anti-inflammatory profile along the repair process.

The main differences in relation to the evaluated bone parameters occurred in the final of healing period and throughout the repair process observed in the majority of immune cells markers analyzed, which suggests that the events in the osteoimmune interaction and the participation of VIP and PACAP as a bone response modulator occurs in all periods of healing. This discussion will follow the overall articles sequence, with the initial discussion of the effects of VIP agonist and antagonist in bone healing outcome, followed by the effects of PACAP and its antagonist in the same model, and them the impact of VIP in chronic inflammatory periapical lesions outcome.

Initially, is important to consider that the inflammatory response and cell migration in the healing process is described to start as a pro-inflammatory response and replaced by an anti-inflammatory or healing profile over time (GAFFNEY et al., 2017). Accordingly, our results demonstrate that a progressive decrease of CD80+ cells followed by a subsequent increase of CD206+ cells was observed in the control group. Similarly, was observed that VIP/PACAP administration resulted in a reduction of total F4/80+ and CD80+ cell counts and in the increase of CD206+ immunolabelled cells, which in theory characterizes this cells as a dominance of M2-type macrophages over M1 subset in the healing sites.

Accordingly, previous studies described the potential VIP/PACAP modulation for an M2 profile (GANEA; DELGADO, 2001a, 2001b). Also, the molecular analysis demonstrated a decrease in the expression of CCL2/CCR2 and CCL5/CCR5, characteristically involved in macrophages chemotaxis (PALOMINO; MARTI, 2013). Additionally, the molecular analysis demonstrated an increased expression of IL-10, FIZZ and ARG and the decrease of IL-6, TNF and IL-1b supports the hypothesis of an increased number of M2 macrophages and an anti-inflammatory profile in the healing site in the VIP-treated group. The increase in GR1 positive cells, followed by the increased expression of CX3CL1 (responsible for leukocyte extravasation by cell adhesion, including neutrophils and monocytes), CXCR1 (receptor expressed on neutrophils, monocytes, T lymphocytes, dendritic cells, eosinophils, basophils and mast cells) and CXCR3 (receptor for CXCL10, inducer of calcium mobilization) (MURPHY et al., 2000), observed in VIP and PACAP groups, shows that not only macrophages suffer the action of VIP and PACAP during the healing process.

Interestingly, usually an inverse association is described between neutrophils and M2 macrophages, since neutrophils depletion results in increase in M2 macrophages increase and M1 reduction in healing sites, a phenotype associated with increased local fibrosis (HORCKMANS et al., 2017). Also, M2 depletion results in increase in neutrophils and M1 macrophages in scar tissue, and decreased collagen deposition (KLINKERT et al., 2017). Importantly, while M1-M2 transition is usually described to favor bone healing, the same is true for the initial presence of neutrophils in bone injury sites (KOVTUN et al., 2016). However, the sustained presence of neutrophils is typically considered a detrimental factor for healing outcome, being associated with exacerbated inflammation and with interferences in bone formation process (BASTIAN et al., 2018; COLAVITE et al., 2019). Interestingly, the increased IL-17 expression in VIP treated group may support an increased neutrophil response in this group, and also can suggest how neutrophils could contribute to a favorable bone healing outcome, since recent studies demonstrate that IL-17 can mediate osteoblastogenesis (CROES et al., 2016; WANG et al., 2018).

At this point, it is mandatory to consider that macrophages are considered one of the major targets for VIP/PACAP activity, and its modulation in healing sites can directly affect the subsequent release of pro- or anti-inflammatory cytokines and growth factors important to the healing process (BURNOUF et al., 2013; NURDEN, 2011; VIEIRA et al., 2015). Indeed, the M2 phenotype in bone repair has been shown to be

responsible for efficiently containing the inflammatory process induced by lesions, improving osteoblastic differentiation and bone regeneration and this modulation and has been explored in the development of osteoimmunomodulator biomaterials taking advantage of these characteristics in the improvement of bone regeneration in chronic inflammatory diseases (HU et al., 2018).

Neuropeptides, such as VIP and PACAP, can be added to the list of endogenous anti-inflammatory molecules. VIP and PACAP exert their anti-inflammatory function in several ways by direct inhibition of pro-inflammatory cytokine production such as TNF, IL-6 and IL-12 by activated macrophages; up-regulation of IL-10 production; inhibition of B7.1/B7.2 expression in activated macrophages; inhibition of IL-2 production and T-cell proliferation and inhibition of Th1 responses (GANEA; DELGADO, 2002). It is also important to consider that in contrast to these well-defined anti-inflammatory functions, VIP supports the generation and long-term survival of Th2 cells (GANEA; DELGADO, 2002), which could justify the increase of CD3 positive cells in the VIP-treated group. In this setting, there is increasing evidence that T lymphocytes play a key role in controlling endogenous regeneration, and that factors such effector/regulator and activated/naïve T cell ratios can influence bone healing outcome (BUCHER et al., 2019; SCHLUNDT et al., 2019).

Our results suggest that the increase of $CD206^+$ in the early periods of the bone repair process modulates the natural course of healing, promoting the decrease in $CD80^+$ cell migration/polarization, and perhaps increasing GR1 positive cells during the early inflammatory process and promoting the significant increase in the new formed bone observed in the VIP and PACAP-treated group. Accordingly, literature data that show VIP and PACAP is able to modulate several types of cells in the most different tissues (COCHAUD et al., 2010; GOZES; FURMAN, 2003). In the end of the healing process, we observed that the initial pro-inflammatory, or a M1 response, is also necessary for a good progress of the healing process and the changes promoted by VIP/PACAP-treatments accelerated the repair capacity after 14 days. The treatment-enhanced M2 response was able to positively modulate the initial M1 response without eliminating it, which can be observed by bone formation within the alveoli, suggesting compensatory mechanisms, or even a change in cell profile, to restore.

Based in our data, neuropeptides such as VIP/PACAP can be added to the list of endogenous molecules that exerts significant immunoregulatory functions in bone

healing process. Importantly, since VIP is not expressed by osteoblastic cells, suggesting the absence of an autocrine system of VIP in osteoblasts (TOGARI et al., 1997), these observations suggest that activities of immune cells presents in healing site are the responsible for VIP expression and its connection to their own receptors in the osteoblasts to regulate bone metabolism. Our data are reinforced by studies that demonstrate that even in conditions of homeostasis, inflammatory mechanisms are extremely important in the bone repair process, participating in the process of angiogenesis, formation and removal of granulation tissue and subsequent formation of bone tissue (CARANO; FILVAROFF, 2003; CARDOSO, 2009; KANCZLER; OREFFO, 2008; KANYAMA et al., 2003; WEISS et al., 2009).

At the end of the healing process, we observed that an initial pro-inflammatory response is necessary for a good progress of the repair process and that even with the changes promoted in the inflammatory response through treatment with VIP and PACAP the repair capacity is not compromised, or even accelerated in the both groups, which can be observed by bone formation inside the alveoli, suggesting compensatory mechanisms, or even a change in cell profile, to restore itself.

In regarding to the results observed in the VIP and PACAP antagonists treated group compared to the control group, contrary to the general expectation that an antagonist would have an inverse effect of an agonist, the results were quite similar to the VIP and PACAP-treated groups in many aspects. Unexpectedly, VIP-VIP antagonist and PACAP-PACAP antagonist behaved similarly in the bone healing process suggesting that common pathways, probably related to the complexity of VIP/PACAP system receptors (JÓZSA et al., 2018; KOVACS et al., 1996; NAGATA et al., 2009).

The putative PACAP/VIP receptors may tentatively be defined best as a PAC1 receptor, based on the receptor kinetics and second messenger. The equal affinities, within an order of magnitude, for PACAP and VIP to the receptor, combined with the indication of an increase in $Ca2^{+}$ in some stromal cells upon stimulation by neuropeptide, is at present consistent with data for the VPAC2. Combined with the presence of nerve fibers immunoreactive for VIP in the bone repair site, suggests that VIP and PACAP, are involved in the local regulation of bone cell metabolism (WINDING; WILTINK; FOGED, 1997), verified in our results by positive immunostaining cells for VIP and PACAP at the repair site.

However, some *in vivo* studies verified that the peptide fragment PACAP(6–38) was not able to provide the antagonist effect (BONI et al., 2009), suggesting a partial inhibition, without being able to inhibit the stimulating action of VIP while PACAP receptor binding is spared (LÁZÁR et al., 2001), similarly studies have observed that PACAP-inducing capacity was sensitive to blockade by the PACAP 6-38 antagonist, but not by a VIP antagonist (JIANG et al., 2008).

The unexpected similarity in the agonists and antagonists may be explained by the complexity of the receptors of VIP/PACAP system, which includes that similarity of the receptors pathways. The blockade of the VPAC1, VPAC2 and PAC1 receptors, which bind VIP and PACAP-38 with varying affinities. Compared to PACAP, VIP binds to PAC1 with lower affinity. Another isoform of PACAP, PACAP-27 can also bind all three receptors promoting a binding of endogenous PACAP with these receptors (HARMAR et al., 2012; KAISER; RUSSO, 2013) and which suggests a compensatory mechanism *in vivo*.

In the case of the treatments performed in this study, the block of VPAC1/VPAC2 and PAC1, which does not prevent the binding of PACAP in VPAC1 and VPAC2 receptors, which, although less efficient in the activation of responses in the bone tissue was able to present similar results for the two treated groups, inferring the activation pathways through compensatory mechanisms in the group treated with the antagonist, suggesting that other mechanisms are directly involved in this differentiation so that it can occur effectively.

In a different context, VIP appears as a potential immunoregulatory factor that could participate of the protective response at the periapex (GANEA; RODRIGUEZ; DELGADO, 2003; SOUZA-MOREIRA et al., 2011). Therefore, in this study we investigated the patterns of VIP expression in human and experimental periapical lesions, as well the effect of recombinant VIP therapy in experimental lesions outcome. Our results demonstrate that VIP expression was higher in the periapical granulomas lesions than controls, being positively associated with the expression of anti-inflammatory and healing markers. Accordingly, a previous study describes the expression of VIP in human periapical lesions with an inverse correlation with lesions size (AZUERO-HOLGUIN et al., 2003; CAVIEDES-BUCHELI et al., 2007).

Additionally, the stratification of human samples based into tertiles based in VIP and/or RANKL/OPG ratio, reveals that VIP presents an inverse/opposite correlation with RANKL/OPG. It is important to mention that the low VIP tertile comprise the

lesions with a RANKL/OPG ratio compatible with theoretical lesion activity, as previously suggested based in the comparison with RANKL/OPG patterns in sites with known active bone resorption (ARAUJO-PIRES et al., 2014a; FUKADA et al., 2008; MENEZES et al., 2008; MUKOHYAMA et al., 2000). Indeed, a minor (14.28%) fraction of intermediate VIP expression quartile presents the active lesions signature (ARAUJO-PIRES et al., 2014a; FUKADA et al., 2008; MENEZES et al., 2008; MUKOHYAMA et al., 2000), suggesting that even a moderate VIP expression can exert a significant immunoregulatory role at periapical environment.

While the human lesions derived data is transversal, the longitudinal analysis of experimental lesions development kinetics offer additional insights into VIP role in lesions pathogenesis. Our data demonstrate that VIP upregulation is temporally associated with the acquisition of a gene expression signature similar to that observed in inactive experimental lesions, and to be associated with a significantly reduced rate of bone resorption progression along the downregulation of pro-inflammatory, proteolytic and osteoclastogenic elements in parallel with the upregulation of anti-inflammatory and healing-related molecules. Such activity/inactivity features are in accordance with previous descriptions of experimental lesions development kinetics (FRANCISCONI et al., 2016; LINDEN et al., 2002; MUKOHYAMA et al., 2000). Therefore, experimental lesions evolution pattern supports the human data, suggesting that VIP can limits lesions development and conceivably promote tissue healing. Accordingly, intracanal calcium hydroxide resulted in increased VIP levels, reinforcing VIP potential protective and pro-reparative capacity (ÖZDEMIR et al., 2019).

Analyzing the patterns of gene expression in human and experimental lesions, it becomes evident the association between VIP and certain T cell subsets with protective roles in periapical lesions pathogenesis, such as Th2 and Tregs. Accordingly, VIP was described to potentiate Th2 and Tregs activity, and to consequently limit the Th1 and Th17 responses (GANEA; RODRIGUEZ; DELGADO, 2003; LECETA et al., 2007; SOUZA-MOREIRA et al., 2011; TAN et al., 2015), which could collectively account for the arrest of lesions progression associated with VIP levels. Indeed, the increase in VIP levels is temporally associated with the conversion/switch of the experimental lesion from active into inactive phenotype (FRANCISCONI et al., 2016; LINDEN et al., 2002; MUKOHYAMA et al., 2000). Also, VIP upregulation is temporally associated with the raise of Th2 and Tregs response, both functionally associated with the attenuation of the progression of these lesions

(FRANCISCONI et al., 2016; LINDEN et al., 2002; MUKOHYAMA et al., 2000), suggesting that VIP could act as trigger of protective Th responses at periapical environment, as described in other chronic inflammation models (DENG et al., 2010; TAN; WASCHEK, 2011). In order to test if VIP actually contribute to periapical lesions inactivity and to healing response in a cause-and-effect manner, mice was treated with recombinant VIP starting at 3d time point, when the endogenous expression of VIP in the lesions is still very low. Our results demonstrate that VIP treatment prompted the arrest of lesions progression and resulted in a molecular signature compatible with inactive lesions profile (GARLET, 2010; GARLET et al., 2012), which was reinforced by the ELISA analysis. Accordingly, VIP was described to arrest experimental arthritis progression, which share some immunopathological features with periapical lesions (DENG et al., 2010; VILLANUEVA-ROMERO et al., 2018).

Looking for possible mechanisms underlying VIP protective function in periapical milieu, we observed that VIP treatment limited the infiltration of potentially pathogenic Th1 and Th17 cells in the lesions (GRAVES; OATES; GARLET, 2011), in accordance with the association described for the endogenous VIP expression kinetics with lesions profile. Also, VIP induced the early expression of endogenous VIP and the chemokine CCL22 in the lesions, prompted Tregs influx into the periapical area and increased Th2 cells counts in the lesions. Accordingly, CCL22 was described to mediate Tregs migration to periapex via CCR4 receptor, and to consequently arrest lesions progression (ARAUJO-PIRES et al., 2015).

Additionally, IL-4 production by Th2 cells was described to induce CCL22 expression (ARAUJO-PIRES et al., 2015), as part of the protective IL-4/CCL22/CCR4 pathway. Additional experiments confirmed the involvement of Tregs in the VIP-protective effect, since the inhibition of Tregs migration (in CCR4KO mice) or activity (with anti-GITR) abrogated the protection in VIP treated mice. Accordingly, human lesions data support the VIP-Tregs connection hypothesis in the view of a very significant correlation observed between the VIP and Tregs markers FOXp3, IL-10 and TGFβ1. As previously mentioned, the synergy between VIP and Tregs in immunoregulation process was described in other inflammatory conditions (TAN et al., 2009). However, despite the increase in Th2 cells migration due VIP therapy, VIP protective effect was IL4-independent, as demonstrated in IL4KO mice. While some studies describe a Th2-inducing effect of VIP (DELGADO et al., 1999), others describe that VIP can inhibit IL-4 transcription, highlighting the complexity of such interplay

(JIANG et al., 1998; TANG et al., 1996; TANG; WELTON; GANEA, 1995). As previously mentioned, IL-4 protective effects involves the induction of CCL22, which allows the Tregs migration via CCR4 (ARAUJO-PIRES et al., 2015).

Nevertheless, since our data demonstrate that VIP prompted CCL22 expression, it may overcome the IL-4 absence. Accordingly, VIP was described to induce the CCL22 expression (DELGADO; GONZALEZ-REY; GANEA, 2004). Additionally, the local release of recombinant CCL22 was found to overcome the overcome IL-4 deficiency by a direct induction of Tregs migration (ARAUJO-PIRES et al., 2015), and to promote Treg migration when applied in the root canal system, and to consequently arrest lesions progression (FRANCISCONI et al., 2016).

Importantly, while the exact source of VIP, originally described as a neuropeptide, at periapical environment remains to be established, increasing evidences support the immunoregulatory properties of nervous system (QUATRINI; VIVIER; UGOLINI, 2018). Indeed, while neuroimmune interactions, mediated by different neuropeptides were initially described as pro-inflammatory, have been demonstrated to be quite more complex and to operate towards restoring homeostasis by controlling the duration and intensity of inflammation through multiple mechanisms (QUATRINI; VIVIER; UGOLINI, 2018). Accordingly, VIP have been demonstrated to be a "neuroimmunopeptide" with a broad spectrum of immunoregulatory functions and as a potential pharmacological target to the clinical management of inflammatory conditions (KABATA; ARTIS, 2019; QUATRINI; VIVIER; UGOLINI, 2018).

CONCLUSION

4 CONCLUSIONS

Analyzing the role of VIP and PACAP in the alveolar bone healing and in the development of periapical lesions, we conclude:

• The VIP treatment increased the bone tissue at the endpoint and demonstrate that the early repair observed in the antiVIP and VIP was associated with an increase presence of M2 macrophages and associated labels;

• The PACAP treatment demonstrated an increase in the bone tissue in the treated groups at the endpoint and shows that the early repair observed in the antiPACAP and PACAP was also associated with an increase presence of M2 macrophages and associated labels.

• The neuropeptide VIP, presents an active immunoregulatory action in periapical granuloma pathogenesis. From the mechanistic viewpoint, VIP induces Treg chemoattraction to the periapical area is mediated by the induction of CCL22.

• Neuropeptides, such as VIP and PACAP, exert a regulatory action over the inflammatory immune response associated with bone tissue, and the extension of regulatory effect seems to be dependent of the nature of inflammatory process.

• Further studies are required to clarify the underlying mechanisms and influence of VIP and PACAP in modulation of inflammatory immune response associated with bone tissue, and the consequent impact in bone lesions or healing outcome. Treatments based in VIP and PACAP administration/delivery can be translationally explored as a complementary strategy to minimize tissue damage and maximize tissue repair in clinical scenarios.

REFERENCES

REFERENCES

ABAD, C.; TAN, Y.-V. Immunomodulatory Roles of PACAP and VIP: Lessons from Knockout Mice. **Journal of molecular neuroscience : MN**, [s. l.], v. 66, n. 1, p. 102–113, 2018. Disponível em: http://www.ncbi.nlm.nih.gov/pubmed/30105629

Al-AQL, Z. S. et al. Molecular mechanisms controlling bone formation during fracture healing and distraction osteogenesis. **Journal of dental research**, [s. l.], v. 87, n. 2, p. 107–18, 2008.

ALEXANDER, K. A. et al. Osteal macrophages promote in vivo intramembranous bone healing in a mouse tibial injury model. **Journal of bone and mineral research : the official journal of the American Society for Bone and Mineral Research**, [s. l.], v. 26, n. 7, p. 1517–32, 2011. Disponível em: http://www.ncbi.nlm.nih.gov/pubmed/21305607

ANG, E. et al. Proteasome inhibitors impair RANKL-induced NF-kappaB activity in osteoclast-like cells via disruption of p62, TRAF6, CYLD, and IkappaBalpha signaling cascades. **Journal of cellular physiology**, [s. l.], v. 220, n. 2, p. 450–9, 2009. Disponível em: http://www.ncbi.nlm.nih.gov/pubmed/19365810

ARAUJO-PIRES, A. C. et al. Simultaneous analysis of T helper subsets (Th1, Th2, Th9, Th17, Th22, Tfh, Tr1 and Tregs) markers expression in periapical lesions reveals multiple cytokine clusters accountable for lesions activity and inactivity status. **Journal of applied oral science : revista FOB**, [s. l.], v. 22, n. 4, p. 336–46, 2014. a. Disponível em: http://www.ncbi.nlm.nih.gov/pubmed/25141207

ARAUJO-PIRES, A. C. et al. Mesenchymal stem cells as active prohealing and immunosuppressive agents in periapical environment: evidence from human and experimental periapical lesions. **Journal of endodontics**, [s. l.], v. 40, n. 10, p. 1560–5, 2014. b. Disponível em: http://www.ncbi.nlm.nih.gov/pubmed/25260726

ARAUJO-PIRES, A. C. et al. IL-4/CCL22/CCR4 axis controls regulatory T-cell migration that suppresses inflammatory bone loss in murine experimental periodontitis. **Journal of bone and mineral research : the official journal of the American Society for Bone and Mineral Research**, [s. l.], v. 30, n. 3, p. 412–22, 2015. Disponível em: http://www.ncbi.nlm.nih.gov/pubmed/25264308

AZUERO-HOLGUIN, M. M. et al. Identification and quantification of vasoactive intestinal peptide in periradicular lesions. **Journal of endodontics**, [s. l.], v. 29, n. 9, p. 557–8, 2003. Disponível em: http://www.ncbi.nlm.nih.gov/pubmed/14503825

BASTIAN, O. W. et al. Neutrophils Inhibit Synthesis of Mineralized Extracellular Matrix by Human Bone Marrow-Derived Stromal Cells In Vitro. **Frontiers in immunology**, [s. l.], v. 9, p. 945, 2018. Disponível em: http://www.ncbi.nlm.nih.gov/pubmed/29765377

BEHL, Y. et al. Activation of the acquired immune response reduces coupled bone formation in response to a periodontal pathogen. **Journal of immunology (Baltimore, Md. : 1950)**, [s. l.], v. 181, n. 12, p. 8711–8, 2008.

BJURHOLM, A. et al. Neuroendocrine regulation of cyclic AMP formation in osteoblastic cell lines (UMR-106-01, ROS 17/2.8, MC3T3-E1, and Saos-2) and primary bone cells. **Journal of bone and mineral research : the official journal of the American Society for Bone and Mineral Research**, [s. l.], v. 7, n. 9, p. 1011–9, 1992. Disponível em: http://www.ncbi.nlm.nih.gov/pubmed/1384276

BODNER, L. et al. Extraction site healing in rats. A radiologic densitometric study. **Oral surgery, oral medicine, and oral pathology**, [s. l.], v. 75, n. 3, p. 367–72, 1993. Disponível em: http://www.ncbi.nlm.nih.gov/pubmed/8469551

BONI, L. J. et al. The in vivo effect of VIP, PACAP-38 and PACAP-27 and mRNA expression of their receptors in rat middle meningeal artery. **Cephalalgia : an international journal of headache**, [s. l.], v. 29, n. 8, p. 837–47, 2009. Disponível em: http://www.ncbi.nlm.nih.gov/pubmed/19220306

BUCHER, C. H. et al. Experience in the Adaptive Immunity Impacts Bone Homeostasis, Remodeling, and Healing. **Frontiers in immunology**, [s. l.], v. 10, p. 797, 2019. Disponível em: http://www.ncbi.nlm.nih.gov/pubmed/31031773

BURNOUF, T. et al. Blood-derived biomaterials and platelet growth factors in regenerative medicine. **Blood reviews**, [s. l.], v. 27, n. 2, p. 77–89, 2013. Disponível em: <http://www.ncbi.nlm.nih.gov/pubmed/23434399>. Acesso em: 4 mar. 2018.

CARANO, R. A. D.; FILVAROFF, E. H. Angiogenesis and bone repair. **Drug discovery today**, [s. l.], v. 8, n. 21, p. 980–9, 2003.

CARDOSO, C. L. **Análise morfométrica e molecular da alveolite induzida em ratos com diferentes modalidades de tratamento**. 2009. Universidade de São Paulo, Bauru, 2009.

CARDOSO, C. R. et al. Evidence of the presence of T helper type 17 cells in chronic lesions of human periodontal disease. **Oral microbiology and immunology**, [s. l.], v. 24, n. 1, p. 1–6, 2009. Disponível em: http://www.ncbi.nlm.nih.gov/pubmed/19121062

CARVALHO, A. C. P. De; OKAMOTO, T. Cirurgia bucal: fundamentos experimentais aplicados à clínica. [s. l.], 1987. Disponível em: <http://bases.bireme.br/cgi-bin/wxislind.exe/iah/online/?IsisScript=iah/iah.xis&src=google&base=LILACS&lang=p&nextAction=lnk&exprSearch=262352&indexSearch=ID#refine>. Acesso em: 23 may. 2019.

CAVIEDES-BUCHELI, J. et al. Vasoactive intestinal peptide receptor expression in chronic periapical lesions. **International endodontic journal**, [s. l.], v. 40, n. 7, p. 521–5, 2007. Disponível em: http://www.ncbi.nlm.nih.gov/pubmed/17511789

CHAN, G. K.; DUQUE, G. Age-related bone loss: Old bone, new facts. **Gerontology**, [s. l.], v. 48, n. 2, p. 62–71, 2002.

COCHAUD, S. et al. The vasoactive intestinal peptide-receptor system is involved in human glioblastoma cell migration. **Neuropeptides**, [s. l.], v. 44, n. 5, p. 373–83, 2010. Disponível em: http://www.ncbi.nlm.nih.gov/pubmed/20638719

COLAVITE, P. M. et al. Alveolar bone healing in mice genetically selected in the maximum (AIRmax) or minimum (AIRmin) inflammatory reaction. **Cytokine**, [s. l.], v. 114, p. 47–60, 2019. Disponível em: http://www.ncbi.nlm.nih.gov/pubmed/30584949

COLIĆ, M. et al. Proinflammatory and immunoregulatory mechanisms in periapical lesions. **Molecular immunology**, [s. l.], v. 47, n. 1, p. 101–13, 2009. Disponível em: http://www.ncbi.nlm.nih.gov/pubmed/19232436

CORMACK, D. H.; HAM, A. W. **Ham's Histology**. 9ª ed. Philadelphia: Lippincott-Raven, 1987.

CROES, M. et al. Proinflammatory T cells and IL-17 stimulate osteoblast differentiation. **Bone**, [s. l.], v. 84, p. 262–270, 2016. Disponível em: http://www.ncbi.nlm.nih.gov/pubmed/26780388

CUTZ, E. et al. Release of vasoactive intestinal polypeptide in mast cells by histamine liberators. **Nature**, [s. l.], v. 275, n. 5681, p. 661–2, 1978. Disponível em: http://www.ncbi.nlm.nih.gov/pubmed/81468

DATTA, H. K. et al. The cell biology of bone metabolism. **Journal of Clinical Pathology**, [s. l.], v. 61, n. 5, p. 577–587, 2008.

DE SENY, D. et al. Biomarkers of inflammation and innate immunity in atrophic

nonunion fracture. **Journal of translational medicine**, [s. l.], v. 14, p. 258, 2016. Disponível em: http://www.ncbi.nlm.nih.gov/pubmed/27599571

DELGADO, M. et al. Vasoactive intestinal peptide and pituitary adenylate cyclase-activating polypeptide stimulate the induction of Th2 responses by up-regulating B7.2 expression. **Journal of immunology (Baltimore, Md. : 1950)**, [s. l.], v. 163, n. 7, p. 3629–35, 1999. Disponível em: http://www.ncbi.nlm.nih.gov/pubmed/10490956

DELGADO, M. et al. Vasoactive intestinal peptide prevents experimental arthritis by downregulating both autoimmune and inflammatory components of the disease. **Nature medicine**, [s. l.], v. 7, n. 5, p. 563–8, 2001. Disponível em: http://www.ncbi.nlm.nih.gov/pubmed/11329057

DELGADO, M.; GANEA, D. Cutting edge: is vasoactive intestinal peptide a type 2 cytokine? **Journal of immunology (Baltimore, Md. : 1950)**, [s. l.], v. 166, n. 5, p. 2907–12, 2001. Disponível em: http://www.ncbi.nlm.nih.gov/pubmed/11207237

DELGADO, M.; GONZALEZ-REY, E.; GANEA, D. VIP/PACAP preferentially attract Th2 effectors through differential regulation of chemokine production by dendritic cells. **FASEB journal : official publication of the Federation of American Societies for Experimental Biology**, [s. l.], v. 18, n. 12, p. 1453–5, 2004. Disponível em: http://www.ncbi.nlm.nih.gov/pubmed/15231725

DELGADO, M.; POZO, D.; GANEA, D. The significance of vasoactive intestinal peptide in immunomodulation. **Pharmacological reviews**, [s. l.], v. 56, n. 2, p. 249–90, 2004. Disponível em: http://www.ncbi.nlm.nih.gov/pubmed/15169929

DENG, S. et al. Regulatory effect of vasoactive intestinal peptide on the balance of Treg and Th17 in collagen-induced arthritis. **Cellular immunology**, [s. l.], v. 265, n. 2, p. 105–10, 2010. Disponível em: http://www.ncbi.nlm.nih.gov/pubmed/20716449

DIMITRIOU, R.; TSIRIDIS, E.; GIANNOUDIS, P. V. Current concepts of molecular aspects of bone healing. **Injury**, [s. l.], v. 36, n. 12, p. 1392–404, 2005.

EDHOLM, E.-S.; RKOO, K. H.; ROBERT, J. **Evolutionary Aspects of Macrophages Polarization**. Cham: Springer International Publishing, 2017. v. 62

ELSUBEIHI, E. S.; HEERSCHE, J. N. M. Quantitative assessment of post-extraction healing and alveolar ridge remodelling of the mandible in female rats. **Archives of oral biology**, [s. l.], v. 49, n. 5, p. 401–12, 2004. Disponível em: http://www.ncbi.nlm.nih.gov/pubmed/15041488

FRANCISCONI, C. F. et al. Characterization of the Protective Role of Regulatory T Cells in Experimental Periapical Lesion Development and Their Chemoattraction Manipulation as a Therapeutic Tool. **Journal of endodontics**, [s. l.], v. 42, n. 1, p. 120–6, 2016. Disponível em: http://www.ncbi.nlm.nih.gov/pubmed/26589811

FRANCISCONI, C. F. et al. RANKL Triggers Treg-Mediated Immunoregulation in Inflammatory Osteolysis. **Journal of dental research**, [s. l.], v. 97, n. 8, p. 917–927, 2018. Disponível em: http://www.ncbi.nlm.nih.gov/pubmed/29499125

FUKADA, S. Y. et al. iNOS-derived nitric oxide modulates infection-stimulated bone loss. **Journal of dental research**, [s. l.], v. 87, n. 12, p. 1155–9, 2008. Disponível em: http://www.ncbi.nlm.nih.gov/pubmed/19029085

FUKUMOTO, S.; MARTIN, T. J. Bone as an endocrine organ. **Trends in endocrinology and metabolism: TEM**, [s. l.], v. 20, n. 5, p. 230–6, 2009. Disponível em: http://www.ncbi.nlm.nih.gov/pubmed/19546009

GAFFNEY, L. et al. Macrophages' Role in Tissue Disease and Regeneration. In: KLOC, M. (Ed.). **Macrophages Origin, Functions and Biointervention**. Results and Problems in Cell DifferentiationCham: Springer International Publishing, 2017. v. 62p. 245–271.

GANEA, D.; DELGADO, M. Neuropeptides as modulators of macrophage functions. Regulation of cytokine production and antigen presentation by VIP and PACAP. **Archivum immunologiae et therapiae experimentalis**, [s. l.], v. 49, n. 2, p. 101–10, 2001. a. Disponível em: http://www.ncbi.nlm.nih.gov/pubmed/11348014

GANEA, D.; DELGADO, M. Inhibitory neuropeptide receptors on macrophages. **Microbes and Infection**, [s. l.], v. 3, n. 2, p. 141–147, 2001. b. Disponível em: http://www.ncbi.nlm.nih.gov/pubmed/11251300

GANEA, D.; DELGADO, M. Vasoactive intestinal peptide (VIP) and pituitary adenylate cyclase-activating polypeptide (PACAP) as modulators of both innate and adaptive immunity. **Critical reviews in oral biology and medicine : an official publication of the American Association of Oral Biologists**, [s. l.], v. 13, n. 3, p. 229–37, 2002. Disponível em: http://www.ncbi.nlm.nih.gov/pubmed/12090463

GANEA, D.; RODRIGUEZ, R.; DELGADO, M. Vasoactive intestinal peptide and pituitary adenylate cyclase-activating polypeptide: players in innate and adaptive immunity. **Cellular and molecular biology (Noisy-le-Grand, France)**, [s. l.], v. 49, n. 2, p. 127–42, 2003. Disponível em: http://www.ncbi.nlm.nih.gov/pubmed/12887096

GARLET, G. P. et al. Cytokine pattern determines the progression of experimental periodontal disease induced by Actinobacillus actinomycetemcomitans through the modulation of MMPs, RANKL, and their physiological inhibitors. **Oral microbiology and immunology**, [s. l.], v. 21, n. 1, p. 12–20, 2006. Disponível em: http://www.ncbi.nlm.nih.gov/pubmed/16390336

GARLET, G. P. et al. The dual role of p55 tumour necrosis factor-alpha receptor in Actinobacillus actinomycetemcomitans-induced experimental periodontitis: host protection and tissue destruction. **Clinical and experimental immunology**, [s. l.], v. 147, n. 1, p. 128–38, 2007. Disponível em: http://www.ncbi.nlm.nih.gov/pubmed/17177972

GARLET, G. P. Destructive and protective roles of cytokines in periodontitis: a re-appraisal from host defense and tissue destruction viewpoints. **Journal of dental research**, [s. l.], v. 89, n. 12, p. 1349–63, 2010. Disponível em: http://www.ncbi.nlm.nih.gov/pubmed/20739705

GARLET, G. P. et al. Expression analysis of wound healing genes in human periapical granulomas of progressive and stable nature. **Journal of endodontics**, [s. l.], v. 38, n. 2, p. 185–90, 2012. Disponível em: http://www.ncbi.nlm.nih.gov/pubmed/22244633

GLOWACKI, A. J. et al. Prevention of inflammation-mediated bone loss in murine and canine periodontal disease via recruitment of regulatory lymphocytes. **Proceedings of the National Academy of Sciences of the United States of America**, [s. l.], v. 110, n. 46, p. 18525–30, 2013. Disponível em: http://www.ncbi.nlm.nih.gov/pubmed/24167272

GOMARIZ, R. P. et al. Immunology of VIP: a review and therapeutical perspectives. **Current pharmaceutical design**, [s. l.], v. 7, n. 2, p. 89–111, 2001. Disponível em: http://www.ncbi.nlm.nih.gov/pubmed/11172702

GONZALEZ-REY, E.; CHORNY, A.; DELGADO, M. Regulation of immune tolerance by anti-inflammatory neuropeptides. **Nature reviews. Immunology**, [s. l.], v. 7, n. 1, p. 52–63, 2007. Disponível em: http://www.ncbi.nlm.nih.gov/pubmed/17186031

GOURLET, P. et al. In vitro properties of a high affinity selective antagonist of the VIP1 receptor. **Peptides**, [s. l.], v. 18, n. 10, p. 1555–60, 1997. Disponível em: http://www.ncbi.nlm.nih.gov/pubmed/9437716

GOZES, I.; FURMAN, S. VIP and drug design. **Current pharmaceutical design**, [s. l.], v. 9, n. 6, p. 483–94, 2003. Disponível em: http://www.ncbi.nlm.nih.gov/pubmed/12570811

GRAVES, D. T.; COCHRAN, D. The contribution of interleukin-1 and tumor necrosis factor to periodontal tissue destruction. **Journal of periodontology**, [s. l.], v. 74, n. 3, p. 391–401, 2003. Disponível em: http://www.ncbi.nlm.nih.gov/pubmed/12710761

GRAVES, D. T.; OATES, T.; GARLET, G. P. Review of osteoimmunology and the host response in endodontic and periodontal lesions. **Journal of oral microbiology**, [s. l.], v. 3, 2011. Disponível em: http://www.ncbi.nlm.nih.gov/pubmed/21547019

HARMAR, A. J. et al. International Union of Pharmacology. XVIII. Nomenclature of receptors for vasoactive intestinal peptide and pituitary adenylate cyclase-activating polypeptide. **Pharmacological reviews**, [s. l.], v. 50, n. 2, p. 265–70, 1998. Disponível em: http://www.ncbi.nlm.nih.gov/pubmed/9647867

HARMAR, A. J. et al. Distribution of the VPAC2 receptor in peripheral tissues of the mouse. **Endocrinology**, [s. l.], v. 145, n. 3, p. 1203–10, 2004. Disponível em: http://www.ncbi.nlm.nih.gov/pubmed/14617572

HARMAR, A. J. et al. Pharmacology and functions of receptors for vasoactive intestinal peptide and pituitary adenylate cyclase-activating polypeptide: IUPHAR review 1. **British journal of pharmacology**, [s. l.], v. 166, n. 1, p. 4–17, 2012. Disponível em: http://www.ncbi.nlm.nih.gov/pubmed/22289055

HERMAN, S.; KRÖNKE, G.; SCHETT, G. Molecular mechanisms of inflammatory bone damage: emerging targets for therapy. **Trends in molecular medicine**, [s. l.], v. 14, n. 6, p. 245–53, 2008. Disponível em: http://www.ncbi.nlm.nih.gov/pubmed/18468489

HOHMANN, E. L.; LEVINE, L.; TASHJIAN, A. H. Vasoactive intestinal peptide stimulates bone resorption via a cyclic adenosine 3',5'-monophosphate-dependent mechanism. **Endocrinology**, [s. l.], v. 112, n. 4, p. 1233–9, 1983. Disponível em: http://www.ncbi.nlm.nih.gov/pubmed/6187560

HORCKMANS, M. et al. Neutrophils orchestrate post-myocardial infarction healing by polarizing macrophages towards a reparative phenotype. **European heart journal**, [s. l.], v. 38, n. 3, p. 187–197, 2017. Disponível em: http://www.ncbi.nlm.nih.gov/pubmed/28158426

HOROWITZ, M. C. et al. Control of osteoclastogenesis and bone resorption by members of the TNF family of receptors and ligands. **Cytokine and Growth Factor Reviews**, [s. l.], v. 12, n. 1, p. 9–18, 2001.

HU, Z. et al. Immunomodulatory ECM-like Microspheres for Accelerated Bone Regeneration in Diabetes Mellitus. **ACS Applied Materials & Interfaces**, [s. l.], v. 10, n. 3, p. 2377–2390, 2018. Disponível em: <http://www.ncbi.nlm.nih.gov/pubmed/29280610>. Acesso em: 5 mar. 2018.

JANEWAY, C. A.; MEDZHITOV, R. Innate immune recognition. **Annual review of immunology**, [s. l.], v. 20, p. 197–216, 2002. Disponível em: http://www.ncbi.nlm.nih.gov/pubmed/11861602

JETTEN, N. et al. Anti-inflammatory M2, but not pro-inflammatory M1 macrophages promote angiogenesis in vivo. **Angiogenesis**, [s. l.], v. 17, n. 1, p. 109–18, 2014. Disponível em: http://link.springer.com/10.1007/s10456-013-9381-6

JIANG, Q. et al. Grass carp somatolactin: I. Evidence for PACAP induction of somatolactin-alpha and -beta gene expression via activation of pituitary PAC-I receptors. **American journal of physiology. Endocrinology and metabolism**, [s. l.], v. 295, n. 2, p. E463-76, 2008. Disponível em: http://www.ncbi.nlm.nih.gov/pubmed/18523122

JIANG, W. et al. Role of vasoactive intestinal peptide in osteoarthritis. **Journal of biomedical science**, [s. l.], v. 23, n. 1, p. 63, 2016. Disponível em: http://www.ncbi.nlm.nih.gov/pubmed/27553659

JIANG, X. et al. VIP1 and VIP2 receptors but not PVR1 mediate the effect of VIP/PACAP on cytokine production in T lymphocytes. **Annals of the New York Academy of Sciences**, [s. l.], v. 865, p. 397–407, 1998. Disponível em: http://www.ncbi.nlm.nih.gov/pubmed/9928038

JONES, K. B. et al. Bone and brain: a review of neural, hormonal, and musculoskeletal connections. **The Iowa orthopaedic journal**, [s. l.], v. 24, p. 123–32, 2004. Disponível em: http://www.ncbi.nlm.nih.gov/pubmed/15296219

JÓZSA, G. et al. Signalling Alterations in Bones of Pituitary Adenylate Cyclase Activating Polypeptide (PACAP) Gene Deficient Mice. **International journal of molecular sciences**, [s. l.], v. 19, n. 9, 2018. Disponível em: http://www.ncbi.nlm.nih.gov/pubmed/30150589

JUHÁSZ, T. et al. PACAP and VIP signaling in chondrogenesis and osteogenesis. **Peptides**, [s. l.], v. 66, p. 51–7, 2015. Disponível em: http://www.ncbi.nlm.nih.gov/pubmed/25701761

JUNQUEIRA, L. C.; CARNEIRO, J. **Histologia Básica**. 13ª ed. Rio de Janeiro, Brasil: Guanabara Koogan, 2017.

KABATA, H.; ARTIS, D. Neuro-immune crosstalk and allergic inflammation. **The Journal of clinical investigation**, [s. l.], v. 130, p. 1475–1482, 2019. Disponível em: http://www.ncbi.nlm.nih.gov/pubmed/30829650

KAISER, E. A.; RUSSO, A. F. CGRP and migraine: could PACAP play a role too? **Neuropeptides**, [s. l.], v. 47, n. 6, p. 451–61, 2013. Disponível em: <http://www.ncbi.nlm.nih.gov/pubmed/24210136>. Acesso em: 4 mar. 2018.

KANCZLER, J. M.; OREFFO, R. O. C. Osteogenesis and angiogenesis: the potential for engineering bone. **European cells & materials**, [s. l.], v. 15, p. 100–14, 2008. Disponível em: http://www.ncbi.nlm.nih.gov/pubmed/18454418

KANYAMA, M. et al. Connective tissue growth factor expressed in rat alveolar bone regeneration sites after tooth extraction. **Archives of oral biology**, [s. l.], v. 48, n. 10, p. 723–30, 2003.

KARSENTY, G.; WAGNER, E. F. Reaching a genetic and molecular understanding of skeletal development. **Developmental cell**, [s. l.], v. 2, n. 4, p. 389–406, 2002.

KATAGIRI, T.; TAKAHASHI, N. Regulatory mechanisms of osteoblast and osteoclast differentiation. **Oral diseases**, [s. l.], v. 8, n. 3, p. 147–59, 2002. Disponível em: http://www.ncbi.nlm.nih.gov/pubmed/12108759

KATCHBURIAN, E.; ARANA, V. **Histologia e Embriologia oral**. 4ª ed. Rio de Janeiro, Brasil: Guanabara Koogan, 2017.

KLINKERT, K. et al. Selective M2 Macrophage Depletion Leads to Prolonged Inflammation in Surgical Wounds. **European surgical research. Europaische chirurgische Forschung. Recherches chirurgicales europeennes**, [s. l.], v. 58, n. 3–4, p. 109–120, 2017. Disponível em: http://www.ncbi.nlm.nih.gov/pubmed/28056458

KOFF, W. C.; DUNEGAN, M. A. Modulation of macrophage-mediated tumoricidal activity by neuropeptides and neurohormones. **Journal of immunology (Baltimore, Md. : 1950)**, [s. l.], v. 135, n. 1, p. 350–4, 1985. Disponível em: http://www.ncbi.nlm.nih.gov/pubmed/2582037

KORPI, J. T. et al. Healing of extraction sockets in collagenase-2 (matrix metalloproteinase-8)-deficient mice. **European journal of oral sciences**, [s. l.], v. 117, n. 3, p. 248–54, 2009. Disponível em: http://www.ncbi.nlm.nih.gov/pubmed/19583751

KOVACS, C. S. et al. Pituitary adenylate cyclase-activating peptide stimulates cyclic AMP accumulation in UMR 106 osteoblast-like cells. **The Journal of endocrinology**, [s. l.], v. 149, n. 2, p. 287–95, 1996. Disponível em: http://www.ncbi.nlm.nih.gov/pubmed/8708540

KOVTUN, A. et al. The crucial role of neutrophil granulocytes in bone fracture healing. **European cells & materials**, [s. l.], v. 32, p. 152–62, 2016. Disponível em: http://www.ncbi.nlm.nih.gov/pubmed/27452963

LÁZÁR, Z. et al. PACAP-(6-38) inhibits the effects of vasoactive intestinal polypeptide, but not PACAP, on the small intestinal circular muscle. **European journal of pharmacology**, [s. l.], v. 431, n. 2, p. 259–64, 2001. Disponível em: http://www.ncbi.nlm.nih.gov/pubmed/11728434

LECETA, J. et al. Vasoactive intestinal peptide regulates Th17 function in autoimmune inflammation. **Neuroimmunomodulation**, [s. l.], v. 14, n. 3–4, p. 134–8, 2007. Disponível em: http://www.ncbi.nlm.nih.gov/pubmed/18073504

LERNER, U. H.; PERSSON, E. Osteotropic effects by the neuropeptides calcitonin gene-related peptide, substance P and vasoactive intestinal peptide. **Journal of musculoskeletal & neuronal interactions**, [s. l.], v. 8, n. 2, p. 154–65, 2008. Disponível em: http://www.ncbi.nlm.nih.gov/pubmed/18622084

LI, Y. et al. B cells and T cells are critical for the preservation of bone homeostasis and attainment of peak bone mass in vivo. **Blood**, [s. l.], v. 109, n. 9, p. 3839–48, 2007. Disponível em: http://www.ncbi.nlm.nih.gov/pubmed/17202317

LINDEN, G. J. et al. Changes in vasoactive intestinal peptide in gingival crevicular fluid in response to periodontal treatment. **Journal of clinical periodontology**, [s. l.], v. 29, n. 6, p. 484–9, 2002. Disponível em: http://www.ncbi.nlm.nih.gov/pubmed/12296773

LISI, L. et al. Proinflammatory-activated glioma cells induce a switch in microglial polarization and activation status, from a predominant M2b phenotype to a mixture of M1 and M2a/B polarized cells. **ASN neuro**, [s. l.], v. 6, n. 3, p. 171–83, 2014. Disponível em: http://www.ncbi.nlm.nih.gov/pubmed/24689533

LLOYD, S. A. et al. Administration of high-dose macrophage colony-stimulating factor

increases bone turnover and trabecular volume fraction. **Journal of Bone and Mineral Metabolism**, [s. l.], v. 27, n. 5, p. 546–554, 2009.

LORENZO, J.; HOROWITZ, M.; CHOI, Y. Osteoimmunology: interactions of the bone and immune system. **Endocrine reviews**, [s. l.], v. 29, n. 4, p. 403–40, 2008.

LUNDBERG, P. et al. Vasoactive intestinal peptide (VIP)/pituitary adenylate cyclase-activating peptide receptor subtypes in mouse calvarial osteoblasts: presence of VIP-2 receptors and differentiation-induced expression of VIP-1 receptors. **Endocrinology**, [s. l.], v. 142, n. 1, p. 339–47, 2001. Disponível em: http://www.ncbi.nlm.nih.gov/pubmed/11145597

MARTINEZ, C. et al. Regulation of VIP production and secretion by murine lymphocytes. **Journal of neuroimmunology**, [s. l.], v. 93, n. 1–2, p. 126–38, 1999. Disponível em: http://www.ncbi.nlm.nih.gov/pubmed/10378876

MARTINEZ, F. O. et al. Macrophage activation and polarization. **Frontiers in bioscience : a journal and virtual library**, [s. l.], v. 13, p. 453–61, 2008. Disponível em: http://www.ncbi.nlm.nih.gov/pubmed/17981560

MARTINEZ, F. O.; GORDON, S. The M1 and M2 paradigm of macrophage activation: time for reassessment. **F1000prime reports**, [s. l.], v. 6, p. 13, 2014. Disponível em: http://www.ncbi.nlm.nih.gov/pubmed/24669294

MCCAULEY, L. K.; NOHUTCU, R. M. Mediators of Periodontal Osseous Destruction and Remodeling: Principles and Implications for Diagnosis and Therapy. **Journal of Periodontology**, [s. l.], v. 73, n. 11, p. 1377–1391, 2005.

MENEZES, R. et al. Differential patterns of receptor activator of nuclear factor kappa B ligand/osteoprotegerin expression in human periapical granulomas: possible association with progressive or stable nature of the lesions. **Journal of endodontics**, [s. l.], v. 34, n. 8, p. 932–8, 2008. Disponível em: http://www.ncbi.nlm.nih.gov/pubmed/18634923

MILLS, C. D. et al. M-1/M-2 macrophages and the Th1/Th2 paradigm. **Journal of immunology (Baltimore, Md. : 1950)**, [s. l.], v. 164, n. 12, p. 6166–73, 2000. Disponível em: http://www.ncbi.nlm.nih.gov/pubmed/10843666

MILLS, C. D. Macrophage arginine metabolism to ornithine/urea or nitric oxide/citrulline: a life or death issue. **Critical reviews in immunology**, [s. l.], v. 21, n. 5, p. 399–425, 2001. Disponível em: http://www.ncbi.nlm.nih.gov/pubmed/11942557

MORRISSETTE, N.; GOLD, E.; ADEREM, A. The macrophage--a cell for all seasons. **Trends in cell biology**, [s. l.], v. 9, n. 5, p. 199–201, 1999.

MOSSER, D. M.; EDWARDS, J. P. Exploring the full spectrum of macrophage activation. **Nature reviews. Immunology**, [s. l.], v. 8, n. 12, p. 958–69, 2008.

MUKOHYAMA, H. et al. The inhibitory effects of vasoactive intestinal peptide and pituitary adenylate cyclase-activating polypeptide on osteoclast formation are associated with upregulation of osteoprotegerin and downregulation of RANKL and RANK. **Biochemical and biophysical research communications**, [s. l.], v. 271, n. 1, p. 158–63, 2000. Disponível em: http://www.ncbi.nlm.nih.gov/pubmed/10777696

MURPHY, P. M. et al. International union of pharmacology. XXII. Nomenclature for chemokine receptors. **Pharmacological reviews**, [s. l.], v. 52, n. 1, p. 145–76, 2000. Disponível em: http://www.ncbi.nlm.nih.gov/pubmed/10699158

MURRAY, P. J.; WYNN, T. A. Protective and pathogenic functions of macrophage subsets. **Nature reviews. Immunology**, [s. l.], v. 11, n. 11, p. 723–37, 2011. Disponível em: http://www.ncbi.nlm.nih.gov/pubmed/21997792

MUTT, V. Vasoactive intestinal polypeptide and related peptides. Isolation and chemistry. **Annals of the New York Academy of Sciences**, [s. l.], v. 527, p. 1–19, 1988. Disponível em: http://www.ncbi.nlm.nih.gov/pubmed/3133967

NAGATA, A. et al. cAMP activation by PACAP/VIP stimulates IL-6 release and inhibits osteoblastic differentiation through VPAC2 receptor in osteoblastic MC3T3 cells. **Journal of cellular physiology**, [s. l.], v. 221, n. 1, p. 75–83, 2009. Disponível em: http://www.ncbi.nlm.nih.gov/pubmed/19496170

NANCI, A. **Ten Cate Histologia Oral: Desenvolvimento, Estrutura e Função**. 8ª ed. Rio de Janeiro, Brasil: Elsevier, 2013.

NEWMAN, M. et al. **Carranza Periodontia Clínica**. Rio de Janeiro, Brasil: Elsevier, 2012.

NICKS, K. M. et al. Regulation of osteoblastogenesis and osteoclastogenesis by the other reproductive hormones, Activin and Inhibin. **Molecular and cellular endocrinology**, [s. l.], v. 310, n. 1–2, p. 11–20, 2009. Disponível em: http://www.ncbi.nlm.nih.gov/pubmed/19615428

NURDEN, A. Platelets, Inflammation And Tissue Regeneration. **Thromb Haemost**, [s. l.], v. 105, n. 1, p. s13-33, 2011.

ÖZDEMIR, M. B. et al. Effect of intracanal medicaments on matrix metalloproteinase-9 and vasoactive intestinal peptide secretion in periapical lesions of re-treated canals: a randomized controlled clinical study. **Clinical oral investigations**, [s. l.], v. 23, n. 2, p. 921–928, 2019. Disponível em: http://www.ncbi.nlm.nih.gov/pubmed/29948282

PALOMINO, D. C. T.; MARTI, L. C. Chemokines and immunity. **Einstein (Sao Paulo, Brazil)**, [s. l.], v. 13, n. 3, p. 469–73, 2013. Disponível em: http://www.ncbi.nlm.nih.gov/pubmed/26466066

PERSSON, E.; LERNER, U. H. The neuropeptide VIP regulates the expression of osteoclastogenic factors in osteoblasts. **Journal of cellular biochemistry**, [s. l.], v. 112, n. 12, p. 3732–41, 2011. Disponível em: http://www.ncbi.nlm.nih.gov/pubmed/21815197

PHILLIPS, A. M. Overview of the fracture healing cascade. **Injury**, [s. l.], v. 36 Suppl 3, p. S5-7, 2005.

POLETI, M. L. **Análise morfométrica, radiográfica e molecular do processo de reparo alveolar após a terapia fotodinâmica antimicrobiana em ratos Wistar**. 2009. Universidade de São Paulo, Bauru, 2009. Disponível em: http://www.teses.usp.br/teses/disponiveis/25/25132/tde-03072009-105031/

QUATRINI, L.; VIVIER, E.; UGOLINI, S. Neuroendocrine regulation of innate lymphoid cells. **Immunological reviews**, [s. l.], v. 286, n. 1, p. 120–136, 2018. Disponível em: http://www.ncbi.nlm.nih.gov/pubmed/30294960

RANSJÖ, M. et al. Microisolated mouse osteoclasts express VIP-1 and PACAP receptors. **Biochemical and biophysical research communications**, [s. l.], v. 274, n. 2, p. 400–4, 2000. Disponível em: http://www.ncbi.nlm.nih.gov/pubmed/10913350

RAUNER, M.; SIPOS, W.; PIETSCHMANN, P. Osteoimmunology. **International archives of allergy and immunology**, [s. l.], v. 143, n. 1, p. 31–48, 2007.

REFAI, E. et al. Biodistribution of liposomal 131I-VIP in rat using gamma camera. **Nuclear medicine and biology**, [s. l.], v. 26, n. 8, p. 931–6, 1999. Disponível em: http://www.ncbi.nlm.nih.gov/pubmed/10708307

REUBI, J. C. Peptide receptors as molecular targets for cancer diagnosis and therapy. **Endocrine reviews**, [s. l.], v. 24, n. 4, p. 389–427, 2003. Disponível em: http://www.ncbi.nlm.nih.gov/pubmed/12920149

RODRIGUES, M. T. V. **Análise microscópica e histométrica comparativa da aplicação de uma pasta à base de metronidazol e da irrigação com iodeto de sódio e peróxido de hidrogênio para o tratamento de alvéolos dentários infectados de ratos**. 2007. Universidade de São Paulo, Bauru, 2007. Disponível em: http://www.teses.usp.br/teses/disponiveis/25/25132/tde-12092007-181441/

ROSCHGER, P. et al. Bone mineralization density distribution in health and disease. **Bone**, [s. l.], v. 42, n. 3, p. 456–466, 2008.

SAID, S. I. **Proinflammatory and Antiinflammatory Peptides**. 1st. ed. New York: TAYLOR & FRANCIS POD, 1998. v. 19 Disponível em: https://books.google.com.br/books?id=wnAepadYVJgC&pg=PR2&lpg=PR2&dq=ISBN+0+8247+0120+8&source=bl&ots=824Xj0ClGN&sig=ACfU3U1WjaxoiUZJMKc3i-bmi4rY1Hun8g&hl=pt-BR&sa=X&ved=2ahUKEwjQ5JriirLiAhXDDbkGHfbNCscQ6AEwA3oECAgQAQ#v=onepage&q=ISBN 0 8247 0120 8&f=false

SANDOR, B. et al. Structural and morphometric comparison of the molar teeth in pre-eruptive developmental stage of PACAP-deficient and wild-type mice. **Journal of molecular neuroscience : MN**, [s. l.], v. 54, n. 3, p. 331–41, 2014. Disponível em: http://www.ncbi.nlm.nih.gov/pubmed/25112419

SANSON, M.; DISTEL, E.; FISHER, E. A. HDL induces the expression of the M2 macrophage markers arginase 1 and Fizz-1 in a STAT6-dependent process. **PloS one**, [s. l.], v. 8, n. 8, p. e74676, 2013. Disponível em: http://www.ncbi.nlm.nih.gov/pubmed/23991225

SCHLUNDT, C. et al. Individual Effector/Regulator T Cell Ratios Impact Bone Regeneration. **Frontiers in immunology**, [s. l.], v. 10, p. 1954, 2019. Disponível em: http://www.ncbi.nlm.nih.gov/pubmed/31475013

SHI, C.; PAMER, E. G. Monocyte recruitment during infection and inflammation. **Nature reviews. Immunology**, [s. l.], v. 11, n. 11, p. 762–74, 2011. Disponível em: http://www.ncbi.nlm.nih.gov/pubmed/21984070

SICA, A.; MANTOVANI, A. **Macrophage plasticity and polarization: In vivo veritas**, 2012.

SILVA, T. A. et al. Differential expression of chemokines and chemokine receptors in inflammatory periapical diseases. **Oral microbiology and immunology**, [s. l.], v. 20, n. 5, p. 310–6, 2005. Disponível em: http://www.ncbi.nlm.nih.gov/pubmed/16101967

SINDRILARU, A.; SCHARFFETTER-KOCHANEK, K. Disclosure of the Culprits: Macrophages-Versatile Regulators of Wound Healing. **Advances in wound care**, [s. l.], v. 2, n. 7, p. 357–368, 2013. Disponível em: http://www.ncbi.nlm.nih.gov/pubmed/24587973

SOUZA-MOREIRA, L. et al. Neuropeptides as pleiotropic modulators of the immune response. **Neuroendocrinology**, [s. l.], v. 94, n. 2, p. 89–100, 2011. Disponível em: http://www.ncbi.nlm.nih.gov/pubmed/21734355

SPILLER, K. L. et al. The role of macrophage phenotype in vascularization of tissue engineering scaffolds. **Biomaterials**, [s. l.], v. 35, n. 15, p. 4477–88, 2014. Disponível em: http://www.ncbi.nlm.nih.gov/pubmed/24589361

SUDA, T.; UDAGAWA, N.; N, T. Cells of bone: osteoclast generation. In: BILEZIKIAN, J. P.; RAISZ, L. G.; RODAN, G. A. (Eds.). **Principles of Bone Biology**. 2. ed. [s.l.] : Academic Press, 2002. p. 1696.

TAKAYANAGI, H. Inflammatory bone destruction and osteoimmunology. **Journal of periodontal research**, [s. l.], v. 40, n. 4, p. 287–93, 2005.

TAKAYANAGI, H. Osteoimmunology: shared mechanisms and crosstalk between the immune and bone systems. **Nature reviews. Immunology**, [s. l.], v. 7, n. 4, p. 292–304, 2007.

TAN, Y.-V. et al. Pituitary adenylyl cyclase-activating polypeptide is an intrinsic regulator of Treg abundance and protects against experimental autoimmune encephalomyelitis. **Proceedings of the National Academy of Sciences of the United States of America**, [s. l.], v. 106, n. 6, p. 2012–7, 2009. Disponível em: http://www.ncbi.nlm.nih.gov/pubmed/19190179

TAN, Y.-V. et al. VPAC2 (vasoactive intestinal peptide receptor type 2) receptor deficient mice develop exacerbated experimental autoimmune encephalomyelitis with increased Th1/Th17 and reduced Th2/Treg responses. **Brain, behavior, and immunity**, [s. l.], v. 44, p. 167–175, 2015. Disponível em: http://www.ncbi.nlm.nih.gov/pubmed/25305591

TAN, Y.-V.; WASCHEK, J. A. Targeting VIP and PACAP receptor signalling: new

therapeutic strategies in multiple sclerosis. **ASN neuro**, [s. l.], v. 3, n. 4, 2011. Disponível em: http://www.ncbi.nlm.nih.gov/pubmed/21895607

TANG, H. et al. Down-regulation of cytokine expression in murine lymphocytes by PACAP and VIP. **Annals of the New York Academy of Sciences**, [s. l.], v. 805, p. 768–78, 1996. Disponível em: http://www.ncbi.nlm.nih.gov/pubmed/8993475

TANG, H.; WELTON, A.; GANEA, D. Neuropeptide regulation of cytokine expression: effects of VIP and Ro 25-1553. **Journal of interferon & cytokine research : the official journal of the International Society for Interferon and Cytokine Research**, [s. l.], v. 15, n. 11, p. 993–1003, 1995. Disponível em: http://www.ncbi.nlm.nih.gov/pubmed/8590312

TEITELBAUM, S. L. Bone resorption by osteoclasts. **Science (New York, N.Y.)**, [s. l.], v. 289, n. 5484, p. 1504–8, 2000. Disponível em: http://www.ncbi.nlm.nih.gov/pubmed/10968780

THEILL, L. E.; BOYLE, W. J.; PENNINGER, J. M. RANK-L and RANK: T cells, bone loss, and mammalian evolution. **Annual review of immunology**, [s. l.], v. 20, p. 795–823, 2002.

TOGARI, A. et al. Expression of mRNAs for neuropeptide receptors and beta-adrenergic receptors in human osteoblasts and human osteogenic sarcoma cells. **Neuroscience letters**, [s. l.], v. 233, n. 2–3, p. 125–8, 1997. Disponível em: http://www.ncbi.nlm.nih.gov/pubmed/9350848

TOMOMATSU, N. et al. LPS-induced inhibition of osteogenesis is TNF-alpha dependent in a murine tooth extraction model. **Journal of bone and mineral research : the official journal of the American Society for Bone and Mineral Research**, [s. l.], v. 24, n. 10, p. 1770–81, 2009. Disponível em: http://www.ncbi.nlm.nih.gov/pubmed/19419299

TSIRIDIS, E.; UPADHYAY, N.; GIANNOUDIS, P. Molecular aspects of fracture healing: which are the important molecules? **Injury**, [s. l.], v. 38 Suppl 1, p. S11-25, 2007.

VIEIRA, A. E. et al. Intramembranous bone healing process subsequent to tooth extraction in mice: micro-computed tomography, histomorphometric and molecular characterization. **PloS one**, [s. l.], v. 10, n. 5, p. e0128021, 2015. Disponível em: http://www.ncbi.nlm.nih.gov/pubmed/26023920

VILLANUEVA-ROMERO, R. et al. The Anti-Inflammatory Mediator, Vasoactive Intestinal Peptide, Modulates the Differentiation and Function of Th Subsets in Rheumatoid Arthritis. **Journal of immunology research**, [s. l.], v. 2018, p. 6043710, 2018. Disponível em: http://www.ncbi.nlm.nih.gov/pubmed/30155495

VIRGOLINI, I. et al. 123I-vasoactive intestinal peptide (VIP) receptor scanning: update of imaging results in patients with adenocarcinomas and endocrine tumors of the gastrointestinal tract. **Nuclear medicine and biology**, [s. l.], v. 23, n. 6, p. 685–92, 1996. Disponível em: http://www.ncbi.nlm.nih.gov/pubmed/8940711

WADA, T. et al. RANKL-RANK signaling in osteoclastogenesis and bone disease. **Trends in molecular medicine**, [s. l.], v. 12, n. 1, p. 17–25, 2006. Disponível em: http://www.ncbi.nlm.nih.gov/pubmed/16356770

WALKER, K. F. et al. Cytokine expression in periapical granulation tissue as assessed by immunohistochemistry. **European journal of oral sciences**, [s. l.], v. 108, n. 3, p. 195–201, 2000. Disponível em: http://www.ncbi.nlm.nih.gov/pubmed/10872989

WANG, Y. et al. Vasoactive intestinal polypeptide enhances oral tolerance by regulating both cellular and humoral immune responses. **Clinical and experimental immunology**, [s. l.], v. 148, n. 1, p. 178–87, 2007.

WANG, Y. et al. A two phase regulation of bone regeneration: IL-17F mediates osteoblastogenesis via C/EBP-β in vitro. **Bone**, [s. l.], v. 116, p. 47–57, 2018. Disponível em: http://www.ncbi.nlm.nih.gov/pubmed/30010083

WEISS, S. et al. The systemic angiogenic response during bone healing. **Archives of orthopaedic and trauma surgery**, [s. l.], v. 129, n. 7, p. 989–97, 2009. Disponível em: http://www.ncbi.nlm.nih.gov/pubmed/19037648

WINDING, B.; WILTINK, A.; FOGED, N. T. Pituitary adenylyl cyclase-activating polypeptides and vasoactive intestinal peptide inhibit bone resorption by isolated rabbit osteoclasts. **Experimental physiology**, [s. l.], v. 82, n. 5, p. 871–86, 1997.

WITTE, M. B.; BARBUL, A. General principles of wound healing. **The Surgical clinics of North America**, [s. l.], v. 77, n. 3, p. 509–28, 1997.

ZHOU, D. et al. Macrophage polarization and function with emphasis on the evolving roles of coordinated regulation of cellular signaling pathways. **Cellular signalling**, [s. l.], v. 26, n. 2, p. 192–7, 2014. Disponível em: http://www.ncbi.nlm.nih.gov/pubmed/24219909

ANNEXES

Anexo A - Ofício de aprovação do projeto de pesquisa pela Comissão de Ética no Ensino e Pesquisa em Animais da FOB/USP

Universidade de São Paulo
Faculdade de Odontologia de Bauru

Comissão de Ética no Ensino e Pesquisa em Animais

CEEPA-Proc. Nº 001/2016

Bauru, 15 de março de 2016.

Senhor Professor,

Informamos que Projeto de Pesquisa denominado ***Papel de VIP (vasoactive intestinal peptide) e PACAP (pituitary adenylate cyclase-activating polypeptide) na polarização M2 e seu impacto no processo de reparo ósseo alveolar*** tendo Vossa Senhoria como Pesquisador Responsável, que envolve a utilização de animais (roedores), para fins de pesquisa científica, encontra-se de acordo com os preceitos da Lei nº 11.794, de 8 de outubro de 2008, do Decreto nº 6.899, de 15 de julho de 2009, e com as normas editadas pelo Conselho Nacional de Controle da Experimentação Animal (CONCEA), foi analisado e considerado APROVADO pela Comissão de Ética no Ensino e Pesquisa em Animais (CEEPA), em reunião realizada no dia **11 de março de 2016**.

Vigência do projeto:	*Abril/2016 a Fevereiro/2018*
Espécie/Linhagem:	*Camundongo isogênico - C57Bl/6*
Nº de animais:	*180*
Peso/Idade	*25g/8 semanas*
Sexo:	*Machos*
Origem:	*Biotério da Faculdade de Medicina de Ribeirão Preto (FM/USP)*

Esta CEEPA solicita que ao final da pesquisa seja enviado um Relatório com os resultados obtidos para análise ética e emissão de parecer final, o qual poderá ser utilizado para fins de publicação científica.

Atenciosamente,

Profª Drª Ana Paula Campanelli

Presidente da Comissão de Ética no Ensino e Pesquisa em Animais

Prof. Dr. Gustavo Pompermaier Garlet
Docente do Departamento de Ciências Biológicas

Al. Dr. Octávio Pinheiro Brisolla, 9-75 – Bauru-SP – CEP 17012-901 – C.P. 73
e-mail: ceepa@fob.usp.br – Fone/FAX (0xx14) 3235-8356
http://www.fob.usp.br

Universidade de São Paulo
Faculdade de Odontologia de Bauru

Comissão de Ética no Ensino e Pesquisa em Animais

CEEPA-Proc. Nº 001/2016

Bauru, 12 de dezembro de 2016.

Senhor Professor,

Em atenção à solicitação de Vossa Senhoria para o acréscimo de 90 camundongos *C57BL/6* na proposta de pesquisa, denominada ***Papel de VIP (vasoactive intestinal peptide) e PACAP (pituitary adenylate cyclase-activating polypeptide) na polarização M2 e seu impacto no processo de reparo ósseo alveolar***, tendo Vossa Senhoria como Pesquisador Responsável, que envolve a utilização de animais pertencentes ao filo Chordata, subfilo Vertebrata (exceto humanos), para fins de pesquisa científica, encontra-se de acordo com os preceitos da Lei nº 11.794, de 8 de outubro de 2008, do Decreto nº 6.899, de 15 de julho de 2009, e com as normas editadas pelo Conselho Nacional de Controle da Experimentação Animal (CONCEA), foi analisada e considerada APROVADA a sua execução nas dependências da FOB-USP, *em reunião ordinária da* Comissão de Ética no Ensino e Pesquisa em Animais (CEEPA) realizada no dia 9 de dezembro de 2016.

Finalidade	*( ) Ensino (X) Pesquisa Científica*
Vigência da autorização:	*Abril/2016 a Fevereiro/2018*
Espécie/linhagem/raça:	*Camundongo isogênico/C57BL/6*
Nº de animais:	*270*
Peso/Idade	*25g/8 semanas*
Sexo:	*Macho*
Origem:	*Biotério da Faculdade de Medicina de Ribeirão Preto (FM/USP)*

Esta CEEPA solicita que ao final da pesquisa seja enviado um Relatório com os resultados obtidos para análise ética e emissão de parecer final, o qual poderá ser utilizado para fins de publicação científica.

Atenciosamente,

Profª Drª Ana Paula Campanelli

Presidente da Comissão de Ética no Ensino e Pesquisa em Animais

Prof. Dr. Gustavo Pompermaier Garlet
Docente do Departamento de Ciências Biológicas

Al. Dr. Octávio Pinheiro Brisolla, 9-75 – Bauru-SP – CEP 17012-901 – C.P. 73
e-mail: ceepa@fob.usp.br – Fone/FAX (0xx14) 3235-8356
http://www.fob.usp.br

Anexo B – Submissão do artigo “Vasoactive intestinal peptide (VIP) immunoregulatory role at the periapex: associative and mechanistic evidences from human and experimental periapical lesions” ao periódico. Journal of Endodontics

28/05/2019 Email – Michelle Soriani Azevedo – Outlook

Track your recent Co-Authored submission to JOE

The Journal of Endodontics <eesserver@eesmail.elsevier.com>
Qua, 28/11/2018 11:03
Para: michelle_soriani@hotmail.com <michelle_soriani@hotmail.com>
*** Automated email sent by the system ***

Dear Dr. Michelle Azevedo,

You have been listed as a Co-Author of the following submission:

Journal: Journal of Endodontics
Title: Vasoactive intestinal peptide (VIP) immunoregulatory role at the periapex: associative and mechanistic evidences from human and experimental periapical lesions
Corresponding Author: Gustavo Garlet
Co-Authors: Michelle C Azevedo; Thiago P Garlet; Carolina F Francisconi; Priscila M Colavite; Andre P Tabanez; Jessica L Melchiades; Ana Paula F Trombone; Charles Sfeir; Steven R Little; Renato M Silva;

To be kept informed of the status of your submission, register or log in (if you already have an Elsevier profile).

Register here: https://ees.elsevier.com/joe/default.asp?acw=&pg=preRegistration.asp&user=coauthor&fname=Michelle&lname=Azevedo&email=michelle_soriani@hotmail.com

Or log in: https://ees.elsevier.com/joe/default.asp?acw=&pg=login.asp&email=michelle_soriani@hotmail.com

If you did not co-author this submission, please do not follow the above link but instead contact the Corresponding Author of this submission at garletgp@usp.br;garletgp@yahoo.com.br.

Thank you,

Journal of Endodontics

https://outlook.live.com/mail/inbox/id/AQMkADAwATY0MDABLWMzYzEtNzAzYy0wMAItMDAKAEYAAANMrD6ico%2FoT53B5MPmuyvOBwAMFz... 1/1