UNIVERSIDADE DE SÃO PAULO
FACULDADE DE ODONTOLOGIA DE BAURU

Lincoln de Campos Fruchi

Efficacy evaluation, through micro-CT, of reciprocating and rotary instruments followed by supplementary irrigant-agitation procedures in the retreatment of curved root canals

Avaliação, por meio da micro-CT, da eficácia de instrumentos reciprocantes e rotatórios seguidos por procedimentos suplementares de agitação de irrigantes no retratamento de canais radiculares curvos

BAURU
2018

Lincoln de Campos Fruchi

Efficacy evaluation, through micro-CT, of reciprocating and rotary instruments followed by supplementary irrigant-agitation procedures in the retreatment of curved root canals

Avaliação, por meio da micro-CT, da eficácia de instrumentos reciprocantes e rotatórios seguidos por procedimentos suplementares de agitação de irrigantes no retratamento de canais radiculares curvos

Tese constituída por artigos, apresentada à Faculdade de Odontologia de Bauru da Universidade de São Paulo para a obtenção do título de Doutor em Ciências no Programa de Ciências Odontológicas Aplicadas na área de concentração de Endodontia.

Orientador: Prof. Dr. Marco Antônio Húngaro Duarte

Versão Corrigida

BAURU

2018

F94e

Fruchi, Lincoln de Campos
Efficacy evaluation, through micro-CT, of reciprocating and rotary instruments followed by supplementary irrigant-agitation procedures in the retreatment of curved root canals / Lincoln de Campos Fruchi. – Bauru, 2018.

87 p. : il. ; 30cm.
Tese (Doutorado) – Faculdade de Odontologia de Bauru. Universidade de São Paulo
Orientador: Prof. Dr. Marco Antônio Húngaro Duarte

Nota: A versão original desta tese encontra-se disponível no Serviço de Biblioteca e Documentação da Faculdade de Odontologia de Bauru – FOB/USP.

Comitê de Ética em Seres Humanos da FOB-USP
CAAE: 44736215.9.0000.5417
Data: 20/05/2015

FOLHA DE APROVAÇÃO

DEDICATÓRIA

Dedico este trabalho à **Anna.**

AGRADECIMENTOS

Agradeço à minha esposa, **Bianca Ubiali Guimarães Fruchi, e à** minha filha, **Anna Guimarães Fruchi,** por suportarem os meus longos períodos de ausência, por terem paciência, por me ampararem e por acreditarem em mim.

Ao meu pai, **Armando Fruchi,** que me ensinou a pescar, a praticar a endodontia, e a dar o devido valor à amizade e à honestidade.

À minha mãe, **Clarice Furquim de Campos Fruchi,** que me ensinou a ter fé e a admirar quem tem o dom de ensinar.

Ao meu orientador, Prof. Dr. **Marco Antônio Húngaro Duarte,** pelos ensinamentos, pela amizade e pela paciência; pelos conhecimentos, não só científicos, mas de vida.

Ao Prof. Dr. **Clovis Monteiro Bramante**, que tem sido minha referência na endodontia por três décadas e que, agora, além de referência, me orienta com paciência e sabedoria inesgotáveis.

Aos Professores Dr. **Ivaldo Gomes de Moraes** (in memoriam)**,** Dra. **Flaviana Bombarda de Andrade**, Dr. **Rodrigo Ricci Vivan,** Dr. **Roberto Brandão Garcia e** Dr. **Norberti Bernardineli,** pela amizade e pelos ensinamentos.

Aos funcionários do departamento de Endodontia da FOB-USP **Edimauro de Andrade**, **Suely Regina Bettio** e **Andressa Barraviera,** porque, sem eles, nada disso seria possível.

Aos meus amigos de pós-graduação **Murilo Priori Alcalde**, **Bruno Guimarães, Bruno Cavenago, Pablo Amoroso-Silva, Ronald Oedinola Zapatta , Aldo, Marina Marciano Amanda, Fernanda Fernandes, Francine, Samuel, layla, Thais, Bruno Piazza, Renan Furlan, Yahir, Melissa, Maricel, Jussaro, Mariana, Rafaela, Ericke, Marcelo Pomini, Milena, Talita, Vanessa, Arthur, Pedro, Vitor, Ericsson, Raquel Midena, Marcela Milanezi, Amanda Maliza, Denise Oda, Gislene, Lyz e Michel** , por toda a ajuda e amizade, com os experimentos e os artigos, cada um com sua contribuição e, em especial, ao amigo **Murilo Priori Alcalde,** pela inestimável ajuda nos experimentos, nos conhecimentos e na amizade.

AGRADECIMENTOS INSTITUCIONAIS

À Faculdade de Odontologia de Bauru da Universidade de São Paulo, na pessoa do **Prof. Dr. Carlos Ferreira dos Santos**, digníssimo Diretor da Faculdade de Odontologia de Bauru da Universidade de São Paulo.

À Comissão de Pós-graduação, na pessoa da **Profa. Dra. Izabel Regina Fischer Rubira Bullen**.

Ao Coordenador do programa de Pós-graduação em Endodontia, Prof. Dr. **Marco Antônio Húngaro Duarte.**

Às funcionárias da Pós-Graduação **Ana Letícia Palombo Momesso**, **Fátima Cassador Carvalho** e **Leila Regina da Silva Yerga Sanches,** pelas orientações e pela constante disposição em ajudar.

À **Faculdade de Odontologia de Bauru da Universidade de São Paulo,** que me concedeu a oportunidade de desenvolver esse trabalho.

“Nós somos o que fazemos. O que não se faz, não existe. Portanto, só existimos quando fazemos. Nos dias que não fazemos, apenas duramos”.

Padre Antônio Vieira

RESUMO

Avaliação, por meio da micro-CT, da eficácia de instrumentos reciprocantes e rotatórios seguidos por procedimentos suplementares de agitação de irrigantes no retratamento de canais radiculares curvos

Os retratamentos endodônticos demandam tempo e são difíceis de serem executados. Remover o material de obturação do tratamento original com a máxima eficiência e segurança é uma tarefa complexa que necessita de técnica, paciência e perseverança. Esse material de obturação muitas vezes está contaminado, e impede o acesso às áreas do canal onde permaneceram restos de tecido necrótico e microrganismos, especialmente na região do istmo e nos túbulos dentinários. O objetivo deste trabalho foi avaliar, por meio da microtomografia computadorizada, dois protocolos de desobturação de canais radiculares curvos de raízes mesiais de molares inferiores utilizando um instrumento reciprocante seguido de dois diferentes instrumentos rotatórios fabricados com diferentes ligas metálicas de níquel-titânio. Além da redução dos volumes de material obturador no interior dos canais, foram avaliados a influência do comprimento da patência do canal radicular (glide path) na obturação, extrusão de material obturador após o uso do instrumento reciprocante Reciproc R25, o volume do material de obturação após o retratamento e a presença deste em áreas de istmo. Também foi avaliado o uso de um solvente seguido da agitação do hipoclorito de sódio a 2% com ultrassom (PUI) e com um instrumento plástico acionado em movimento reciprocante. Foram selecionadas 40 raízes mesiais de molares inferiores com curvatura média de 25 graus que foram divididos em dois grupos de forma homogênea quanto ao comprimento, à curvatura e à anatomia (classes II e IV de acordo com a classificação de Vertucci) dos canais radiculares. Os dentes foram instrumentados com o instrumento Reciproc R25 e obturados com a técnica do cone único e com cimento AHPlus. Previamente ao uso do instrumento Reciproc R25, obteve-se a patência inicial do canal, ou seja, criou-se um glide path, com os instrumentos PathFile em toda a extensão do canal no Grupo RHPui e 1 mm aquém do comprimento total do canal no Grupo RMEasy. Os dois grupos foram definidos de acordo com o protocolo de retratamento adotado, a saber, RHPui

(Reciproc + Hyflex + PUI) e RMEasy (Reciproc + Mtwo + EasyClean). Nos dois grupos, a remoção do material obturador original foi realizada com o instrumento Reciproc R25, sendo que no grupo RHPui foi utilizado o solvente xilol até a proximidade do terço médio, não sendo utilizado solvente no terço apical. No Grupo RHPui, utilizou-se, então, o instrumento Hyflex 40.04 feito com liga de niquel-titânio CM ("control memory" ou de memória controlada) e, por último, utilizou-se o solvente xilol por um minuto na câmara pulpar, seguido de irrigação ultrassônica passiva (PUI) com solução de hipoclorito de sódio a 2% utilizando o instrumento Irrisonic, até o limite de 2 mm aquém do comprimento de trabalho. No Grupo RMEasy, foi utilizado o instrumento Mtwo 40.04 fabricado com liga de níquel-titânio convencional e, a seguir, também se utilizou o solvente xilol por um minuto na câmara pulpar seguido de uma agitação mecânica do hipoclorito de sódio a 2% com o instrumento plástico EasyClean em movimento reciprocante até o limite do comprimento total de trabalho. Os dois grupos foram re-obturados com a técnica de condensação vertical aquecida com cone de guta-percha correspondente ao instrumento final e com cimento AHPus. Foram realizadas microtomografias após cada procedimento para avaliar o volume de material remanescente, a extrusão após o uso dos instrumentos reciprocantes, o volume final da obturação ao final do retratamento e o volume na área de istmo, tanto após a obturação original quanto após a re-obturação. Os resultados obtidos mostraram que, no tratamento inicial, a patência do canal (ou glidepath) realizado com instrumentos Pathfile previamente ao uso dos instrumentos Reciproc R25 possibilitou que a obturação dos canais atingisse um limite significativamente ($P < 0,05$) mais próximo ao forame apical no grupo RHPui, onde o glidepath foi realizado em toda a extensão do canal. Em relação aos diferentes protocolos de retratamento, não houve remoção completa do material obturador do interior dos canais nos dois grupos estudados em todos os níveis avaliados, sem diferença estatisticamente significativa ($P > 0,05$) entre os grupos com relação a essa variável. Na avaliação intragrupo, houve uma diferença estatisticamente significativa ($P < 0,05$) entre os passos do procedimento em relação à redução do volume de material obturador, tanto na extensão total do canal, quanto nos seus diferentes níveis, com exceção do terço médio após o Hyflex, no terço cervical após o Mtwo e no terço médio após o EasyClean. O volume do material obturador final foi significativamente maior ($P < 0,05$) do que o volume do material obturador original, nos dois grupos estudados. O volume

de material obturador na região do istmo foi significativamente maior ($P < 0,05$) após a re-obturação nos dois grupos, sendo significativamente maior ($P < 0,05$) no grupo RMEasy do que no grupo RHPui. Não houve diferença estatística ($P > 0,05$) entre os grupos com relação ao tempo total despendido na remoção do material obturador ($P > 0,05$), sendo 209,40 s para o Grupo RHPui e 227,40 s para o Grupo RMEasy. Não houve diferença estatística ($P > 0,05$) entre os grupos com relação ao volume da extrusão de material obturador, sendo 0,0258 mm^3 (0 – 0,954) no Grupo RHPui e 0,0037 mm^3 (0 – 0,565) no Grupo RMEasy. Os testes de Shapiro-Wilks, Mann-Whitney, Wilcoxon, Friedman e Dunn foram utilizados na análise dos dados.

Palavras-chave: Micro-tomografia computadorizada, movimento reciprocante, tratamento de canal radicular, sistemas rotatórios, canais radiculares curvos, patência do canal radicular.

ABSTRACT

Efficacy evaluation, through micro-CT, of reciprocating and rotary instruments followed by supplementary irrigant-agitation procedures in the retreatment of curved root canals

Endodontic retreatments are time-consuming and difficult to perform. Removing the root canal filling material of the original treatment with maximum efficiency and safety is a complex task that requires a good technique, patience and perseverance. This filling material is often contaminated and prevents access to areas of the canal harboring bacteria and remnants of necrotic tissue, especially in the isthmus region and in dentinal tubules. The aim of this study was to use micro-computed tomography to evaluate two protocols for the removal of root canal filling material from curved root canals of the mesial roots of mandibular molars using a reciprocating instrument followed by two different rotary instruments manufactured with different nickel-titanium alloys. The reduction in the volume of the filling material inside the root canals was evaluated. Assessments were also made of the influence of the glide path extension on root canal obturation, the extrusion of filling material after the use of the reciprocating instrument, the volume of filling material after retreatment and its presence in isthmus areas. In addition, the use of a solvent and the agitation of a 2% sodium hypochlorite solution using either passive ultrasonic irrigation (PUI) or a plastic instrument in reciprocating motion were evaluated. A total of 40 mesial roots of mandibular molars with a mean curvature of 25 degrees were selected. The teeth were radiographed digitally in the buccolingual and mesiodistal directions, with a digital X-ray system (Schick CDR; Schick Technologies, Long Island, NY), using an exposure time of 0.16 s. This was done in order to select the teeth and then compose two groups with similar characteristics to ensure their anatomic homogeneity. Group homogeneity in terms of anatomy, root canal length, curvature angle, and Vertucci classification type II and IV were confirmed and showed that the study groups were well balanced. Two groups were defined according to the retreatment protocol adopted, namely RHPui (Reciproc + Hyflex + PUI) and RMEasy (Reciproc + Mtwo + EasyClean). The teeth were instrumented with the Reciproc R25 instrument and filled using the single-cone technique and AHPlus cement. Prior to the use of this instrument, canal patency was

achieved by creating a glide path with PathFile instruments, throughout the entire extension of the canal in Group RHPui, and up to 1 mm short of the total canal length in Group RMEasy. In both groups, the original filling material was removed with the Reciproc R25 instrument. Xylene was used as a solvent in Group RHPui up to the middle third, but not in the apical area, in the later steps of instrumentation with Reciproc R25. In Group RHPui, the Hyflex 40.04 instrument, made with a CM nickel-titanium alloy, was used. After that, xylene solvent was applied for one minute in the pulp chamber, followed by passive ultrasonic irrigation (PUI) with 2% sodium hypochlorite using an irrisonic instrument, applied up to 2 mm short of the working length. In Group RMEasy, the Mtwo 40.04 instrument, made with a conventional nickel-titanium alloy, was used. Xylene solvent was also used in the pulp chamber for one minute, followed by application of a 2% sodium hypochlorite solution agitated mechanically with an EasyClean plastic instrument in reciprocating motion up to the full working length. The two groups were re-obturated using the warm vertical condensation technique, with a gutta-percha cone corresponding to the final instrument, and with AHPus cement. Micro-CT scans were performed after each procedure to evaluate the volume of the remaining material, the extrusion after the use of the reciprocating instruments, the final volume of the obturation at the end of the retreatment and the filling material volume in the isthmus area, both after the original obturation and after re-obturation. The results showed that the initial filling was significantly closer to the apical foramen in Group RHPui than in Group RMEasy, after the initial treatment. After performing the retreatment protocols, the complete removal of filling material from inside the root canals was not achieved in either study group, with no statistically significant difference ($P > 0.05$) between groups regarding this variable. In the intra-group evaluation, a statistically significant difference ($P < 0.05$) was found between the procedural steps regarding the reduction in filling material volume, both in the total canal length and at its different levels, except for the middle third after HyFlex, the cervical third after Mtwo, and the middle third after EasyClean. The volume of the final filling material was significantly higher ($P < 0.05$) than the volume of the original filling material in both study groups. The volume of filling material in the isthmus region was significantly higher after re-obturation in both groups ($P < 0.05$), and this increase was greater in the RMEasy Group. There was no statistically significant difference ($P > 0.05$) between groups regarding the total amount of time

expended in the removal of filling material (P > 0.05), namely 209.40 s for the RHPui Group and 227.40 s for the RMEasy Group. There was also no statistically significant difference (P > 0.05) between groups regarding the volume of extruded filling material, namely 0.0258 mm3 (0 – 0.954) in the RHPui Group and 0.0037 mm3 (0 – 0.565) in the RMEasy Group. The Shapiro-Wilks, Mann-Whitney, Wilcoxon, Friedman and Dunn tests were used in the data analysis.

Keywords: Micro-computed tomography, reciprocating motion, root canal treatment, rotary systems, curved root canals, glide path.

LISTA DE ABREVIATURAS E SIGLAS

%	percentagem
<	menor
>	maior
#	diâmetro de ponta
=	igual
º	grau
EDTA	ácido etileno diaminotetracético
kV	quilovolt
mA	miliampere
micro-CT	microtomografia computadorizada
min	minutos
mL	mililitro
mm	milímetro
mm^3	milímetro cúbico
n	número
NaOCl	hipoclorito de sódio
NiTi	níquel-titânio
P	significância estatística
PUI	irrigação ultrassônica passiva
µm	micrômetro

SUMMARY

1 INTRODUCTION

1 INTRODUCTION

Accomplishing a successful endodontic re-treatment after failure of the original treatment, either by the appearance of signs and symptoms of apical periodontitis or by the persistence or worsening of this condition, represents a great challenge in view of the great technical difficulty and extensive amount of time involved in retreatment procedures, especially in curved canals (WILCOX et al., 1987; SCHIRRMEISTER et al., 2006a; SCHIRRMEISTER et al., 2006b). The elimination of bacteria and remnants of necrotic tissue and contaminated filling material in areas of difficult access is necessary to achieve endodontic re-treatment success (ZEHNDER & PAQUÉ, 2011). When faced with endodontic treatment failure, the method of choice is non-surgical re-treatment owing to its high success rate, leaving the surgical re-treatment option for cases in which adequate repair cannot be achieved after conservative re-treatment has been attempted (BERGENHOLTZ et al., 1979; TORABINEJAD et al., 2009).

Several methods have been proposed to achieve an efficient reduction in the original filling material during endodontic re-treatment. Manual instruments are not only difficult to use, but can lead to deviations and perforations (GARIP; GÜNDAY, 2001). Rotary instruments entail reduced re-treatment times and less operator fatigue (SCHIRRMEISTER et al., 2006a; SCHIRRMEISTER et al., 2006b). The use of balanced forces, as proposed by Roane et al. in 1985, enables the maintenance of the original canal shape (ROANE et al., 1985). Yared used NiTi instruments based on this concept of balanced forces, which proved efficient in canal shaping (YARED, 2008). Several studies were carried out with this principle, using different instruments (FRUCHI et al., 2014; BRAMANTE et al., 2010; ZUOLO et al., 2013; RIOS et al., 2014; RÖDIG et al., 2014). The question of whether or not to create a glide path, i.e., achieving canal patency, prior to the use of these instruments (BERUTTI et al., 2012; DE-DEUS et al., 2013; ALOVISI et al., 2017) and the influence glide path creation on root canal filling (FRUCHI et al., 2017) have also been evaluated. The use of different rotary, reciprocating and manual instruments, whether or not associated with solvents and whether or not followed by the agitation of irrigating chemical substances, in the removal of filling material, has been studied (CAVENAGO et al., 2014; YÜRÜKER et al., 2016; ROSSI-FEDELE; AHMED, 2017). The effect of irrigant agitation or solvent

use on filling removal effectiveness is controversial (FRUCHI et al., 2014; BUENO et al., 2006; BARRETO et al., 2016).

The micro-CT method used in this study has been shown to be effective in the evaluation of endodontic re-treatment, particularly when using additional procedural steps, as in the present study (FRUCHI et al., 2014; BARLETTA et al., 2008; HAMMAD et al., 2008; HAMMAD et al., 2009; ALOVISI et al., 2017). The two-dimensional evaluation methods used in previous studies are less accurate, and the cleavage used in them makes it unfeasible to reuse the same specimens in the evaluation of subsequent procedures (WILCOX et al., 1987; ZUOLO et al., 2013; RIOS et al., 2014). In our study, micro-CT was also used to evaluate the volume of filling material extruded during instrumentation with the reciprocating instrument. To the best of our knowledge, this method has not been used previously, and studies on the extrusion of debris during endodontic treatment have been conducted primarily through the collection of material in paper containers or filters followed by their weighing before and after instrumentation (BÜRKLEIN; SCHÄFER, 2012; DINCER et al., 2015; ÇANAKÇI et al., 2016).

The main objective of the present study was to evaluate the combined use of instruments operated in different kinematics and manufactured with NiTi alloys submitted to different treatments, with or without a solvent and followed (or not) by ultrasonic or mechanical irrigant agitation. Additional assessments were made regarding the amount of time expended in removing the filling material and the volume of extruded filling material after the use of the reciprocating instrument. The differences between the volumes of the initial and final obturations throughout the entire length of the canal, at the different canal levels, and in the isthmus area were also evaluated.

2 ARTICLES

2 ARTICLES

2.1 Article 1 – Microtomography evaluation of glide path length influence on volume and apical limit of root canal fillings[1].

[1] Fruchi LC, Vivan RR, Alcalde MP *et al.* (2017) Microtomography evaluation of glide path length influence on volume and apical limit of root canal fillings. Dental Press Endod. 2017;7(2):15–20.

original article

Microtomography evaluation of glide path length influence on volume and apical limit of root canal fillings

Lincoln de Campos **FRUCHI**[1]
Rodrigo Ricci **VIVAN**[1]
Murilo Priori **ALCALDE**[1]
Flaviana Bombarda **ANDRADE**[1]
Marco Antonio Hungaro **DUARTE**[1]

DOI: https://doi.org/10.14436/2358-2545.7.2.015-020.oar

ABSTRACT

Introduction: The objective of the present study was to evaluate the influence of the glide path length on the apical volume and limit of root canal fillings using PathFile instruments. **Methods:** Thirty-four root canals from seventeen mesial roots of mandibular molars were divided into two groups based on the glide path length created using #13, 16, and 19 PathFile instruments: Group 1 (G1) - full root canal length; Group 2 (G2) - 1 mm short of the apical foramen. Next, the root canals were instrumented with the Reciproc R25 until 1 mm short of the apical foramen in both groups and filled with AHPlus and gutta-percha using the single cone technique. The volume of material used to fill the 3 mm apical portions of the canals and the distance from the filling to the apical foramen were determined through microtomography. The data were compared statistically and the Mann Whitney test was used to evaluate differences between groups. **Results:** No statistically significant difference was observed for the volume of the material used to fill the canals between groups ($P > 0.05$). However, the distance between the apical limit of the filling material and the apical foramen was significantly different between groups G1 (0.4335) and G2 (1.241 mm) ($P < 0.05$). **Conclusions:** The creation of a glide path within the root canal length favors a limit of the root canal filling closer to the apex that was statically significant, although it was not significant regarding to the volume.

Keywords: Endodontics. Root canal obturation. X-Ray Microtomography.

How to cite: Fruchi LC, Vivan RR, Alcalde MP, Andrade FB, Duarte MAH. Microtomography evaluation of glide path length influence on volume and apical limit of root canal fillings. Dental Press Endod. 2017 May-Aug;7(2):15-20.
DOI: https://doi.org/10.14436/2358-2545.7.2.015-020.oar

[1]Universidade de São Paulo, Faculdade de Odontologia de Bauru, Departamento de Dentística, Endodontia e Materiais Odontológicos, Bauru/SP, Brazil.

» The authors report no commercial, proprietary or financial interest in the products or companies described in this article.

Submitted: June 02, 2016. Revised and accepted: March 14, 2017.

Contact address: Lincoln de Campos Fruchi
Rua Frei Caneca, 1212, cj. 84
Consolação, São Paulo/SP - CEP: 01307002
E-mail: lincolnfruchi@usp.br

Introduction

Maintenance of the original anatomy of root canals while using rotary instruments without inflicting any damage to the tooth has been a major concern. However, the establishment of a glide path before using rotary instruments is known to address this concern.[1-5]

The glide path is the creation of root canal patency from the open orifice canal access to the apical foramen. It creates an enlargement within the root canal before instrumentation with rotary or reciprocating motion instruments, with the intention of avoiding stresses that could fracture the instruments.6 Furthermore, the ability to reach the working length could be improved by avoiding the so-called "taper-lock effect".[2,3] The use of hand instruments to create a glide path is technically difficult and risky when compared to rotary instruments.[2,4] The manufacturer of the Reciproc instrument believes that the creation of a glide path prior to the use of reciprocating instruments is not necessary in most treatments.[7,8]

In recent years, the use of a glide path before root canal instrumentation has been studied to determine the various factors that influence root canal transportation, deformation, and torsional and fatigue stress.[2-5,9] However, there are no reports that evaluate the influence of the glide path limit with PathFile instruments (Dentsply; Maillefer, Ballaigues, Switzerland) on the apical volume and limit of the root canal filling.

The purpose of the present study was to create a glide path using PathFile instruments at different working lengths, before the use of a rotary instrument (Reciproc; VDW, Munich, Germany), and evaluate its influence on the apical volume and limit of the root canal obturation. The null hypothesis was that the length of the glide path does not interfere with the limit and apical volume of the root canal filling.

Material and methods

The present study was conducted under the approval of the Ethics Committee of the Bauru School of Dentistry, University of São Paulo (1.093.113). Forty human mandibular molars with curved mesio-buccal canals, donated by the Human Teeth Bank of the University of São Paulo, São Paulo, Brazil, were used in the study.

The teeth were digitally radiographed in the bucco-lingual and mesio-distal directions with an exposure time of 0.16 s using the Schick CDR X-ray digital system (Schick Technologies, Long Island, NY). This was done in order to select the teeth and divide them into two groups with similar characteristics, as the root canal length and curvature, and the Vertucci classification (II and IV) that were distributed in a balanced way to ensure the homogeneity between the groups regarding the anatomy. The teeth that were chosen were those which the apical foramens were possible to bypass with slight resistance to the tip of a #10 K file instrument (Dentsply; Maillefer, Ballaigues, Switzerland). All root canal treatments and measures were made by the same skilled professional.

The crowns of the teeth were flattened to a length of 16 mm with the aid of a diamond disc (FKG, Dentaire, Switzerland). The patency and working lengths of the root canals were established by inserting the tip of a #10 K file until the apex and observing them with an operatory microscope with 8X magnification (Alliance, São Paulo, Brazil). PathFiles files (Dentsply; Maillefer, Ballaigues, Switzerland) #13, 16, and 19 were used to make the glide paths.

The teeth were divided into two groups based on the length of insertion: Group 1 (G1), Pathfiles files were inserted until the full length of the canal: Group 2 (G2), Pathfiles files were inserted until 1 mm before the full canal length, which correspond to 1 mm below the patency.

The PathFiles were used with VDW electric motors (VDW, Munich, Germany) at a speed of 300 rpm and a torque of 60 g•cm. Subsequently, all teeth were instrumented with R25 Reciproc files (VDW) until the working length, established at 1 mm short of the full canal length, corresponding to 1 mm from patency. The Reciproc instrument was used with the corresponding VDW electric motor as per the Reciproc program; with three in and out pecking motions using light apical pressure until it reached the working length. During the glide path formation and root canal instrumentation, 2.5% sodium hypochlorite (Formula & Ação Farmácia, São Paulo, SP, Brazil) was used as an irrigant. Final irrigation was done with 1 ml of 17% EDTA (Formula & Ação Farmácia, São Paulo, SP, Brazil) for 1 minute followed by a final rinse with

2 ml of 2.5% sodium hypochlorite. The canals were then dried with R25 paper points and filled with R25 single cones (VDW) and AH Plus sealer (Dentsply) using the single cone technique. The teeth were again digitally radiographed in the bucco-lingual and mesio-distal directions with an exposure time of 0.16 s using the Schick CDR X-ray digital system (Schick Technologies, Long Island, NY) in order to evaluate the quality of the root canal filling.

The crowns were temporarily sealed with Citodur (Dorident, Wien, Austria) temporary restorative material and stored at 37°C and 100% humidity for 3 months.

After the storage period, the teeth were mounted on a custom attachment and scanned in a micro computed tomography system (micro-CT) (SkyScan 1174; Bruker-microCT, Kontich, Belgium) using the following voxel parameters: 50 kV, 800 µA, and an isotropic voxel size of 39 µm. Other parameters used were 360° rotation, 0.8° step rotation and 0.5 mm aluminum filter. The samples were reconstructed with the NRecon software version 1.6.3 and the axial cross sections were obtained with parameters of Beam Hardening Correction of 30 %, Ring Artefact Correction of 4.

Subsequently, 17 teeth, 9 teeth from G1(n = 18 root canals) and 8 teeth from G2 (n = 16 root canals), presenting Vertucci type IV canals (two independent canals with a mean curvature angle of 24° and mean length of 10.75 mm) were chosen for analysis. The other 23 teeth were excluded because they were either corresponding to Vertucci type II or due to anatomic discrepancies between groups.

Volumetric analyses of the 3D models were made with similar parameters with the CTAn v.1.12 software (Bruker-microCT), divided into 3 segments of 3 mm each, which corresponded to the apical, middle and cervical portions. The angle of the root canal curvature was measured as described by Schneider.[10] The volume of the filling material in the 3 mm apical close to the foramen was calculated from the binarized area inside the region of interest. The canal lengths and distance of the filling material to the apex were measured through the path measure tool of CTAn v.1.12 software (Bruker-microCT)), in bucco-lingual and mesial-distal views. The longer distances found were considered. The softwares Data Viewer v.1.5.1 64-bit (Brucker-microCT) and CTVol v.2.3.1 (Bucker-microCT) were used for qualitative evaluation.

Statistical analysis was performed using the Prism 6.0 software (GraphPad Software Inc., L Jolla, CA, US). The normality of the data was analyzed by the Shapiro-Wilks test, and due to the absence of normality, the Mann Whitney test was used to compare the groups regarding the volume of the filling material in the apical third and length from the end of the filling material to the apical foramen. The significance level was established at 5%.

Results

Table 1 presents the median, minimum and maximum values of apical volumes of the filling material, and apical lengths (distance from the end of the filling material to the apical foramen). The volumes of filling material did not significantly differ between the two groups ($P > 0.05$). On the other hand, a significant difference was observed for the lengths of the canal filled between the groups, G1: 0.4335, 0 – 1.69 mm; G2: 1.241 mm, 0 – 2 mm ($P < 0.05$).

Table 1. Median, maximum and minimum values of the apical volumes and apical lengths (distance from the end of the filling material to the apical foramen) for the two groups. (G1 and G2).

	Apical volumes (mm3)		Apical lengths (mm)	
	G1	G2	G1	G2
Median	0.7581[a]	0.4388[a]	0.4335[a]	1.241[b]
Minimum	0.2235	0.2072	0	0.0000
Maximum	1.008	1.062	1.69	2.000

G1: the glide path length was created along the full canal length; G2: the glide path length was created until 1 mm short of the full canal length. Different letters indicate the statistical significance differences ($P < .05$).

Discussion

The null hypothesis was rejected since the apical limit of the glide path influenced the apical limit of the root canal filling. Several studies have reported the importance of creating a glide path before instrumentation, and its influence on the fatigue and torsional resistance, as well as deviation and/or preservation of the root canal anatomy.[2-4,11] One study reported that pre-flaring or creation of a glide path before instrumentation using Reciproc instruments is not necessary in most root canal treatments.[8] However, in the present study, the apical limits of the root canal filling ranged between 0 and 1.69 mm for all teeth in G1 and 0 and 2 mm in G2. The teeth from G1 presented an apical limit of filling closer to the foramen when compared with those from G2 (mean difference of 0.60 mm) (Fig 1).

In this study the canals were instrumented to the same master apical file size and were filled with a corresponding single cone obturation technique. In this situation the volume of filling material in the apical region would be the same. In the present study, Reciproc files reached the working length easier and with more precision in G1 than in G2, probably due to the bigger preflaring that the PathFile made near the apical foramen in G1. It could make difference in the volume and length of the filling material between groups. Furthermore, most sealers and gutta-percha cannot be differentiated through micro-CT, they were considered as the same unit.[12] Therefore, achieving patency at the full canal length avoided the vapor lock effect, allowing better irrigation of the apical region[13] which could allow the filling material (sealer and/or gutta-percha) to reach the apical area easier.

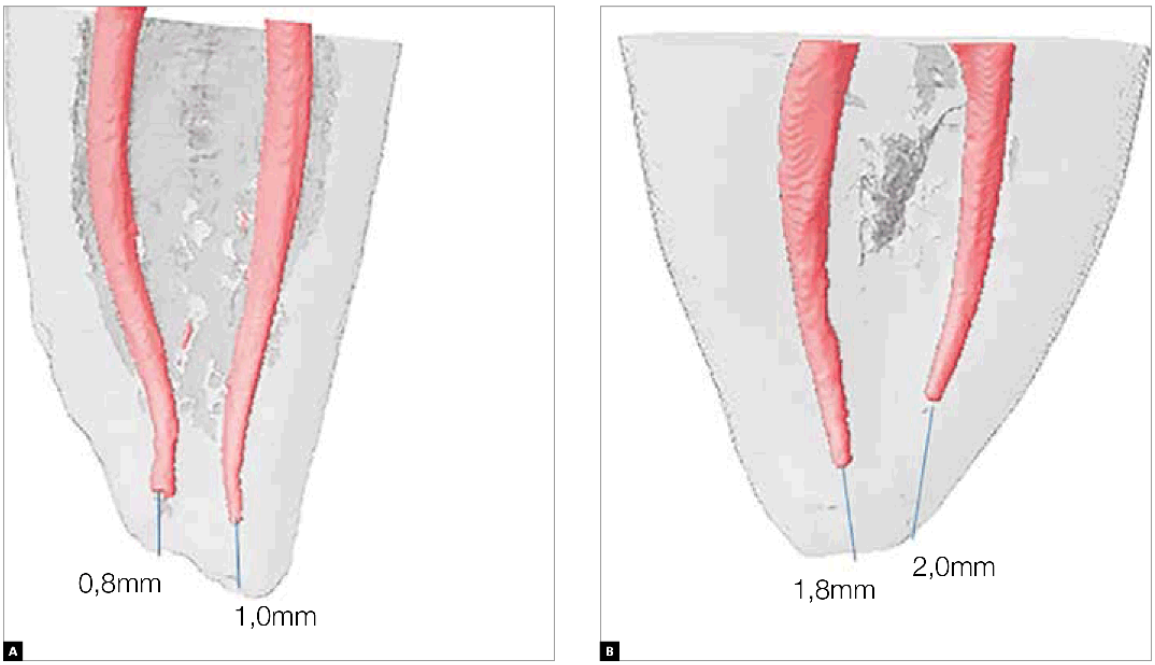

Figure 1. Micro-computed tomography reconstructions of representative samples from Group 1 (**A**) and Group 2 (**B**). The filling material in the canal using PathFile instruments along the full canal length (**A**), and 1 mm shorter from the full canal length (**B**).

In G1 the instruments are in contact with a greater surface area of the root canal walls. Clinically it could lead to better cleaning and disinfection, which can favor the predictability of the success of the root canal treatment.[14,17] and, according to the present study, a better limit of the filling. Although the limit of the instrumentation and the filling material is controversial, several studies showed that these limits should be within 2 mm from the radiographic apex, at or short of the apical constriction.[16-18] Therefore, the relevance of this study evaluating the volume and length of filling material between groups with the glide path in different lengths is justified.

In the present study, the working length was determined by observing the tip of the instrument at the root apex with the aid of an operatory microscope.

In clinical settings, the determination of the working length using electronic foramen locators is a reliable method, with the added advantage of reducing radiographic exposure.[19,20]

The full length of the canals, curvature degrees, filling material volume, and the end limits inside the canals were evaluated by micro-CT, which is an excellent method for the evaluation of root canals.[21] The volume of the filling material has also been evaluated through microtomography.[22,23]

Studies on root canal deviation, thickness of the remaining dentin, and centering ability with or without the creation of a glide path[24,25] have reported that glide paths favor lesser root canal deviation as well as centering of the root canal instrumentation.

In this study the results showed that the creation of a glide path within the root canal length favors a limit of instrumentation and filling closer to the apex. Regarding the volume of filling material, the glide path within the root canal length (G1) showed greater volume than the group where it was 1 mm short of the foramen (G2), although it was not statistically different. Further studies should be conducted in order to better understand the influence of the glide path limit on the extrusion of debris.

Within the limits of the present study, it was concluded that the use of PathFiles for the creation of a glide path along the full length of the root canal, before the use of Reciproc R25 instruments, enabled the limit of the root canal filling to be located closer to the apex.

Acknowledgements

This study was supported by State of São Paulo Research Foundation, FAPESP (2015/03829-1).

References

1. Alves VO, Bueno CE, Cunha RS, Pinheiro SL, Fontana CE, Martin AS. Comparison among manual instruments and PathFile and Mtwo rotary instruments to create a glide path in the root canal preparation of curved canals. J Endod. 2012 Jan;38(1):117-20.
2. Berutti E, Cantatore G, Castellucci A, Chiandussi G, Pera F, Migliaretti G, et al. Use of nickel-titanium rotary PathFile to create the glide path: comparison with manual preflaring in simulated root canals. J Endod. 2009 Mar;35(3):408-12.
3. Berutti E, Paolino DS, Chiandussi G, Alovisi M, Cantatore G, Castellucci A, et al. Root canal anatomy preservation of WaveOne reciprocating files with or without glide path. J Endod. 2012;38(1):101-4.
4. Pasqualini D, Bianchi CC, Paolino DS, Mancini L, Cemenasco A, Cantatore G, et al. Computed micro-tomographic evaluation of glide path with nickel-titanium rotary PathFile in maxillary first molars curved canals. J Endod. 2012;38(3):389-93.
5. Pasqualini D, Mollo L, Scotti N, Cantatore G, Castellucci A, Migliaretti G, et al. Postoperative pain after manual and mechanical glide path: a randomized clinical trial. J Endod. 2012;38(1):32-6.
6. Uroz-Torres D, González-Rodríguez MP, Ferrer-Luque CM. Effectiveness of a manual glide path on the preparation of curved root canals by using Mtwo rotary instruments. J Endod. 2009;35(5):699-702.
7. Bürklein S, Poschmann T, Schäfer E. Shaping ability of different nickel-titanium systems in simulated S-shaped canals with and without glide path. J Endod. 2014;40(8):1231-4.
8. De-Deus G, Arruda TE, Souza EM, Neves A, Magalhães K, Thuanne E, et al. The ability of the Reciproc R25 instrument to reach the full root canal working length without a glide path. Int Endod J. 2013;46(10):993-8.
9. Nazarimoghadam K, Daryaeian M, Ramazani N. An in vitro comparison of root canal transportation by Reciproc file with and without glide path. J Dent (Tehran). 2014;11(5):554-9.
10. Schneider SW. A comparison of canal preparations in straight and curved root canals. Oral Surg Oral Med Oral Pathol. 1971;32(2):271-5.
11. Dhingra A, Manchanda N. Modifications in canal anatomy of curved canals of mandibular first molars by two glide path instruments using CBCT. J Clin Diagn Res. 2014;8(11):ZC13-7.
12. Hammad M, Qualtrough A, Silikas N. Evaluation of root canal obturation: a three-dimensional in vitro study. J Endod. 2009;35(4):541-4.
13. Vera J, Hernández EM, Romero M, Arias A, van der Sluis LW. Effect of maintaining apical patency on irrigant penetration into the apical two millimeters of large root canals: an in vivo study. J Endod. 2012;38(10):1340-3.
14. Versiani MA, Leoni GB, Steier L, De-Deus G, Tassani S, Pecora JD, et al. Micro-computed tomography study of oval-shaped canals prepared with the self-adjusting file, Reciproc, WaveOne, and ProTaper universal systems. J Endod. 2013;39(8):1060-6.
15. Alves FR, Almeida BM, Neves MA, Moreno JO, Rôças IN, Siqueira JF. Disinfecting oval-shaped root canals: effectiveness of different supplementary approaches. J Endod. 2011;37(4):496-501.
16. Ricucci D. Apical limit of root canal instrumentation and obturation, part 1. Literature review. Int Endod J. 1998;31(6):384-93.
17. Ricucci D, Langeland K. Apical limit of root canal instrumentation and obturation, part 2. A histological study. Int Endod J. 1998;31(6):394-409.
18. Wu MK, Wesselink PR, Walton RE. Apical terminus location of root canal treatment procedures. Oral Surg Oral Med Oral Pathol Oral Radiol Endod. 2000;89(1):99-103.
19. Vasconcelos BC, Frota LM, Souza T de A, Bernardes RA, Duarte MA. Evaluation of the maintenance of the apical limit during instrumentation with hybrid equipment in rotary and reciprocating modes. J Endod. 2015;41(5):682-5.
20. Pereira KF, Silva PG, Vicente FS, Arashiro FN, Coldebella CR, Ramos CA. An in vivo study of working length determination with a new apex locator. Braz Dent J. 2014;25(1):17-21.
21. Grande NM, Plotino G, Gambarini G, Testarelli L, D'Ambrosio F, Pecci R, et al. Present and future in the use of micro-CT scanner 3D analysis for the study of dental and root canal morphology. Ann Ist Super Sanita. 2012;48(1):26-34.
22. Fruchi L de C, Ordinola-Zapata R, Cavenago BC, Hungaro Duarte MA, Bueno CE, De Martin AS. Efficacy of reciprocating instruments for removing filling material in curved canals obturated with a single-cone technique: a micro-computed tomographic analysis. J Endod. 2014 July;40(7):1000-4.
23. Rödig T, Reicherts P, Konietschke F, Dullin C, Hahn W, Hülsmann M. Efficacy of reciprocating and rotary NiTi instruments for retreatment of curved root canals assessed by micro-CT. Int Endod J. 2014;47(10):942-8.
24. Zanette F, Grazziotin-Soares R, Flores ME, Camargo Fontanella VR, Gavini G, Barletta FB. Apical root canal transportation and remaining dentin thickness associated with ProTaper Universal with and without PathFile. J Endod. 2014;40(5):688-93.
25. Elnaghy AM, Elsaka SE. Evaluation of root canal transportation, centering ratio, and remaining dentin thickness associated with ProTaper Next instruments with and without glide path. J Endod. 2014;40(12):2053-6.

2.2 Article 2 - Micro-CT assessment of filling removal effectiveness of two hybrid instrumentation protocols followed by supplementary irrigant-agitation procedures

The article presented in this thesis was prepared according to the author guidelines of the International Endodontic Journal for article submission

Micro-CT assessment of filling removal effectiveness of two hybrid instrumentation protocols followed by supplementary irrigant-agitation procedures

Lincoln de Campos Fruchi (corresponding author)
PhD Student, Department of Operative Dentistry, Endodontics and Dental Materials, Bauru School of Dentistry, University of São Paulo
Address: Al. Dr. Octávio Pinheiro Brisolla, 9-75, Bauru, SP, Brazil, ZIP: 17012-901, Phone:+55 14 3235-8344, E-mail: lincolnfruchi@.usp.br

Murilo Priori Alcalde
Associate Professor, Department of Operative Dentistry, School of Dentistry, Sagrado Coração University
Address: Rua Irmã Arminda, 10-50, Bauru, SP, Brazil, ZIP: 17011-160, Phone: +55 14 2107-7000, E-mail: murilo.alcalde@usp.br

Pablo Andres Amoroso-Silva
Professor, Department of Operative Dentistry, School of Dentistry, State University of Londrina
Address: Rodovia Celso Garcia Cid (PR 445), Km 380, Londrina, PR, Brazil, ZIP: 86057-970, Phone: +55 43 3371-4746, E-mail: pabloamoroso@usp.br

Rodrigo Ricci Vivan
Professor, Department of Operative Dentistry, Endodontics and Dental Materials, Bauru School of Dentistry, University of São Paulo
Address: Al. Dr. Octávio Pinheiro Brisolla, 9-75, Bauru, SP, Brazil, ZIP: 17012-901, Phone: +55 14 3235-8344, E-mail: rodrigo.vivan@fob.usp.br

Clovis Monteiro Bramante
Professor, Department of Operative Dentistry, Endodontics and Dental Materials, Bauru School of Dentistry, University of São Paulo
Address: Al. Dr. Octávio Pinheiro Brisolla, 9-75, Bauru, SP, Brazil, ZIP: 17012-901, Phone +55 14 3235-8344, E-mail: clobra@uol.com.br

Marco Antonio Hungaro Duarte
Professor, Department of Operative Dentistry, Endodontics and Dental Materials, Bauru School of Dentistry, University of São Paulo
Address: Al. Dr. Octávio Pinheiro Brisolla, 9-75, Bauru, SP, Brazil, ZIP: 17012-901, Phone: +55 14 3235-8344, E-mail: mhungaro@fob.usp.br

Micro-CT assessment of filling removal effectiveness of two hybrid instrumentation protocols followed by supplementary irrigant-agitation procedures

ABSTRACT

Aim: To assess the filling removal effectiveness of different reciprocating instrumentation protocols, followed by additional rotary instrumentation and supplementary irrigant agitation in curved root canals. **Methodology:** Forty mesial roots of mandibular molars were divided into two groups (n = 20). In Group RHPui, initial filling removal was performed with a Reciproc R25 instrument, followed by a #40 HyFlex instrument and passive ultrasonic irrigation (PUI). In Group RMEasy, initial filling removal was performed as in Group RHPui, followed by a #40 MTwo instrument and irrigant agitation with a plastic reciprocating instrument (EasyClean). After each procedural step, the roots were scanned using micro-tomography. Re-obturation was performed using the warm vertical condensation technique. A significance level of 5% was adopted. **Results**: Filing material was not completely removed in either group, with no significant difference between groups. There were significant intragroup differences between the successive procedural steps in terms of filling removal, albeit not in all of the root canal levels evaluated. A significant increase ($P < 0.05$) in filling material volume was observed in both groups after re-obturation. No significant difference was found regarding the amount of extruded debris and the effective time of reciprocating instrumentation. **Conclusions:** None of the protocols completely removed the filling material. A supplementary step for irrigant agitation proved effective in promoting enhanced cleaning and filling removal in both groups. The best results

were found for the apical level after PUI. The two retreatment protocols evaluated increased the volume of filling material in the root canal system, including the isthmus.

KEY WORDS

Root canal retreatment, Rotary instrumentation systems, Curved root canals, Reciprocating motion, Micro-computed tomography, Irrigation.

INTRODUCTION

The persistence of apical periodontitis after primary endodontic treatment is mostly caused by bacteria that remain unaffected by antimicrobial procedures (Siqueira & Rôças 2008). When apical periodontitis persists, nonsurgical retreatment should be considered the primary therapeutic approach. Endodontic surgery has lower success rates when long-term outcomes are considered (Ng *et al.* 2008, Torabinejad *et al.* 2009).

Nickel-titanium (NiTi) rotary and reciprocating systems have proven safer and more efficient for endodontic retreatment than hand files (Betti *et al.* 2009, de Mello Junior *et al.* 2009, Fruchi *et al.* 2014, Rödig *et al.* 2014). NiTi alloys are made using different thermal treatments to increase flexibility (Shen *et al.* 2013). The thermomechanical treatment of NiTi files provides significant benefits with regard to the efficacy and safety of endodontic instruments (Shen *et al.* 2013). “M-wire” instruments are mainly in the R-phase, and “CM-wire,” mainly in the martensitic phase. These phases are modified by heating or cooling. The properties of CM-wire impart a high elastic memory to the material, thus increasing instrument flexibility and resistance to fatigue, and also preventing procedural errors during instrumentation (Goo *et al.* 2017). However, to our knowledge, the effectiveness of the CM-wire HyFlex file, when used as an additional instrument for the removal of filling material in curved root canals of molars, has not been previously investigated.

Complete (or at least highly effective) removal of filling material during endodontic retreatment must be achieved to promote the best possible level of disinfection (Cavenago *et al.* 2014), for a successful treatment outcome. The more recent use of regenerative endodontic therapy for endodontic treatment also relies on the effective removal of filling material (Saoud *et al.* 2015). Several techniques have

been used for this purpose, including hand files, burs, and rotary instruments (Betti *et al.* 2009, de Mello Junior *et al.* 2009, Fruchi *et al.* 2014, Rödig *et al.* 2014). The removal of filling material can be performed with supplementary procedural steps, such as passive ultrasonic irrigation (PUI) (Cavenago *et al*. 2014) or irrigant agitation by mechanized rotary devices (Rodrigues CT *et al.* 2017). EasyClean (Easy Equipamentos Odontológicos, Belo Horizonte, Brazil) is a plastic irrigant-agitation instrument designed for use in reciprocating motion and in curved canals. It has been shown to provide better smear layer removal than PUI in curved mesial root canals (Kato *et al.* 2016, Duque *et al.* 2017), and has also been studied in curved roots of maxillary lateral incisors using continuous rotation after applying a solvent (Rodrigues *et al.* 2017). Nevertheless, its effectiveness in retreatment procedures in curved roots of molars using reciprocating motion and without a solvent has yet to be evaluated.

Some studies have shown that instrument hybridization is more effective for filling removal (Rodrigues *et al.* 2016, Yürüker *et al.* 2016). Others have demonstrated that rotary and reciprocating NiTi instruments are safe and efficient in root canal retreatment procedures (Zuolo *et al.* 2013, Fruchi *et al.* 2014, Rios *et al.* 2014, Rödig *et al.* 2014, Rodrigues *et al.* 2016).

Effective filling removal is necessary to provide the conditions for the direct and enhanced action of irrigant solutions and of chemical substances used as dressing materials, in order to reduce bacterial levels and promote biofilm dissolution inside root canals, dentinal tubules and poorly accessible anatomic areas, such as isthmuses. Furthermore, optimal re-obturation of the root canal system also depends on an effective removal of filling material.

To date, there is no consensus in the literature as to what protocol could be considered optimal for root canal retreatment. Therefore, the aim of the present study

was to evaluate the filling removal effectiveness of two different protocols hybridizing instrumentation techniques, i.e. using different motions and instruments made with alloys submitted to different heat treatments, followed by different supplementary irrigant-agitation procedures. Additionally, a comparison was made between the volumes of the debris extruded after reciprocating instrumentation and the volumes of the new fillings obtained after performing the retreatment procedures, according to the two different protocols tested. The null hypotheses were that there would be no differences between the tested instrumentation + irrigation protocols in terms of their efficacy in removing root canal filling material during endodontic retreatment, and in terms of the volume of the new filling obtained after re-obturation.

MATERIAL AND METHODS

The present study was conducted with the approval of the Research Ethics Committee of the Bauru School of Dentistry, University of São Paulo (CAAE: 44736215.9.0000.5417). Forty human mandibular molars with curved mesial canals were used in the study, donated by the Human Tooth Bank of the University of São Paulo, São Paulo, SP, Brazil. The teeth were radiographed digitally in the buccolingual and mesiodistal directions, with a digital X-ray system (Schick CDR; Schick Technologies, Long Island, NY), using an exposure time of 0.16 s. This was done in order to select the teeth and then compose two groups with similar characteristics to ensure their anatomic homogeneity.

The tooth crowns were flattened with a diamond disc (FKG Dentaire, La Chaux-de-Fonds, Switzerland) to obtain a standardized specimen length of 16 mm. The working length (WL) was established by inserting a #10 K-file into each root canal until its tip was visible at the root apex, using an operatory microscope (Alliance, São Paulo,

SP, Brazil) under 8X magnification. The patency of the canals was confirmed using a #10 K-file (Dentsply Maillefer, Ballaigues, Switzerland).

Endodontic treatment

PathFile instruments #13, #16, and #19 (Dentsply Maillefer) were used to make the glide paths with a VDW electric motor (VDW, Munich, Germany), operating at a speed of 300 rpm and torque of 60 g.cm. Afterwards, the teeth were instrumented with R25 Reciproc files (VDW) up to the WL, established at 1 mm short of the total canal length. The Reciproc instrument was used with the corresponding VDW electric motor as per the Reciproc program, with three in-and-out pecking motions applied with light apical pressure. During glide path creation and root canal instrumentation, 2.5% sodium hypochlorite (NaOCl) was used as an irrigant. Final irrigation was performed with 1 mL of 17% ethylenediaminetetraacetic acid (EDTA) for 1 minute, followed by a final rinse with 2 mL of 2.5% NaOCl dispensed with a 30-gauge needle (Navitips; Ultradent Products, South Jourdan, UT, USA). The canals were then dried with R25 paper points and obturated with R25 cones (VDW) and AH Plus sealer (Dentsply Maillefer), according to the single-cone technique. The teeth were again radiographed digitally, as described above, in order to evaluate canal filling quality. The crowns were temporarily sealed with a provisional sealant (Citodur; Dorident, Wien, Austria) and stored at 37°C under 100% humidity for 3 months.

Initial removal of the filling material

The R25 Reciproc instrument was used to perform an initial removal of the filling material. In Group RHPui, one drop (0.8 ml) of xylene was used in the pulp chamber as a solvent. This solvent was used only in Group RHPui, in the early steps of

instrumentation, and not in the apical third of the root canal. The R25 Reciproc instrument was used following the same protocol as that used in the original endodontic treatment, but a brushing motion was applied after each three in-and-out pecking motions, and just until reaching the WL. In Group RMEasy, 2.5% NaOCl was used during the instrumentation steps and in the final rinse. The effective time period—i.e., the time during which the instrument was effectively applied to the root canal walls—required to remove the filling material was recorded. The filling removal procedure was considered concluded when the canal walls were clean and smooth, and when no material was observed on the instrument flutes, under an operating microscope (Alliance, São Paulo, SP, Brasil).

Collection of extruded debris

The material extruded after reciprocating instrumentation was collected in an Eppendorf tube half-filled with gelatin agar and adapted to the apex of each tooth during instrumentation. The space between the cervical surface of the root and the Eppendorf opening was sealed with a photoactivated resin (Top Dam, FGM Produtos Odontológicos, Joinville, SC, Brazil).

Additional rotary instrumentation step

In Group RHPui, a HyFlex #40/.04 instrument (Coltene-Whaledent, Allstetten, Switzerland) was used as an additional step for filling removal and re-instrumentation. In Group RMEasy, a Mtwo #40/.04 instrument (VDW) was used as an equivalent additional procedure.

Completion of the filling removal procedure was established when an appearance of smooth walls was attained, when no remaining filling material was

observed on the file, and when no gutta-percha was visible on the canal walls, under an operating microscope at 8X magnification (de Mello Junior *et al.* 2009).

Supplementary irrigant-agitation step

In Group RHPui, the supplementary step consisted of performing PUI with 2.5% NaOCl, using an E1 #20/.01 Irrisonic tip (Helse Indústria e Comércio, Santa Rosa de Viterbo, SP, Brazil) mounted on an ultrasonic device (Jet Sonic; Gnatus, São Paulo, SP, Brazil), set to operate at a 20% power level, and applied up to 2 mm short of the working length (Cavenago *et al.* 2014). This procedure was carried out after putting a drop (0.8 ml) of xylene in the pulp chamber and keeping it there for 1 minute, and then drying with paper points. In Group RMEasy, the equivalent supplementary step consisted of agitating the 2.5% NaOCl solution with an EasyClean rotary instrument in reciprocating motion up to the full working length, as described by the manufacturer and assessed in a previous study (Kato *et al.* 2016). This procedure was also carried out after putting a drop (0.8 ml) of xylene in the pulp chamber and keeping it there for 1 minute, and then drying with paper points. In a pilot study, the agitation of xylene proved impractical with EasyClean because of the damage caused by the solvent to this instrument, made of plastic. Therefore, we chose not to use a solvent during the irrigant-agitation procedures.

Re-obturation of the root canals

After re-instrumentation, the teeth were filled again with gutta-percha and a resin-based sealer (AHPlus; Dentsply Maillefer), using warm vertical condensation. A single cone matched to the size and length of the canal WL was vertically compacted with a warm tip device (Touch'N Heat; SybronEndo, West Collins. Orange, CA) up to

a level 5 mm short of the WL. The canal filling was completed using the backfill technique (BeeFill; VDW).

Micro-CT evaluation of the retreatment protocols

After completion of the storage period, the teeth were mounted onto a custom attachment and scanned in a micro-computed tomography apparatus (SkyScan 1174; Bruker-microCT, Kontich, Belgium) using the following parameters: 50 kV, 800 µA, and isotropic voxel size of 39 µm. The other parameters used were a 360° rotation, 0.8° rotation steps and a 0.5 mm aluminum filter. Axial cross sections were obtained with a beam hardening correction of 30% and a ring artefact correction of 4. The images of the specimens were reconstructed with NRecon v. 1.6.3 software (Bruker-microCT), and the volumetric analyses of the 3D models were performed with similar parameters using CTAn v.1.12 software (Bruker-microCT). The models were divided into 3 segments of 3 mm each, which corresponded to the apical, middle and cervical portions of the root specimens. The filling material volume was calculated from the binarized area inside the region of interest, which included both root canals and isthmuses, using the same parameters. This final volume was recorded and converted into a percentage relative to the volume of the initial filling.

Group homogeneity in terms of filling material volume, anatomy, root canal length, curvature angle, and Vertucci classification (types II and IV; Vertucci 1984) were confirmed and showed that the study groups were well balanced. The root canal curvature angle was measured as described by Schneider (Schneider 1971). Only teeth with root curvature angles between 25º and 35º were included. The volume of the initial filling material, of that remaining after removal, of that observed after re-

obturation, and of the extruded debris were all measured with the same parameters and using the same CTAn software.

The micro-CT scans were repeated after each procedural step of the protocols tested in Groups RHPui and RMEasy, using the same parameters, as shown in Figure 1. Micro-CT scans were also made to evaluate the initial and final filling material in the isthmus areas of all the class-II teeth, as defined by the Vertucci classification.

The volumes of the filling material in the isthmus areas were measured with Seg3D 2.2.1 software (National Institutes of Health Center for Integrative Biomedical Computing, University of Utah Scientific Computing and Imaging Institute, Salt Lake City, UT).

Statistical analysis

Statistical analysis was performed using Prism 6.0 software (GraphPad Software Inc, L Jolla, CA, USA). The normality of the data was assessed by the Shapiro-Wilks test, and lack of normality led to performance of the Mann-Whitney test to compare the groups after each step of the retreatment protocols.

The Friedman and Dunn tests were used to compare the reductions in filling material volume obtained after performing each mechanical step of root canal instrumentation, namely after using the Reciproc R25, HyFlex CM #40, and Mtwo #40 instruments. The Wilcoxon test was used to compare the reductions in filling material volume obtained after each supplementary irrigant-agitation step, namely after using PUI and the EasyClean instrument, and to compare the filling material volumes before and after re-obturation. The significance level adopted was 5%.

RESULTS

Filling removal

The filling material was not completely removed from inside the root canals in either group, or at any of the levels of the root canal length. The remaining volumes of filling material in the two groups were not significantly different (Table 1; $P > 0.05$).

In the intragroup evaluation, significant differences ($P < 0.05$) were observed between each procedural step in terms of remaining filling material, except for the middle third after HyFlex, the cervical third after Mtwo, and the middle third after EasyClean (Table 1).

Filling material volume after re-obturation

The volume of filling material observed after re-obturation was significantly higher than that of the original obturation, at all the root levels evaluated ($P < 0.05$; Table 2).

The evaluation of the isthmus areas also revealed significant increases in filling material volume after retreatment, pointing out that this increase was greater in Group RMEasy ($P < 0.05$; Table 2).

Extruded debris and effective time of instrumentation

No significant differences were observed between groups regarding the median amounts of debris extruded after reciprocating instrumentation ($P > 0.05$). Likewise, there were no significant differences between groups regarding the median effective time period required to remove the filling material from both mesial canals of each mesial root ($P > 0.05$; Table 3).

DISCUSSION

The null hypotheses were accepted since there were no differences between groups regarding the efficacy of filling material removal or the volume of the new filling after re-obturation.

The Reciproc instruments in the two protocols evaluated were unable to completely remove the filling material from the root canals, and the filling removal was least effective at the apical level, which is in agreement with the results of previous studies (Reddy *et al.* 2013, Crozeta *et al.* 2016). The main objective of this study was to evaluate the efficacy of both additional retreatment steps involving the use of HyFlex and Mtwo instruments, and supplementary retreatment steps involving the use of PUI and EasyClean to perform agitation of the irrigant solution.

The tip and taper of the former two rotary instruments (#40/.04) were chosen to improve the cleaning of the apical third. This is based on micro-CT study findings of a high incidence of ramifications in this portion of the root canal system, as well as the presence of isthmuses with an apical diameter measuring approximately 0.350 mm (Villas-Bôas *et al.* 2011, Keleş & Keskin 2017). Accordingly, the Reciproc R25 instrument with a .25 tip is probably ineffective in cleaning this area.

The *in vivo* incidence of teeth classified as type II in the Vertucci classification—two canals that merge into a single apical canal—is relatively high, and can be found in 54% of cases (Keleş & Keskin 2017, Gambarini *et al.* 2018). The apical area of these joining canals usually has an oval shape that renders filling removal difficult (Figure 2). In this study, a 52.5% frequency of the Vertucci type-II configuration was found in the randomly selected teeth, which were evenly distributed between the study groups.

This study also conducted a micro-CT assessment of the amount of extruded debris. Previous studies (Bürklein *et al.* 2014, Dincer *et al.* 2015, Çanakçi *et al.* 2016)

have assessed extruded debris with electronic balances in pre-weighed vials. To the best of our knowledge, there are no studies on the evaluation of extruded debris using Micro-CT; moreover this method has proven a viable option to evaluate the extrusion of material during endodontic retreatment.

The use of a solvent appeared to have no influence on debris extrusion since no differences were observed between the study groups with or without this additional step. It is not possible to compare these results with those of previous studies, owing to the difference in evaluation methods, i.e. our results were expressed in mm^3, whereas those of previous studies, in mg or µg (Çanakçi *et al.* 2016, Delvarani *et al.* 2017).

In one study, the HyFlex CM instrument proved more effective at cutting in a lateral action, compared with M-wire instruments (Morgental *et al.* 2013). In our study, there were no significant differences between HyFlex and Mtwo instruments regarding filling removal. The intra-group analyses showed that there was an increase in the volume of filling material removed from the apical third after the use of rotary instruments, namely 18% and 19% for RHPui and RMEasy, respectively. In the middle third, this increase was 6% and 8% after HyFlex and Mtwo, respectively, and, in the cervical third, it was 3% for both groups. The taper difference between Reciproc, HyFlex and Mtwo is probably the main reason for these results. The diameter of the R25 instrument at 3 mm from its tip is 0.49 mm, whereas the diameter of the HyFlex and Mtwo instruments at that same level is 0.52 mm. Therefore, the additional use of instruments with a tip greater than that of the last instrument used in the initial removal of filling material, but with a smaller taper, was effective in the apical region, but with little or no effect in the middle and cervical regions. Some filling removal was observed for HyFlex and Mtwo in the middle and cervical thirds, but this can be attributed to the

brushing movement used with these instruments.

The areas left untouched by reciprocating and rotary instruments can range from 10% to 50% of the root canal walls (Paqué *et al.* 2011, Siqueira *et al.* 2018). This could explain why the EasyClean instrument, which also uses reciprocating motion, was significantly less effective in the middle third of the root canal. Furthermore, although the EasyClean instrument has an equivalent 0.25 tip, its taper is 0.04, therefore smaller than that of Reciproc (0.08); this could have led to the instrument leaving untouched areas in the root canal walls.

The use of PUI and the EasyClean reciprocating instrument for irrigant agitation produced similar filling removal results. Both enhanced the total filling removal effectiveness in the intragroup analysis. PUI performed with the Irrisonic tip promoted significant filling removal at all root levels, with better results in the apical third, whereas the reciprocating agitation with EasyClean produced significant removal in the apical and cervical thirds, but not in the middle third, after using the Mtwo instrument.

The filling removal effectiveness of PUI in curved root canals is controversial (Cavenago *et al.* 2014, Fruchi *et al.* 2014, Barreto *et al.* 2016, Rodrigues CT *et al*. 2017). In a previous study conducted with mesiobuccal root canals, the use of xylene combined with PUI increased the removal of filling material, but this increase was not statistically significant (Fruchi *et al.* 2014). In the present study, ultrasonic agitation produced significant removal ($p < 0.05$) after use of the HyFlex instrument. The enlargement of the apical area performed with a #40/.04 instrument could have been responsible for the efficacy of the ultrasound in this area, since this result was not found in a previous study conducted with a #25/.08 instrument (Fruchi *et al.* 2014). This was confirmed by another clinical study that showed that larger preparations in the apical third improved the disinfection achieved with irrigant solutions (Rodrigues *et al.* 2017).

Another factor that could have been responsible for this difference was that both canals of the mesial root canal system and the isthmus area were evaluated in the present study. The cleaning of the isthmus is an important supplementary step. One study showed that the presence of an isthmus in the mesial root of mandibular molars is a very frequent occurrence (64%), and the frequencies of its location are 30.3% in the cervical third, 14.8% in the middle third, and 44.3% in the apical third (Tahmasbi *et al.* 2017).

Irrigant agitation with EasyClean was effective in the cervical and apical thirds; however, the best cleaning results were observed for PUI in the apical area. This could be due to the greater effectiveness of the tip of the ultrasound instrument and to its pre-shaping (Ahmad *et al.* 1992).

A statistically significant increase ($P < 0.05$) in filling material volume in the isthmus area was observed for both groups after reobturation, considering that better results were obtained for Group RMEasy, where no xylene was used. This could have occurred because a solvent causes the softened gutta-percha and sealer to form a thin layer of material that can be difficult to remove, thus keeping the isthmus area from being adequately cleansed and from properly receiving the new filling material. Furthermore, the warm vertical condensation technique could also have provided a better distribution of the filling material in the isthmus area during re-obturation, as compared with the single-cone technique of the original obturation.

No statistically significant differences were found between groups regarding the effective time required to reach the WL, demonstrating that the use of a solvent had no positive effect on this variable.

CONCLUSION

None of the protocols completely removed the filling material from the curved root canals used in this study. The use of additional rotary instrumentation and supplementary irrigant agitation steps after initial filling removal with reciprocating instrumentation proved effective in promoting better cleaning and improved filling removal. The best results were found for the apical level and after PUI. The two protocols evaluated, followed by the vertical warm condensation filling technique, enhanced the volume of filling material in the root canal system, including the isthmus.

ACKNOWLEDGMENTS

This study was supported by the State of São Paulo Research Foundation (FAPESP, grant no. 2015/03829-1). The authors deny any conflicts of interest related to this study.

REFERENCES

Ahmad M, Roy RA, Kamarudin AG (1992) Observations of acoustic streaming fields around an oscillating ultrasonic file. *Endodontics & Dental Traumatology* **8,** 189-94.

Barreto MS, Rosa RA, Santini MF *et al.* (2016) Efficacy of ultrasonic activation of NaOCl and orange oil in removing filling material from mesial canals of mandibular molars with and without isthmus. *Journal of Applied Oral Science* **24,** 37-44.

Betti LV, Bramante CM, de Moraes IG, Bernardineli N, Garcia RB (2009) Efficacy of Profile .04 taper series 29 in removing filling materials during root canal retreatment--an in vitro study. *Oral Surgery, Oral Medicine, Oral Pathology, Oral Radiology, and Endodontics* **108,** e46-50.

Bürklein S, Benten S, Schäfer E (2014) Quantitative evaluation of apically extruded debris with different single-file systems: Reciproc, F360 and OneShape versus Mtwo. *International Endodontic Journal* **47,** 405-9.

Cavenago BC, Ordinola-Zapata R, Duarte MA *et al.* (2014) Efficacy of xylene and passive ultrasonic irrigation on remaining root filling material during retreatment of anatomically complex teeth. *International Endodontic Journal* **47**, 1078-83.

Crozeta BM, Silva-Sousa YT, Leoni GB *et al.* (2016) Micro-computed tomography study of filling material removal from oval-shaped canals by using rotary, reciprocating, and adaptive motion systems. *Journal of Endodontics* **42,** 793-7.

de Mello Junior JE, Cunha RS, Bueno CE, Zuolo ML (2009) Retreatment efficacy of gutta-percha removal using a clinical microscope and ultrasonic instruments: part I--an ex vivo study. *Oral Surgery, Oral Medicine, Oral Pathology, Oral Radiology, and Endodontics* **108,** e59-62.

Delvarani A, Mohammadzadeh Akhlaghi N, Aminirad R, Tour Savadkouhi S, Vahdati SA (2017) Comparison of apical debris extrusion using rotary and reciprocating systems in severely curved root canals. *Iranian Endodontic Journal* **12,** 34-7.

Dincer AN, Er O, Canakci BC (2015) Evaluation of apically extruded debris during root canal retreatment with several NiTi systems. *International Endodontic Journal* **48,** 1194-8.

Duque JA, Duarte MA, Canali LC *et al.* (2017) Comparative effectiveness of new mechanical irrigant agitating devices for debris removal from the canal and isthmus of mesial roots of mandibular molars. *Journal of Endodontics* **43,** 326-31.

Fruchi L de C, Ordinola-Zapata R, Cavenago BC, Hungaro Duarte MA, Bueno CE, De Martin AS (2014) Efficacy of reciprocating instruments for removing filling material in curved canals obturated with a single-cone technique: a micro–computed tomographic analysis. *Journal of Endodontics* **40**, 1000-4.

Gambarini G, Ropini P, Piasecki L *et al.* (2018) A preliminary assessment of a new dedicated endodontic software for use with CBCT images to evaluate the canal complexity of mandibular molars. *International Endodontic Journal* **51**, 259-68.

Goo HJ, Kwak SW, Ha JH, Pedullà E, Kim HC (2017) Mechanical properties of various heat-treated nickel-titanium rotary instruments. *Journal of Endodontics* **43**, 1872-7.

Kato AS, Cunha RS, da Silveira Bueno CE, Pelegrine RA, Fontana CE, de Martin AS (2016) Investigation of the efficacy of passive ultrasonic irrigation versus irrigation with reciprocating activation: an environmental scanning electron microscopic study. *Journal of Endodontics* **42,** 659-63.

Keleş A, Keskin C (2017) Apical root canal morphology of mesial roots of mandibular first molar teeth with Vertucci type II configuration by means of micro-computed tomography. *Journal of Endodontics* **43,** 481-5.

Morgental RD, Vier-Pelisser FV, Kopper PM, de Figueiredo JA, Peters OA (2013) Cutting efficiency of conventional and martensitic nickel-titanium instruments for coronal flaring. *Journal of Endodontics* **39,** 1634-8.

Ng YL, Mann V, Gulabivala K (2008) Outcome of secondary root canal treatment: a systematic review of the literature. *International Endodontic Journal* **41,** 1026-46.

Paqué F, Zehnder M, De-Deus G (2011) Microtomography-based comparison of reciprocating single-file F2 ProTaper technique versus rotary full sequence. *Journal of Endodontics* **37,** 1394-7.

Reddy N, Admala SR, Dinapadu S, Pasari S, Reddy MP, Rao MS (2013) Comparative analysis of efficacy and cleaning ability of hand and rotary devices for gutta-percha removal in root canal retreatment: an in vitro study. *The Journal of Contemporary Dental Practice* **14,** 635-43.

Rios MeA, Villela AM, Cunha RS *et al.* (2014) Efficacy of 2 reciprocating systems compared with a rotary retreatment system for gutta-percha removal. *Journal of Endodontics* **40,** 543-6.

Rodrigues CT, Duarte MA, de Almeida MM, de Andrade FB, Bernardineli N (2016) Efficacy of CM-Wire, M-Wire, and nickel-titanium instruments for removing filling material from curved root canals: a micro-computed tomography study. *Journal of Endodontics* **42,** 1651-5.

Rodrigues CT, Duarte MAH, Guimarães BM, Vivan RR, Bernardineli N (2017) Comparison of two methods of irrigant agitation in the removal of residual filling material in retreatment. *Brazilian Oral Research* **31,** e113.

Rodrigues RCV, Zandi H, Kristoffersen AK *et al.* (2017) Influence of the apical preparation size and the irrigant type on bacterial reduction in root canal-treated teeth with apical periodontitis. *Journal of Endodontics* **43,** 1058-63.

Rödig T, Reicherts P, Konietschke F, Dullin C, Hahn W, Hülsmann M (2014) Efficacy of reciprocating and rotary NiTi instruments for retreatment of curved root canals assessed by micro-CT. *International Endodontic Journal* **47**, 942-8.

Saoud TM, Huang GT, Gibbs JL, Sigurdsson A, Lin LM (2015) Management of teeth with persistent apical periodontitis after root canal treatment using regenerative endodontic therapy. *Journal of Endodontics* **41,** 1743-8.

Schneider SW (1971) A comparison of canal preparations in straight and curved root canals. *Oral Surgery, Oral Medicine, and Oral Pathology* **32,** 271-5.

Shen Y, Zhou HM, Zheng YF, Peng B, Haapasalo M (2013) Current challenges and concepts of the thermomechanical treatment of nickel-titanium instruments. *Journal of Endodontics* **39,** 163-72.

Siqueira JF Jr, Pérez AR, Marceliano-Alves MF *et al.* (2018) What happens to unprepared root canal walls: a correlative analysis using micro-computed tomography and histology/scanning electron microscopy. *International Endodontic Journal* **51**, 501-8.

Siqueira JF, Rôças IN (2008) Clinical implications and microbiology of bacterial persistence after treatment procedures. *Journal of Endodontics* **34,** 1291-301.e1293.

Tahmasbi M, Jalali P, Nair MK, Barghan S, Nair UP (2017) Prevalence of middle mesial canals and isthmi in the mesial root of mandibular molars: an in vivo cone-beam computed tomographic study. *Journal of Endodontics* **43,** 1080-3.

Torabinejad M, Corr R, Handysides R, Shabahang S (2009) Outcomes of nonsurgical retreatment and endodontic surgery: a systematic review. *Journal of Endodontics* **35,** 930-7.

Villas-Bôas MH, Bernardineli N, Cavenago BC *et al.* (2011) Micro-computed tomography study of the internal anatomy of mesial root canals of mandibular molars. *Journal of Endodontics* **37,** 1682-6.

Yürüker S, Görduysus M, Küçükkaya S *et al.* (2016) Efficacy of combined use of different nickel-titanium files on removing root canal filling materials. *Journal of Endodontics* **42,** 487-92.

Zuolo AS, Mello JE, Cunha RS, Zuolo ML, Bueno CE (2013) Efficacy of reciprocating and rotary techniques for removing filling material during root canal retreatment. *International Endodontic Journal* **46**, 947-53.

Çanakçi BC, Ustun Y, Er O, Genc Sen O (2016) Evaluation of apically extruded debris from curved root canal filling removal using 5 nickel-titanium systems. *Journal of Endodontics* **42,** 1101-4.

Vertucci FJ (1984) Root canal anatomy of the human permanent teeth. *Oral Surgery, Oral Medicine, and Oral Pathology* **58**, 589–99.

Table 1. Median, minimum and maximum values of initial and remaining filling material volume (mm^3), and percentage (%) of the initial filling material removed after each procedural step, for the different root canal levels and for the total root canal length.

GROUP RHPui (Reciproc + HyFlex)				**GROUP RMEasy (Reciproc + Mtwo)**			
Initial filling material				Initial filling material			
Apical	Middle	Cervical	Total	Apical	Middle	Cervical	Total
1.465^{aA}	2.446^{aA}	3.970^{aA}	7.830^{aA}	1.477^{aA}	2.292^{aA}	3.830^{aA}	7.934^{aA}
(0.590–2.781)	(1.702–4.609)	(3.028–8.745)	(5.860–16.135)	(0.720–3.077)	(1.768–5.248)	(2.792–5.917)	(5.673–13.411)
After Reciproc				After Reciproc			
0.336^{aB}	0.513^{aB}	0.892^{aB}	1.779^{aB}	0.411^{aB}	0.5641^{aB}	0.6621^{aB}	1.645^{aB}
(0.055–1.821)	(0.067–3.515)	(0.215–5.094)	(0.615–10.430)	(0.016–1.523)	(0.0201–3.139)	(0.006–3.438)	(0.496–7.499)
–67%	–77%	–77%	–78%	–62%	–73%	–82%	–77%
(35%–97%)	(24%–96%)	42%–94%)	(35%–92%)	(29%–99%)	(29%–99%)	(32%–100%)	(41%–91%)
After HyFlex				After Mtwo			
0.186^{aC}	0.300^{aB}	0.846^{aC}	1.129^{aC}	0.2334^{aC}	0.4378^{aC}	0.5417^{aB}	1.229^{aC}
(0.019–1.254)	(0.049–3.005)	(0.099–3.209)	(0.263–7.468)	(0.00041–0.8728)	(0.0000–2.1930)	(0.00328-3.356)	(0.2364–6.161)
–85%	–83%	–80%	–83%	–81%	–81%	–85%	–84%
(55%–98%)	(35%–98%)	(55%–97%)	(54%–96%)	(64%–100%)	(40%–100%)	(34%–100%)	(54%–96%)
After PUI				After EasyClean			
0.137^{aD}	0.230^{aD}	0.651^{aD}	1.089^{aD}	0.2007^{aD}	0.4179^{aC}	0.4504^{aD}	1.134^{aD}
(0.009–1.177)	(0.053–2.687)	(0.010–3.191)	(0.229–7.054)	(0.00056-0.7571)	(0.0000–2.283)	(0.06333–2.222)	(0.2085–4.994)
–91%	–88%	–83%	–83%	–84%	–83%	–87%	–85%
(58%–99%)	(42%–98%)	(56%–100%)	(56%–96%)	(47%–100%)	(41%–100%)	(56%–99%)	(61%–96%)

Different superscript lowercase letters in each row indicate significant differences between groups ($P < .05$). Different superscript uppercase letters in each column indicate significant differences within the same group after each procedural step ($P < 0.05$).

Table 2. Median, minimum and maximum values of initial filling material volume (mm^3), final filling material volume, and percent increase (%) in filling material volume after re-obturation, for the different root canal levels, for the total root canal length, and for the isthmuses.

GROUP RHPui (Reciproc + HyFlex + PUI)					**GROUP RMEasy (Reciproc + Mtwo + EasyClean)**				
Initial filling material					Initial filling material				
Apical	Middle	Cervical	Total	Isthmus	Apical	Middle	Cervical	Total	Isthmus
1.312^{aA} (0.590–2.781)	2.351^{aA} (1.702–4.609)	3.968^{aA} (3.028–8.258)	7.688^{aA} (5.860–15.648)	0.099^{aA} (0.00012–0.71406)	1.421^{aA} (0.720–2.4789)	2.068^{aA} (1.768–3.930)	3.788^{aA} (2.792–5.809)	7.086^{aA} (5.673–10.743)	0.264^{bA} (0.02611–1.46624)
Final filling material					Final filling material				
Apical	Middle	Cervical	Total	Isthmus	Apical	Middle	Cervical	Total	Isthmus
1.877^{aB} (1.293–3.048)	3.151^{aB} (2.657–5.578)	4.552^{aB} (3.493–8.596)	9.875^{aB} (7.903–17.222)	0.196^{aB} (0.0000–1.02533)	1.930^{aB} (1.083–3.571)	3.675^{aB} (2.545–4.633)	4.581^{aB} (3.880–9.101)	10.646^{aB} (7.881–16.442)	0.562^{bB} (0.0769–2.24183)
43% (10%–177%)	34% (6%–85%)	15% (1%–30%)	28% (8%–52%)	45% (0%–282%)	36% (8%–161%)	78% (18%–95%)	21% (5%–65%)	50% (23%–69%)	86% (17%–195%)

Different superscript lowercase letters in each row indicate significant differences between groups ($P < 0.05$). Different superscript uppercase letters in each column indicate significant differences within the same group ($P < 0.05$).

Table 3 - Median, minimum and maximum values of the effective time required (s) for the removal of the filling material and the volume (mm^3) of extruded debris.

	Group RHPui	Group RMEasy
Effective time (s)	209.40[a] (140.4 – 364.8)	227.40[a] (188.40 – 381)
Extruded debris volume (mm^3)	0.0258[a] (0 – 0.954)	0.0037[a] (0 – 0.565)

The same superscript letters in each row indicate no statistically significant differences ($P > 0.05$).

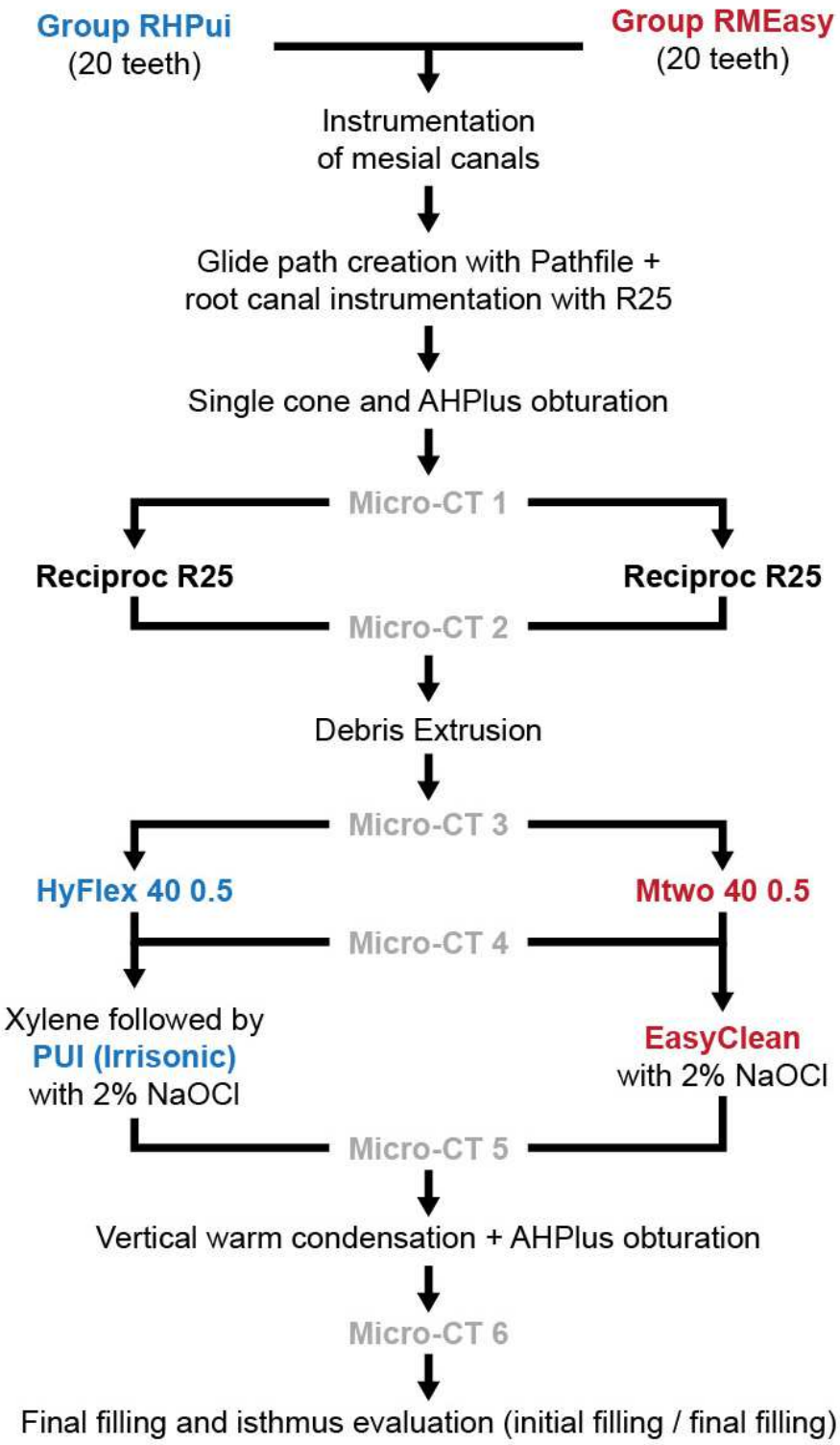

Figure 1. Summary of the experimental design.

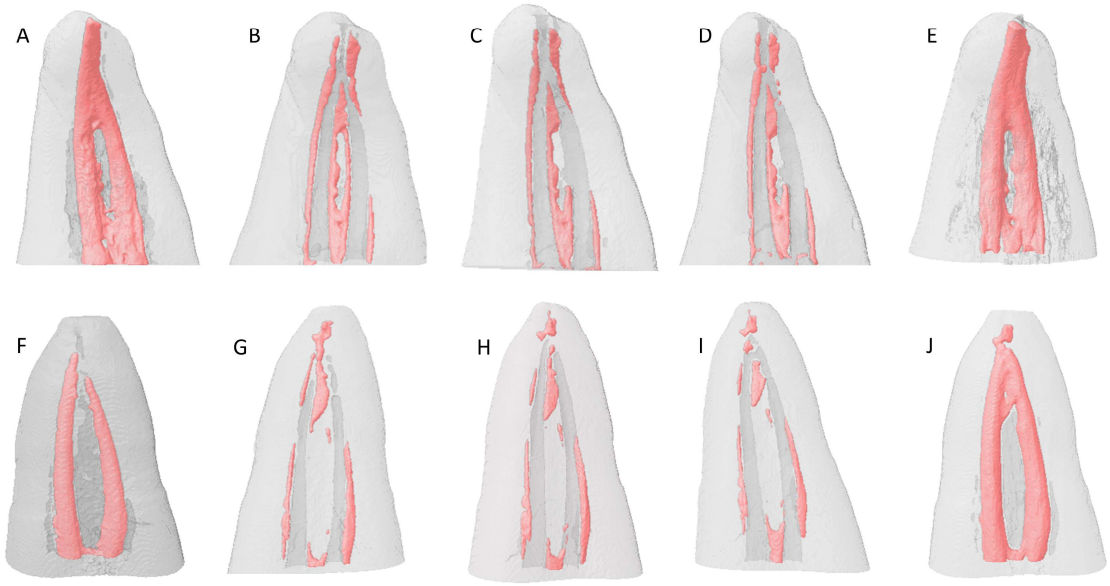

Figure 2. Micro-CT reconstructions of two representative specimens before and after each procedural step of endodontic retreatment. A and F: Initial filling, B and G: after Reciproc, C: after HyFlex, H: after Mtwo, D: after PUI, I: after EasyClean, E and J: new filling after reobturation.

3 DISCUSSION

3 DISCUSSION

Achieving root canal patency prior to the use of rotary or reciprocating instruments through the creation of a glide path has been evaluated in several studies (BERUTTI et al., 2009; BERUTTI et al., 2012; PASQUALINI et al., 2012a; PASQUALINI et al., 2012b; DE-DEUS et al., 2013). In the first part of this study, we showed that the endodontic obturation was closer to the apical foramen when the PathFile instruments were used to create a glide path throughout the canal, prior to the use of the Reciproc R25 reciprocating instrument, contrasting with the situation in which they were applied up to 1 mm short of the apical foramen.

It was also observed that the volume of filling material was greater in the group where the glide path was created throughout the entire canal length than when it was performed up to 1 mm short of its total length, and that this increase was substantial, although not statistically significant (P = 0.059).

Previous studies have shown that endodontic obturation should extend up to a region involving the 2 mm closest to the radiographic apex (RICUCCI, 1998; WU et al., 2000; VASCONCELOS et al., 2015). This would ensure canal patency throughout its length, which would avoid the taper-lock effect and allow the instruments and irrigation substances to reach the apical region (BERUTTI et al., 2009; BERUTTI et al., 2012).

The use of manual instruments for glide path creation is problematic and poses greater risks than the use of NiTi rotary instruments (BERUTTI et al., 2009; BERUTTI et al., 2012; PASQUALINI et al., 2012). Studies on glide path creation have been carried out in order to evaluate the reduction in fatigue stress and in the occurrence of deviations or changes in root canal anatomy by rotary and reciprocating instruments, enabling them to reach the apical region more safely and effectively (BERUTTI et al., 2012; NAZARIMOGHADAM et al., 2014).

The results presented in the second part of this study on the effectiveness of reciprocating instruments in reducing the amount of filling material are in agreement with the results of previous studies, showing that these instruments, although efficient, are incapable of completely removing the filling material from inside the canals,

especially in the apical third (CROZETA et al., 2016; REDDY et al., 2011; CAVENAGO et al., 2014; RÖDIG et al., 2014).

A more marked enlargement of the apical region would allow an improved removal of filling material and dentin contaminated with necrotic remnants and bacteria. These microorganisms are resistant to retreatment, especially owing to the predominance of Enterococcus faecalis (SUNDQVIST et al., 1998; RÔÇAS et al., 2004a; RÔÇAS, 2004b; GOMES et al., 2008; SCHIRRMEISTER et al., 2009), although some studies have disputed the prevalence of this bacterium in this type of infection (ZEHNDER; GUGGENHEIM, 2009; ZEHNDER; BELIBASAKIS, 2015; ALVES et al., 2016; CANCIO et al., 2017).

The action of irrigating substances is improved with the enlargement of the apical region, as demonstrated in our study, confirming the results of previous studies (CROZETA et al., 2016; RODRIGUES et al., 2016; RODRIGUES et al., 2017). The importance of this enlargement is even greater in oval-shaped canals, where cleaning and removal of filling material are more difficult (PAQUÉ et al., 2010). In our study, the same Reciproc R25 instrument used in the endodontic treatment was used for the initial removal of filling material. It seemed logical to assume that further enlargement of the canal, as long as the original anatomy was preserved, would be especially necessary in the region of confluence of the mesial canals of the mesial root of mandibular molars. For this purpose, NiTi instruments with a #40 tip (0.040 mm) and 0.04 mm taper increase for every mm were chosen, as opposed to the design of Reciproc instruments, namely a #25 tip (0.25 mm) and 0,08 mm taper increase for every mm. Thus, the apical region, being the most critical during both treatment and re-treatment procedures, would be subject to a more significant enlargement, which would contribute to a greater disinfection of this region. This disinfection would be the result of both greater removal of contaminated material and more effective irrigation action, irrespective of the solution used for this purpose (RODRIGUES et al., 2017). In the present study, a more effective action of the irrigating substances in the apical region was observed with both irrigant-agitation methods – PUI with Irrisonic or EasyClean – with a slight advantage for the former.

The oval-shaped anatomy type is prevalent in the mesial root canals of molars that join together in their apical third (Vertucci class II). The frequency of this type of

anatomy reaches 54% of cases in some studies (VILLAS-BÔAS et al., 2011; KELEŞ; KESKIN, 2017). In the present study, we observed a prevalence of 52.5% of this anatomical type in the 40 mesial molar roots evaluated.

In addition to choosing to use rotary instruments as an additional step after reciprocating instrumentation, we also evaluated two types of NiTi alloys with different surface and thermal treatments, namely the Conventional NiTi alloy of the Mtwo instrument and an alloy known as "controlled memory" (CM) of the HyFlex instrument, whose alleged greater flexibility and fatigue resistance properties (SHEN et al., 2013) could have an influence on their ability to remove filling material. Although a previous work has shown a greater cutting ability in lateral action for the HyFlex CM instrument over M-Wire alloy instruments (MORGENTAL et al., 2013), we did not observe significant differences between these two types of instrument in terms of their ability to remove filling material, probably owing to the observation of equivalent percentages of areas left untouched by the two instruments during the filling removal. In some studies, this percentage may reach 50%, especially in the apical area (PAQUÉ et al., 2011; SIQUEIRA et al., 2018). A previous study demonstrated that the HyFlex CM instrument is more capable of preserving the original root canal shape than the WaveOne and Reciproc reciprocating instruments owing to its greater flexibility (MARCELIANO-ALVES et al., 2015). The preservation of the original canal anatomy associated with the same filling removal effectiveness provided by the HyFlex CM instrument could lead to a lower rate of accidents during instrumentation.

The two rotary instruments, HyFlex and Mtwo, proved more effective in the apical region, with filling removal effectiveness increases of 18% and 19%, respectively, over the Reciproc R25 instrument. These increases were of 6% and 8%, respectively, in the middle third, and of 3%, for both groups, in the cervical third. This result was probably observed owing to tip and taper differences between the Reciproc R25 instrument (0.25 mm tip and 0.08 mm taper) and the HyFlex and Mtwo instruments (0.40 mm tip and 0.04 mm taper). The diameter of the R25 instrument at 3 mm from its tip is 0.49 mm, whereas the diameter of the HyFlex and Mtwo instruments at that same level is 0.52 mm. Therefore, the additional use of instruments with a tip greater than that of the last instrument used in the initial removal of filling material, but with a smaller taper, was effective in the apical region, but with little or no effect in the middle and cervical regions. The removal of filling material that occurred in these latter areas,

although small, can probably be accounted for by the brushing motion applied to these instruments.

The use of xylene as a solvent during filling material removal with the R25 reciprocating instrument failed to reduce the amount of time expended during this procedure and to increase the extrusion of debris in both groups. Nonetheless, the increase in filling material volume observed in the isthmus region after re-obturation in the group where the solvent was not used was significantly higher than in the group where it was. This result may have occurred owing to the dissolution of the gutta-percha promoted by the solvent and the resulting formation of a thin and difficult-to-remove layer of this material, thus reducing the permeability of the poorly accessible isthmus region and dentinal tubules (WILCOX; JUHLIN, 1994). Use of the warm vertical condensation technique in the re-obturation procedure (as opposed to the single-cone technique used in the original filling), of the additional rotary instrumentation step, and of the supplementary irrigant agitation step may also have contributed to the significant increase in filling material observed in the root canal system and isthmus of the mandibular molar roots after re-obturation.

4 CONCLUSIONS

4 CONCLUSIONS

- The creation of a glide path with the PathFile instruments up to the full extent of the root canals prior to the use of the Reciproc R25 instrument brought the filling material closer to the apical foramen.
- The two endodontic re-treatment protocols evaluated were not significantly different, and both were efficient in removing the filling material.
- The best results were obtained in the apical region in the RHPui group (Reciproc, HyFlex, PUI).
- Both protocols increased the volume of the filling material after re-obturation, including in the isthmus area.

REFERENCES

REFERENCES

Alovisi M, Cemenasco A, Mancini L, Paolino D, Scotti N, Bianchi CC, et al. Micro-CT evaluation of several glide path techniques and ProTaper Next shaping outcomes in maxillary first molar curved canals. Int Endod J. 2017;50(4):387-97.

Alves FR, Andrade-Junior CV, Marceliano-Alves MF, Pérez AR, Rôças IN, Versiani MA, et al. Adjunctive steps for disinfection of the mandibular molar root canal system: a correlative bacteriologic, micro-computed tomography, and cryopulverization approach. J Endod. 2016;42(11):1667-72.

Barletta FB, de Sousa Reis M, Wagner M, Borges JC, Dall'Agnol C. Computed tomography assessment of three techniques for removal of filling material. Aust Endod J. 2008;34(3):101-5.

Barreto MS, Rosa RA, Santini MF, Cavenago BC, Duarte MA, Bier CA, et al. Efficacy of ultrasonic activation of NaOCl and orange oil in removing filling material from mesial canals of mandibular molars with and without isthmus. J Appl Oral Sci. 2016;24(1):37-44.

Bergenholtz G, Lekholm U, Milthon R, Heden G, Odesjö B, Engström B. Retreatment of endodontic fillings. Scand J Dent Res. 1979;87(3):217-24.

Berutti E, Cantatore G, Castellucci A, Chiandussi G, Pera F, Migliaretti G, et al. 2009 Use of nickel-titanium rotary PathFile to create the glide path: comparison with manual preflaring in simulated root canals. J Endod. 2009;35(3):408-12.

Berutti E, Paolino DS, Chiandussi G, Alovisi M, Cantatore G, Castellucci A, et al. Root canal anatomy preservation of WaveOne reciprocating files with or without glide path. J Endod. 2012;38(1):101-4.

Bramante CM, Fidelis NS, Assumpção TS, Bernardineli N, Garcia RB, Bramante AS, et al. Heat release, time required, and cleaning ability of MTwo R and ProTaper universal retreatment systems in the removal of filling material. J Endod. 2010;36(11):1870-3.

Bueno CE, Delboni MG, de Araújo RA, Carrara HJ, Cunha RS. Effectiveness of rotary and hand files in gutta-percha and sealer removal using chloroform or chlorhexidine gel. Braz Dent J. 2006;17(2):139-43.

Bürklein S, Schäfer E. Apically extruded debris with reciprocating single-file and full-sequence rotary instrumentation systems. J Endod. 2012;38(6):850-2.

Cancio V, Carvalho Ferreira D, Cavalcante FS, Rosado AS, Teixeira LM, Braga Oliveira Q, et al. Can the Enterococcus faecalis identified in the root canals of primary teeth be a cause of failure of endodontic treatment? Acta Odontol Scand. 2017;75(6):423-8.

Cavenago BC, Ordinola-Zapata R, Duarte MA, del Carpio-Perochena AE, Villas-Bôas MH, Marciano MA, et al. Efficacy of xylene and passive ultrasonic irrigation on remaining root filling material during retreatment of anatomically complex teeth. Int Endod J. 2014;47(11):1078-83.

Crozeta BM, Silva-Sousa YTC, Leoni GB, Mazzi-Chaves JF, Fantinato T, Baratto-Filho F. et al. micro–computed tomography study of filling material removal from oval-shaped canals by using rotary, reciprocating, and adaptive motion systems. J Endod.2016;42(5):793-7.

De-Deus G, Arruda TE, Souza EM, Neves A, Magalhães K, Thuanne E, et al. The ability of the Reciproc R25 instrument to reach the full root canal working length without a glide path. Int Endod J. 2013;46(10):993-8.

Dincer AN, Er O, Canakci BC. Evaluation of apically extruded debris during root canal retreatment with several NiTi systems. Int Endod J. 2015;48(12):1194-8.

Fruchi LC, Vivan RR, Alcalde MP, Andrade FB, Hungaro Duarte MA. Microtomography evaluation of glide path length influence on volume and apical limit of root canal fillings. Dent press endod. 2017;7(2):15-20.

Fruchi L de C, Ordinola-Zapata R, Cavenago BC, Hungaro Duarte MA, Bueno CE, De Martin AS. Efficacy of reciprocating instruments for removing filling material in curved canals obturated with a single-cone technique: a micro–computed tomographic analysis. J Endod. 2014;40(7):1000-4.

Garip Y, Günday M. The use of computed tomography when comparing nickel-titanium and stainless steel files during preparation of simulated curved canals. Int Endod J. 2001;34(6):452-7.

Gomes BP, Pinheiro ET, Jacinto RC, Zaia AA, Ferraz CC, Souza-Filho FJ. Microbial analysis of canals of root-filled teeth with periapical lesions using polymerase chain reaction. J Endod. 2008;34(5):537-40.

Hammad M, Qualtrough A, Silikas N. Three-dimensional evaluation of effectiveness of hand and rotary instrumentation for retreatment of canals filled with different materials. J Endod. 2008;34(11):1370-3.

Hammad M, Qualtrough A, Silikas N. Evaluation of root canal obturation: a three-dimensional in vitro study. J Endod. 2009;35(4):541-4.

Keleş A, Keskin C. Apical root canal morphology of mesial roots of mandibular first molar teeth with Vertucci Type II configuration by means of micro-computed tomography. J Endod. 2017;43(3):481-5.

Marceliano-Alves MF, Sousa-Neto MD, Fidel SR, Steier L, Robinson JP, Pécora JD, et al. Shaping ability of single-file reciprocating and heat-treated multifile rotary systems: a micro-CT study. Int Endod J. 2015;48(12):1129-36.

Morgental RD, Vier-Pelisser FV, Kopper PM, de Figueiredo JA, Peters OA. Cutting efficiency of conventional and martensitic nickel-titanium instruments for coronal flaring. J Endod. 2013;39(12):1634-8.

Nazarimoghadam K, Daryaeian M, Ramazani N. An in vitro comparison of root canal transportation by reciproc file with and without glide path. J Dent (Tehran). 2014;11(5):554-9.

Paqué F, Balmer M, Attin T, Peters OA. Preparation of oval-shaped root canals in mandibular molars using nickel-titanium rotary instruments: a micro-computed tomography study. J Endod. 2010;36(4):703-7.

Paqué F, Zehnder M, De-Deus G. Microtomography-based comparison of reciprocating single-file F2 ProTaper technique versus rotary full sequence. J Endod. 2011;37(10):1394-7.

Pasqualini D, Bianchi CC, Paolino DS, Mancini L, Cemenasco A, Cantatore G, et al. Computed micro-tomographic evaluation of glide path with nickel-titanium rotary PathFile in maxillary first molars curved canals. J Endod. 2012a;38(3):389-93.

Pasqualini D, Mollo L, Scotti N, Cantatore G, Castellucci A, Migliaretti G, et al. Postoperative pain after manual and mechanical glide path: a randomized clinical trial. J Endod. 2012b;38(1):32-6.

Reddy S, Neelakantan P, Saghiri MA, Lotfi M, Subbarao CV, Garcia-Godoy F et al. Removal of gutta-percha/zinc-oxide-eugenol sealer or gutta-percha/epoxy resin sealer from severely curved canals: an in vitro study. Int J Dent;2011:541831. doi: 10.1155/2011/541831.

Ricucci D. Apical limit of root canal instrumentation and obturation, part 1. Literature review. Int Endod J. 1998;31(6):384-93.

Rios M de A, Villela AM, Cunha RS, Velasco RC, De Martin AS, Kato AS, et al. Efficacy of 2 reciprocating systems compared with a rotary retreatment system for gutta-percha removal. J Endod. 2014;40(4):543-6.

Roane JB, Sabala CL, Duncanson MG. The "balanced force" concept for instrumentation of curved canals. J Endod. 1985;11(5):203-11.

Rodrigues CT, Duarte MA, de Almeida MM, de Andrade FB, Bernardineli N. Efficacy of CM-Wire, M-Wire, and nickel-titanium instruments for removing filling material from curved root canals: a micro-computed tomography study. J Endod. 2016;42(11):1651-5.

Rodrigues CT, Duarte MAH, Guimarães BM, Vivan RR, Bernardineli N. Comparison of two methods of irrigant agitation in the removal of residual filling material in retreatment. Braz Oral Res. 2017;31:e113. doi: 10.1590/1807-3107BOR-2017.vol31.0113.

Rodrigues RCV, Zandi H, Kristoffersen AK, Enersen M, Mdala I, Ørstavik D. et al. Influence of the Apical Preparation Size and the Irrigant Type on Bacterial Reduction in Root Canal-treated Teeth with Apical Periodontitis. J Endod. 2017;43(7):1058-63.

Rossi-Fedele G, Ahmed HM. Assessment of root canal filling removal effectiveness using micro-computed tomography: a systematic review. J Endod. 2017;43(4):520-6.

Rôças IN, Jung IY, Lee CY, Siqueira JF. Polymerase chain reaction identification of microorganisms in previously root-filled teeth in a South Korean population. J Endod. 2004;30(7):504-8.

Rôças IN, Siqueira JF, Santos KR. Association of Enterococcus faecalis with different forms of periradicular diseases. J Endod. 2004;30(5):315-20.

Rödig T, Reicherts P, Konietschke F, Dullin C, Hahn W, Hülsmann M. Efficacy of reciprocating and rotary NiTi instruments for retreatment of curved root canals assessed by micro-CT. Int Endod J. 2014;47(10):942-8.

Schirrmeister JF, Liebenow AL, Pelz K, Wittmer A, Serr A, Hellwig E, et al. New bacterial compositions in root-filled teeth with periradicular lesions. J Endod. 2009;35(2):169-74.

Schirrmeister JF, Wrbas KT, Meyer KM, Altenburger MJ, Hellwig E. Efficacy of different rotary instruments for gutta-percha removal in root canal retreatment. J Endod. 2006a;32(5):469-72.

Schirrmeister JF, Wrbas KT, Schneider FH, Altenburger MJ, Hellwig E. Effectiveness of a hand file and three nickel-titanium rotary instruments for removing gutta-percha in curved root canals during retreatment. Oral Surg Oral Med Oral Pathol Oral Radiol Endod. 2006b;101(4):542-7.

Shen Y, Zhou HM, Zheng YF, Peng B, Haapasalo M. Current challenges and concepts of the thermomechanical treatment of nickel-titanium instruments. J Endod. 2013;39(2):163-72.

Siqueira JF Jr, Pérez AR, Marceliano-Alves MF, Provenzano JC, Silva SG, Pires FR, et al. What happens to unprepared root canal walls: a correlative analysis using micro-computed tomography and histology/scanning electron microscopy. Int Endod J. 2018;51(5):501-8.

Sundqvist G, Figdor D, Persson S, Sjögren U. Microbiologic analysis of teeth with failed endodontic treatment and the outcome of conservative re-treatment. Oral Surg Oral Med Oral Pathol Oral Radiol Endod. 1998;85(1):86-93.

Torabinejad M, Corr R, Handysides R, Shabahang S. Outcomes of nonsurgical retreatment and endodontic surgery: a systematic review. J Endod. 2009;35(7):930-7.

Vasconcelos BC, Frota LM, Souza T de A, Bernardes RA, Duarte MA. Evaluation of the maintenance of the apical limit during instrumentation with hybrid equipment in rotary and reciprocating modes. J Endod. 2015;41(5):682-5.

Villas-Bôas MH, Bernardineli N, Cavenago BC, Marciano M, Del Carpio-Perochena A, de Moraes IG, et al. Micro-computed tomography study of the internal anatomy of mesial root canals of mandibular molars. J Endod. 2011;37(12):1682-6.

Wilcox LR, Juhlin JJ. Endodontic retreatment of Thermafil versus laterally condensed gutta-percha. J Endod. 1994;20(3):115-7.

Wilcox LR, Krell KV, Madison S, Rittman B.Endodontic retreatment: evaluation of gutta-percha and sealer removal and canal reinstrumentation. J Endod. 1987;13(9):453-7.

Wu MK, Wesselink PR, Walton RE. Apical terminus location of root canal treatment procedures. Oral Surg Oral Med Oral Pathol Oral Radiol Endod. 2000;89(1):99-103.

Yared G. Canal preparation using only one Ni-Ti rotary instrument: preliminary observations. Int Endod J. 2008;41(4):339-44.

Yürüker S, Görduysus M, Küçükkaya S, Uzunoğlu E, Ilgın C, Gülen O, et al. Efficacy of combined use of different nickel-titanium files on removing root canal filling materials. J Endod. 2016;42(3):487-92.

Zehnder M, Belibasakis GN. On the dynamics of root canal infections-what we understand and what we don't. Virulence. 2015;6(3):216-22.

Zehnder M, Guggenheim B. The mysterious appearance of enterococci in filled root canals. Int Endod J. 2009;42(4):277-87.

Zehnder M, Paqué F. Disinfection of the root canal system during root canal re-treatment. Endodontic Topics. 2011;19(1), 58-73.

Zuolo AS, Mello JE Jr, Cunha RS, Zuolo ML, Bueno CE. Efficacy of reciprocating and rotary techniques for removing filling material during root canal retreatment. Int Endod J. 2013;46(10):947-53.

Çanakçi BC, Ustun Y, Er O, Genc Sen O. Evaluation of apically extruded debris from curved root canal filling removal using 5 nickel-titanium systems. J Endod. 2016;42(7):1101-4.

APPENDIXES

APENDIX A - DECLARATION OF EXCLUSIVE USE OF ARTICLE IN THESIS

We hereby declare that we are aware that the article entitled **"Microtomography evaluation of glide path length influence on volume and apical limit of root canal fillings"** will be included in the thesis of graduate student Lincoln de Campos Fruchi, and may not be used in other works of graduate programs held at the Bauru School of Dentistry, University of São Paulo.

Bauru, April 23, 2018.

Lincoln de Campos Fruchi
Author — Signature

Murilo Priori Alcalde
Author — Signature

Rodrigo Ricci Vivan
Author — Signature

Flaviana Bombarda de Andrade
Author — Signature

Marco Antonio Hungaro Duarte
Author — Signature

APENDIX B - DECLARATION OF EXCLUSIVE USE OF ARTICLE IN THESIS

We hereby declare that we are aware that the article entitled **"Micro-CT assessment of filling removal effectiveness of two hybrid instrumentation protocols followed by supplementary irrigant-agitation procedures"** will be included in the thesis of graduate student Lincoln de Campos Fruchi, and may not be used in other works of graduate programs held at the Bauru School of Dentistry, University of São Paulo.

Bauru, April 23, 2018.

Lincoln de Campos Fruchi
Author

Signature

Murilo Priori Alcalde
Author

Signature

Rodrigo Ricci Vivan
Author

Signature

Pablo de Amoroso-Silva
Author

Signature

Clovis Monteiro Bramante
Author

Signature

Marco Antonio Hungaro Duarte
Author

Signature

ANNEXES

ANNEX A – Ethics committee approval

FACULDADE DE ODONTOLOGIA DE BAURU-USP

PARECER CONSUBSTANCIADO DO CEP

DADOS DO PROJETO DE PESQUISA

Título da Pesquisa: Avaliação por meio de Microtomografia e Microscopia Confocal da eficácia de instrumentos reciprocantes seguidos de rotatórios e do uso de ultrassom com solvente no retratamento de canais radiculares curvos

Pesquisador: lincoln de campos fruchi

Área Temática:

Versão: 1

CAAE: 44736215.9.0000.5417

Instituição Proponente: Universidade de São Paulo - Faculdade de Odontologia de Bauru

Patrocinador Principal: Financiamento Próprio

DADOS DO PARECER

Número do Parecer: 1.093.113

Data da Relatoria: 20/05/2015

Apresentação do Projeto:

No projeto Avaliação por meio de Microtomografia e Microscopia Confocal da eficácia de instrumentos reciprocantes seguidos de rotatórios e do uso de ultrassom com solvente no retratamento de canais radiculares curvos" serão utilizados 40 dentes humanos (molares inferiores) provenientes do Banco de Dentes Humanos da Faculdade de Odontologia da Universidade de São Paulo (FOUSP). Serão instrumentados os canais mesio vestibulares de quarenta dentes molares inferiores com instrumentos Reciproc R25 (VDW, Munique, Alemanha), sendo que em vinte dentes (grupo 1) será feito pré-alargamento com limas Pathfile (Dentsply, Maillefer, Ballaigues, Suíça) no limite apical do comprimento real do dente e no grupo 2 (n=20) com limite 1mm aquém do comprimento real. Os dentes serão obturados com técnica de condensação vertical aquecida (Schilder) e cimento AHPlus associado a Rodamina B a 0,1%. Posteriormente os dentes serão desobturados com instrumentos Reciproc R25 (VDW). Após a remoção do material obturador os dentes serão retratados e divididos conforme o instrumento utilizado, em dois grupos de 20 dentes, grupo 1a: Mtwo (VDW) 40, grupo 2a: R40 (VDW). Os dentes serão então subdivididos em dois grupos de vinte dentes de acordo com o uso de instrumento Irrisonic (Helse, São Paulo, SP, Brasil) (Grupo 1b) ou espaçador digital A de Níquel Titânio (Dentsply Maillefer, Suiça) (Grupo 2b) adaptado ao uso de aparelho de ultrassom ativados

Endereço: DOUTOR OCTAVIO PINHEIRO BRISOLLA 75 QUADRA 9
Bairro: VILA NOVA CIDADE UNIVERSITARIA **CEP:** 17.012-901
UF: SP **Município:** BAURU
Telefone: (14)3235-8356 **Fax:** (14)3235-8356 **E-mail:** cep@fob.usp.br

em aparelho de ultrassom (Jet Sonic; Gnatus, SP, Brasil) com potência de 15% ou 4,5K Hertz na presença do solvente Xilol no interior dos canais para o Grupo 1b e solvente Xilol com 50% ou 15K hertz de potência do aparelho de ultrassom para o Grupo 2b. A seguir os canais serão obturados com técnica de condensação vertical aquecida com cimento MTA Fillapex (Angelus, Londrina, PR, Brasil) adicionado a Fluoresceína a 0,1%. Será feito escaneamento por microtomografia computadorizada previamente à instrumentação inicial e a avaliação da eficácia do retratamento será feita pela diferença do volume inicial e remanescente de material obturador medidos através de microtomografias com os canais obturados e após o retratamento com os instrumentos rotatórios e reciprocantes após cada etapa, ou seja, após cada instrumento utilizado, e novamente após o uso de ultrassom.

Objetivo da Pesquisa:

Avaliar o retratamento de canais radiculares curvos com instrumentos rotatórios em movimento reciprocante e rotatório contínuo e do uso de ultrassom com Xilol.

Avaliação dos Riscos e Benefícios:

Não há riscos previsiveis para os participantes da pesquisa (dentes doados pelo banco de dentes humanos da Faculdade de Odontologia da Universidade de São Paulo, sem identificação dos pacientes) ou para os pesquisadores. Os benefícios consistem em contribuições compreender a eficácia de diferentes métodos de retratamento endodôntico frente às novas técnicas de retratamento e aos diferentes métodos de avaliação.

Comentários e Considerações sobre a Pesquisa:

A pesquisa utilizará 40 dentes para procedimentos laboratoriais, visando ao teste das hipóteses apresentadas, implicando o valor de R$9.440,00 na rubrica custeio. Os autores informam que haverá financiamento próprio, sem mencionar a contrapartida institucional.

Considerações sobre os Termos de apresentação obrigatória:

No formulário PB_Informações Básicas do Projeto, consta que os 40 dentes serão doados pelo Banco de Dentes Humanos da Faculdade de Odontologia da Universidade de São Paulo (FOUSP), quando, na realidade, trata-se de cessão destes dentes. O autor solicita a dispensa do TCLE, uma vez que utilizados dentes humanos extraídos fornecidos pelo Banco de Dentes humanos da Faculdade de Odontologia da Universidade de São Paulo, sem identificação dos pacientes.

Recomendações:

Recomenda-se a substituição do termo "doação de dentes" pelo termo "cessão de dentes".

FACULDADE DE ODONTOLOGIA DE BAURU-USP

Continuação do Parecer: 1.093.113

Conclusões ou Pendências e Lista de Inadequações:

Uma inadequação que requer correção refere-se a considerar como cessão de dentes os espécimes provenientes do Banco de Dentes Humanos da FOUSP.

Situação do Parecer:

Aprovado

Necessita Apreciação da CONEP:

Não

Considerações Finais a critério do CEP:

Esse projeto foi considerado APROVADO na reunião ordinária do CEP de 20.05.2015, com base nas normas éticas da Resolução CNS 466/12. Ao término da pesquisa o CEP-FOB/USP exige a apresentação de relatório final. Os relatórios parciais deverão estar de acordo com o cronograma e/ou parecer emitido pelo CEP. Alterações na metodologia, título, inclusão ou exclusão de autores, cronograma e quaisquer outras mudanças que sejam significativas deverão ser previamente comunicadas a este CEP sob risco de não aprovação do relatório final. Quando da apresentação deste, deverão ser incluídos todos os TCLEs e/ou termos de doação assinados e rubricados, se pertinentes.

BAURU, 03 de Junho de 2015

Assinado por:
Izabel Regina Fischer Rubira Bullen
(Coordenador)

Endereço: DOUTOR OCTAVIO PINHEIRO BRISOLLA 75 QUADRA 9
Bairro: VILA NOVA CIDADE UNIVERSITARIA **CEP:** 17.012-901
UF: SP **Município:** BAURU
Telefone: (14)3235-8356 **Fax:** (14)3235-8356 **E-mail:** cep@fob.usp.br

ANNEX B – Ethics committee approval

USP - FACULDADE DE ODONTOLOGIA DE BAURU DA USP

Plataforma Brasil

PARECER CONSUBSTANCIADO DO CEP

DADOS DO PROJETO DE PESQUISA

Título da Pesquisa: Avaliação por meio de Microtomografia e Microscopia Confocal da eficácia de instrumentos reciprocantes seguidos de rotatórios e do uso de ultrassom com solvente no retratamento de canais radiculares curvos

Pesquisador: lincoln de campos fruchi

Área Temática:

Versão: 1

CAAE: 44736215.9.0000.5417

Instituição Proponente: Universidade de São Paulo - Faculdade de Odontologia de Bauru

Patrocinador Principal: Financiamento Próprio

DADOS DA NOTIFICAÇÃO

Tipo de Notificação: Envio de Relatório Final

Detalhe:

Justificativa: Envio de relatório final para análise do CEP.

Data do Envio: 03/05/2018

Situação da Notificação: Parecer Consubstanciado Emitido

DADOS DO PARECER

Número do Parecer: 2.730.970

Apresentação da Notificação:

Notificação dos resultados finais da pesquisa apresentada em relatório final

Objetivo da Notificação:

Relatório final da pesquisa

Avaliação dos Riscos e Benefícios:

Não foram relatados riscos decorrentes da pesquisa de acordo com o proposto no projeto inicial

Comentários e Considerações sobre a Notificação:

Relatório final entregue cumprindo as normas deste CEP.

Considerações sobre os Termos de apresentação obrigatória:

Relatório final entregue cumprindo as normas deste CEP.

Endereço: DOUTOR OCTAVIO PINHEIRO BRISOLLA 75 QUADRA 9
Bairro: VILA NOVA CIDADE UNIVERSITARIA **CEP:** 17.012-901
UF: SP **Município:** BAURU
Telefone: (14)3235-8356 **Fax:** (14)3235-8356 **E-mail:** cep@fob.usp.br

USP - FACULDADE DE ODONTOLOGIA DE BAURU DA USP

Continuação do Parecer: 2.730.970

Conclusões ou Pendências e Lista de Inadequações:

Aprovado

Considerações Finais a critério do CEP:

O CEP reunido ordinariamente no dia 13/06/2018 acata por unanimidade o parecer APROVADO, emitido pelo relator, sobre o relatório final da pesquisa.

Este parecer foi elaborado baseado nos documentos abaixo relacionados:

Tipo Documento	Arquivo	Postagem	Autor	Situação
Envio de Relatório Final	Formulario_relatorio_final.docx	03/05/2018 12:21:46	lincoln de campos fruchi	Postado

Situação do Parecer:

Aprovado

Necessita Apreciação da CONEP:

Não

BAURU, 22 de Junho de 2018

Assinado por:
Ana Lúcia Pompéia Fraga de Almeida
(Coordenador)

Endereço: DOUTOR OCTAVIO PINHEIRO BRISOLLA 75 QUADRA 9
Bairro: VILA NOVA CIDADE UNIVERSITARIA **CEP:** 17.012-901
UF: SP **Município:** BAURU
Telefone: (14)3235-8356 **Fax:** (14)3235-8356 **E-mail:** cep@fob.usp.br

ANNEX C – Permission letter to include a published article from the Dental Press Endodontics journal in this thesis

DentalPress
PUBLISHING

05 de dezembro de 2017

Prezado Dr. Lincoln de Campos Fruchi

A Dental Press Editora, autoriza o uso das informações/imagens do artigo citado abaixo:

Fruchi LC, Vivan RR, Alcalde MP, Andrade FB, Duarte MAH. Microtomography evaluation of glide path length influence on volume and apical limit of root canal fillings. Dental Press Endod. 2017 May-Aug;7(2):15-20.

Solicitamos que seja citada a referência acima como fonte.

Qualquer dúvida estaremos à disposição.

Atenciosamente,

Simone L. L. Rafael
(44) 3033-9818
biblioteca@dentalpress.com.br
www.dentalpress.com.br

Av. Dr. Luiz Teixeira Mendes, 2712
Zona 05 | CEP 87015-001
Maringá | Paraná | Brazil

ANNEX D –Submission confirmation from the International Endodontic Journal.

26/04/2018 International Endodontic Journal - Manuscript ID IEJ-18-00311 - lincolnfruchi@uol.com.br - UOL Mail

UOL mail

★ **International Endodontic Journal - Manuscript ID IEJ-18-00311**

De: **International Endodontic Journal**
Para: **lincolnfruchi@uol.com.br ,lincoln.cf@uol.com.br**
Cópia:
Cópia oculta:
Assunto: International Endodontic Journal - Manuscript ID IEJ-18-00311
Enviada em: 25/04/2018 | 18:49
Recebida em: 25/04/2018 | 18:49

25-Apr-2018

Dear Dr. Fruchi

Your manuscript entitled "Micro-CT assessment of filling removal effectiveness of two hybrid instrumentation protocols followed by supplementary irrigant-agitation procedures" has been successfully submitted online to the International Endodontic Journal.

Your manuscript ID is IEJ-18-00311.

Please mention the above manuscript ID in all future correspondence or when calling the Editorial Office for questions. If there are any changes in your postal or e-mail address, please log in to ScholarOne Manuscripts at https://mc.manuscriptcentral.com/iej and edit your user information as appropriate.

You can also view the status of your manuscript at any time by checking your Author Centre after logging in to https://mc.manuscriptcentral.com/iej.

Thank you for submitting your manuscript to the International Endodontic Journal.

Kind regards

Paul Dummer
Editor, International Endodontic Journal
iejeditor@cardiff.ac.uk