

UNIVERSIDADE DE SÃO PAULO
FACULDADE DE ODONTOLOGIA DE BAURU

RODRIGO ANDRÉS NAVEDA ARAQUE

**Miniscrew-assisted rapid palatal expansion: Influence of age and
bone maturity in the dentoskeletal and periodontal results**

**Expansão maxilar ancorada em mini-implantes: Influência da idade
e da maturidade óssea nos resultados dento-esqueléticos e
periodontais**

BAURU

2022

RODRIGO ANDRÉS NAVEDA ARAQUE

Miniscrew-assisted rapid palatal expansion: Influence of age and bone maturity in the dentoskeletal and periodontal results

Expansão maxilar ancorada em mini-implantes: Influência da idade e da maturidade óssea nos resultados dento-esqueléticos e periodontais

Tese constituída por artigos apresentada à Faculdade de Odontologia de Bauru da Universidade de São Paulo para obtenção do título de Doutor em Ciências no Programa de Ciências Odontológicas Aplicadas, na área de concentração Ortodontia.

Orientador: Profa. Dra. Daniela Gamba Garib Carreira

BAURU

2022

Naveda Araque, Rodrigo Andrés

Miniscrew-assisted rapid palatal expansion:
Influence of age and bone maturity in the
dentoskeletal and periodontal results / Rodrigo
Andrés Naveda Araque. -- Bauru, 2022.

80 p. : il. ; 31cm.

Tese (Doutorado) – Faculdade de Odontologia
de Bauru. Universidade de São Paulo

Orientador: Profa. Dra. Daniela Gamba Garib
Carreira

Autorizo, exclusivamente para fins acadêmicos e científicos, a
reprodução total ou parcial desta tese, por processos
fotocopiadores e outros meios eletrônicos.

Assinatura:

Data:

Comitê de Ética da FOB-USP
Protocolo nº: 22084619.5.0000.5417
Data: **13 de dezembro de 2019**

ERRATA

Universidade de São Paulo
Faculdade de Odontologia de Bauru
Assistência Técnica Acadêmica
Serviço de Pós-Graduação



FOLHA DE APROVAÇÃO


Tese apresentada e defendida por
RODRIGO ANDRES NAVEDA ARAQUE
e aprovada pela Comissão Julgadora
em 28 de março de 2022.





Prof. Dr. **ALEXANDRE MAGNO DOS SANTOS**





Prof. Dr. **HIDEO SUZUKI**

Prof.^a Dr.^a **FELICIA MIRANDA**

Prof.^a Dr.^a **DANIELA GAMBA GARIB CARREIRA**
Presidente da Banca
FOB - USP


Prof. Dr. Marco Antonio Hungaro Duarte
Presidente da Comissão de Pós-Graduação
FOB-USP

 Al. Dr. Octávio Pinheiro Brisolla, 9-75 | Bauru-SP | CEP 17012-901 | C.P. 73
 <https://posgraduacao.fob.usp.br>
 14 | 3235-8223 / 3226-6097 / 3226-6096
 posgrad@fob.usp.br

 [posgraduacaofobusp](#)
 [@posgradfobusp](#)
 [fobuspoficial](#)
 [@Fobpos](#)

DEDICATÓRIA

À minha família, **Rodrigo José, Isabelita, Pao e José Luís**. Seu exemplo foi a bússola que me guiou nessa caminhada de 8 anos

A mi familia, **Rodrigo José, Isabelita, Pao y José Luís**. Su ejemplo fue la brújula que me guio en este caminar de 8 años.

AGRADECIMENTOS

A **Deus**, por ter me acompanhado todos os dias da minha vida no Brasil.

Aos meus pais **Rodrigo José** e **Isabelita**, amigos, maestros, guias. Ainda longe nunca me senti só, pois sabia que com uma ligação podia me sentir em casa. Vocês foram e sempre serão o pilar fundamental das minhas conquistas. Mi eterno gracias para ustedes.

Aos meus irmãos, **Paola** e **José Luís**, pelo apoio, torcida e carinho que me deram desde que criança até hoje. Saber que vocês existem me deixa feliz.

Aos meus tios e primos, por sempre terem torcido por mim.

Ao **Ernesto**, meu irmão de outra mãe, obrigado pelos ensinamentos, pelas conversas e pelo apoio incondicional desde sempre. Nossa convivência juntos ficara sempre no meu coração.

Ao **José Gregorio**, outro irmão, por sempre ser o primeiro em ver as minhas capacidades e me incentivar a ser melhor ortodontista e professor.

À minha querida **María Pía**, sua companhia, seu sorriso e sua forma de ser fizeram minha vida mais feliz. Obrigado pelo constante aprendizado de vida, ortodontia e docência.

Ao **Silvio**, mais um irmão, que me demonstrou que existe a possibilidade de conciliar o trabalho e o lazer com 100% de efetividade. Obrigado por ser um exemplo de dedicação e organização.

À minha orientadora Professora **Daniela Garib**, pela paciência, competência, dedicação, carinho e apoio. Sua sala se converteu no santuário no qual ideias podem ser discutidas, alunos podem ser escutados e no qual todos os problemas são solucionados. Obrigado por ter me aceitado como o seu orientado, levarei isso no meu coração pelo resto da minha vida. Muchas gracias por todo, querida profesora Dani.

Ao Professor **Alexandre Magno dos Santos**, pela paciência e carinho com que me ensinou a técnica apresentada nessa pesquisa. Você é um exemplo de clínico, professor e amigo, levo todos seus conselhos comigo.

À minha turma de mestrado: **Cinthya, Cristina, Danelin, Gabriela, Jessica, José, Marcelo, María Claudia, María Pía, Olga e Silvio**. Obrigado pela convivência no mestrado, aprender junto com vocês foi muito mais simples.

À minha turma de doutorado: **Cinthya, Cristina, Gabriela, José, Marcelo V, María Pía, Olga, Silvio, Pedro, Luciana, Marcelo C**. Que prazer ter conhecido vocês.

Ao Professor **Guilherme Janson**, que com dedicação e com o jeito único ele abriu para mim as portas da vida científica. Levarei seus ensinamentos comigo pelo resto da minha vida. Já falei mil vezes, meu eterno carinho e respeito para você.

Ao Professor **Estevam Bonfante**, sua conversa com a Prof.^a Daniela mudou da melhor forma minha vida acadêmica. Obrigado por ter confiado na minha capacidade e por sempre me receber com um sorriso e um abraço sincero.

Aos Professores do Departamento de Ortodontia, **Prof. Dr. Arnaldo Pinzan, Prof. Dr. José Fernando Castanha Henriques, Prof. Dr. Marcos Roberto de Freitas, Prof. Dr. Renato Rodrigues de Almeida**, pelos ensinamentos nos últimos 5 anos. Sua dedicação à FOB-USP é admirável.

Aos meus amigos do Doutorado 2017-2020, **Aron, Camila e Felícia**, sempre dispostos a ajudar, a ensinar e passar todas as dicas necessárias para que a vida na pós-graduação seja mais simples. Obrigado pelo exemplo e pelo carinho nestes 5 anos.

À banca examinadora deste trabalho, por aceitarem o convite e por toda a atenção e tempo disponibilizado.

À **Vera Purgato**, por sempre estar disposta a me ajudar com qualquer documento e informação, por sempre ter um tempo para conversar, e pela sinceridade com que sempre atuou.

À **Cléo Vieira**, sua presença na clínica de Ortodontia faz com que ela seja muito mais prazerosa. Sua organização, dedicação e sinceridade são admiráveis.

Aos funcionários do Departamento de Ortodontia: **Sérgio Vieira**, e **Wagner Baptista**, pela colaboração, disposição e ajuda em todos os trabalhos realizados.

Ao **Daniel Selmo**, pela colaboração e sorriso sincero durante esses anos.

Aos pacientes da FOB-USP, pelo carinho e confiança. Em especial aos pacientes dessa pesquisa, sem vocês tudo isso não seria possível.

À **Faculdade de Odontologia de Bauru- Universidade de São Paulo**, na pessoa do diretor **Prof. Dr. Carlos Ferreira dos Santos**.

À **CAPES**. O presente trabalho foi realizado com apoio da Coordenação de Aperfeiçoamento de Pessoal de Nível Superior – Brasil (CAPES) – Código de Financiamento 001.

ABSTRACT

ABSTRACT

Miniscrew-assisted rapid palatal expansion: Influence of age and bone maturity in the dentoskeletal and periodontal results

Introduction: The aim of the present study was to compare the dentoskeletal and periodontal changes after MARPE in patients aged 18-29 year versus patients aged 30-45 years, and to evaluate the midpalatal suture (MPS) bone repair after MARPE in adults. **Methods:** Patients older than 18 years with maxillary transverse deficiency were recruited. Patients were treated with miniscrew assisted rapid palatal expansion using a prefabricated expander with four paramedian miniscrews. The sample comprised 28 subjects with transverse maxillary discrepancy successfully treated with MARPE. Young-Adult Group (YA) was composed by 14 subjects (mean age of 22.8 years, 3 male, 11 female). Middle-Adult Group (MA) was composed by 14 subjects (mean age 36.8 years, 6 male, 8 female). Cone-beam computed tomography (CBCT) was used to evaluate transversal effects and MPS repair. Posterior skeletal effects were measured at the level of the palatine root of the maxillary first right molar, and anterior skeletal effects were measured at the level of the maxillary first right premolar, approximately 15mm anteriorly. Dental effects of first molars and first premolars were measured. Periodontal effects were evaluated measuring alveolar bone thickness of maxillary first molars and first premolars between the apical and medial third of the teeth. Changes were obtained by the difference of measurements achieved. Objective and subjective assessments of MPS repair were performed. Objective assessments were performed measuring MPS bone density at anterior, median and posterior region of the hard palate. Midpalatal suture bone repair was scored 0 to 3 considering, respectively, the complete absence of bone repair in the MPS, the repair of less than 50% of the MPS, the repair of more than 50% of the MPS and the complete repair of the MPS. **Results:** Intergroup comparison for the skeletal, dental and periodontal changes showed no significant differences between both study groups. For the MPS repair, the objective evaluation showed a significant higher bone density at the pre-expansion stage in all palatal regions. Scores 1, 2 and 3 were found in 19.05%, 38.09% and 42.86% of the sample, respectively. The most common region demonstrating absence of bone repair was the middle third. The anterior third of the midpalatal suture was repaired in all patients. **Conclusions:** After MARPE, middle adults showed similar dentoskeletal and periodontal changes compared to young adults. Most adult patients

demonstrated incomplete repair of the midpalatal suture after MARPE. However, adequate bone repair covering more than half of the hard palate extension was observed in 80.95% of the patients. **Funding:** This study was financed in part by the Coordenação de Aperfeiçoamento de Pessoal de Nível Superior – Brasil (CAPES) – Finance Code 001.

Keywords: Palatal Expansion Technique, Skeletal Anchorage, Cone-Beam Computed Tomography, Bone Repair.

RESUMO

RESUMO

Expansão maxilar ancorada em mini-implantes: Influência da idade e da maturidade óssea nos resultados dentoalveolares e periodontais

Introdução: O objetivo do presente estudo foi comparar as alterações dentoalveolares e periodontais após MARPE em pacientes com idade entre 18-29 anos versus pacientes com idade entre 30-45 anos, e avaliar o reparo ósseo da sutura palatina média (SPM) após MARPE em adultos. **Métodos:** Foram recrutados pacientes maiores de 18 anos com deficiência transversal da maxila. Os pacientes foram tratados com expansão rápida da maxila assistida por mini-implantes usando um expansor pré-fabricado com quatro mini-implantes colocados paralelos à SPM. A amostra foi composta por 28 indivíduos com discrepância transversal da maxila tratados com MARPE. O Grupo Adulto Jovem (AJ) foi composto por 14 sujeitos (idade média de 22,8 anos, 3 do sexo masculino, 11 do sexo feminino). O Grupo de Adultos Médios (AM) foi composto por 14 sujeitos (idade média de 36,8 anos, 6 homens, 8 mulheres). A tomografia computadorizada de feixe cônico (TCFC) foi usada para avaliar os efeitos transversais e o reparo da MPS. Os efeitos alveolares posteriores foram medidos ao nível da raiz palatina do primeiro molar superior direito, e os efeitos alveolares anteriores foram medidos ao nível do primeiro pré-molar superior direito. Os efeitos dentários dos primeiros molares e primeiros pré-molares também foram medidos. Os efeitos periodontais foram avaliados medindo-se a espessura do osso alveolar dos primeiros molares e primeiros pré-molares superiores entre o terço apical e medial dos dentes. As alterações foram obtidas pela diferença das medidas alcançadas. Avaliações objetivas e subjetivas do reparo da SPM foram realizadas. A avaliação objetiva foi realizada medindo a densidade óssea da SPM na região anterior, média e posterior do palato duro. O reparo ósseo da sutura palatina mediana foi pontuado de 0 a 3 considerando, respectivamente, a ausência completa de reparo ósseo da SPM, o reparo de menos de 50% da SPM, o reparo de mais de 50% da SPM e o reparo completo da SPM. **Resultados:** A comparação intergrupos para as alterações alveolares, dentárias e periodontais não mostrou diferenças significativas entre os dois grupos de estudo. Para o reparo de MPS, a avaliação objetiva mostrou uma densidade óssea significativamente maior na fase de pré-

expansão em todas as regiões palatinas. Os escores 1, 2 e 3 foram encontrados em 19,05%, 38,09% e 42,86% da amostra, respectivamente. A região mais comum demonstrando ausência de reparo ósseo foi o terço médio. O terço anterior da sutura palatina média foi reparado em todos os pacientes. **Conclusões:** Após MARPE, adultos médios apresentaram alterações dentoalveolares e periodontais semelhantes aos adultos jovens. A maioria dos pacientes adultos demonstrou reparo incompleto da sutura palatina média após MARPE. Entretanto, reparo ósseo adequado cobrindo mais da metade da extensão do palato duro foi observado em 80,95% dos pacientes. **Financiamento:** Este estudo foi financiado em parte pela Coordenação de Aperfeiçoamento de Pessoal de Nível Superior – Brasil (CAPES) – Código de financiamento 001.

Palavras-chave: Técnica de expansão palatina, Ancoragem esquelética, Tomografia computadorizada de feixe cônico, Reparo ósseo.

LIST OF ILLUSTRATIONS

ARTICLE 1

- Figure 1** - MARPE appliance used in both groups.....37
- Figure 2** - Maxillary variables analyzed. (A) Skeletal transversal variables measured parallelly to the horizontal plane in coronal sections passing through maxillary first molars and first premolars: nasal cavity width measured at the level of the wider region of the nasal cavity lower third; maxillary width measured as a tangent to the inferior border of the nasal cavity; and alveolar width measured 10mm below the last measurement. (B) Dental variables were measured in coronal sections passing through the maxillary first molars and first premolars: inter-root width measured between the palatal roots; maxillary arch width measured between maxillary first molar distolingual cusp or between maxillary first premolars lingual cusps; and dental tip defined as an angle between the tooth long axes, determined by connecting the palatine cusp and the palatal root apex, in relation to the nasal floor line. (C) Periodontal variables measured in cross sections passing through the palatine and distobuccal roots of maxillary first molar and by the center of maxillary first premolar. Maxillary first molar and first premolar were divided in three thirds based on the distance between palatal cusp tip and palatal root apex. The buccal bone plate thickness (BBT) and lingual bone plate thickness (LBT) were measured between the middle and apical thirds, parallelly to the horizontal plane.....38
-
-

ARTICLE 2

Figure 1 - Expander used for MARPE.	52
Figure 2 - Standardization of image position	53
Figure 3 - Examples of scores 1 to 3 for midpalatal bone repair after MARPE. A. Score 1: incomplete bone repair in the midpalatal suture covering less than 50% of the hard palate; B. Score 2: incomplete bone formation in the midpalatal suture with more than 50% of the hard palate demonstrating bone repair; C. Score 3: complete repair of the midpalatal region extending from the anterior to the posterior region of the hard palate	54
Figure 4 - A transpalatal arch of 0.8mm stainless-steel wire installed immediately after expander removal	55

LIST OF TABLES

ARTICLE 1

- Table I** - Intergroup comparisons for initial age and sex ratio (t and chi-square tests)39
- Table II** - Intergroup comparisons of pretreatment variables (t-test and Mann Whitney U test).....40
- Table III** - Intergroup comparisons of interphase changes (t-test and Mann Whitney U test).....41

ARTICLE 2

- Table I** - Measurement of midpalatal suture bone density at T1 and T2.....56
- Table II** - Regeneration stage intra and interexaminer reproducibility57
- Table III** - Distribution of the regeneration stages, initial age, and time of retention58
- Table IV** - Distribution of the regenerated areas of the midpalatal suture59
-
-

LIST OF ABBREVIATIONS AND ACRONYMS

MARPE	Miniscrew Assisted Rapid Palatal Expansion
RPE	Rapid Palatal Expansion
CBCT	Cone-beam computed tomography
CAPES	Coordenação de Aperfeiçoamento de Pessoal de Nível Superior.
BBT	Buccal Bone Thickness.
LBT	Lingual Bone Thickness.
MPS	Midpalatal Suture
HU	Hounsfield Units

TABLE OF CONTENTS

1	INTRODUCTION	21
2	ARTICLES	25
2.1	ARTICLE 1 - Immediate dentoskeletal and periodontal effects of miniscrew assisted rapid palatal expansion: comparison between young vs middle adults	26
2.2	ARTICLE 2 - Midpalatal suture bone repair after miniscrew-assisted rapid palatal expansion in adults.....	42
3	DISCUSSION.....	61
4	FINAL CONSIDERATIONS.....	64
	REFERENCES	66
	APPENDIX.....	72
	ANNEXES.....	75

1 INTRODUCTION

1 INTRODUCTION

Midpalatal suture (MPS) split has proven to be an adequate method for the treatment of maxillary transverse discrepancy, maxillary crowding and as part of Class II and Class III treatment in growing patients.¹⁻⁴ This procedure was first described by Angell in 1860.⁵ However, it was clinically accepted since 1961 after the studies performed by Haas.³ Haas proved, clinically and radiographically, that it was possible to separate the MPS through the application of transversal forces using the teeth and the palatal mucosa as anchorage.³

Rapid palatal expansion (RPE) increase arch perimeter and interdental distances of canines and posterior teeth.^{6,7} This procedure along with interproximal reduction and bone anchorage decreased the necessity of teeth extraction related to crowding.^{6,8} Nevertheless, orthopedic effects of conventional RPE decrease with age.⁹⁻¹¹ In young patients 50% of orthopedic effect is expected, while teenagers present 30% of orthopedic effect, regarding the total amount of expansion.¹² It was previously reported that patients between 16 and 28 years treated with conventional RPE presented a success rate of 81.5%, based on the interincisal diastema presence.¹³ However, success decreased with age, and complications varying from moderate to severe were reported.¹³

Unsuccess is related to the failure of opening the MPS, and conventional RPE in adults has relevant failure rates, with complications such as pain, mucosal ulceration/necrosis, excessive buccal tipping of anchor teeth and gingival recession of posterior teeth.¹³ Failure of conventional RPE in adults is associated to the greater bone resistance and the greater maturation of the midpalatal and circummaxillary sutures.^{14,15} In order to treat maxillary transverse discrepancy in adults, surgically assisted rapid palatal expansion (SARPE) was introduced.¹⁶ SARPE was indicated for adult patients or in cases of failure with conventional RME.^{16,17} SARPE aims to reduce the strength of the zygomatic and midpalatal bone sutures to allow the rapid palatal expansion in adults.^{16,18} Asymmetrical expansion, local infections, and endodontic problems have been observed after SARPE.¹⁹ Periodontal detrimental effects in the central incisors and anchorage teeth have also been reported after SARPE.²⁰ Despite

these secondary detrimental effects, SARPE has shown good short-term and long-term stability.^{21,22}

In order to reduce the side effects of RPE in adults, maxillary distraction anchored in palatal implants was introduced.²³⁻²⁵ Nonetheless, installation and removal of implants required invasive surgical procedures, in addition to the increased risk of root injuries and infections.^{23,25} In 2008, maxillary skeletal expansion using small implants with low-quality titanium, to prevent osseointegration, was described.²⁶ This expansion procedure proved to be effective, with less buccal tipping of posterior teeth, less apical resorption and avoiding root fenestrations.²⁶ However, it was limited by the need of a surgical procedure to install the implant.

Miniscrews were introduced in the orthodontic field due to the versatility, low cost, and especially to the easy installation and removal, that eliminated the need for complex surgical procedures. The first miniscrew assisted rapid palatal expansion (MARPE) in an adult patient was reported by Lee et al. in 2010.²⁷ The procedure was performed in a 20-year-old male patient with maxillary transversal deficiency and mandibular prognathism.²⁷ In this case, MARPE aimed to eliminate the need of multiple surgeries that would be required to correct transverse and sagittal problems. A modify Hyrax anchored to the first premolars, first molars and 4 miniscrew was used. The separation of the midpalatal suture was confirmed by intraoral and anteroposterior radiographs. Excellent post-expansion stability was observed without periodontal damage.²⁷ Since then, MARPE in adults has shown excellent results expanding the age limits for orthopedic skeletal expansion.²⁸⁻³³

Immediate skeletal and dental effects of MARPE in adult patients have been previously studied. A pyramidal expansion pattern with more dental effects, similar to conventional rapid palatal expansion, was observed.²⁸ Skeletal transverse dimensions at the level of the nasal cavity, maxillary basal bone and maxillary alveolar bone increased significantly after MARPE.^{28,30,34} The skeletal effect corresponded to approximately 40% of the amount of screw activation.²⁸ Interdental distance increase was also reported after MARPE.^{28,30,34} Good stability in the long-term, with no significant relapse after orthodontic treatment has been reported.^{28,30,34} Significant decrease of the dental effects after comprehensive orthodontic treatment was observed, however, with no relapse of posterior crossbite.^{28,30,34} The question that rises

is whether the midpalatal suture repair after MARPE in mature patients is similar to that observed in growing patients.

Midpalatal suture repair in growing patients after RPE has been previously studied.^{35,36} Histological evaluation of the MPS repair after RPE in children of 8 to 13 years of age showed evidence of inflammation with intense osteoblastic activity after the first month of retention.³⁶ Bone islands along the suture were observed after 5 to 6 months, and after 1 year of retention a complete repaired suture was present.³⁶ A radiographic evaluation of a 10-year-old boy treated with RPE, showed well established mineralization of the MPS after 3 months of retention, similar to the initial level.³⁵ Tomographic evaluation performed in a sample of children from 5 to 10 years showed a completely ossified suture after 8 to 9 months of retention.³⁷ MPS repair after MARPE in adult patients was not previously described. Nonetheless, previous studies with surgically assisted rapid palatal expansion (SARPE) in adults showed absence of complete sutural repair after 3 to 9 months of retention.³⁸⁻⁴⁰

The mean age of patients in the current studies vary from 20 to 23 years of age, however, the success observe in young adult patients has become the base for treating older patients. So, the possibility of using MARPE in more mature subjects is still in debate. Also, differences between young and adult patients for timing and pattern of MPS repair after rapid maxillary expansion are expected. Midpalatal suture repair after MARPE is important to be assessed in order to define an adequate protocol of post-expansion retention. Therefore, the aim of the present study was to compare the dentoskeletal and periodontal changes after MARPE in patients aged 18-29 versus patienes aged 30-45 years, and to evaluate bone repair after midpalatal suture split with MARPE in adults and to propose a classification method of midpalatal suture repair.

2 ARTICLES

2 ARTICLES

The articles presented in this thesis were written according to the American Journal of Orthodontics and Dentofacial Orthopedics instructions and guidelines for article submission.

ARTICLE 1 - Immediate dentoskeletal and periodontal effects of miniscrew assisted rapid palatal expansion: comparison between young vs middle adults

ARTICLE 2 - Midpalatal suture bone repair after miniscrew-assisted rapid palatal expansion in adults

2.1 ARTICLE 1

Immediate dentoskeletal and periodontal effects of miniscrew assisted rapid palatal expansion: comparison between young vs middle adults

ABSTRACT

Introduction: This study aimed to compare the dentoskeletal and periodontal changes after miniscrew-assisted rapid palatal expansion (MARPE) in patients from 18 to 29 years of age versus 30 to 45 years of age. **Methods:** The sample comprised 28 subjects with transverse maxillary discrepancy successfully treated with MARPE. Young-Adult Group (YA) was composed by 14 subjects (mean age of 22.8 years, 3 male, 11 female). Middle-Adult Group (MA) was composed by 14 subjects (mean age 36.8 years, 6 male, 8 female). Cone-beam computed tomography scans (CBCT) taken before (T0) and immediately after expansion (T1) were analyzed using OnDemand3D Dental software. Using CBCT coronal images, transversal dentoskeletal and periodontal variables were measured pre and postexpansion. Intergroup comparison of expansion changes were performed using t and Mann-Whitney tests ($p < 0.05$). **Results:** Groups were compatible at T1 for most CBCT measurements. A success rate of midpalatal suture opening of 100% and 81% was observed for young and middle adult groups, respectively. No intergroup differences were found for the increases in the maxillary and dental arch widths. Buccal tip of anchorage teeth was observed similarly in both groups. The buccal bone thickness of posterior teeth decreased and the lingual bone thickness increased after expansion with no difference between groups. **Conclusions:** After MARPE, middle adults showed similar dentoskeletal and periodontal changes compared to young adults.

Keywords: Palatal Expansion Technique; Skeletal Anchorage; Cone-Beam Computed Tomography.

INTRODUCTION

Rapid palatal expansion (RPE) is an established procedure for treating maxillary constrictions in growing patients.^{1,2} The skeletal effects produced by RPE comprise the intermaxillary suture split increasing the width of maxillary basal bone and nasal cavity.³ Age is a limiting factor for orthopedic maxillary expansion.⁴ Adult patients have an uncertain prognosis for midpalatal suture split with conventional RPE.⁵

Midpalatal and circummaxillary sutures start to fuse at late adolescence and craniofacial structure become more rigid with age.^{6,7} Adult patients show greater resistance to expansion forces. In subjects older than 18 years of age, the skeletal effects of RPE are negligible. Greater dentoalveolar and undesirable secondary effects are expected after conventional RPE in adult patients.⁵ Surgical assisted rapid palatal expansion (SARPE) is usually indicated for postpubertal patients.⁸ However, SARPE has the disadvantages of higher economic costs and morbidity related to surgical procedures.⁹

Mini-implant assisted rapid palatal expansion (MARPE) was firstly described 12 years ago¹⁰ becoming a simpler option for maxillary skeletal expansion in adults. MARPE allowed the application of transversal forces directly to the palate, producing an adequate skeletal effects and slight buccal tip of anchorage teeth.¹¹ Excellent success rates were observed for young adult patients, varying from 76% to 92%.¹¹⁻¹⁵ Transversal dimensions of the nasal cavity, maxillary basal bone and interdental distances increased significantly after MARPE in adult patients.¹¹⁻¹⁴ The maxillary skeletal effect of approximately 40% regarding the total amount of expansion was reported after MARPE.¹² An adequate stability in the long-term was also observed with no clinically significant relapse.^{14,15}

Most previous studies have evaluated MARPE effects at age 18 to 30 years. Successful attempts to treat older adult patients were also reported.^{16,17} However, no previous studies have evaluated the MARPE transversal effects in patients older than 30 years. The basal bone transversal change is comparable before and after 30 years of age? The anchorage teeth tip and the periodontal changes are similar in young and middle adults? This study aimed to compare the dentoskeletal and periodontal changes after MARPE in patients aged 18-29 versus patients from 30 to 45 years. The null hypothesis was that both age groups have similar dentoskeletal and periodontal effects.

MATERIAL AND METHODS

This prospective study was approved by the institutional Research Ethics Committee of _____ . The primary outcome was the maxillary width increase (MW) at the level of the hard palate. The sample size calculation was based on a standard deviation for MW of 1.8mm¹³ with a minimum intergroup difference of 2mm. An alpha value of 5% and a statistical power of 80% were considered. The minimum sample size for each group was 14 patients.

A sample of adult patients treated with MARPE was collected at a private practice and two postgraduation programs. The inclusion criteria were patients older than 18 years of age with unilateral or bilateral posterior crossbite, and history of successful MARPE therapy with clinical or radiographic evidence of midpalatal suture split. The exclusion criteria were patients older than 45 years, presence of craniofacial anomalies and presence of active/inactive periodontal disease.

Young-Adult group (YA) was composed by 14 patients from 18 to 29 years of age (3 male, 11 female) with an initial mean age of 22.87 years (SD=3.52). Middle-Adult Group (MA) comprised 14 subjects between 30 and 45 years (6 male, 8 female) with an initial mean age of 36.85 years (SD=5.55). A prefabricated expander (_____) was used in all patients of both groups (Fig. 1). The expander consisted of a Hyrax expander with four paramedian miniscrews positioned approximately in the middle third of the hard palate (Fig. 1). The expanders were activated one-quarter turn (0.2mm) twice a day until the opening of a midline diastema. After the midpalatal suture split, the screw was activated one-quarter turn a day in the consecutive days until reaching an overcorrection of the posterior crossbite. The active expansion phase length was approximately 21 to 30 days. The screw was expanded 6.03mm in the YA group and 5.69mm in the MA group.

CBCT exams were obtained before expansion (T0) and immediately after the active phase (T1) using 120kVp, a FOV of 8 to 13cm and a voxel size of 0.4mm. Image position standardization was performed in the three orthogonal planes (Fig. 2). In the frontal view, the plane passing through the lower limit of the nasal cavity was positioned parallel to the horizontal plane. In the sagittal view, a plane passing through the anterior and posterior nasal spines was oriented parallel to the horizontal plane. In the axial view, the midpalatal suture was positioned perpendicular to the horizontal plane.

A CBCT frontal section passing through the canal of the palatine root of maxillary right first molar and 15mm anteriorly were used to measure the dentoskeletal variable (Fig. 2A and 2B). In cross sections passing through the palatine and distobuccal roots of first molars and through the center of first premolars, the thickness of the buccal and lingual bone plates were measured (Fig. 2C).

Statistical Analysis

The method reliability was evaluated by remeasuring all the variables in 50% of the sample after a minimum 30-day interval. Intraclass correlation coefficient (ICC) was used for intra-examiner agreement assessment¹⁸. Dahlberg's formula¹⁹ was used to evaluate the random errors.

Normal distribution was assessed using the Shapiro-Wilk test. Intergroup comparisons of interphase changes were performed using t and Mann-Whitney tests ($p < 0.05$). Statistical analyses were performed using Statistica software (Statistica for Windows version 11.0; StatSoft Inc., Tulsa, OK).

RESULTS

The ICC varied from 0.889 to 0.994 showing adequate intra-examiner reproducibility. The random errors ranged from 0.10 (first premolar buccal bone thickness) to 1.80 (first premolar inclination).

Groups were comparable regarding sex distribution (Table I). Middle-Adult group showed a statistically significant older age than Young-Adult group (Table I). The comparison between starting forms showed that both groups presented similar skeletal, dental and periodontal variables, except for the inter-root width of first premolar, which was significantly greater in MA group (Table II).

A success rate of midpalatal suture opening of 100% and 81% was observed for young and middle adults, respectively.

All skeletal transverse widths increased after expansion from 1.4 to 4.2mm (Table III). The changes of maxillary widths were similar between groups at both molar and premolar regions (Table III).

The transversal increase at the level of the dental arch was greater than at the level of the root apex (Table III). MARPE caused a buccal tip of anchorage teeth

varying from 3.96 to 5.06 degrees (Table III). No differences between age groups was found for dental variables.

After MARPE, the buccal bone thickness decreased while the lingual bone thickness increased similarly in both age groups (Table III).

DISCUSSION

MARPE has been used to treat maxillary transversal deficiency in adult patients.^{10,12} However, the age limit for successful MARPE therapy remain unknown. Additionally, the transversal effects of MARPE in different age of adulthood were not clear. Previous studies have evaluated MARPE in young adult patients with age ranging from 18 to 30 years.^{11-14,20} In order to elucidate the outcomes of MARPE in older adults, the present study compared the dentoskeletal and periodontal changes between two age groups, young and middle adults. CBCT provide accurate information regarding the dentoskeletal and periodontal changes produced by RME.^{21,22} The reproducibility of maxillary transverse measurements after RPE in tomographic images are well documented in the literature.^{3,11,22} Adequate intraexaminer reproducibility was found for all the measurements (ICC ranging from 0.889 to 0.994).

In the present study, maxillary widths increased similarly in both groups (Table III). A pyramidal expansion pattern was observed, similarly to previous studies,^{2,20} with greater width increase at the alveolar level compared to the nasal level (Table III).

In the present study, the nasal cavity width at the posterior region increased by 41% and 32% of the total amount of screw expansion in young and middle adults, respectively. At the anterior region, the nasal cavity width increased by 46% and 38% of screw activation in young and middle adults, respectively. Similar results were previously reported in recent studies.^{14,20} In contrast, some studies with MARPE in adults found increases of nasal cavity width varying from 12.8% to 24.6%.¹¹⁻¹³ These differences might be related to the expander rigidity and sagittal position at the palate. Nasal cavity width increase after MARPE in adults showed acceptable one-year post-treatment stability.¹¹ Using Hybrid expanders in adolescents, a previous study reported an increase of the nasal cavity by 40% of the total amount of screw expansion.²² The expanders anchored with palatal miniscrews apply the expansion forces directly to palatal shelves closer to the nasal cavity, explaining these outcomes. A recent study observed that, in adult patients with obstructive sleep apnea, MARPE

produced an important improvement in the respiratory capacity and a significant reduction of the apnea/hypopnea index.²³

Producing a maxillary width increase is an important objective of MARPE. In the present study, maxillary basal bone increased similarly in both age groups at the anterior and posterior regions. At the posterior region, the maxillary width increased by 31% and 24% of the amount of screw activation in young and middle adults, respectively. These results were similar to those observed in adult patients after MARPE, that showed a maxillary width increase varying from 25,3% and 43.2%.^{11-14,20} Investigations using SARPE have reported less basal bone increase at the posterior region of the maxilla compared to MARPE.²⁰ At the anterior region, the maxillary basal bone increase were 52% and 45% of the amount of screw activation for young and middle adults, respectively. A previous study also reported similar increases of maxillary width after MARPE.²⁰ The similarity of skeletal effects between groups might be explained by the fact that, after the midpalatal split occurs, the maxillary resistance to lateral movements tend to be similar in young and middle adult patients.

The maxillary alveolar bone changes also showed no significant differences between the two study groups (Table III). Maxillary alveolar width at the posterior region (Alveolar width-6) increased 56% and 47.9% for the YA Group and MA Group, respectively. Changes at the maxillary alveolar width at the anterior region (Alveolar width-4) represented 69.6% and 62.5% of the total expansion for the YA Group and the MA Group, respectively. A previous study found an increase of 73.5% and 81.9% for the posterior and anterior regions, respectively.²⁰ Nevertheless, most previous studies have found an alveolar width increase that varied from 26.9% to 39.7%.¹¹⁻¹⁴

In the present study a success rate of 91% was observed for the complete sample, similarly to previous studies reporting success frequencies varying from 76% to 92%.¹¹⁻¹⁵ The success rate was smaller at middle adult age (80.9%) compared to young adults (100%). These results are in accordance with previous studies reporting that MARPE success decrease with age.^{15,24} These results were expected because midpalatal suture density and ossification continuously increase during aging.^{6,25,26} Besides age, other factors that have an influence on the success rate is sex²⁴ and the bone palate thickness¹⁵.

The dental effects of maxillary expansion in adults was observed even in the presence of skeletal anchorage. The dental changes were similar in both age groups.

In the present study, first molars and first premolar showed a buccal tip of approximately 4 degrees in accordance to previous studies.¹¹ The dental arch width increase was similar to the total amount of screw expansion, probably due to use of dental anchorage. These outcomes are in agreement with previous MARPE studies.^{11,12}

Buccal bone resorption have been observed after conventional RPE in young patients.²⁷ In adult patients, more detrimental effects would be expected.⁵ However, the use of miniscrews had a protective effect on the buccal bone plates that showed only a slight thickness decrease. Both age groups demonstrated similar decreases of the buccal bone plate thickness (Table III), pointing that 4 miniscrews seems enough to avoid damage of the periodontal bone for both young and middle adult patients. As expected, the lingual bone thickness increased similarly in both groups. These outcomes were also found in the MARPE study by Lim et al. in patients from 18 to 26 years of age.¹¹

The limitation of this study is the mixed sample of males and females, considering that females showed a success rate greater than males.²⁴ Skull bone density remained constant during adulthood in males and decrease in females.²⁸ Future studies should evaluate the dentoskeletal outcomes in different age groups separating man and woman by means of larger sample. Additionally, in woman, the effects of MARPE performed before and after menopause should also be evaluated.

CONCLUSIONS

The null hypothesis was confirmed. After MARPE, middle adults showed similar dentoskeletal and periodontal changes compared to young adults.

ACKNOWLEDGMENTS

This research was financed in part by the Coordenação de Aperfeiçoamento de Pessoal de Nível Superior – Brasil (CAPES) – Finance Code 001.

REFERENCES

1. Angell DJDC. Treatment of irregularity of the permanent or adult teeth. *Dental Cosmos* 1860;1:540-544.
 2. Haas AJ. Rapid expansion of the maxillary dental arch and nasal cavity by opening the midpalatal suture. *Angle Orthod* 1961;31:73-90.
 3. Christie KF, Boucher N, Chung CH. Effects of bonded rapid palatal expansion on the transverse dimensions of the maxilla: a cone-beam computed tomography study. *Am J Orthod Dentofacial Orthop* 2010;137:S79-85.
 4. Bishara SE, Staley RN. Maxillary expansion: clinical implications. *Am J Orthod Dentofacial Orthop* 1987;91:3-14.
 5. Capelozza Filho L, Cardoso Neto J, da Silva Filho OG, Ursi WJ. Non-surgically assisted rapid maxillary expansion in adults. *Int J Adult Orthodon Orthognath Surg* 1996;11:57-66; discussion 67-70.
 6. Melsen B, Melsen F. The postnatal development of the palatomaxillary region studied on human autopsy material. *Am J Orthod* 1982;82:329-342.
 7. Persson M, Thilander B. Palatal suture closure in man from 15 to 35 years of age. *Am J Orthod* 1977;72:42-52.
 8. Suri L, Taneja P. Surgically assisted rapid palatal expansion: a literature review. *Am J Orthod Dentofacial Orthop* 2008;133:290-302.
 9. Lanigan DT, Mintz SM. Complications of surgically assisted rapid palatal expansion: review of the literature and report of a case. *J Oral Maxillofac Surg* 2002;60:104-110.
 10. Lee KJ, Park YC, Park JY, Hwang WS. Miniscrew-assisted nonsurgical palatal expansion before orthognathic surgery for a patient with severe mandibular prognathism. *Am J Orthod Dentofacial Orthop* 2010;137:830-839.
 11. Lim HM, Park YC, Lee KJ, Kim KH, Choi YJ. Stability of dental, alveolar, and skeletal changes after miniscrew-assisted rapid palatal expansion. *Korean J Orthod* 2017;47:313-322.
 12. Choi SH, Shi KK, Cha JY, Park YC, Lee KJ. Nonsurgical miniscrew-assisted rapid maxillary expansion results in acceptable stability in young adults. *Angle Orthod* 2016;86:713-720.
-

13. Park JJ, Park YC, Lee KJ, Cha JY, Tahk JH, Choi YJ. Skeletal and dentoalveolar changes after miniscrew-assisted rapid palatal expansion in young adults: A cone-beam computed tomography study. *Korean J Orthod* 2017;47:77-86.
 14. Tang H, Liu P, Liu X, Hou Y, Chen W, Zhang L et al. Skeletal width changes after mini-implant-assisted rapid maxillary expansion (MARME) in young adults. *Angle Orthod* 2021;91:301-306.
 15. Jesus AS, Oliveira CB, Murata WH, Suzuki SS, Santos-Pinto AD. Would midpalatal suture characteristics help to predict the success rate of miniscrew-assisted rapid palatal expansion? *Am J Orthod Dentofacial Orthop* 2021;160:363-373.
 16. Kim H, Park SH, Park JH, Lee KJ. Nonsurgical maxillary expansion in a 60-year-old patient with gingival recession and crowding. *Korean J Orthod* 2021;51:217-227.
 17. Suzuki SS, Braga LFS, Fujii DN, Moon W, Suzuki H. Corticopuncture Facilitated Microimplant-Assisted Rapid Palatal Expansion. *Case Rep Dent* 2018;2018:1392895.
 18. Shrout PE, Fleiss JL. Intraclass correlations: uses in assessing rater reliability. *Psychol Bull* 1979;86:420-428.
 19. Dahlberg G. Standard error and medicine. *Acta Genet Stat Med* 1949;1:313-321.
 20. de Oliveira CB, Ayub P, Ledra IM, Murata WH, Suzuki SS, Ravelli DB et al. Microimplant assisted rapid palatal expansion vs surgically assisted rapid palatal expansion for maxillary transverse discrepancy treatment. *Am J Orthod Dentofacial Orthop* 2021;159:733-742.
 21. Garib DG, Henriques JF, Janson G, Freitas MR, Coelho RA. Rapid maxillary expansion--tooth tissue-borne versus tooth-borne expanders: a computed tomography evaluation of dentoskeletal effects. *Angle Orthod* 2005;75:548-557.
 22. Garib D, Miranda F, Palomo JM, Pugliese F, da Cunha Bastos JC, Dos Santos AM et al. Orthopedic outcomes of hybrid and conventional Hyrax expanders. *Angle Orthod* 2021;91:178-186.
 23. Brunetto DP, Moschik CE, Dominguez-Mompell R, Jaria E, Sant'Anna EF, Moon W. Mini-implant assisted rapid palatal expansion (MARPE) effects on adult obstructive sleep apnea (OSA) and quality of life: a multi-center prospective controlled trial. *Prog Orthod* 2022;23:3.
-

24. Jeon JY, Choi SH, Chung CJ, Lee KJ. The success and effectiveness of miniscrew-assisted rapid palatal expansion are age- and sex-dependent. *Clin Oral Investig* 2021.
 25. Angelieri F, Cevidanes LH, Franchi L, Goncalves JR, Benavides E, McNamara JA, Jr. Midpalatal suture maturation: classification method for individual assessment before rapid maxillary expansion. *Am J Orthod Dentofacial Orthop* 2013;144:759-769.
 26. Chae JM, Rogowski L, Mandair S, Bay RC, Park JH. A CBCT Evaluation of Midpalatal Bone Density in Various Skeletal Patterns. *Sensors (Basel)* 2021;21.
 27. Garib DG, Henriques JF, Janson G, de Freitas MR, Fernandes AY. Periodontal effects of rapid maxillary expansion with tooth-tissue-borne and tooth-borne expanders: a computed tomography evaluation. *Am J Orthod Dentofacial Orthop* 2006;129:749-758.
 28. Schulte-Geers C, Obert M, Schilling RL, Harth S, Traupe H, Gizewski ER et al. Age and gender-dependent bone density changes of the human skull disclosed by high-resolution flat-panel computed tomography. *Int J Legal Med* 2011;125:417-425.
-
-

FIGURE LEGENDS

Fig 1. MARPE appliance used in both groups.

Fig 2. Maxillary variables analyzed. **(A)** Skeletal transversal variables measured parallel to the ground in coronal sections passing through maxillary first molars and first premolars: nasal cavity width between the most lateral walls of the nasal cavity; maxillary width tangent to the inferior level of the nasal floor; and alveolar width measured 10mm below the nasal floor. **(B)** Dental variables measured in coronal sections passing through maxillary first molars and first premolars: inter-root width between palatal roots; maxillary arch width between maxillary first molars distolingual cusp and maxillary first premolars lingual cusps; and dental tip defined as an angle between the right and left tooth axes, determined by connecting the palatine cusp and palatal root apex, in relation to nasal floor. **(C)** Periodontal variables measured in cross sections passing through the palatine and distobuccal roots of maxillary first molar and the center of maxillary first premolar: maxillary first molar and first premolar were divided in thirds based on distopalatine cusp-palatal root apex and palatine cusp-root apex lengths, respectively, and buccal bone plate thickness (BBT) and lingual bone plate thickness (LBT) were measured parallel to the nasal floor between the middle third and apical third.

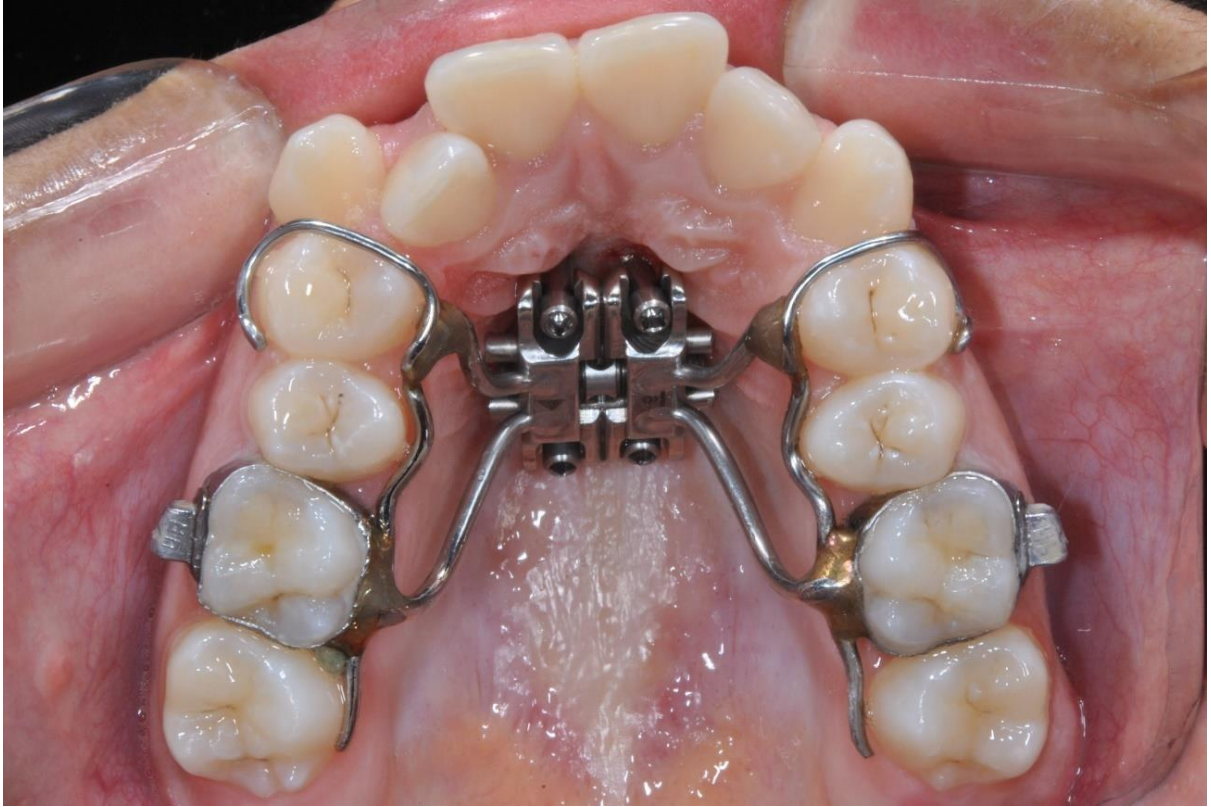

Fig 1.

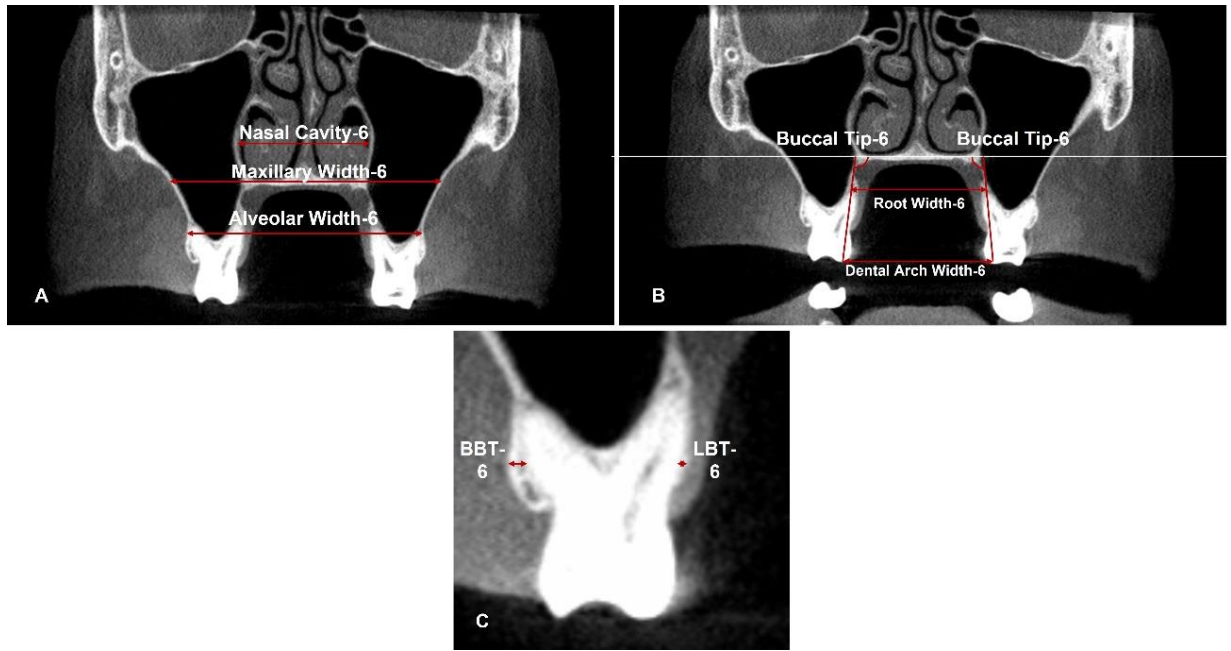


Fig 2.

Table I. Intergroup comparisons for initial age and sex ratio (t and chi-square tests).

Variable	Young-Adult Group (n = 14)		Middle-Adult Group (n = 14)		P
	Mean	SD	Mean	SD	
Age, y	22.87 (Min, 18.16; Max, 28.57)	3.52	36.85 (Min, 30.11; Max, 45.28)	5.55	<0.001 ^{t*}
Sex	n	%	n	%	
Male	3	21.43	6	42.86	0.225 [§]
Female	11	78.57	8	57.14	

^t t-test (Age); [§]Chi-square test (sex); * statistically significant.

Table II. Intergroup comparisons of pretreatment variables (t-test and Mann Whitney U test).

Variables	Young-Adult Group n=14		Middle-Adult Group n=14		Estimate Difference		
	Mean	SD	Mean	SD	Mean	CI 95%	p
SKELETAL							
Nasal Cavity-6	29.32	2.93	30.96	2.73	1.64	-0.55; 3.85	0.137 [†]
Maxillary Width-6	63.48	6.19	64.11	6.60	0.63	-4.34; 5.60	0.796 [†]
Alveolar Width-6	55.38	3.07	56.45	3.51	1.07	-1.50; 3.63	0.403 [†]
Nasal Cavity-4	27.26	3.72	28.19	4.69	0.93	-2.37; 4.21	0.910 [¥]
Maxillary Width-4	36.86	5.92	38.24	7.67	1.38	-3.94; 6.70	0.599 [†]
Alveolar Width-4	39.12	3.49	41.17	4.14	2.05	-0.93; 5.02	0.170 [†]
DENTAL							
Inter-root Width-6	31.64	3.46	33.37	4.10	1.73	-1.22; 4.68	0.239 [†]
Dental Arch Width-6	38.34	3.60	39.54	3.11	1.20	-1.42; 3.81	0.356 [†]
Buccal Tip-6	99.48	5.90	99.54	5.94	0.06	-3.11; 3.23	0.970 [†]
Inter-root Width-4	28.33	2.76	31.70	3.24	3.37	1.03; 5.72	0.006 ^{*†}
Dental Arch Width-4	33.00	3.39	34.48	3.39	1.48	-1.21; 4.16	0.270 [†]
Buccal Tip-4	97.86	7.92	94.47	7.73	-3.39	-7.57; 0.80	0.111 [†]
PERIODONTAL							
BBT-6	1.06	0.67	1.07	0.58	0.01	-0.32; 0.35	0.935 [†]
LBT-6	0.72	0.47	0.75	0.61	0.03	-0.26; 0.32	0.948 [¥]
BBT-4	0.70	0.32	0.76	0.42	0.06	-0.14; 0.25	0.600 [†]
LBT-4	1.47	1.04	1.18	0.71	-0.29	-0.76; 0.18	0.325 [¥]

[†] t-test; [¥] Mann-Whitney U test; ^{*}Statistically significant.

Table III. Intergroup comparison of interphase changes (t-test and Mann Whitney U test).

Variables	Young-Adult Group (T1-T0)		Middle-Adult Group (T1-T0)		Estimate Difference		
	Mean	SD	Mean	SD	Mean	CI 95%	p
Activation	6.03	1.74	5.69	1.36	-0.34	-1.55; 0.88	0.576
SKELETAL							
Nasal Cavity-6	2.47	1.35	1.81	1.01	-0.66	-1.59; 0.26	0.154 ^f
Maxillary Width-6	1.89	1.61	1.40	1.08	-0.49	-1.55; 0.58	0.362 ^f
Alveolar Width-6	3.38	1.75	2.73	1.73	-0.65	-2.00; 0.70	0.335 ^f
Nasal Cavity-4	2.77	1.53	2.17	1.03	-0.60	-1.61; 0.41	0.236 ^f
Maxillary Width-4	3.17	2.49	2.56	2.00	-0.61	-2.37; 1.14	0.477 ^f
Alveolar Width-4	4.20	2.19	3.56	1.90	-0.64	-2.22; 0.96	0.376 [¥]
DENTAL							
Inter-root Width-6	3.37	2.14	2.08	2.81	-1.29	-3.23; 0.64	0.454 [¥]
Dental Arch Width-6	6.08	1.79	6.26	2.43	0.18	-1.47; 1.84	0.817 ^f
Buccal Tip-6	4.18	3.80	4.95	3.96	0.77	-1.31; 2.84	0.465 ^f
Inter-root Width-4	3.56	2.09	2.46	1.51	-1.10	2.51; 0.32	0.126 ^f
Dental Arch Width-4	5.81	2.19	5.73	2.14	-0.08	-1.78; 1.60	0.922 ^f
Buccal Tip-4	3.96	4.58	5.06	4.06	1.10	-1.22; 3.42	0.346 ^f
PERIODONTAL							
BBT-6	-0.24	0.43	-0.26	0.43	-0.02	-0.25; 0.21	0.737 [¥]
LBT-6	0.39	0.43	0.46	0.52	0.07	-0.18; 0.32	0.706 [¥]
BBT-4	-0.23	0.29	-0.18	0.33	0.05	-0.12; 0.21	0.577 ^f
LBT-4	0.10	0.86	0.10	0.42	0.00	-0.37; 0.35	0.164 [¥]

^f t-test; [¥] Mann Whitney U test.

2.2 ARTICLE 2

Midpalatal suture bone repair after miniscrew-assisted rapid palatal expansion in adults

ABSTRACT

Introduction: Midpalatal suture (MPS) repair in growing patients after RPE has been previously reported. However, differences between young and adult patients for timing and pattern of MPS repair after rapid maxillary expansion are expected. The aim of this study was to evaluate the midpalatal suture repair pattern after miniscrew-assisted rapid palatal expansion (MARPE) in adult patients. **Methods:** The study included 21 patients (6 male, 15 female) successfully treated with MARPE with a mean initial age of 29.1 years of age (SD=8.0; range=20.1-45.1). MPS repair was evaluated using maxillary axial and coronal sections derived from CBCT exams taken 16 months after the expansion (SD=5.9). Objective and subjective assessments of MPS repair were performed. Objective assessments were performed measuring MPS bone density at anterior, median and posterior region of hard palate. Pre-expansion and post-retention bone density changes were evaluated using paired t tests ($p<0.05$). Midpalatal suture bone repair was scored 0 to 3 considering, respectively, the complete absence of bone repair in the MPS, the repair of less than 50% of the MPS, the repair of more than 50% of the MPS and the complete repair of the MPS. Intra and interexaminer reliability evaluation were assessed using Kappa coefficient. **Results:** The objective evaluation showed a significant higher bone density at the pre-expansion stage in all palatal regions. The reliability of the subjective method was adequate with intra and interexaminer agreements varying from 0.807 to 0.904. Scores 1, 2 and 3 were found in 19.05%, 38.09% and 42.86% of the sample, respectively. The most common region demonstrating absence of bone repair was the middle third. The anterior third of the midpalatal suture was repaired in all patients. **Conclusions:** A decreased bone density was observed after the retention period when compared to pre-expansion stage. Most adult patients demonstrated incomplete repair of the midpalatal suture 16 months after MARPE. However, adequate bone repair covering more than half of the hard palate extension was observed in 80.95% of the patients.

KEY WORDS: Palatal Expansion Technique, Skeletal Anchorage, Cone-Beam Computed Tomography.

INTRODUCTION

Midpalatal suture (MPS) split has proven to be an adequate method for treatment of maxillary constriction and moderate maxillary crowding.¹⁻³ Conventional rapid palatal expansion (RPE) has the increasing age as a limitation to achieve maxillary transverse separation. Recently, miniscrew-assisted rapid palatal expansion (MARPE) has widened the age limit for midpalatal suture split allowing treatment of maxillary constriction in mature patients.⁴

Immediate skeletal and dental effects of MARPE in adult patients have been previously studied. A pyramidal expansion pattern with more dental effects, similar to conventional rapid palatal expansion, was observed.⁵ Skeletal transverse dimensions at the level of the nasal cavity, maxillary basal bone and alveolar ridge increased significantly after MARPE.⁵⁻⁷ The skeletal effect corresponded to approximately 43.84% of the amount of screw activation.⁵ Molars, premolars and canines widths also increased significantly after expansion.⁵⁻⁷ Skeletal effects showed good stability in the long-term, with no significant relapse after orthodontic treatment.⁵⁻⁷ Dental effects decreased significantly after comprehensive orthodontic treatment, however, with no relapse of posterior crossbite.⁵⁻⁷ The question that rises is whether the midpalatal suture repair after MARPE in mature patients is similar to that observed in growing patients.

Midpalatal suture repair in growing patients after RPE has been previously reported.^{8,9} Melsen histologically evaluated MPS repair after RPE in children of 8 to 13 years of age.⁹ Evidence of inflammation with intense osteoblastic activity was reported after the first month of retention. After 5 to 6 months, bone islands along the suture were observed and after 1 year of retention a complete repaired suture was observed.⁹ Ekstrom radiographically evaluated the MPS repair in a 10-year-old boy treated with RPE, calculating the mineral mass per surface unit.⁸ After 3 months of retention the MPS showed well established mineralization, similar to the initial level.⁸ Tomographic evaluation performed in a sample of 17 children ranging from 5 to 10 years showed a completely ossified suture after 8 to 9 months of retention.¹⁰ A bone scintigraphy study evaluated bone activity in 1 pre-adolescent and 2 teenager patients after RPE.¹¹ Greater bone activity in the anterior and medial sections was observed during the first 3 months of retention. After this period, bone activity returned to the original level.¹¹ MPS repair after MARPE in adult patients was not previously described. Bone repair

has been related to initial age and amount of bone separation.¹² Previous studies with surgically assisted rapid palatal expansion (SARPE) in adults showed absence of complete sutural repair after 3 to 7 months of retention.¹³⁻¹⁵

Differences between young and adult patients for timing and pattern of MPS repair after rapid maxillary expansion are expected. Midpalatal suture repair after MARPE is important to be assessed in order to define an adequate protocol of post-expansion retention. Therefore, the objective of this study was to evaluate bone repair after midpalatal suture split with MARPE in adults and to propose a classification method of midpalatal suture repair.

MATERIALS AND METHODS

This retrospective study was approved by the institutional Research Ethics Committee of _____ . The sample included 24 consecutive patients treated with MARPE at a private practice by one orthodontist and two postgraduation programs.

The inclusion criteria were patients older than 20 years of age with unilateral or bilateral posterior crossbite, successful MARPE therapy with radiographic confirmation of midpalatal suture split, and cone-beam computed tomography (CBCT) taken at least 6 months after expansion, for bone repair assessment. The exclusion criteria were presence of craniofacial anomalies and syndromes. The final sample comprised 21 patients (6 male, 15 female) with a mean initial age of 29.1 years of age (SD= 8.0; range= 20.1 - 45.1).

All expansion procedures were performed using a prefabricated expander (_____) illustrated in Figure 1. The expander consisted of a Hyrax expander with four paramedian miniscrews of 1.8x7mm. The expander was positioned approximately in the middle third of the hard palate. The activation protocol initiated with two-quarter turns immediately after installation, followed by one-quarter turn (0.2mm) twice a day in the consecutive days. When an interincisal diastema was opened, the screw was activated one-quarter turn a day until reaching overcorrection of the crossbite. The active expansion phase was approximately 21 to 30 days with a mean screw activation of 7mm. The mean split at the level of the prosthion measured with a digital calypter in the occlusal radiograph was 4.66mm (SD=1.37). The expander

device was left as retention for 12 months. Fixed orthodontic appliance was installed approximately 6 months after the active expansion phase in all the patients.

CBCT exams were obtained before expansion (T1) and after a retention period of at least 6 months (T2) using a FOV of 6cm and a voxel size of 0.4mm. The average time from the end of active expansion to the T2 CBCT exam was 16.5 ± 5.9 months. T1 and T2-CBCT derived axial sections of the hard palate were obtained. Image position standardization was performed in the 3 planes of space (Fig. 2). In the frontal view, the plane passing through the lower limit of the nasal cavity was left parallel to the horizontal plane. In the sagittal plane, a plane passing through the A point to the middle of posterior nasal spine was oriented parallel to the horizontal plane. In the axial view, the midpalatal suture was positioned perpendicular to the horizontal plane.

Bone density was measured before the expansion and after the retention period on CBCT coronal sections passing by the anterior, median and posterior regions of the hard palate. The anterior margin of the incisive foramen was reference for the anterior coronal section. The interproximal contact between maxillary right second premolar and first molar was the reference for the median coronal slice. The distal aspect of maxillary right second molar was the reference for the posterior coronal slice. An area of 2x2mm was selected on the midpalatal suture at each coronal slice to determine the mean bone density using Hounsfield units (HU).

In the T2 axial section, the degree of midpalatal bone repair was subjectively evaluated based on the presence/absence of visual bone at the MPS and a score from 0 to 3 was assigned (Fig. 3). Score 0 represented complete absence of bone repair in the MPS. Score 1 represented bone repair of less than 50% of the hard palate sagittal length (Fig. 3A). Score 2 demonstrated bone repair of more than 50% of the midpalatal suture (Fig. 3B). Score 3 was observation of complete repair of the midpalatal suture from the anterior to the posterior limit of the hard palate (Fig. 3C). The pre- and post-retention axial images of all patients were organized in a presentation as shown in figure 3 (Microsoft Office PowerPoint 2019; Microsoft, Redmont, Wash).

In order to evaluate reliability of the new evaluation method, the assessment was performed twice by 3 orthodontists. The three raters had previous training using 6 subjects from all scores and disagreements were openly discussed. After the preliminary training, the axial images of the 21 patients were presented to the 3 examiners. After a 30-day interval, all the sample was scored again using a second presentation with different arrangement of the images.

Statistical Analysis

Paired t tests were used to evaluate T1-T2 changes in bone density at the midpalatal suture. Kappa coefficient was used to evaluate intra and interexaminer reliability of subjective assessments. Frequencies were used to describe the sample distribution among each bone repair score.

RESULTS

Objective evaluation showed a significant decrease in bone density from pre-expansion to post-retention phase (Table 1). A bone density decrease of 33%, 77% and 52% in the anterior, median and posterior regions, respectively, was observed after the retention period.

Intra and interexaminer reproducibility of subjective assessment showed substantial agreement, with kappa coefficients varying from 0.807 to 0.904 (Table 2).

Subjective assessment of midpalatal suture bone repair demonstrated that no patients had score 0 (Table 3). Score 1 was the less frequent with 19.05% of the sample. Scores 2 and 3 were found in 38.09% and 42.86% of the sample, respectively.

Considering the hard palate anteroposterior dimension, the most common region demonstrating absence of bone repair was the middle third (Table 4). The anterior third of the midpalatal suture was repaired in all patients.

DISCUSSION

This is the first study showing the degree and pattern of bone repair of the midpalatal suture after miniscrew-assisted rapid palatal expansion in adults. Previous studies that evaluated MPS repair in young patients after expansion showed complete repair after 9 to 12 months of retention.^{9,10} Even with the presence of cellular activity in the MPS, mature patients seem to present a lower degree of repair after RPE.¹¹ The sample size was based on previous studies evaluating MPS bone repair after SARPE.^{14,15}

The bone density at the midpalatal suture decreased after expansion (Table 1). These results are in accordance with previous studies that evaluated the MPS repair in adults after SARPE.^{14,15} A study that evaluated the bone density of 16 patients

treated with SARPE associated to bone-borne Dresden Distractor reported lower bone density values compared to preoperative levels.¹⁵ Our results showed that the greater decrease in bone density occurred in the middle region of the palate followed by the posterior and anterior regions (Table 1). Conversely, previous studies evaluating bone repair after SARPE observed a greater decrease in bone density at the anterior region of the palate.^{14,15} These differences might be related to the injuries caused by the use of chisel in the anterior region of the palate in SARPE. Another study evaluated MPS repair in a sample of 14 patients with a mean age of 25.3 years successfully treated with SARPE.¹⁴ The tomographic evaluation after 180 days of the expansion showed lower bone density than the initial values, suggesting that the retention period was not enough for bone mineralization in adults.¹⁴ The evaluation of the occlusal radiographs of 21 patients also showed absence of complete repair of the MPS after 120 days after SARPE.¹³

Despite the absence of complete repair in 57.14% of the sample in the subjective assessment, 80.95% of the patients presented bone repair covering more than half of the hard palate, 16 months after expansion (Table 3). The absence of complete repair of the MPS after expansion in adult patients is not unusual, and the results of this study are in accordance with previous studies¹³⁻¹⁸ suggesting a lower degree of regeneration when compared to younger patients.

The complete sample demonstrated bone repair in the anterior region of the hard palate. Seventeen out of 21 subjects presented the anterior and posterior third of the palate repaired (Table 4). On the other hand, the middle third of the hard palate was the most frequently unrepaired region, observed in 57.14% of the patients. These outcomes might be related to a greater vascular irrigation in the anterior and posterior regions of the hard palate.¹⁹ The middle region of the hard palate shows less vascular irrigation.¹⁹ Additionally, the fact that high forces of the expansion are located in the area surrounding the miniscrews²⁰ and that they are installed in the middle region of the palate could have negatively influenced bone repair at this area. These results are in accordance with a previous study with bone scintigraphy showing that the anterior region of the midpalatal suture often shows more bone activity after RPE.¹¹

The absence of complete MPS repair observed in this study suggests that retention should be carefully planned after MARPE in order to maintain the transversal outcomes in adult patients. A transpalatal arch of 0.8mm stainless-steel wire should be installed immediately after expander removal (Fig. 4).

Despite the limitations of studying a small sample with great initial age variance, the results of the present study provide preliminary information on MPS repair in adult patients after MARPE. Future studies should investigate the relationship of midpalatal suture repair and stability of the transverse results of MARPE

CONCLUSIONS

- A decreased bone density was observed after the retention period when compared to pre-expansion stage;
- Most adult patients demonstrated incomplete repair of the midpalatal suture 16 months after MARPE;
- Bone repair covering more than half of the hard palate extension was observed in 80.95% of the patients;
- The middle third of the hard palate was the most frequently unrepaired region. Conversely, the anterior region of the hard palate showed bone formation in all patients after MARPE;
- The proposed scale for assessment of midpalatal suture bone repair after MARPE demonstrated adequate reliability.

ACKNOWLEDGMENTS

This research was financed in part by the Coordenação de Aperfeiçoamento de Pessoal de Nível Superior – Brasil (CAPES) – Finance Code 001.

REFERENCES

1. Baccetti T, Franchi L, McNamara JA, Jr. Treatment and posttreatment craniofacial changes after rapid maxillary expansion and facemask therapy. *Am J Orthod Dentofacial Orthop* 2000;118:404-413.
 2. Bishara SE, Staley RN. Maxillary expansion: clinical implications. *Am J Orthod Dentofacial Orthop* 1987;91:3-14.
 3. Haas AJ. Rapid expansion of the maxillary dental arch and nasal cavity by opening the midpalatal suture. *Angle Orthod* 1961;31:73-90.
-
-

4. Lee KJ, Park YC, Park JY, Hwang WS. Miniscrew-assisted nonsurgical palatal expansion before orthognathic surgery for a patient with severe mandibular prognathism. *Am J Orthod Dentofacial Orthop* 2010;137:830-839.
5. Choi SH, Shi KK, Cha JY, Park YC, Lee KJ. Nonsurgical miniscrew-assisted rapid maxillary expansion results in acceptable stability in young adults. *Angle Orthod* 2016;86:713-720.
6. Lim HM, Park YC, Lee KJ, Kim KH, Choi YJ. Stability of dental, alveolar, and skeletal changes after miniscrew-assisted rapid palatal expansion. *Korean J Orthod* 2017;47:313-322.
7. Park JJ, Park YC, Lee KJ, Cha JY, Tahk JH, Choi YJ. Skeletal and dentoalveolar changes after miniscrew-assisted rapid palatal expansion in young adults: A cone-beam computed tomography study. *Korean J Orthod* 2017;47:77-86.
8. Ekstrom C, Henrikson CO, Jensen R. Mineralization in the midpalatal suture after orthodontic expansion. *Am J Orthod* 1977;71:449-455.
9. Melsen B. A histological study of the influence of sutural morphology and skeletal maturation on rapid palatal expansion in children. *Trans Eur Orthod Soc* 1972:499-507.
10. da Silva Filho OG, Lara TS, da Silva HC, Bertoz FA. Post expansion evaluation of the midpalatal suture in children submitted to rapid palatal expansion: a CT study. *J Clin Pediatr Dent* 2006;31:142-148.
11. Arat ZM, Gokalp H, Atasever T, Turkkahraman H. 99mTechnetium-labeled methylene diphosphonate uptake in maxillary bone during and after rapid maxillary expansion. *Angle Orthod* 2003;73:545-549.
12. Koczewski P, Shadi M. Factors influencing bone regenerate healing in distraction osteogenesis. *Ortop Traumatol Rehabil* 2013;15:591-599.
13. Malmström MFV, Gurgel JdA. Avaliação da neoformação óssea na sutura palatina mediana por meio de radiografia digitalizada após a expansão assistida cirurgicamente. *Revista Dental Press de Ortodontia e Ortopedia Facial* 2007;12:82-93.
14. Salgueiro DG, Rodrigues VH, Tieghi Neto V, Menezes CC, Goncales ES, Ferreira Junior O. Evaluation of opening pattern and bone neoformation at median palatal suture area in patients submitted to surgically assisted rapid maxillary expansion (SARME) through cone beam computed tomography. *J Appl Oral Sci* 2015;23:397-404.

15. Petrick S, Hothan T, Hietschold V, Schneider M, Harzer W, Tausche E. Bone density of the midpalatal suture 7 months after surgically assisted rapid palatal expansion in adults. *Am J Orthod Dentofacial Orthop* 2011;139:S109-116.
 16. Brin I, Hirshfeld Z, Shanfeld JL, Davidovitch Z. Rapid palatal expansion in cats: effect of age on sutural cyclic nucleotides. *Am J Orthod* 1981;79:162-175.
 17. Kanekawa M, Shimizu N. Age-related changes on bone regeneration in midpalatal suture during maxillary expansion in the rat. *Am J Orthod Dentofacial Orthop* 1998;114:646-653.
 18. Ten Cate AR, Freeman E, Dickinson JB. Sutural development: structure and its response to rapid expansion. *Am J Orthod* 1977;71:622-636.
 19. Kim DH, Won SY, Bae JH, Jung UW, Park DS, Kim HJ et al. Topography of the greater palatine artery and the palatal vault for various types of periodontal plastic surgery. *Clin Anat* 2014;27:578-584.
 20. Seong EH, Choi SH, Kim HJ, Yu HS, Park YC, Lee KJ. Evaluation of the effects of miniscrew incorporation in palatal expanders for young adults using finite element analysis. *Korean J Orthod* 2018;48:81-89.
-
-

FIGURE LEGENDS

Fig 1. Expander used for MARPE.

Fig 2. Standardization of image position.

Fig 3. Examples of scores 1 to 3 for midpalatal bone repair after MARPE. A. Score 1: incomplete bone repair in the midpalatal suture covering less than 50% of the hard palate; B. Score 2: incomplete bone formation in the midpalatal suture with more than 50% of the hard palate demonstrating bone repair; C. Score 3: complete repair of the midpalatal region extending from the anterior to the posterior region of the hard palate.

Fig 4. A transpalatal arch of 0.8mm stainless-steel wire installed immediately after expander removal.

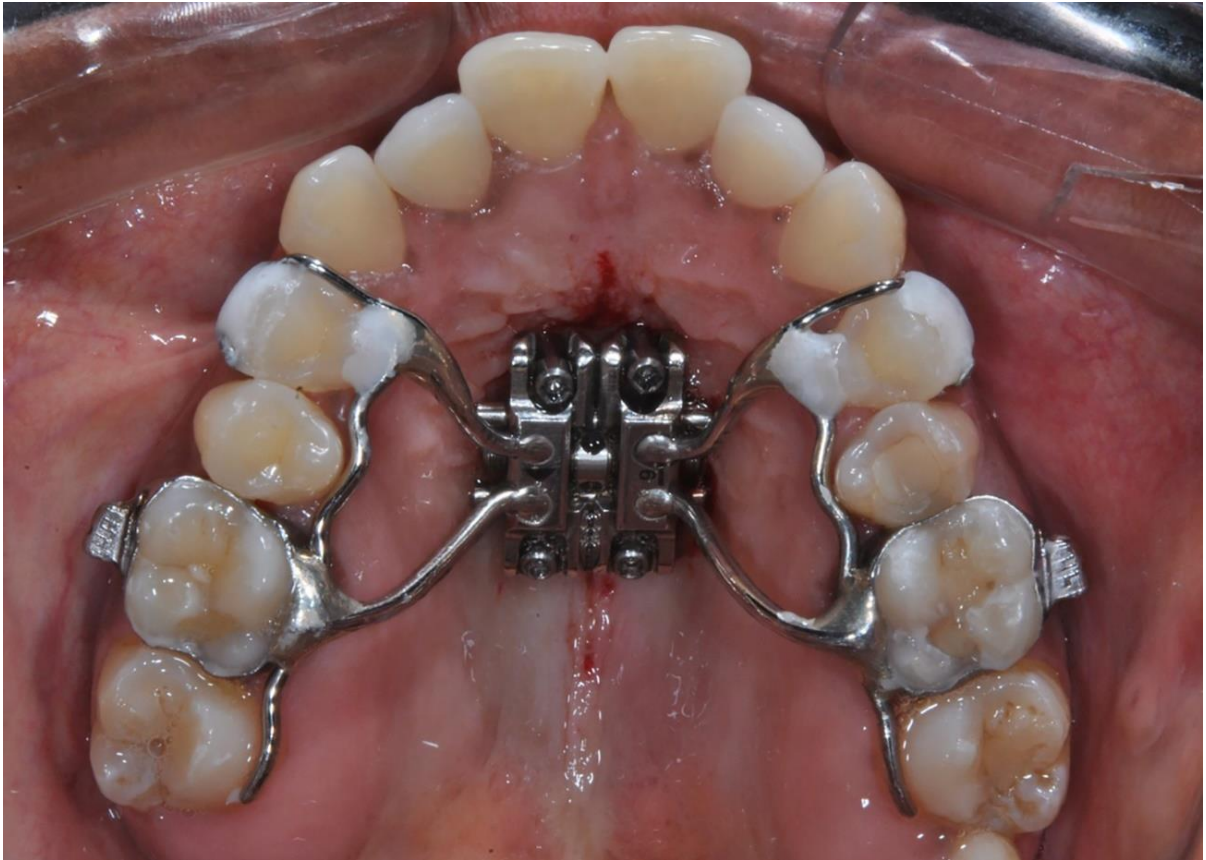

Fig 1.

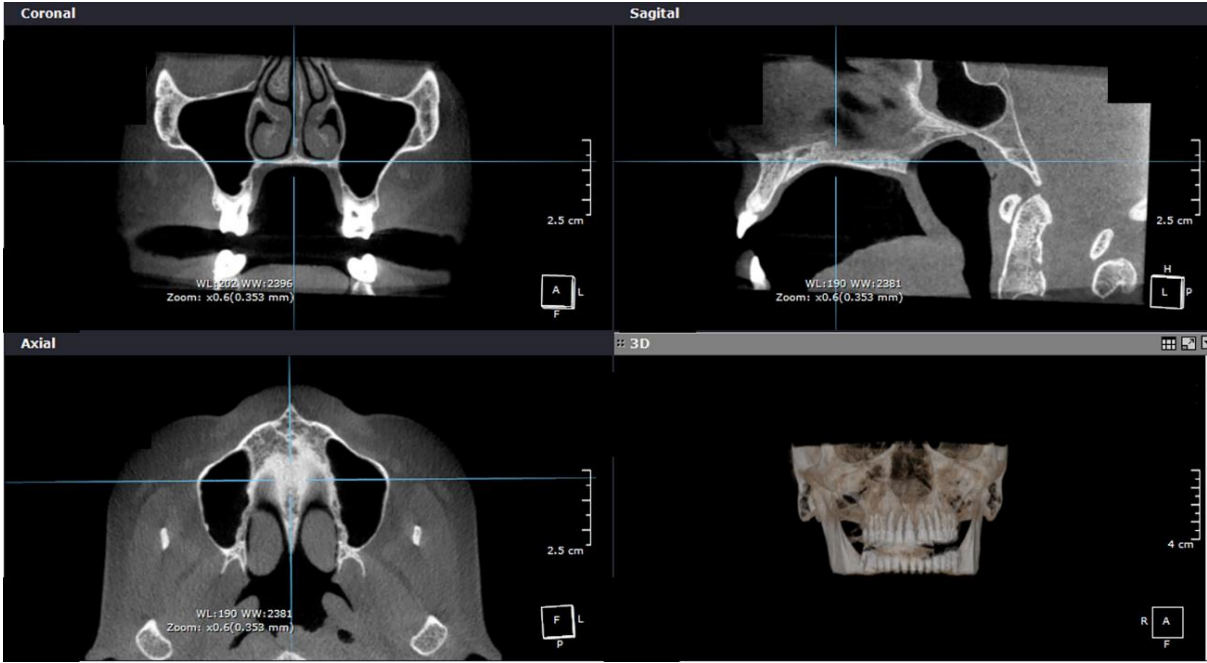


Fig 2.

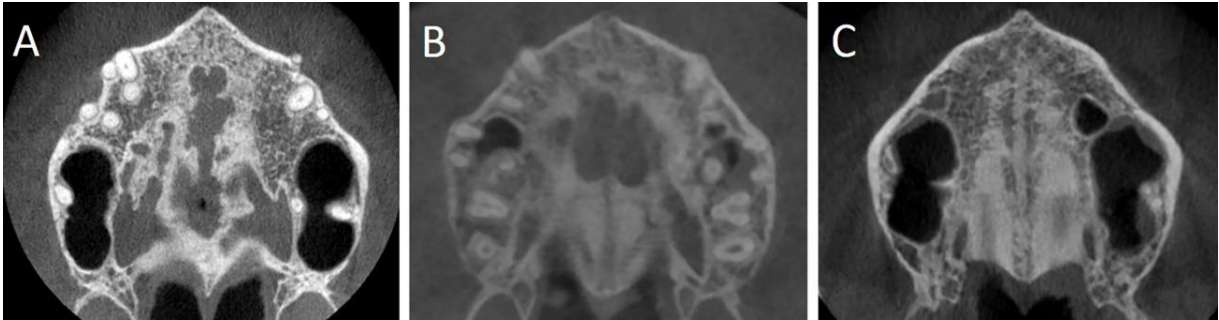


Fig 3.

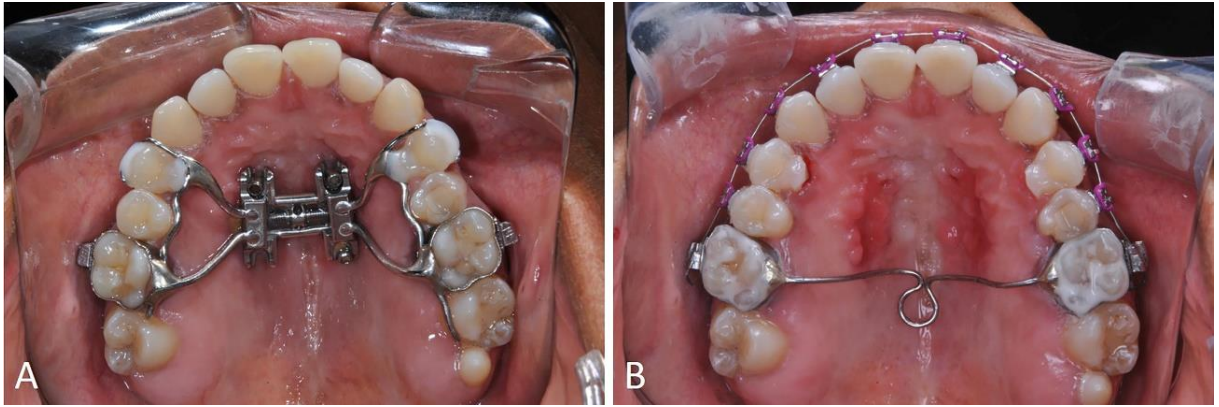


Fig 4.

Table I. Measurement of midpalatal suture bone density at T1 and T2.

Density (HU)	T1 (Pre-expansion)				T2 (Postexpansion)				T2-T1		P
	Mean	SD	Minimum	Maximum	Mean	SD	Minimum	Maximum	Absolute	Relative	
Anterior	841.22	320.94	353,42	1543,19	556.87	308.75	-13,50	1247,93	-284,35	-33.80%	0.005*
Median	759,34	242,88	422,76	1287,42	172,38	229,48	-119,17	678,40	-586,96	-77.29%	<0.001*
Posterior	751,95	330,82	212,30	1511,37	359,93	424,07	-319,96	1061,75	-392,01	-52.13%	0.008*

*Statistically significant at $p < 0.05$.

Table II. Regeneration stage intra and interexaminer reproducibility.

Intraexaminer error		Interexaminer error	
Examiners	Kappa Coefficient	Examiners	Kappa Coefficient
1-1	0.813	1-2	0.904
2-2	0.807	1-3	0.904
3-3	0.811	2-3	0.811

Table III. Distribution of the regeneration stages, initial age, and time of retention.

	Stage 1	Stage 2	Stage 3
# (%)	4 (19.05%)	8 (38.09%)	9 (42.86%)
Initial age (SD)	24.5 (5.0)	34.6 (7.1)	26.1 (7.4)
Retention time (SD)	17.7 (6.2)	18.4 (4.7)	14.2 (6.5)

Table IV. Distribution of the regenerated areas of the midpalatal suture.

Palatal region	Anterior	Medium	Posterior
Frequency of bone repair	21 (100%)	9 (42.86%)	17 (80.85%)

3 DISCUSSION

3 DISCUSSION

Miniscrew assisted rapid palatal expansion (MARPE) has proven to be an excellent option to treat maxillary transversal deficiency in adult patients. However, age limit and midpalatal suture (MPS) repair are still in debate. Most articles have focused on young adult patients,^{28,30} however, case reports have shown successful skeletal expansion in older patients.^{41,42} Also, no previous study have evaluated the MPS repair after MARPE.

The transversal effects of MARPE as well as the repair of the MPS after skeletal expansion are usually evaluated using cone-beam computed tomography (CBCT).^{30,31,39,40} Good intra and interexaminer reliability has been reported with these methods.^{30,31,39,40,43}

Transversal effects of MARPE in young adults with a mean age varying between 20 and 23 years have been previously studied. Significant increase of skeletal and dental transversal dimensions was reported. A pyramidal expansion pattern with more dental effects, similar to conventional rapid palatal expansion, was observed.²⁸ Skeletal transverse dimensions at the level of the nasal cavity, maxillary basal bone and maxillary alveolar bone increased significantly after MARPE.^{28,30,34} The present study compared patients aged 18-29 versus patients aged 30-45 years, and no significant differences for the skeletal and dental changes after MARPE was observed. Skeletal width increase in this study was similar to those observed after MARPE in young patients, and greater than young patients treated with conventional RPE.⁴³ These results suggest that MARPE could be used in older patients, with good skeletal effects. Also, the use of miniscrews allows the application of expansion transversal forces to higher maxillary levels, increasing the skeletal effects. The difference between posterior and anterior effects was also evaluated. A greater anterior expansion was observed for all the variables, which could be explained by the anterior position of the expander. This expansion characteristic was similar to the pattern observed in young patients after conventional RPE.

Periodontal effects, mainly at the anchorage teeth, are also expected after MARPE. Decrease of buccal alveolar bone thickness and increased palatal alveolar bone thickness of anchorage teeth have been reported.³⁰ In the present study, these effects were observed in the maxillary first molar and premolar. However, with no significant differences between both groups. The similarities for skeletal, dental, and periodontal changes of both study groups could be related to the fact that all the patients presented a complete bone maturation at the beginning of treatment.

MPS repair is expected in young patients. Previous studies that evaluated MPS repair in young patients after expansion showed complete repair after 9 to 12 months of retention.^{36,37} MPS repair evaluation after surgically assisted rapid palatal expansion (SARPE) showed no complete repair after a retention period between 3 and 7 months.³⁸⁻⁴⁰ This is the first study that assessed the pattern and amount of MPS repair of adult patients after MARPE.

It was observed that MPS density decreased after the expansion, similar to previous studies.³⁸⁻⁴⁰ Despite the absence of complete repair in most of the sample in the subjective assessment, 80.95% of the patients presented bone repair covering more than half of the hard palate, 16 months after expansion. The absence of complete repair of the MPS after expansion in adult patients is not unusual, and the results of this study are in accordance with previous studies.³⁸⁻⁴⁰ The anterior region was repaired in all the patients, while the middle third was the most frequently unrepaired region. These outcomes might be related to a greater vascular irrigation in the anterior and posterior regions of the hard palate. The middle region of the hard palate shows less vascular irrigation.⁴⁴ Additionally, the fact that high forces of the expansion are located in the area surrounding the miniscrews and that they are installed in the middle region of the palate could have negatively influenced bone repair at this area.³² This result suggests that retention should be carefully planned after MARPE in order to maintain the transversal outcomes in adult patients.

4 FINAL CONSIDERATIONS

4 FINAL CONSIDERATIONS

A success rate of midpalatal suture opening of 100% and 81% was observed for young and middle adults, respectively.

After MARPE, middle adults showed similar dentoskeletal and periodontal changes compared to young adults.

A decreased bone density was observed after the retention period when compared to pre-expansion stage, with most percentage of the sample demonstrating incomplete repair of the midpalatal suture 16 months after MARPE;

Bone repair covering more than half of the hard palate extension was observed in 80.95% of the patients. The middle third of the hard palate was the most frequently unrepaired region. Conversely, the anterior region of the hard palate showed bone formation in all patients after MARPE;

REFERENCES

REFERENCES

1. Bishara SE, Staley RN. Maxillary expansion: clinical implications. *Am J Orthod Dentofacial Orthop* 1987;91:3-14.
 2. da Silva Filho OG, Magro AC, Capelozza Filho L. Early treatment of the Class III malocclusion with rapid maxillary expansion and maxillary protraction. *Am J Orthod Dentofacial Orthop* 1998;113:196-203.
 3. Haas AJ. Rapid expansion of the maxillary dental arch and nasal cavity by opening the midpalatal suture. *The Angle Orthodontist* 1961;31:73-90.
 4. McNamara JA. Maxillary transverse deficiency. *Am J Orthod Dentofacial Orthop* 2000;117:567-570.
 5. Angell E. Treatment of irregularities of the permanent or adult teeth. *Dent. Cosmos* 1860;1:599-600.
 6. Adkins MD, Nanda RS, Currier GF. Arch perimeter changes on rapid palatal expansion. *Am J Orthod Dentofacial Orthop* 1990;97:194-199.
 7. Ballanti F, Lione R, Fanucci E, Franchi L, Baccetti T, Cozza P. Immediate and post-retention effects of rapid maxillary expansion investigated by computed tomography in growing patients. *Angle Orthod* 2009;79:24-29.
 8. Janson G, Maria FR, Bombonatti R. Frequency evaluation of different extraction protocols in orthodontic treatment during 35 years. *Prog Orthod* 2014;15:51.
 9. Baccetti T, Franchi L, Cameron CG, McNamara JA, Jr. Treatment timing for rapid maxillary expansion. *Angle Orthod* 2001;71:343-350.
 10. Seif-Eldin NF, Elkordy SA, Fayed MS, Elbeialy AR, Eid FH. Transverse Skeletal Effects of Rapid Maxillary Expansion in Pre and Post Pubertal Subjects: A Systematic Review. *Open Access Maced J Med Sci* 2019;7:467-477.
 11. Wang L. [Comparative research on forms of dental and palatal arches between adults and children after rapid maxillary expansion]. *Hua Xi Kou Qiang Yi Xue Za Zhi* 2000;18:397-400.
-

12. Krebs A. Midpalatal Suture Expansion Studies by the Implant Method over a Seven-Year Period. *Rep Congr Eur Orthod Soc* 1964;40:131-142.
 13. Capelozza Filho L, Cardoso Neto J, da Silva Filho OG, Ursi WJ. Non-surgically assisted rapid maxillary expansion in adults. *Int J Adult Orthodon Orthognath Surg* 1996;11:57-66; discussion 67-70.
 14. Carlson C, Sung J, McComb RW, Machado AW, Moon W. Microimplant-assisted rapid palatal expansion appliance to orthopedically correct transverse maxillary deficiency in an adult. *Am J Orthod Dentofacial Orthop* 2016;149:716-728.
 15. Brunetto DP, Sant'Anna EF, Machado AW, Moon W. Non-surgical treatment of transverse deficiency in adults using Microimplant-assisted Rapid Palatal Expansion (MARPE). *Dental Press J Orthod* 2017;22:110-125.
 16. Kraut RA. Surgically assisted rapid maxillary expansion by opening the midpalatal suture. *J Oral Maxillofac Surg* 1984;42:651-655.
 17. Wertz RA. Skeletal and dental changes accompanying rapid midpalatal suture opening. *Am J Orthod* 1970;58:41-66.
 18. Pogrel MA, Kaban LB, Vargervik K, Baumrind S. Surgically assisted rapid maxillary expansion in adults. *Int J Adult Orthodon Orthognath Surg* 1992;7:37-41.
 19. Pereira MD, Koga AF, Prado GPR, Ferreira LM. Complications From Surgically Assisted Rapid Maxillary Expansion With HAAS and HYRAX Expanders. *J Craniofac Surg* 2018;29:275-278.
 20. Sendyk M, Sendyk WR, Pallos D, Boaro LCC, Paiva JB, Rino Neto J. Periodontal clinical evaluation before and after surgically assisted rapid maxillary expansion. *Dental Press J Orthod* 2018;23:79-86.
 21. de Gijt JP, Gul A, Tjoa ST, Wolvius EB, van der Wal KG, Koudstaal MJ. Follow up of surgically-assisted rapid maxillary expansion after 6.5 years: skeletal and dental effects. *Br J Oral Maxillofac Surg* 2017;55:56-60.
 22. Siqueira DF, Cardoso Mde A, Capelozza Filho L, Goldenberg DC, Fernandes Mdos S. Periodontal and dental effects of surgically assisted rapid maxillary expansion, assessed by using digital study models. *Dental Press J Orthod* 2015;20:58-63.
-
-

23. Harzer W, Schneider M, Gedrange T. Rapid maxillary expansion with palatal anchorage of the hyrax expansion screw--pilot study with case presentation. *J Orofac Orthop* 2004;65:419-424.
 24. Koudstaal MJ, van der Wal KG, Wolvius EB, Schulten AJ. The Rotterdam Palatal Distractor: introduction of the new bone-borne device and report of the pilot study. *Int J Oral Maxillofac Surg* 2006;35:31-35.
 25. Mommaerts MY. Transpalatal distraction as a method of maxillary expansion. *Br J Oral Maxillofac Surg* 1999;37:268-272.
 26. Garib DG, Navarro R, Francischone CE, Oltramari PV. Rapid maxillary expansion using palatal implants. *J Clin Orthod* 2008;42:665-671.
 27. Lee KJ, Park YC, Park JY, Hwang WS. Miniscrew-assisted nonsurgical palatal expansion before orthognathic surgery for a patient with severe mandibular prognathism. *Am J Orthod Dentofacial Orthop* 2010;137:830-839.
 28. Choi SH, Shi KK, Cha JY, Park YC, Lee KJ. Nonsurgical miniscrew-assisted rapid maxillary expansion results in acceptable stability in young adults. *Angle Orthod* 2016;86:713-720.
 29. Cunha ACD, Lee H, Nojima LI, Nojima M, Lee KJ. Miniscrew-assisted rapid palatal expansion for managing arch perimeter in an adult patient. *Dental Press J Orthod* 2017;22:97-108.
 30. Lim HM, Park YC, Lee KJ, Kim KH, Choi YJ. Stability of dental, alveolar, and skeletal changes after miniscrew-assisted rapid palatal expansion. *Korean J Orthod* 2017;47:313-322.
 31. Lin L, Ahn HW, Kim SJ, Moon SC, Kim SH, Nelson G. Tooth-borne vs bone-borne rapid maxillary expanders in late adolescence. *Angle Orthod* 2015;85:253-262.
 32. Seong EH, Choi SH, Kim HJ, Yu HS, Park YC, Lee KJ. Evaluation of the effects of miniscrew incorporation in palatal expanders for young adults using finite element analysis. *Korean J Orthod* 2018;48:81-89.
 33. Suzuki H, Moon W, Previdente LH, Suzuki SS, Garcez AS, Consolaro A. Miniscrew-assisted rapid palatal expander (MARPE): the quest for pure orthopedic movement. *Dental Press J Orthod* 2016;21:17-23.
-

34. Park JJ, Park YC, Lee KJ, Cha JY, Tahk JH, Choi YJ. Skeletal and dentoalveolar changes after miniscrew-assisted rapid palatal expansion in young adults: A cone-beam computed tomography study. *Korean J Orthod* 2017;47:77-86.
 35. Ekstrom C, Henrikson CO, Jensen R. Mineralization in the midpalatal suture after orthodontic expansion. *Am J Orthod* 1977;71:449-455.
 36. Melsen B. A histological study of the influence of sutural morphology and skeletal maturation on rapid palatal expansion in children. *Trans Eur Orthod Soc* 1972:499-507.
 37. da Silva Filho OG, Lara TS, da Silva HC, Bertoz FA. Post expansion evaluation of the midpalatal suture in children submitted to rapid palatal expansion: a CT study. *J Clin Pediatr Dent* 2006;31:142-148.
 38. Malmström MFV, Gurgel JdA. Avaliação da neoformação óssea na sutura palatina mediana por meio de radiografia digitalizada após a expansão assistida cirurgicamente. *Revista Dental Press de Ortodontia e Ortopedia Facial* 2007;12:82-93.
 39. Petrick S, Hothan T, Hietschold V, Schneider M, Harzer W, Tausche E. Bone density of the midpalatal suture 7 months after surgically assisted rapid palatal expansion in adults. *Am J Orthod Dentofacial Orthop* 2011;139:S109-116.
 40. Salgueiro DG, Rodrigues VH, Tieghi Neto V, Menezes CC, Goncales ES, Ferreira Junior O. Evaluation of opening pattern and bone neoformation at median palatal suture area in patients submitted to surgically assisted rapid maxillary expansion (SARME) through cone beam computed tomography. *J Appl Oral Sci* 2015;23:397-404.
 41. Kim H, Park SH, Park JH, Lee KJ. Nonsurgical maxillary expansion in a 60-year-old patient with gingival recession and crowding. *Korean J Orthod* 2021;51:217-227.
 42. Suzuki SS, Braga LFS, Fujii DN, Moon W, Suzuki H. Corticopuncture Facilitated Microimplant-Assisted Rapid Palatal Expansion. *Case Rep Dent* 2018;2018:1392895.
 43. Garib D, Miranda F, Palomo JM, Pugliese F, da Cunha Bastos JC, Dos Santos AM et al. Orthopedic outcomes of hybrid and conventional Hyrax expanders. *Angle Orthod* 2021;91:178-186.
-
-

44. Kim DH, Won SY, Bae JH, Jung UW, Park DS, Kim HJ et al. Topography of the greater palatine artery and the palatal vault for various types of periodontal plastic surgery. *Clin Anat* 2014;27:578-584.

APPENDIX

**APPENDIX A - DECLARATION OF EXCLUSIVE USE OF THE ARTICLE IN
DISSERTATION/THESIS**

We hereby declare that we are aware of the article “Immediate dentoskeletal and periodontal effects of miniscrew assisted rapid palatal expansion: comparison between young vs middle adults” will be included in Thesis of the student Rodrigo Andrés Naveda Araque and may not be used in other works of Graduate Programs at the Bauru School of Dentistry, University of São Paulo.

Bauru, February 25th, 2022.

Rodrigo Andrés Naveda Araque
Author



Signature

Daniela Gamba Garib Carreira
Author



Signature

Author

Signature

Author

Signature

**APPENDIX B - DECLARATION OF EXCLUSIVE USE OF THE ARTICLE IN
DISSERTATION/THESIS**

We hereby declare that we are aware of the article "Midpalatal suture bone repair after miniscrew-assisted rapid palatal expansion in adults" will be included in Thesis of the student Rodrigo Andrés Naveda Araque and may not be used in other works of Graduate Programs at the Bauru School of Dentistry, University of São Paulo.

Bauru, February 25th, 2022.

Rodrigo Andrés Naveda Araque
Author



Signature

Daniela Gamba Garib Carreira
Author



Signature

Author

Signature

Author

Signature

ANNEXES

ANNEX A. Ethics Committee approval, protocol number 3.739.978 (front).

USP - FACULDADE DE
ODONTOLOGIA DE BAURU DA
USP

**PARECER CONSUBSTANCIADO DO CEP****DADOS DO PROJETO DE PESQUISA**

Título da Pesquisa: Expansão maxilar ancorada em mini-implantes: Influência da idade e da maturidade óssea nos resultados dentoalveolares e periodontais

Pesquisador: Rodrigo Andrés Naveda Araque

Área Temática:

Versão: 2

CAAE: 22084619.5.0000.5417

Instituição Proponente: Universidade de Sao Paulo

Patrocinador Principal: Financiamento Próprio

DADOS DO PARECER

Número do Parecer: 3.739.978

Apresentação do Projeto:

Trata-se de um estudo clínico prospectivo no qual serão analisadas variáveis quantitativas e qualitativas de pacientes adultos, que serão os participantes da pesquisa, submetidos à expansão rápida da maxila para avaliar as alterações dentárias, esqueléticas e periodontais produzidas pela expansão maxilar osseosuportada. Também serão comparados os efeitos dentoalveolares do procedimento de acordo com a idade cronológica e grau de maturação da sutura palatina mediana. Serão convidados 36 participantes, de ambos os sexos, com idades variando de 18 a 40 anos, com atresia do arco dentário superior acompanhado ou não de mordida cruzada posterior. Estes serão divididos em 3 subgrupos de acordo com faixas etárias de 18-24 anos, 25-30 anos e 31-40 anos, tratados com o expansor maxilar MARPE ancorado por quatro mini implantes para-suturais. Antes da expansão (T0) e logo após a fase ativa da expansão (T1), serão feitos modelos dentários e exames de tomografias computadorizadas cone-beam (TCCB). As alterações interfases (T1-T0) serão avaliadas pelo teste t pareado e as comparações das alterações dentoalveolares serão realizadas pela análise de ANOVA e teste de Tukey. Será adotado um nível de significância de 5%.

Objetivo da Pesquisa:

Avaliar, em pacientes adultos, as alterações dentárias, esqueléticas e periodontais produzidas pela expansão maxilar ósseo-suportada e comparar os efeitos dentoalveolares do procedimento de acordo com a idade cronológica e grau de maturação da sutura palatina mediana.

Endereço: DOUTOR OCTAVIO PINHEIRO BRISOLLA 75 QUADRA 9
Bairro: VILA NOVA CIDADE UNIVERSITARIA **CEP:** 17.012-901
UF: SP **Município:** BAURU
Telefone: (14)3235-8356 **Fax:** (14)3235-8356 **E-mail:** cep@fob.usp.br

ANNEX A. Ethics Committee approval, protocol number 3.739.978 (verso).

USP - FACULDADE DE
ODONTOLOGIA DE BAURU DA
USP



Continuação do Parecer: 3.739.978

Avaliação dos Riscos e Benefícios:

Os riscos e benefícios foram incluídos na Plataforma Brasil, segundo o projeto de pesquisa:

Riscos:

"Após a instalação do aparelho, o participante poderá sentir algum tipo de desconforto, porém suportável, na região do palato ou na língua. Essa sensação é normal pois o aparelho será instalado no palato com a assistência de 4 mini-parafusos. Devido a posição do aparelho a língua poderá apresentar algum tipo de desconforto. Adicionalmente, o participante poderá ou não relatar desconforto durante a mastigação durante a primeira semana de uso do aparelho que irá diminuindo a partir da segunda semana de tratamento. É importante que as orientações em relação à alimentação sejam levadas em consideração para diminuir dito desconforto. É importante saber que pacientes com maxilar superior muito maduro apresentam a possibilidade de não responder corretamente ao tratamento. Nesses casos é necessária a remoção do aparelho expansor e dos miniparafusos localizados no céu da boca e serão substituídos por aparelhos ortodônticos convencionais. Todos os cuidados e procedimentos serão realizados pelo pesquisador responsável para evitar que os possíveis riscos descritos acima aconteçam."

Benefícios:

"Os benefícios para os participantes serão a gratuidade do planejamento ortodôntico, do tratamento das suas más oclusões (posicionamento incorreto dos dentes), do acompanhamento clínico, e, caso apresentem a necessidade de algum outro tratamento bucal, serão encaminhados para o sistema de Triagem da Faculdade de Odontologia de Bauru para serem posteriormente encaminhados a outros Departamentos. Os resultados dessa pesquisa elucidarão a idade máxima para realizar a expansão rápida da maxila sem a necessidade de procedimentos cirúrgicos."

Comentários e Considerações sobre a Pesquisa:

Será um estudo clínico prospectivo a partir de tratamento ortodôntico com aparelho expansor preso diretamente ao osso do céu da boca por um parafuso chamado mini implante. Está embasado na literatura e os autores demonstram bastante conhecimento técnico a respeito. Caso esta técnica não seja satisfatória, os autores garantem o tratamento convencional para o participante da pesquisa.

Considerações sobre os Termos de apresentação obrigatória:

As recomendações feitas por este CEP foram acatadas na íntegra:

Endereço: DOUTOR OCTAVIO PINHEIRO BRISOLLA 75 QUADRA 9
Bairro: VILA NOVA CIDADE UNIVERSITARIA **CEP:** 17.012-901
UF: SP **Município:** BAURU
Telefone: (14)3235-8356 **Fax:** (14)3235-8356 **E-mail:** cep@fob.usp.br

ANNEX A. Ethics Committee approval, protocol number 3.739.978 (verso).

USP - FACULDADE DE
ODONTOLOGIA DE BAURU DA
USP



Continuação do Parecer: 3.739.978

- 1- O TCLE foi corrigida de acordo com a Resolução 466/2012.
- 2- O item Riscos e Benefícios, em Informações Básicas do Projeto - Plataforma Brasil, foram descritos (conforme o TCLE), incluindo os benefícios aos participantes da pesquisa e não somente os benefícios científicos.
- 3- os cronogramas apresentados foram uniformizados, contendo os mesmos itens e com datas coerentes com a ordem dos procedimentos e o calendário proposto.
- 4- O orçamento contemplou as despesas previstas, incluindo auxílio para o transporte dos participantes até o local nos dias de atendimento para a realização da pesquisa e demais despesas que couberem.

Desta forma, consideramos que os termos de apresentação obrigatória estão de acordo.

Recomendações:

Não há.

Conclusões ou Pendências e Lista de Inadequações:

Aprovado.

Considerações Finais a critério do CEP:

Esse projeto foi considerado APROVADO na reunião ordinária do CEP de 11/12/2019, com base nas normas éticas da Resolução CNS 466/12. Ao término da pesquisa o CEP-FOB/USP exige a apresentação de relatório final. Os relatórios parciais deverão estar de acordo com o cronograma e/ou parecer emitido pelo CEP. Alterações na metodologia, título, inclusão ou exclusão de autores, cronograma e quaisquer outras mudanças que sejam significativas deverão ser previamente comunicadas a este CEP sob risco de não aprovação do relatório final. Quando da apresentação deste, deverão ser incluídos todos os TCLEs e/ou termos de doação assinados e rubricados, se pertinentes.

Este parecer foi elaborado baseado nos documentos abaixo relacionados:

Tipo Documento	Arquivo	Postagem	Autor	Situação
Informações Básicas do Projeto	PB_INFORMAÇÕES_BÁSICAS_DO_PROJETO_1415901.pdf	17/11/2019 23:01:01		Aceito
Outros	Oficio.pdf	17/11/2019 23:00:10	Rodrigo Andrés Naveda Araque	Aceito

Endereço: DOUTOR OCTAVIO PINHEIRO BRISOLLA 75 QUADRA 9
Bairro: VILA NOVA CIDADE UNIVERSITARIA **CEP:** 17.012-901
UF: SP **Município:** BAURU
Telefone: (14)3235-8356 **Fax:** (14)3235-8356 **E-mail:** cep@fob.usp.br

ANNEX A. Ethics Committee approval, protocol number 3.739.978 (verso).

USP - FACULDADE DE
ODONTOLOGIA DE BAURU DA
USP



Continuação do Parecer: 3.739.978

Projeto Detalhado / Brochura Investigador	Projeto_de_pesquisa.pdf	17/11/2019 22:59:53	Rodrigo Andrés Naveda Araque	Aceito
TCLE / Termos de Assentimento / Justificativa de Ausência	TCLE.pdf	17/11/2019 22:59:12	Rodrigo Andrés Naveda Araque	Aceito
Cronograma	Cronograma_de_Atividades.pdf	17/11/2019 22:58:02	Rodrigo Andrés Naveda Araque	Aceito
Orçamento	Orcamento.pdf	17/11/2019 22:57:25	Rodrigo Andrés Naveda Araque	Aceito
Declaração de Pesquisadores	Declaracao_de_compromisso.pdf	19/09/2019 14:32:41	Rodrigo Andrés Naveda Araque	Aceito
Outros	Check_List_CEP.pdf	19/09/2019 13:44:09	Rodrigo Andrés Naveda Araque	Aceito
Outros	Carta_de_encaminhamento.pdf	19/09/2019 12:10:02	Rodrigo Andrés Naveda Araque	Aceito
Folha de Rosto	Folha_de_rostro.pdf	18/09/2019 21:46:10	Rodrigo Andrés Naveda Araque	Aceito

Situação do Parecer:

Aprovado

Necessita Apreciação da CONEP:

Não

BAURU, 13 de Dezembro de 2019

Assinado por:

Ana Lúcia Pompéia Fraga de Almeida
(Coordenador(a))

Endereço: DOUTOR OCTAVIO PINHEIRO BRISOLLA 75 QUADRA 9
Bairro: VILA NOVA CIDADE UNIVERSITARIA **CEP:** 17.012-901
UF: SP **Município:** BAURU
Telefone: (14)3235-8356 **Fax:** (14)3235-8356 **E-mail:** cep@fob.usp.br

ANNEX B – Informed consent (front)

Página 1 de 2



Universidade de São Paulo
Faculdade de Odontologia de Bauru

Departamento de Odontopediatria, Ortodontia e
Saúde Coletiva

Termo de Consentimento Livre e Esclarecido

Você está sendo convidado a participar como voluntário da pesquisa intitulada “**Expansão maxilar ancorada em mini-implantes: Influência da idade e da maturidade óssea nos resultados dentoalveolares e periodontais**”. Essa pesquisa científica será realizada por Rodrigo Andrés Naveda Araque, Doutorando em Ortodontia na Faculdade de Odontologia de Bauru da Universidade de São Paulo, sob orientação da Profa. Dra. Daniela Garib e terá como objetivo avaliar, em pacientes adultos, as alterações dentária e do maxilar superior produzidas por um aparelho expansor que prende-se diretamente ao osso do céu da boca por meio de um parafuso chamado mini-implante. O aparelho tem a função de corrigir o estreitamento do maxilar superior. Correta higiene bucal e cuidados com alimentos duros serão importantes para a manutenção da saúde bucal e do aparelho em boas condições. Você será orientado durante todo o tratamento sobre os cuidados necessários e sobre eventuais questionamentos.

Serão realizadas a documentação (registro) ao início e após a fase ativa da expansão, que consistirão em: três fotografias extrabucais (frente, lateral, e do sorriso), cinco fotografias intrabucais (frontal, lateral direita, lateral esquerda, oclusal superior e oclusal inferior), e tomografia computadorizada de Feixe Cônico (TCFC). Por fim, durante todo o acompanhamento da terapia serão realizadas também algumas fotografias intrabucais (frontal, lateral direita, lateral esquerda, oclusal superior e oclusal inferior) e extrabucais (frente, lateral, e do sorriso), para complementar a avaliação acima descrita. As documentações são necessárias para avaliar os efeitos do tratamento. As tomadas tomográficas são procedimentos necessários para a realização de um correto planejamento e para a avaliação dos efeitos dentoalveolares e periodontais produzidos. As TCFC serão realizadas respeitando todas as medidas de segurança com a mínima exposição necessária aos raios-x.

A fase em que damos corda no aparelho dura 1 mês, e o tempo que ele permanece na boca para estabilização será de mais 6 meses, dando um total de 7 meses de tratamento. Todos os procedimentos clínicos serão realizados pelo próprio pesquisador responsável, na clínica de Ortodontia da Faculdade de Odontologia de Bauru, Universidade de São Paulo. Ao participar desta pesquisa, você apresentará como benefícios a gratuidade do planejamento ortodôntico, do tratamento das suas más oclusões (posicionamento incorreto dos dentes), do acompanhamento clínico, e, caso apresentem a necessidade de algum outro tratamento bucal, serão encaminhados para o sistema de Triagem da Faculdade de Odontologia de Bauru para serem posteriormente encaminhados a outros Departamentos. Se houver suspeita de qualquer alteração médica ou psicológica, você será orientado a buscar tratamento e acompanhamento adequado. Ao final do estudo, os participantes terão garantido o acompanhamento e/ou tratamento ortodôntico complementar (se necessário) e estarão dispostos aos melhores métodos preventivos, diagnósticos e terapêuticos que se demonstrarem eficazes, por parte da Instituição patrocinadora. Não será oferecida remuneração, auxílio para alimentação ou transporte até o local nos dias de atendimento. É garantida a indenização em casos de danos que ocorram decorrentes dos procedimentos empregados nesta pesquisa.

Fotografias são procedimentos rápidos e fazem parte da rotina odontológica. Se acontecer algum tipo de desconforto, o profissional saberá como aliviar-o imediatamente.

Após a instalação do aparelho, você pode sentir algum tipo de desconforto, porém suportável, na região do palato ou na língua. Essa sensação é normal pois o aparelho será instalado no palato com a assistência de 4 mini-parafusos. Devido a posição do aparelho a língua pode poderá apresentar algum tipo de desconforto. Adicionalmente, você poderá ou não relatar desconforto durante a mastigação durante a primeira semana de uso do aparelho que irá diminuindo a partir da segunda semana de tratamento. É importante que as orientações em relação à alimentação sejam levadas em consideração para diminuir dito desconforto. É importante saber que pacientes com maxilar superior muito maduro apresentam a possibilidade de não responder corretamente ao tratamento. Nesses casos é necessária a remoção do aparelho expansor e dos mini-parafusos localizados no céu da boca e serão substituídos por aparelhos ortodônticos convencionais. Todos os cuidados e procedimentos serão realizados pelo pesquisador responsável para evitar que os possíveis riscos descritos acima aconteçam.

É importante que você saiba que a sua privacidade será respeitada. Ou seja, seu nome ou qualquer outro dado que possa, de qualquer forma, identificá-los, será mantido em sigilo.

O pesquisador envolvido com a referida pesquisa é **Rodrigo Andrés Naveda Araque** e com ele você poderá manter contato via e-mail (rodrigonaveda8@gmail.com) ou telefone (14) 996923838.

É assegurado o esclarecimento de dúvidas durante toda a pesquisa, bem como será garantido o livre acesso a todas as informações e esclarecimentos adicionais sobre o estudo. Pelo presente instrumento que atende às exigências legais, o(a) Sr.(a) _____

Rubrica do Participante da Pesquisa :

Rubrica do Pesquisador Responsável:

ANNEX B – Informed consent (verso)



**Universidade de São Paulo
Faculdade de Odontologia de Bauru**

Página 2 de 2

Departamento de Odontopediatria, Ortodontia e
Saúde Coletiva

portador da cédula de identidade _____, após leitura minuciosa das informações constantes neste TERMO DE CONSENTIMENTO LIVRE E ESCLARECIDO, devidamente explicada pelos profissionais em seus mínimos detalhes, ciente dos serviços e procedimentos aos quais será submetido, não restando quaisquer dúvidas a respeito do lido e explicado, DECLARA e FIRMA seu CONSENTIMENTO LIVRE E ESCLARECIDO concordando em participar da pesquisa proposta. Fica claro que o participante da pesquisa, pode a qualquer momento retirar seu CONSENTIMENTO LIVRE E ESCLARECIDO e deixar de participar desta pesquisa e ciente de que todas as informações prestadas tornar-se-ão confidenciais e guardadas por força de sigilo profissional (Art 9º do Código de Ética Odontológica).

Por fim, como pesquisador responsável pela pesquisa, DECLARO o cumprimento do disposto na Resolução CNS nº 466 de 2012, contidos nos itens IV.3 e IV.5.a e, na íntegra com a resolução CNS nº 466 de dezembro de 2012.

Por estarmos de acordo com o presente termo o firmamos em duas vias igualmente válidas (uma via para o participante da pesquisa e outra para o pesquisador) que serão rubricadas em todas as suas páginas e assinadas ao seu término, conforme o disposto pela Resolução CNS nº 466 de 2012, itens IV.3.f e IV.5.d.

Bauru, ____ de _____ de _____.

Rodrigo Andrés Naveda Araque
Pesquisador responsável

Assinatura do participante

Rubrica do Participante da Pesquisa :

O Comitê de Ética em Pesquisa – CEP, organizado e criado pela FOB-USP, em 29/06/98 (Portaria GD/0698/FOB), previsto no item VII da Resolução nº 466/12 do Conselho Nacional de Saúde do Ministério da Saúde (publicada no DOU de 13/06/2013), é um Colegiado interdisciplinar e independente, de relevância pública, de caráter consultivo, deliberativo e educativo, criado para defender os interesses dos participantes da pesquisa em sua integridade e dignidade e para contribuir no desenvolvimento da pesquisa dentro de padrões éticos.

Qualquer denúncia e/ou reclamação sobre sua participação na pesquisa poderá ser reportada a este CEP:

Horário e local de funcionamento:

Comitê de Ética em Pesquisa
Faculdade de Odontologia de Bauru-USP - Prédio da Pós-Graduação (bloco E - pavimento superior), de segunda à sexta-feira, no horário das 13h30 às 17 horas, em dias úteis.
Alameda Dr. Octávio Pinheiro Brisolla, 9-75
Vila Universitária – Bauru – SP – CEP 17012-901
Telefone/FAX(14)3235-8356
e-mail: cep@fob.usp.br

Rubrica do Pesquisador Responsável: