Universidade de São Paulo

Instituto de Biociências

Melina Guerreiro Rodrigues

Em busca da etiologia das displasias frontonasais

In search of the etiology of frontonasal dysplasias

São Paulo

2013

Melina Guerreiro Rodrigues

Em busca da etiologia das displasias frontonasais

In search of the etiology of frontonasal dysplasias

Dissertação apresentada ao Instituto de Biociências da Universidade de São Paulo para obtenção do título de Mestre em Ciências, na Área de Biologia/Genética.

Orientador: Prof. Dra. Maria Rita dos Santos e Passos Bueno

São Paulo

2013

Ficha Catalográfica

Rodrigues, Melina

Em busca da etiologia das displasias frontonasais

70 páginas

Dissertação (Mestrado) - Instituto de Biociências da Universidade de São Paulo. Departamento de Genética e Biologia Evolutiva.

1. Displasia frontonasal
2. CNV
3. Genes candidatos

Comissão Julgadora:

_____ _____

Prof. Dr(a). Prof. Dr(a).

_____

Prof. Dra. Maria Rita dos Santos e Passos Bueno

Orientadora

Dedicatória

Aos meus pais, base e exemplos maiores de minha vida,

por toda dedicação e amor.

Ao André Luiz Cechini, meu grande companheiro, pela

amizade, amor, paciência e apoio incondicionais durante

os anos de realização deste trabalho.

“The greater our knowledge increases the more our ignorance unfolds.”

- John F. Kennedy

Agradecimentos

Agradeço aos meus pais, Elaine e Gilberto, por todo carinho, amor e dedicação. Obrigada por terem ensinado a mim e minhas irmãs a valorizar cada oportunidade que a vida nos dá, e por nos mostrarem que entre todos os bens existentes, o conhecimento é o maior. Agradeço a Deus por ter me permitido nascer, crescer e poder contar sempre com os grandes exemplos que vocês são.

Agradeço às minhas irmãs, Talita e Aline, por todo apoio, torcida e força que sempre me passaram. Obrigada pelo carinho, amor e amizade de vocês, que mesmo à distância se fazem tão presentes em minha vida.

Agradeço ao André, amigo e companheiro de tantos anos, pelo carinho, atenção, amor, paciência e apoio que sempre me dedicou. Você fez meus dias mais felizes e leves, e me mostrou que mesmo em dias conturbados temos muitas razões para sorrir. Obrigada por tudo!

Agradeço ao Paulo e à Vera pelo carinho com que sempre me trataram. Obrigada por terem me acolhido tão bem e por todo apoio que deram a mim e ao André.

Família, Amo Vocês!!!

Agradeço à prof. Maria Rita pela oportunidade de aprender com ela e seu grupo. Obrigada pela paciência e dedicação de sua orientação, sem as quais esse e tantos outros trabalhos não existiriam.

Agradeço aos queridos amigos do laboratório por todo auxílio em experimentos, pelas discussões de artigos e principalmente pelas risadas. De forma especial, agradeço às amigas e irmãs de coração: Cintia, Francine, Andressa, Larissa, Simone, Ana e Joana. Obrigada por estarem sempre disponíveis e por tornarem os momentos mais simples em especiais!!! Cintia, obrigada por estar

todos os dias ao meu lado... e não estou me referindo apenas aos nossos lugares na bancada! rsrsrs... Amigas, amo vocês!!!

Agradeço às amigas de muitos anos, Thaisa e Patrícia, por serem prova de que amizade verdadeira transcende as fronteiras geográficas. Obrigada por serem tão especiais! Amo vocês!!!

Agradeço a todos os colaboradores que tornaram este estudo possível: Dra. Roseli Maria Zechi Ceide, Dra. Débora Romeo Bertola, Dra. Maria Leine Guion de Almeida, Dr. Antônio Richieri Costa, Dra. Josiane de Souza, Dr. Renato da Silva Freitas, Dra. Carla Rosenberg, Dra. Angela Maria Vianna Morgante, MSc. Ana Carolina Fonseca.

Agradeço com carinho aos pacientes e seus familiares pela participação tão especial.

Agradeço os apoios financeiros: CEPID/FAPESP, CAPES e CNPq.

Notas

Esta dissertação compreende um trabalho desenvolvido durante os anos de 2010 a 2013 no Laboratório de Genética do Desenvolvimento do Centro de Estudos do Genoma Humano, Instituto de Biociências, Universidade de São Paulo (CEGH/IB-USP).

As referências citadas nos artigos (capítulos 3 a 6) encontram-se ao final de cada um. As referências bibliográficas dos capítulos 1, 2 e 7 (Introdução, Casuística e Métodos e Discussão Geral e Conclusões, respectivamente) estão relacionadas ao final da dissertação.

Os artigos estão redigidos em inglês, por motivos referentes à publicação.

Índice

I. Introdução

1.1 Aspectos Gerais das Displasias Frontonasais

Anomalias craniofaciais respondem por aproximadamente um terço de todas as anomalias congênitas humanas (Trainor e Krumlauf, 2000). Dentre elas estão os defeitos de linha média craniofacial, que compreendem alterações do sistema nervoso central (SNC), decorrentes de falha na clivagem do prosencéfalo, e alterações faciais, decorrentes de falha no desenvolvimento do processo frontonasal. Considerada um plano sagital imaginário, a linha média se refere a um campo especial de desenvolvimento que determina tanto a posição das vísceras nos embriões como o plano de clivagem de gêmeos monozigóticos (Opitz, 1993 revisado por Guion-Almeida, 2000). Defeitos no desenvolvimento da linha média craniofacial levam a diferentes fenótipos faciais, tanto quando há redução do espaço interorbitário, tendendo para a holoprosencefalia (HPE) e até ciclopia, como quando há uma expansão, sendo a duplicação facial ou *diprosopus* seu estágio mais grave (Brugmann et al., 2010).

Dentro do espectro de expansão de linha média, a displasia frontonasal (DFN) compreende quadros de aparência facial variável, sendo clinicamente caracterizada por dois ou mais dos seguintes sinais: hipertelorismo com consequente alargamento da base nasal; fissura facial mediana afetando o nariz ou o nariz e lábio superior e, por vezes, o palato; fissura alar (uni ou bilateral); ponta nasal ausente; crânio anterior bífido, e implantação em "V" dos cabelos na fronte (Sedano e Gorlin, 1988 revisado por Guion-Almeida, 2000). A DFN pode ser vista como um defeito de desenvolvimento que pode ocorrer por si só ou como parte do quadro clínico de várias síndromes, a grande maioria de etiologia e padrão de herança desconhecidos (Guion-Almeida, 2000; Guion-Almeida et al., 1996, 2007; Guion-Almeida e Richieri-Costa, 2001, 2003, 2009; Wu, Vargevik e Slavotinek, 2007). Há

trabalhos que sugerem uma maior ocorrência de DFN em meninos, mas estes resultados são ainda controversos (Guion-Almeida et al., 1996; Rizvi et al., 2010; Antoneli, 2011).

1.1.1 Desenvolvimento embriológico

A face dos vertebrados é uma estrutura complexa que consiste de uma grande variedade de tecidos com arranjo precisamente definido. Durante a embriogênese, a face desenvolve-se a partir de 4 primórdios faciais, os quais envolvem a boca primitiva e os placódios nasais. A proeminência frontonasal, o processo nasal lateral e o processo maxilar expandem-se e fundem-se parcialmente para formar o maxilar superior e a região nasal, enquanto o primórdio mandibular dá origem à mandíbula. Inicialmente, todos os primórdios faciais consistem de um centro mesenquimal indiferenciado revestido por ectoderme. O mesênquima contém células da crista neural e do mesoderma cranial. As células derivadas da crista neural dão origem ao esqueleto facial, enquanto as células mesodermais dão origem, principalmente, aos músculos faciais (Nie et al., 2006). O processo de desenvolvimento craniofacial é controlado por uma complexa rede de genes que inclui genes que codificam uma variedade de moléculas sinalizadoras, fatores de transcrição e fatores e receptores de crescimento. A ruptura dessa regulação molecular resulta em diversos defeitos craniofaciais (Francis-West et al., 1998; Wilkie e Morris-Kay et al., 2001; Jiang et al., 2006; Nie et al., 2006; Handrigan et al., 2007).

O espectro fenotípico da DFN é resultante de uma interrupção no desenvolvimento normal do processo frontonasal como uma forma de defeito de campo e o aspecto facial é mais grave quanto mais precocemente ocorrer essa alteração (Sedano e Gorlin, 1988 revisado por Guion-Almeida, 2000). Do ponto de vista embriológico, o desenvolvimento inadequado do placódio nasal, impedindo a formação da cápsula nasal, ou um defeito intrínseco da cápsula nasal, podem levar ao

fenótipo facial de DFN. Anomalias de linha média craniofacial podem, ainda, resultar de anomalias do processo sutural dos ossos da abóbada craniana com os ossos da base do crânio (fronto-etmoidal) ou resultar da alteração na harmonia do fechamento das suturas da base do crânio, principalmente da sutura esfeno-etmoidal. Nessas circunstâncias, é comum ocorrer encefalocele frontonasal, fronto-etmoidal, etmoidal e esfeno-etmoidal. A presença de encefaloceles nessas linhas de sutura, usualmente determinam hipertelorismo de graus variáveis e fenótipo facial de DFN. O envolvimento do processo frontonasal, nessas situações, seria secundário. Diferenciação prematura e rápida dos ossos do neurocrânio levando à fusão precoce das suturas afetando, secundariamente, o desenvolvimento do cérebro, pode resultar também numa face semelhante à DFN. Sedano e Gorlin (1988 revisado por Guion-Almeida, 2000) comentam, ainda, que a ação de um agente em período embrionário precoce que implique no desenvolvimento anormal do primeiro arco branquial pode levar a um consequente prejuízo no desenvolvimento do processo frontonasal. Sendo assim, o processo embriogênico que induz a formação da face observada na DFN e nas condições que incluem este fenótipo facial é variável.

1.1.2 Etiologia

A maioria dos casos de DFN é esporádica. Das síndromes que ocorrem com DFN, até pouco tempo apenas a displasia craniofrontonasal (DCFN) apresentava etiologia genética definida, sendo mutações no gene *EFNB1* responsáveis pelo quadro clínico de grande parte dos afetados. A DCFN se caracteriza por anomalias estruturais do SNC, craniossinostose coronal, hipertelorismo ocular, nariz bífido, fissura de lábio e palato e anomalias esqueléticas. A grande maioria das mutações do gene *EFNB1* ocorrem em seus éxons 2 e 3 (Twigg et al., 2004; Wieland et al., 2004; Twigg et al., 2006; Wallis et al., 2008), e a natureza variável dessas mutações sugere que o fenótipo resulta de perda de função da proteína efhrin-B1 (Twigg et al., 2004; Wieland et al., 2004; Twigg et al., 2006). Embora a

DCFN apresente herança dominante ligada ao X, a gravidade do fenótipo nas mulheres afetadas é maior do que nos homens. O mecanismo de interferência celular, que tem sido apontado como a explicação mais adequada para tal paradoxo (Compagni et al., 2003; Twigg et al., 2004; Wieland et al., 2004; Wieacker e Wieland, 2005; Wieland et al., 2008; Evers et al., 2013), seria resultado da combinação de: (1) inativação randômica do X nas mulheres, (2) funções específicas do gene *EFNB1* (que é sujeito a essa inativação) nas propriedades das superfícies celulares, levando a interações anormais entre células no estado mosaico, e (3) provável redundância funcional do gene em homens hemizigotos não mosaicos (Twigg et al., 2013). Estudos com camundongos (Compagni et al., 2003; Wieland et al.,2008) e a detecção de mosaicismo somático em todos os indivíduos do sexo masculino com quadro de DCFN grave (semelhante ao que ocorre nas mulheres) investigados por Twigg et al. (2013) corroboram esta hipótese.

Três recentes estudos atraíram atenção aos fatores de transcrição *Homeobox aristaless-related*, relacionando-os à patogênese molecular de algumas das síndromes com DFN (Twigg et al., 2009; Kayserili et al., 2009; Uz et al., 2010). Acredita-se que, nos vertebrados, os genes *Aristaless-like homeobox Alx1 (Cart1), Alx3 e Alx4* codifiquem proteínas que exercem papéis críticos durante o desenvolvimento de estruturas derivadas do mesênquima craniofacial, do primeiro arco branquial e dos brotos de membros (revisto em Uz et al., 2010). Embora camundongos com deleções tanto hetero quanto homozigotas do *Alx3* não exibam fenótipo óbvio de expansão de linha média, mutações em homozigose no *ALX3* em seres humanos causam a frontorrinia, uma síndrome descrita por Twigg et al. (2009). A frontorrinia se caracteriza por hipertelorismo, ponte nasal larga, crista nasal curta, ossos nasais afunilados com a ponta nasal bífida, columela ampla unida à face acima da asa nasal, narinas em fenda amplamente separadas, filtro longo, cume do filtro proeminente, ocasionalmente com edema bilateral adicional em direção às narinas, e entalhe medial no lábio superior e alvéolos. Aparentemente a expressividade dessa síndrome não é muito variável e não há correlação genótipo-fenótipo; até o momento 14 casos foram reportados na literatura (Twigg et al.,

2009; Pham et al., 2011). Kayserili et al. (2009), por sua vez, demonstraram que mutações em homozigose no gene *ALX4* respondem pelo fenótipo de dois pacientes com hipertelorismo, ponta nasal bífida, grave defeito de crânio, craniossinostose coronal, agenesia de corpo caloso, criptorquidismo, alopecia total e retardo mental. Segundo revisão dos próprios autores, camundongos homozigoto-mutantes para *Alx4* compartilham diversas das características faciais apresentadas pelos pacientes. Kayserili et al. (2012) encontraram uma mutação em homozigose no *ALX4* causando também um fenótipo mais leve de DFN em um menino com hipertelorismo, base e ponte nasais largas, ponta nasal bífida, fissura alar, columela ampla, apêndice pré-auricular unilateral, sulco lábio-gengival alargado e forame parietal bilateral alargado. Esta última característica já foi descrita ocorrendo isoladamente em indivíduos com mutação em heterozigose no *ALX4* (Mavrogiannis et al., 2006). Já Uz et al. (2010) encontraram mutações em homozigose no gene *ALX1* em dois pacientes com microftalmia bilateral grave, fissura facial oblíqua bilateral, palato completamente fissurado, hipertelorismo, ponte nasal larga com hipoplasia de narinas, e orelhas com baixa implantação e posteriormente rodadas. Camundongos com *knockout* homozigoto para o *Alx1* apresentam, além da cartilagem nasal gravemente afetada, defeitos de fechamento do tubo neural que levam a anencefalia e grandes defeitos cranianos (revisto em Uz et al., 2010). Não foi encontrada anomalia de fechamento de tubo neural nos pacientes por eles estudados. Em todos os casos de DFN relacionada a genes *ALX* descritos até então o padrão de herança é autossômico recessivo.

Em raras circunstâncias foram observadas alterações cromossômicas em indivíduos com DFN, tais como: trisomia 2q31-2qter e monossomia do 7q36-7qter em uma menina com DFN e arrinencefalia; translocação equilibrada entre os cromossomos 15 (15q22) e 22 (22q13) em uma criança com DFN; rearranjo cromossômico complexo envolvendo os cromossomos 3 (3q23 e 3q27), 7 (7q21.3) e 11 (11q21), em um menino com DFN (Wu et al., 2007); deleção parcial do 2q36 em uma menina com DFN, dolicocefalia, hipertricose, alterações esqueléticas, deficiência intelectual leve, hipotonia, entre outros achados, e em estado mosaico em sua mãe, que apresentou quadro mais

leve (Freitas et al., 2012); deleção parcial do 21q22.3 em uma menina com DFN, agenesia de corpo caloso, encefalocele e anomalias oculares (Guion-Almeida et al., 2012). Esses achados sugeriram que tais regiões cromossômicas podem conter genes associados à etiologia da DFN.

A descrição de raros casos de DFN com recorrência familial, a observação de alterações cromossômicas em determinados pacientes com DFN e a identificação de mutações em *EFNB1, ALX1, ALX3* e *ALX4* como causativas de quadros que cursam com DFN mostram a influência de fatores genéticos em sua etiologia. Embora a discordância de DFN entre gêmeos monozigóticos a princípio sugira a ação de fatores ambientais no fenótipo, vale notar que ela pode ser também explicada por mecanismos genéticos e epigenéticos (Guion-Almeida, 2000; Wu, Vargevik e Slavotinek, 2007), tais como mosaicismo cromossômico, mutações pós-zigóticas, metilação diferencial de DNA, entre outros (Silva et al., 2011).

1.2 Justificativa

Embora seja claro que haja heterogeneidade etiológica na DFN e quatro genes já tenham sido descritos como responsáveis por quadros com este fenótipo, a maioria dos casos continua sem identificação causal. Dessa forma, estudos envolvendo diferentes estratégias metodológicas em indivíduos com DFN podem auxiliar na compreensão de sua etiologia, a qual é ainda muito pouco conhecida. O melhor entendimento das causas da DFN poderão também auxiliar na realização de um aconselhamento genético mais preciso aos pacientes e seus familiares.

Uma estratégia que pode ser bem sucedida para a identificação de genes associados a doenças é a clonagem de pontos de quebra de rearranjos cromossômicos balanceados em indivíduos com um dado fenótipo, uma vez que tais pontos de quebra podem romper um ou mais genes ou regiões regulatórias importantes (Petek et al., 2001; Kim et al., 2008; Poot et al., 2010).

Nos últimos anos, tem-se demonstrado que variações de número de cópias (*copy number variations* – CNVs) podem estar relacionadas com a etiologia de diferentes entidades clínicas, a maioria com padrão de herança complexa tais como autismo e esquizofrenia (Sebat et al., 2007; Marshall et al., 2008; Sutrala et al., 2008; Xu et al., 2009). No entanto, CNVs também tem sido identificadas como mecanismo genético causativo de malformações congênitas, particularmente quando associadas a alterações de desenvolvimento (Krepischi-Santos et al., 2006; Shinawi e Cheung, 2008; Jehee et al., 2009; Sun et al., 2009; Rossi et al., 2009; Zhang et al., 2009). Estudo de CNVs seria, portanto, uma abordagem promissora para triagem genética em indivíduos com DFN e alterações de desenvolvimento. O uso de hibridização genômica comparativa por microarranjo (*microarray comparative genomic hybridization* – array-CGH) e de micrroarranjo de polimorfismos de base única (*single nucleotide polymorphism microarray* - SNP-arrays) são técnicas com eficiência comprovada para análise de CNVs nas diferentes plataformas disponíveis (Hester et al., 2009).

Embora a análise de CNVs seja uma boa abordagem para triagem em pacientes com malformações congênitas, ela não é capaz de identificar certos tipos de alterações genômicas plausíveis de explicar tais fenótipos, como mutações de ponto, pequenas deleções e inserções, entre outras. Para os genes nos quais mutações já foram efetivamente encontradas em pacientes com algum fenótipo que inclui DFN (*EFNB1, ALX1, ALX3* e *ALX4*), uma abordagem relativamente simples capaz investigar tais tipos de alterações é o sequenciamento dos genes.

1.3 Objetivo

O objetivo geral deste trabalho é identificar possíveis causas genéticas da DFN.

Os objetivos específicos, por sua vez, são:

- Verificar a presença de mutações nos genes *EFNB1, ALX1, ALX3* e *ALX4* em casos de DFN com ou sem atraso de desenvolvimento.

- Verificar se um rearranjo cromossômico previamente identificado em um caso de DFN, atraso de desenvolvimento e outras anomalias rompe um ou mais genes que possam estar relacionados ao quadro clínico do paciente.

- Verificar se CNVs podem estar relacionadas ao mecanismo etiopatológico de DFN associada a atraso de desenvolvimento.

II. Casuística e Métodos

2.1 Casuística

Ao todo foram incluídos neste estudo 10 pacientes:

- Um indivíduo com fenótipo brando de DFN cuja mãe apresenta quadro bastante semelhante, atendido no Centro de Estudos do Genoma Humano (CEGH) da Universidade de São Paulo, São Paulo/SP – **Capítulo 3**.

- Um indivíduo com fenótipo grave de DFN indicativo de mutação em *ALX1*, atendido no CEGH – **Capítulo 4**.

- Um indivíduo com DFN associada a outras anomalias que possui um rearranjo cromossômico detectável via cariótipo, avaliado pela Seção de Genética Clínica do Hospital de Reabilitação de Anomalias Craniofaciais (HRAC) da Universidade de São Paulo, Bauru/SP – **Capítulo 5**.

- Sete indivíduos com DFN associada a alterações de desenvolvimento com ou sem outras anomalias, dos quais quatro são pacientes do HRAC e três do Centro de Atendimento Integral ao Fissurado Lábio-palatal (CAIF), Curitiba/PA – **Capítulo 6**.

Em todos os casos, os indivíduos somente foram incluídos no estudo mediante autorização expressa do paciente ou responsável através da concordância com o Termo de Consentimento Livre e Esclarecido, aprovado pelo Comitê de Ética do HRAC (19/2011-SVAPEPE-CEP). Os pacientes atendidos no CEGH foram avaliados pela geneticista clínica Dra. Débora Romeo Bertola, do Instituto de Biociências, Departamento de Genética. Os pacientes atendidos no HRAC foram avaliados no Setor de Genética Clínica pela geneticista Dra. Roseli Maria Zechi Ceide, e pelos geneticistas clínicos

Dra. Maria Leine Guion de Almeida e Dr. Antônio Richieri Costa. Os pacientes atendidos no CAIF foram avaliados pela geneticista clínica Dra. Josiane de Souza e pelo cirurgião plástico e craniofacial Dr. Renato da Silva Freitas.

2.2 Métodos

Inicialmente foi realizada triagem de mutação nos genes *EFNB1, ALX1, ALX3* e *ALX4* em todos os pacientes. Para aqueles que mostraram resultados normais nos sequenciamentos desses genes, foi realizada análise de CNVs. Para o paciente com rearranjo cromossômico foi realizado também o mapeamento dos pontos de quebra.

2.2.1 Amostras de DNA

As amostras de DNAs utilizadas neste projeto tiveram sua concentração e a qualidade verificadas no aparelho *NanoDrop ND 1000* (espectrofotômetro da *Peqlab Biotechnologie™*) e em gel de agarose 1,0%.

2.2.2 Triagem dos Genes *EFNB1, ALX1, ALX3* e *ALX4*

Para todos os pacientes incluídos no estudo foi realizada triagem de mutação por sequenciamento Sanger nos genes já descritos como relacionados a fenótipos com DFN: *EFNB1, ALX1, ALX3* e *ALX4*. Os *primers* e as condições de reação (concentrações e temperaturas) utilizados para amplificação da região codificante dos genes foram descritos por Twigg et al. (2004; 2009). Para a análise dos cromatogramas foi utilizado o *software Sequencher 4.9 Demo*, da *Gene Codes Corporation.*

2.2.3 Análise de CNVs

Para a análise de CNVs optamos por realizar a técnica de *SNP-array*, que apresenta alta resolução na detecção de ganhos e perdas de material genético por apresentar sondas em diversos *loci* distribuídos por todo o genoma. Utilizamos para tanto a plataforma *GeneChip® Human Mapping 500K Array Set, Affymetrix®* (Santa Clara, CA, EUA) de acordo com o protocolo do fabricante. Esta plataforma compreende dois *arrays*, cada um capaz de genotipar em media 250 mil polimorfismos de base única (SNPs) – aproximadamente 262 mil para a enzima de restrição Nsp e 238 mil para a Sty. A distribuição resultante das sondas considerando os 500 mil SNPs não é uniforme nas lâminas, tendo distância física mediana entre eles de 2,5kb e média de 5,8kb.

Após a hibridação, lavagem e marcação, as lâminas foram escaneadas no *GeneChip® Scanner 3000 7G* (Affymetrix® - Santa Clara, CA, EUA). Os dados de intensidade foram gerados pelo programa *GeneChip Command Console Software* (Affymetrix® - Santa Clara, CA, EUA). A qualidade da hibridização das amostras foi avaliada pelo índice de *QC Call Rate*; o limite mínimo escolhido para este índice foi 90,0. Os dados gerados nos arrays foram analisados através dos softwares *Genotyping Console, Affymetrix* (Santa Clara, CA, EUA), *PennCNV* (Wang et al., 2007; Wang e Bucan, 2008), e *dChip* (Li and Wong 2001; Lin et al. 2004). Segundo Kim et al. (2012), ao se combinar múltiplos algoritmos de definição de regiões de CNV a partir de SNP-arrays, aumenta-se a segurança e confiabilidade da análise. Assim, definimos como critério mínimo de confiança para a existência de determinada CNV o fato de ela estar presente nos resultados gerados por pelo menos dois *software* distintos.

As variações encontradas segundo este critério foram comparadas às dos bancos de dados *Database of Genomic Variants* (DGV - http://projects.tcag.ca/variation/), que contém informações sobre CNVs observadas em indivíduos controles, e *Database of Chromosomal Imbalance and Phenotype in Humans using Ensembl Resources* (DECIPHER - http://decipher.sanger.ac.uk/), que compila dados de alterações encontradas em indivíduos com fenótipos alterados. Para investigação

de genes localizados em tais regiões foram realizadas análises *in silico* nos bancos de dados do *UCSC Genome Browser* (UCSC - http://genome.ucsc.edu/), *Ensembl Genome Browser* (Ensembl - http://www.ensembl.org/) e do *National Center for Biotechnology Information* (NCBI - http://www.ncbi.nlm.nih.gov/).

2.2.4 Mapeamento do ponto de quebra

O mapeamento do ponto de quebra foi realizado através da técnica de hibridização *in situ* fluorescente (*Fluorescense In Situ Hybridization* – FISH). Para tanto contamos com infra-estrutura, materiais e protocolos do laboratório da Drª. Angela Maria Vianna Morgante, colaboradora deste projeto, e com o auxílio de sua aluna de doutorado, Ana Carolina Fonseca (Processo FAPESP 2011/14293-4).

Recebemos 5ml de sangue periférico do paciente em tubo com heparina. Estabelecemos cultura temporária de linfócitos adicionando 0,5 mL de plasma sanguíneo em 4,5 mL de meio de cultura TC 199 (Invitrogen, Carlsbad, EUA), complementado com soro fetal bovino 15% (Invitrogen), L-glutamina 1% (Sigma, Saint Louis, EUA) e fitohemaglutinina 1% (Invitrogen), por 72 h, a 37°C. O tratamento com colchicina (Sigma) na concentração final de 0,0016% foi realizado nos 40 min finais do cultivo. Para a hipotonização, utilizamos solução de KCl (0,075 M) por 12 min a 37°C e para a fixação, metanol:ácido acético, 3:1. Parte do material foi conservada a 20°C no fixador e parte foi utilizada na preparação de lâminas, que foram mantidas em estufa a 37°C, por sete a quinze dias e, então, utilizadas para a aplicação da técnica de bandamento cromossômico GTG ou congeladas a –20°C, para utilização posterior em experimentos de FISH.

Para a identificação do rearranjo cromossômico foi utilizada a técnica de bandamento GTG descrita por Seabright (1971), com modificações. As lâminas foram tratadas com 2xSSC (cloreto de sódio 0,03 M e citrato trissódico 0,03 M, pH 7,0) por 15 minutos, a 60°C. Em seguida, foram lavadas

em água destilada e tratadas com solução de tripsina (1:250; Invitrogen) 0,025% em tampão fosfato Sörensen (fosfato dissódico 0,03 M e fosfato monopotássico 0,03 M), pH 6,8, a 37°C por tempo aproximado de 15 s. A seguir, as lâminas foram lavadas em água destilada e coradas por 3 a 6 min com solução a 2% do corante de Giemsa (Merck), em tampão fosfato, pH 6,8. Após serem coradas, foram mais uma vez lavadas em água destilada; secaram ao ar e posteriormente foram analisadas ao microscópio óptico para realização do cariótipo.

Para a técnica de FISH, utilizamos como sondas os segmentos cromossômicos clonados em cromossomos artificiais de bactérias (BACs) que fazem parte da biblioteca utilizada para a confecção de *1Mb-array* produzido pela Dra. Carla Rosenberg, no Leiden University Medical Centre. Tais clones foram cedidos pelo *Wellcome Trust Sanger Institute*, UK; maiores informações sobre o conjunto estão disponíveis no site do banco de dados do Sanger Institute, Ensembl, sob a denominação *1Mb clone set*.

De acordo com os pontos de quebra mapeados por bandamento G, a seleção de sondas para este experimento foi feita com base nos mapas obtidos no Ensembl. As bactérias com os clones escolhidos foram cultivadas em meio LB (1% bactotriptona; 0,5% extrato de levedura; 1% NaCl; pH 7,5) acrescido do antibiótico para seleção de bactérias resistentes com os segmentos de interesse. Para a extração dos clones, utilizamos o kit Illustra™ PlasmidPrep Mini Spin (GE Healthcare, New Jersey, EUA). As sondas foram marcadas por *nick translation* com biotina ou digoxigenina por meio, respectivamente, da incorporação dos nucleotídeos Bio-16-dUTP ou Dig-11-dUTP, utilizando os kits de marcação Biotin-Nick Translation Mix ou Dig-Nick Translation (ambos da Roche Applied Science, Manheim, Alemanha), conforme instruções do fabricante. As sondas foram desnaturadas a 95°C em meio de hibridação (50% formamida, e 10% dextran sulfato, em 2xSSC). A supressão de sequências repetitivas foi feita com DNA humano Cot-1 (Invitrogen).

O DNA dos cromossomos das lâminas foi desnaturado em 70% formamida/2xSSC a 72°C. A hibridação, por sua vez, foi realizada em câmara úmida por 48 a 72 horas a 37°C. Para a detecção das

sondas marcadas com biotina, utilizamos avidina conjugada a FITC e para a detecção de sondas marcadas com digoxigenina, anti-digoxigenina conjugada a rodamina. As lâminas foram montadas em Vectashield Mouting Medium (Vector Laboratories, Califórnia, EUA) contendo o corante DAPI (0,8 µg/mL) (Sigma, Saint Louis, EUA). A análise foi realizada no microscópio de fluorescência Axiophot 2 (Carl Zeiss, Alemanha). Para a documentação, as imagens foram capturadas por câmara de CCD e processadas utilizando-se o software ISIS (MetaSystem, Alemanha).

A partir do resultado final do FISH, realizamos análises *in silico* nos bancos de dados do UCSC, Ensembl e NCBI, para investigar possíveis genes candidatos.

III. Transmissão Vertical de um Fenótipo Frontonasal Causado por uma Nova Mutação em *ALX4*

Artigo publicado na revista *American Journal of Medical Genetics*, em fevereiro de 2013.

Referência:

Bertola DR, Rodrigues MG, Quaio CR, Kim CA, Passos-Bueno MR. Vertical transmission of a frontonasal phenotype caused by a novel ALX4 mutation. Am J Med Genet A. 2013 Mar;161(3):600-4.

Resumo

Displasias frontonasais compreendem um espectro de desordens causadas por desenvolvimento anormal da face mediana. Sua etiologia é ainda pouco conhecida, mas, recentemente, fenótipos de displasia frontonasal foram relacionados a mutações de perda de função na família gênica *ALX-homeobox*, que compreende os genes *ALX1*, *ALX3* e *ALX4*. Até o momento, todos os fenótipos frontonasais relacionados a *ALX* foram compatíveis com modo de herança autossômico recessivo. Em contraste, mutações de perda de função no *ALX4* foram associadas isoladamente a defeitos simétricos de ossificação parietal na intersecção das suturas sagital e lambdóide, conhecidos como forame parietal alargado. Nós descrevemos uma família com transmissão vertical de mãe para filho de fenótipo brando de displasia frontonasal causado por uma nova mutação no gene *ALX4* (c.1080-1089_delGACCCGGTGCinsCTAAGATCTCAACAGAGATGGCAACT, p.Asp326fsX21). Este é o primeiro relato de fenótipo frontonasal relacionado a mutação em heterozigose no *ALX4*. A mutação é predita a levar à perda do domínio *aristaless* na região C-terminal da proteína, mas preserva o homeodomínio. Nós especulamos que um diferente mecanismo, de efeito dominante negativo, seja responsável pelo fenótipo distinto desta família.

CLINICAL REPORT

AMERICAN JOURNAL OF medical genetics PART A

Vertical Transmission of a Frontonasal Phenotype Caused by a Novel *ALX4* Mutation

Débora R Bertola,[1,2]* Melina G. Rodrigues,[2] Caio R.D.C. Quaio,[1] Chong A. Kim,[1] and Maria Rita Passos-Bueno[2]

[1]Instituto da Criança - HC/FMUSP, São Paulo, Brazil

[2]Instituto de Biociências - Universidade de São Paulo, São Paulo, Brazil

Manuscript Received: 23 February 2012; Manuscript Accepted: 16 October 2012

Frontonasal dysplasias (FND) comprise a spectrum of disorders caused by abnormal median facial development. Its etiology is still poorly understood but recently frontonasal dysplasia phenotypes were linked to loss-of-function mutations in the *ALX* homeobox gene family, which comprises the *ALX1*, *ALX3*, and *ALX4* genes. All ALX-related frontonasal phenotypes till date had been compatible with an autosomal recessive mode of inheritance. In contrast, heterozygous loss-of-function mutations in *ALX4* had been only associated with isolated symmetrical parietal ossification defects at the intersection of the sagittal and lambdoid sutures, known as enlarged parietal foramina. We report a family with vertical transmission from mother to son of mild frontonasal dysplasia phenotype caused by a novel *ALX4* gene mutation (c.1080-1089_delGACCCGGTGCinsCTAAGATCTCAACAGAGATGGCAACT, p.Asp326fsX21).This is the first report of a frontonasal phenotype related to a heterozygous mutation in *ALX4*. This mutation is predicted to cause the loss of the aristaless domain in the C-terminal region of the protein and preserves the homeodomain. We speculate that a different mechanism, a dominant-negative effect, is responsible for the distinct phenotype in this family. © 2013 Wiley Periodicals, Inc.

Key words: ALX4; parietal foramina; frontonasal dysplasia; dysmorphology

How to Cite this Article:
Bertola DR, Rodrigues MG, Quaio CRDC, Kim CA, Passos-Bueno MR. 2013. Vertical transmission of a frontonasal phenotype caused by a novel *ALX4* mutation.
Am J Med Genet Part A 161A:600–604.

INTRODUCTION

Frontonasal dysplasias (FND) comprise a spectrum of heterogeneous disorders caused by abnormal median facial development. The presence of two or more of the following clinical findings could define FND: True ocular hypertelorism, broadening of the nasal root, median facial cleft affecting the nose and/or upper lip and palate, unilateral or bilateral clefting of the alae nasi, lack of formation of the nasal tip, anterior cranium bifidum occultum, and a V-shaped or widow's peak frontal hairline [Sedano and Gorlin, 1988]. Additional characteristics are responsible for a myriad of other disorders within the FND spectrum, such as craniofrontonasal dysplasia (OMIM 304110), oculoauriculofrontonasal syndrome (OMIM 601452), frontofacionasal dysplasia (OMIM 229400), cerebrofrontofacial syndrome (OMIM 608578), acromelic frontonasal dysostosis (OMIM 603671), acrofrontofacionasal dysostosis 1 (OMIM 201180) and 2 (OMIM 239710), among others.

The majority of these cases are sporadic and their etiology is generally poorly understood. A genetic cause (*EFNB1* gene mutations) has been identified in X-linked craniofrontonasal dysplasia [Wieland et al., 2004]. Recently, patients with autosomal recessive FND were linked to homozygous loss-of-function mutations in the *ALX* homeobox gene family, which comprises *ALX1*, *ALX3*, and *ALX4* genes [Twigg et al., 2009; Kayserili et al., 2009; Uz et al., 2010]. This gene family belongs to the Paired-class homeoproteins and plays an important role in the complex processes of cranial development as well as neural tube closure and limb development [McGonnell et al., 2011]. Biallelic mutations in *ALX4* were identified in a patient with severe FND with additional findings of alopecia, coronal craniosynostosis, hypogonadism, and intellectual disability, named ALX4-related FrontoNasal Dysplasia with Alopecia and Genital abnormality phenotype (ALX4-related FNDAG) [Kayserili et al., 2009]. More recently, an attenuated FND phenotype, with enlarged parietal foramina and abnormalities of the corpus callosum and cerebellum was described in a boy with a homozygous mutation in *ALX4* [Kayserili et al., 2012].

Conflict of interest: None.

*Correspondence to:
Débora R Bertola, MD, PhD, Unidade de Genética – ICr. Av. Dr. Enéas Carvalho de Aguiar, 647, São Paulo – SP CEP: 05403-000 Brazil.
E-mail: debora.bertola@icr.usp.br

Article first published online in Wiley Online Library (wileyonlinelibrary.com): 7 February 2013
DOI 10.1002/ajmg.a.35762

In contrast, heterozygous loss-of-function mutations in *ALX4* were originally associated with isolated symmetrical parietal ossification defects at the intersection of the sagittal and lambdoid sutures, known as enlarged parietal foramina, without facial features characteristic of FND [Wuyts et al., 2000]. We report on the first vertical transmission of a mild FND phenotype caused by a novel heterozygous *ALX4* gene mutation.

CLINICAL REPORT

The proband, the second child of non-consanguineous parents, whose mother presented with arterial hypertension during pregnancy, was born preterm by cesarean with a birth weight of 2,650 g and length of 45 cm. He developed jaundice and required phototherapy. He evolved with normal developmental milestones. Because of bilateral cryptorchidism, the patient underwent orchidopexy at the age of 4 years, without success. He underwent two additional surgical procedures, but his left testis was considered dysgenetic. He has used corrective lenses for hyperopia since the age of 8 years.

He was referred to the Genetics Unit because of craniofacial dysmorphisms and cryptorchidism. He was evaluated at the age of 10 years and 4 months showing normal anthropometric measurements (W: 38.5 kg ~75th centile; H: 136 cm ~25th centile, and OFC: 53.5 cm ~50th centile); craniofacial features comprised frontal alopecia, sparse eyebrows, widely spaced eyes (ICD = 4 cm, OCD = 8.8 cm, IPD = 6.4 cm), telecanthus, lack of formation of the nasal tip, broad and elongated columella (Fig. 1A,E,F); undescended left testis, and broad thumbs (Fig. 1G).

His mother shared a similar pattern of facial features, including sparse eyebrows, widely spaced eyes, telecanthus (ICD = 3.7 cm, OCD = 8.5 cm, IPD = 6.1 cm), median cleft at the tip of the nose, and a broad and elongated columella (Fig. 1C).

Complementary exams in the proband, including abdominal ultrasound, echocardiogram, audiologic, and ophthalmologic evaluations (fundoscopy and slip-lamp exam), were normal. His cranial X-ray, as well as his mother's, displayed forme fruste parietal foramina (Fig. 1B,D).

The proband's sister and a female maternal cousin (Fig. 2A) were normal upon physical exam and cranial X-rays.

We concluded that the craniofacial features presented by this family were suggestive of FND and once mutations in *ALX4* gene have been recently described in patients with a mild phenotype, this specific gene was selected to be sequenced.

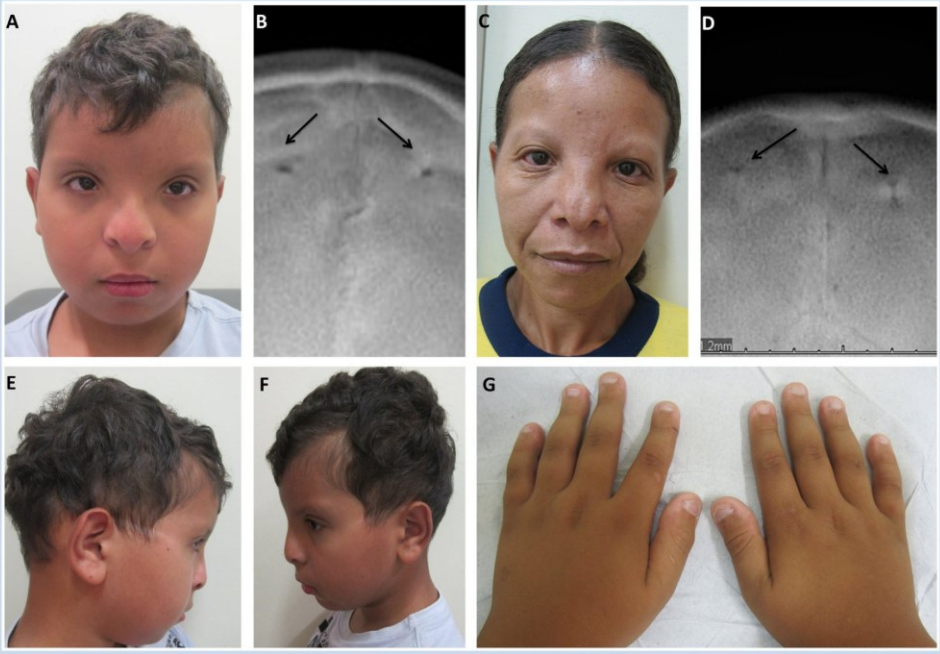

FIG. 1. Frontal view of the proband (A) and his mother (C): Note the sparse eyebrows, widely spaced eyes, telecanthus, broad nasal bridge, lack of the tip of their nose, with broad, elongated columella, and frontal alopecia in the proband (E,F). B,D: Cranial X-ray of the proband (B) and his mother (D) showing parietal foramina (dark arrows). G: Note broad thumbs in the proband's hands. [Color figure can be seen in the online version of this article, available at http://wileyonlinelibrary.com/journal/ajmga]

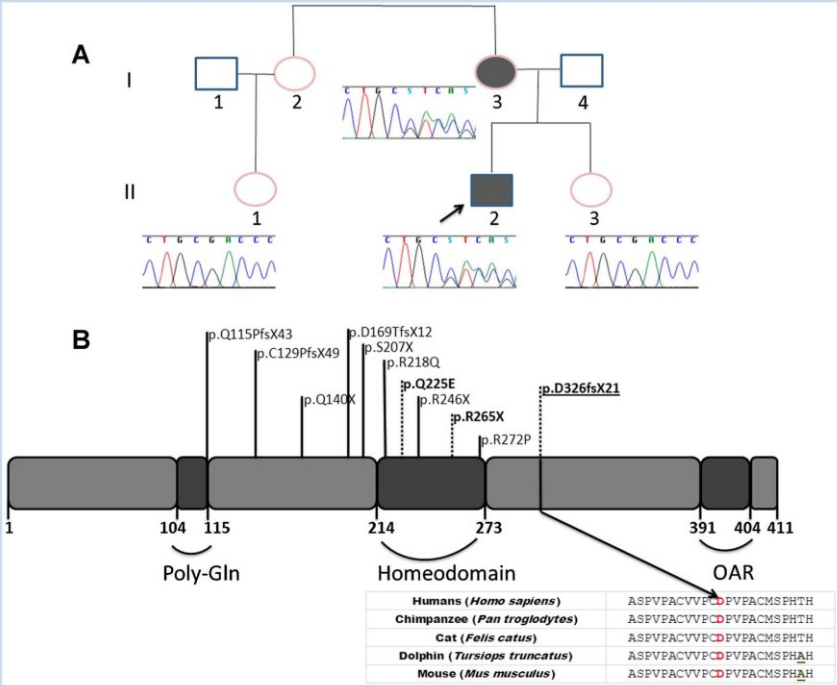

FIG. 2. A: Family pedigree: Observe that only the proband (II-2) and his mother (I-3) harbor the frameshift mutation in *ALX4*. B: The *ALX4* gene product showing the distribution of the mutations according to the localizations of the protein domains: p.Asn326fsX21, in bold and underlined, is the mutation described here; p.Gln225Glu and p.265X, in bold, are the mutations described in the literature related to a frontonasal involvement in homozygosity; the other mutations shown are related to parietal foramina [Wuyts et al., 2000; Mavrogiannis et al., 2001; Gentile et al., 2004; Mavrogiannis et al., 2006]. The arrow depicts the conservation of the region harboring the mutation here described among different species. [Color figure can be seen in the online version of this article, available at http://wileyonlinelibrary.com/journal/ajmga]

MATERIALS AND METHODS

For DNA sequencing analysis, we amplified the four *ALX4* exons of the proband and his mother as well as those of his sister and a female maternal cousin. The pair of primers used were described elsewhere [Mavrogiannis et al., 2001]. Bi-directional sequencing was performed using the BigDye Terminator v3.1 Cycle Sequencing kit, (Applied Biosystems, Carlsbad, CA) on the ABI PRISM® 3037 DNA Analyzer (Applied Biosystems) sequencer.

RESULTS

Exon sequencing of *ALX4* disclosed a novel heterozygous mutation carried by the proband and his mother: p.Asp326fsX21 (c.1080-1089_delGACCCGGTGCinsCTAAGATCTCAACAGAG ATGGCAACT; cDNA reference: NM_021926.3; protein reference: NP_068745.2). The analysis in the proband's sister and cousin yielded normal results (Fig. 2A).

DISCUSSION

We have presented the first FND phenotype associated with a heterozygous mutation in the *ALX4*. This illustrates the phenotypic heterogeneity of ALX4-related phenotypes, ranging from severe frontonasal involvement associated with homozygous loss-of-function mutations to enlarged parietal foramina caused by haploinsufficiency. The phenotype expressed by our family is placed in the middle of this spectrum.

The facial features observed in this group of patients are the main clinical finding. Kayserili et al. [2012] pointed out that the nasal configuration with notched alae nasi was shared by all the three described patients and this dysmorphic feature could be used as a good clinical discriminator between *ALX4* group and the other *ALX* gene phenotypes. Nevertheless, the mother and son reported here lacked the notched alae nasi, but shared a broad and elongated columella, providing a different gestalt (Fig. 1A,C). Thus, the facial features, within the spectrum of frontonasal dysplasia, are more diverse than previously thought and further clinical reports will be

important to fully discover the full range of phenotypes associated with *ALX4* mutations.

Genital anomalies are a frequent finding and restricted to males, although the mother of the proband has shown normal reproductive capacity. Three out of four male patients with a FND phenotype, including the proband described here, presented bilateral cryptorchidism [Kayserili et al., 2009]. The follow-up of these affected individuals would be important to determine if the gonadal abnormality will interfere in their ability to bear children.

Ectodermal involvement is a variable characteristic in patients with FND. It ranges from universal alopecia, described in the two original patients [Kayserili et al., 2009], to normal hair pattern [Kayserili et al., 2012]. The proband reported here had frontal alopecia and sparse eyebrows (Fig. 1A,E,F). The latter was also observed in the mother (Fig. 1C). These findings indicate an essential role of *ALX4* in the development of skin structures, such as the hair follicle [Kayserili et al., 2009].

Another point of interest is the presence of calvarial bone defects. It is known that enlarged parietal foramina are caused by heterozygous loss-of-function mutations in either *ALX4* or *MSX2*. Typically, they present as bilateral oval or round openings in the parietal bones on either sides of the posterior sagittal suture. When the bone defect extends between the anterior and posterior fontanelles, it is termed cranium bifidum. They are anatomically distinct from the normal minute foramina that transmit anastomotic vessels [Mavrogiannis et al., 2006]. Patients with the autosomal recessive FND phenotype have also shown the spectrum of cranium bifidum/enlarged parietal foramina. Interestingly, three parents of probands, heterozygous for the mutations, were also evaluated for this specific abnormality and only one of them showed smaller enlarged parietal foramina. Two others showed a normal parietal foramina, also observed in the mother–son described here (Fig. 1B,D). This could be explained by an incomplete penetrance of this trait, already observed on several patients carrying heterozygous mutations that do not show the bone abnormalities on their X-rays [Mavrogiannis et al., 2006].

The genetic background underlying the phenotype in the family reported here is distinct from the previous case reports. *ALX4* has two different isoforms, which may be transcribed from two different translation initiation sites, and encodes a homeodomain transcription factor required for many developmental processes. Identifiable motifs include a poly Pro/Gln sequence encoded by exon 1, a homeodomain DNA-binding region encoded by exons 2 and 3 and an aristaless/OAR domain encoded by exon 4 [Mavrogiannis et al., 2001].

All the three patients with ALX4-related FNDAG phenotype reported in the literature showed mutations in a homozygous status, severely impairing the protein function. Two of them exhibited the same mutation (p.Arg265X), and were from nearby cities in the Black Sea region of Turkey, suggesting a founder effect. The p.Arg265X mutation, located on helix III of the homeodomain (Fig. 2B) that is known to interact with DNA major groove, probably disrupts part of this highly conserved domain and causes the complete loss of the C-terminal paired tail domain. The authors also demonstrated that the protein was mislocalized to the cytoplasm, giving further support to a loss-of-function mechanism [Kayserili et al., 2009].

A milder ALX4-related FNDAG phenotype was described in a patient presenting another homozygous missense mutation (p.Gln225Glu) on the helix I of the homeodomain (Fig. 2B). The fact that in silico studies showed that the mutation could interfere in the protein folding and that there are other mutations in the same highly conserved Gln12 residue of other Paired-class homeodomain coding genes, reported as causing different disorders, support the pathogenicity of the mutation described here. Furthermore, the authors speculated that a residual ALX4 activity could be responsible for the milder phenotype of this patient compared to the two previously ones [Kayserili et al., 2012].

On the other hand, heterozygous mutations either in the homeodomain or in the N-terminal region adjacent to the homeodomain (Fig. 2B), causing protein haploinsufficiency, were only associated with the presence of enlarged parietal foramina [Wuyts et al., 2000; Mavrogiannis et al., 2001; Gentile et al., 2004; Mavrogiannis et al., 2006].

The family reported here has a heterozygous frameshift mutation in the C-terminal region adjacent to the homeodomain (p.Asp326fsX21), a site not overlapping with the ones in enlarged parietal foramina. This mutation was considered pathogenic: It predicts a premature stop-codon, the region is highly conserved among different taxa, it segregates only in the affected individuals within this family, and it predicts the loss of the OAR domain (Fig. 2B).

The OAR or aristaless domain is conserved in a subset of the large class of Paired-class homeoproteins [Brouwer et al., 2003]. Its function in ALX4 has never been addressed. Studies on the function of the OAR domain in other Paired-class homeoproteins, such as ALX1 and ARX have shown different activities: The deletion of the aristaless domain in ALX1 unleashes its teratogenic potential, functioning to restrain activity of this transcription factor in vivo, partially or completely through its effect on DNA binding. The same study showed that this pattern was not shared by ALX3 [Brouwer et al., 2003]. On the other hand, McKenzie et al., [2007] demonstrated that the transcription repression activity of ARX is modulated by two strong repression domains and one activator domain, the aristaless domain. The authors of these studies suggested that each transcriptional factor could have distinct forms that may be activated or repressed. Until the precise role of the OAR in ALX4 is understood, we speculate that the loss of this OAR domain with the maintenance of the homeodomain in the allele carrying the mutation in the family reported here will generate a product that is not subject to nonsense mediated decay (NMD), as the mutation is located in the last exon of the gene. In mammalian cells, this mechanism of RNA degradation requires at least one intron downstream of a premature termination codon in order for the transcript to be targeted for NMD [Inoue et al., 2004]. Therefore, the generated product in the present family could interfere with the normal allele, in a dominant-negative manner. This distinct mechanism could explain the differences observed in the family when compared to the other reported cases, once triggering or escaping NMD is known to cause different phenotypes, besides contributing to a variable phenotypic expressivity [Inoue et al., 2004]. On the other hand, residual function of the normal *ALX4* allele

could be an explanation for preventing the present patients from developing the ALX4-related FNDAG, the severe end of the ALX4-spectrum disorders, originally described only in patients with homozygous loss-of-function mutations.

In summary, we have described two related individuals with a heterozygous mutation in *ALX4* presenting a distinct phenotype of FND that may be placed in the middle of the severity scale of the ALX4-spectrum disorders. We suggest that the loss of the ALX4 OAR domain with the maintenance of the homeodomain impairs the function of the normal allele in a dominant-negative effect, explaining the increased severity when compared to patients with heterozygous mutations. This report strengths the argument that mild FND phenotypes could be caused by *ALX4* gene mutations, contributing to uncover the etiology of this heterogeneous group of disorders.

ACKNOWLEDGMENTS

We would like to thank CEPID/FAPESP, CNPq for the financial support.

REFERENCES

Brouwer A, ten Berge D, Wiegerinck R, Meijlink F. 2003. The OAR/aristaless domain of the homeodomain protein Cart1 has an attenuating role in vivo. Mech Dev 120:241–252.

Gentile M, Wuyts W, Grittani S, Di Carlo A, Cariola F, Verdyck P, Margari L, Perniola T, Buonadonna AL. 2004. Clinical, cytogenetic, and molecular characterization of a patient with a de novo interstitial 22q12 duplication. Am J Med Genet Part A 127A:186–190.

Inoue K, Khajavi M, Ohyama T, Hirabayashi S, Wilson J, Reggin JD, Mancias P, Butler IJ, Wilkinson MF, Wegner M, Lupski JR. 2004. Molecular mechanism for distinct neurological phenotypes conveyed by allelic truncating mutations. Nat Genet 36:361–369.

Kayserili H, Uz E, Niessen C, Vargel I, Alanay Y, Tuncbilek G, Yigit G, Uyguner O, Candan S, Okur H, Kaygin S, Balci S, Mavili E, Alikasifoglu M, Haase I, Wollnik B, Akarsu NA. 2009. ALX4 dysfunction disrupts craniofacial and epidermal development. Hum Mol Genet 18: 4357–4366.

Kayserili H, Altunoglu U, Ozgur H, Basaran S, Uyguner ZO. 2012. Mild nasal malformations and parietal foramina caused by homozygous ALX4 mutations. Am J Med Genet Part A 158A:236–244.

Mavrogiannis LA, Antonopoulou I, Baxova A, Kutilek S, Kim CA, Sugayama SM, Salamanca A, Wall SA, Morriss-Kay GM, Wilkie AO. 2001. Haploinsufficiency of the human homeobox gene ALX4 causes skull ossification defects. Nat Genet 27:17–18.

Mavrogiannis LA, Taylor IB, Davies SJ, Ramos FJ, Olivares JL, Wilkie AO. 2006. Enlarged parietal foramina caused by mutations in the homeobox genes ALX4 and MS X2: from genotype to phenotype. Eur J Hum Genet 14:151–158.

McGonnell IM, Graham A, Richardson J, Fish JL, Depew MJ, Dee CT, Holland PW, Takahashi T. 2011. Evolution of the Alx homeobox gene family: Parallel retention and independent loss of the vertebrate Alx3 gene. Evol Dev 13:343–351.

McKenzie O, Ponte I, Mangelsdorf M, Finnis M, Colasante G, Shoubridge C, Stifani S, Gécz J, Broccoli V. 2007. Aristaless-related homeobox gene, the gene responsible for West syndrome and related disorders, is a Groucho/transducin-like enhancer of split dependent transcriptional repressor. Neuroscience 146:236–247.

Sedano HO, Gorlin RJ. 1988. Frontonasal malformation as a field defect and in syndromic associations. Oral Surg Oral Med Oral Pathol 65:704–710.

Twigg SR, Versnel SL, Nürnberg G, Lees MM, Bhat M, Hammond P, Hennekam RC, Hoogeboom AJ, Hurst JA, Johnson D, Robinson AA, Scambler PJ, Gerrelli D, Nürnberg P, Mathijssen IM, Wilkie AO. 2009. Frontorhiny, a distinctive presentation of frontonasal dysplasia caused by recessive mutations in the ALX3 homeobox gene. Am J Hum Genet 84:698–705.

Uz E, Alanay Y, Aktas D, Vargel I, Gucer S, Tuncbilek G, von Eggeling F, Yilmaz E, Deren O, Posorski N, Ozdag H, Liehr T, Balci S, Alikasifoglu M, Wollnik B, Akarsu NA. 2010. Disruption of ALX1 causes extreme microphthalmia and severe facial clefting: Expanding the spectrum of autosomal-recessive ALX-related frontonasal dysplasia. Am J Hum Genet 86:789–796.

Wieland I, Jakubiczka S, Muschke P, Cohen M, Thiele H, Gerlach KL, Adams RH, Wieacker P. 2004. Mutations of the ephrin-B1 gene cause craniofrontonasal syndrome. Am J Hum Genet 74:1209–1215.

Wuyts W, Cleiren E, Homfray T, Rasore-Quartino A, Vanhoenacker F, Van Hul W. 2000. The ALX4 homeobox gene is mutated in patients with ossification defects of the skull (foramina parietalia permagna, OMIM 168500). J Med Genet 37:916–920.

IV. Nova Mutação em Homozigose Causando Fenótipo de Displasia Frontonasal Relacionada a *ALX1*

Novel homozygous mutation causing *ALX1*-related frontonasal dysplasia phenotype

Rodrigues MG[1], Bertola DR[1,2], Alonso, N.[3], Passos-Bueno MR[1]

[1] Departamento de Genética e Biologia Evolutiva, Instituto de Biociências, Universidade de São Paulo, São Paulo, Brazil.
[2] Instituto da Criança, Hospital das Clínicas, Faculdade de Medicina, Universidade de São Paulo, São Paulo, Brazil.
[3] Departamento de Cirurgia Plástica, Hospital das Clínicas, Faculdade de Medicina, Universidade de São Paulo, São Paulo, Brazil.

Resumo

Displasia frontonasal (DFN) é uma desordem heterogênea caracterizada por dois ou mais dos seguintes sinais clínicos: hipertelorismo ocular, base nasal larga, fissura facial mediana afetando o nariz e/ou lábio superior e palato, fissura uni ou bilateral da asa nasal, ausência de formação de ponta nasal, crânio anterior bífido oculto e implantação em "V" dos cabelos na fronte. DFN compreende um amplo espectro de fenótipos, incluindo a forma autossômica recessiva caracterizada por microftalmia extrema e fissura facial grave que foi recentemente descrita como sendo causada por mutações no gene *ALX1*. Até o momento, há apenas duas famílias descritas com mutação em *ALX1.* Aqui, nós relatamos o primeiro caso brasileiro conhecido deste tipo de DFN, que é clinicamente muito similar aos casos anteriores, exceto pela ausência de atraso de desenvolvimento e deficiência intelectual. O diagnóstico de DFN relacionada a *ALX1* foi confirmado pela existência de uma nova mutação *frameshift* no *ALX1*. Os achados clínicos e molecular do nosso paciente corroboram o papel crucial, específico e não redundante do *ALX1* no início do desenvolvimento craniofacial humano. O fato de nosso paciente não apresentar nenhum tipo de atraso de

desenvolvimento pode ser importante para delinear as funções do *ALX1*, além de trazer novo conhecimento quanto às consequências clínicas de mutações neste gene.

Abstract

Frontonasal dysplasia (FND) is a heterogeneous disorder characterized by two or more of the following clinical features: true ocular hypertelorism; broadening of the nasal root; median facial cleft affecting the nose and/or upper lip and palate; unilateral or bilateral clefting of the alae nasi; lack of formation of the nasal tip; anterior cranium bifidum occultum; and a V-shaped or widow's peak frontal hairline. FND comprises a wide spectrum of phenotypes, including an autosomal-recessive form characterized by extreme microphthalmia and severe facial clefting that was recently described to be caused by mutations in *ALX1* gene. There are only two FND families so far reported with mutations in *ALX1*. Here, we report on the first known Brazilian case with this type of FND. However, in contrast to the previous cases, this case did not present developmental delay or intellectual disability. The putative diagnosis of *ALX1*-related FND was confirmed by the finding of a novel homozygous frameshift mutation in *ALX1*. Molecular and clinical findings of our patient corroborate a crucial, specific, and non-redundant role of *ALX1* in early human craniofacial development. The fact that our patient does not present any kind of developmental delay can be important to delineate *ALX1* functions, besides adding new insights into clinical consequences of its mutations.

Introduction

Frontonasal dysplasia (FND) is a heterogeneous disorder characterized by two or more of the following clinical features: true ocular hypertelorism; broadening of the nasal root; median facial

cleft affecting the nose and/or upper lip and palate; unilateral or bilateral clefting of the alae nasi; lack of formation of the nasal tip; anterior cranium bifidum occultum; and a V-shaped or widow's peak frontal hairline [Sedano and Gorlin, 1988]. FND comprises a wide spectrum of phenotypes and can occur alone or with additional clinical findings, as seen in craniofrontonasal dysplasia (OMIM 304110), oculoauriculofrontonasal syndrome (OMIM 601452), frontofacionasal dysplasia (OMIM 229400), acromelic frontonasal dysostosis (OMIM 603671), acrofrontofacionasal dysostosis 1 and 2 (OMIM 201180, OMIM 239710), among other disorders.

Most of FND cases are sporadic and have no identified cause [Twigg et al., 2009]. At present, mutations in four genes have been related to FND phenotypes: *EFNB1,* in X-linked craniofrontonasal dysplasia [Wieland et al., 2004], and *ALX* homeobox gene family in recessive forms of FNDs - *ALX3* in frontorhiny [Twigg et al., 2009], *ALX1* in extreme microphthalmia and severe facial clefting [Uz et al., 2010], and *ALX4* in both FND with alopecia and genital abnormality [Kayserili et al., 2009] and a mild FND phenotype [Kayserili et al., 2012]. Recently, we reported the first case of vertical transmission of a FND phenotype due to a heterozygous mutation in *ALX4* [Bertola et al., 2013], and suggested that this may occur by a dominant-negative effect.

Here, we report on the first known Brazilian case of extreme microphthalmia and severe facial clefting caused by a novel homozygous mutation in *ALX1* gene.

Patient and Methods

The Local Ethics Committee at Universidade de São Paulo approved this study, and patient's family signed written informed consent.

Patient

The proband (Figure 1), a 10-year-old male, is the second child of consanguineous parents (F = 1/32) with no history of similar cases in family. He was born at term, by vaginal delivery, after an uneventful pregnancy, with BW of 3,800g (50th centile) and BL of 51 cm (50th centile). At birth, bilateral cleft lip and palate associated with eye malformations were observed. At the age of 1 month, according to a clinical evaluation by a craniofacial surgeon, he had cleft lip and palate with bilateral severe deformity of the nose, bilateral absence of upper and lower eyelids, bilateral dermoid in the eye, ocular bulb completely abnormal in size and shape on both sides, altered hairline and absence of eyebrows. Cranial tomography showed no anomalies in encephalic region. He was submitted to several surgical corrections of the facial anomalies. He was referred to the Genetics Unit because of craniofacial dysmorphisms. He was evaluated by us at the age of 7 years and 2 months showing a weight of 27.4 kg (75-95th centile), height of 131.5 cm (50th centile), OFC of 50 cm (above 95th centile); craniofacial features comprised: hypertelorism, depression in the frontal region, broad nose with absence of nasal tip, severe bilateral microphtalmia, surgical scar of correction of bilateral cleft lip and cleft palate, and large and prominent ears. Complementary exams, including echocardiogram, spine X-rays and abdominal ultrassound disclosed normal results. Ophthalmological evaluation showed severe microphthalmia and keratinization of the conjunctiva and cornea. He evolved with normal developmental milestones and, at the age of 9 years, he attends regular school and learned Braille.

We concluded that the craniofacial features presented by this patient were suggestive of *ALX1*-related FND, and this specific gene was selected to be sequenced.

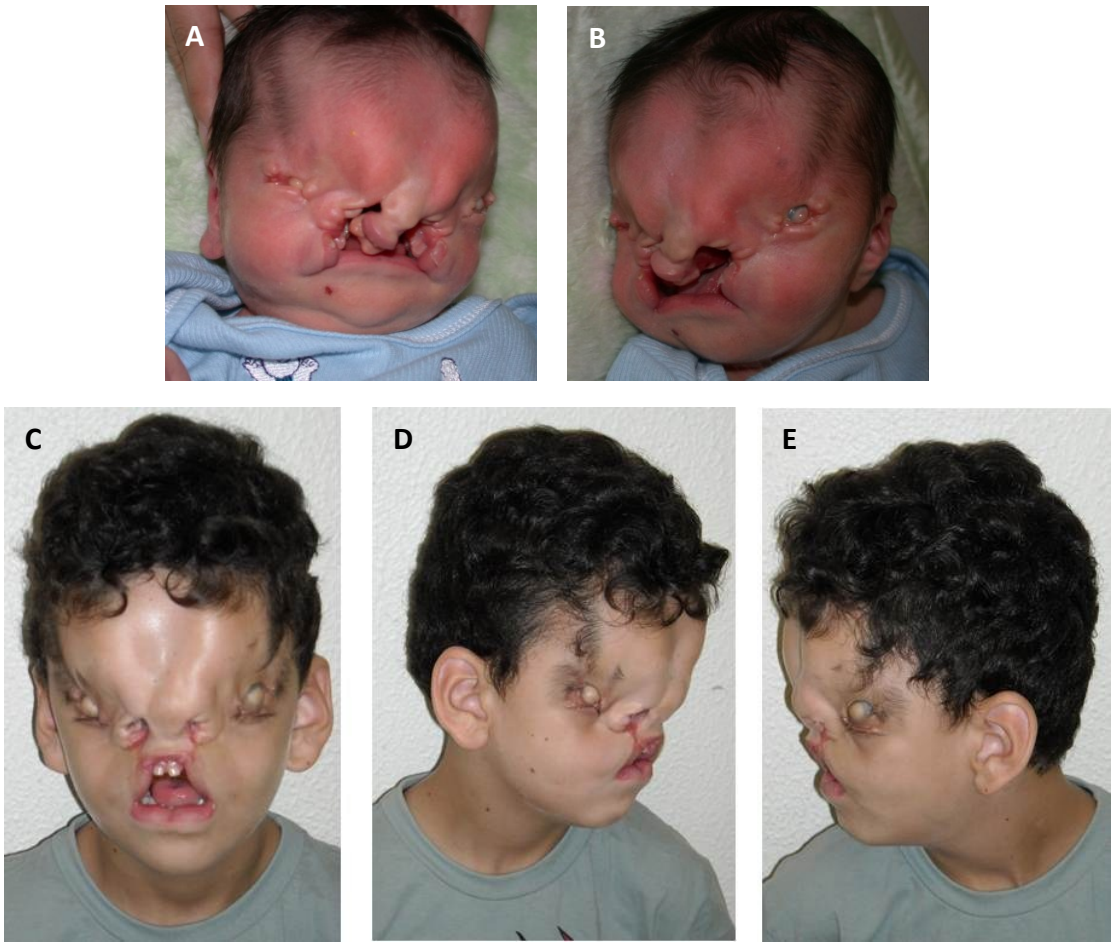

Figure 1. Frontal and lateral views of the patient. A and B) At the age of 1 month. C, D and E) At the age of 7 years and 2 months, after surgical procedures to correct cleft lip and palate and initiation of nasal reconstruction, besides orthodontic treatment with removable appliances.

Methods

We amplified the four *ALX1* exons of the proband and his parents and performed Sanger sequencing. The primers and conditions used were described elsewhere [Twigg et al., 2009]. Bi-directional sequencing was performed using the BigDye Terminator v3.1 Cycle Sequencing kit, (Applied Biosystems, Carlsbad, California, USA) on the ABI PRISM® 3037 DNA Analyzer (Applied Biosystems, Carlsbad, California, USA) sequencer.

Results

Exon sequencing of *ALX1* disclosed a novel homozygous mutation on the proband: p.Lys132Asnfs*13 (c.396del; cDNA reference: NM_006982.2; protein reference: NP_008913.2). Both parents were heterozygous for the mutation (Figure 2).

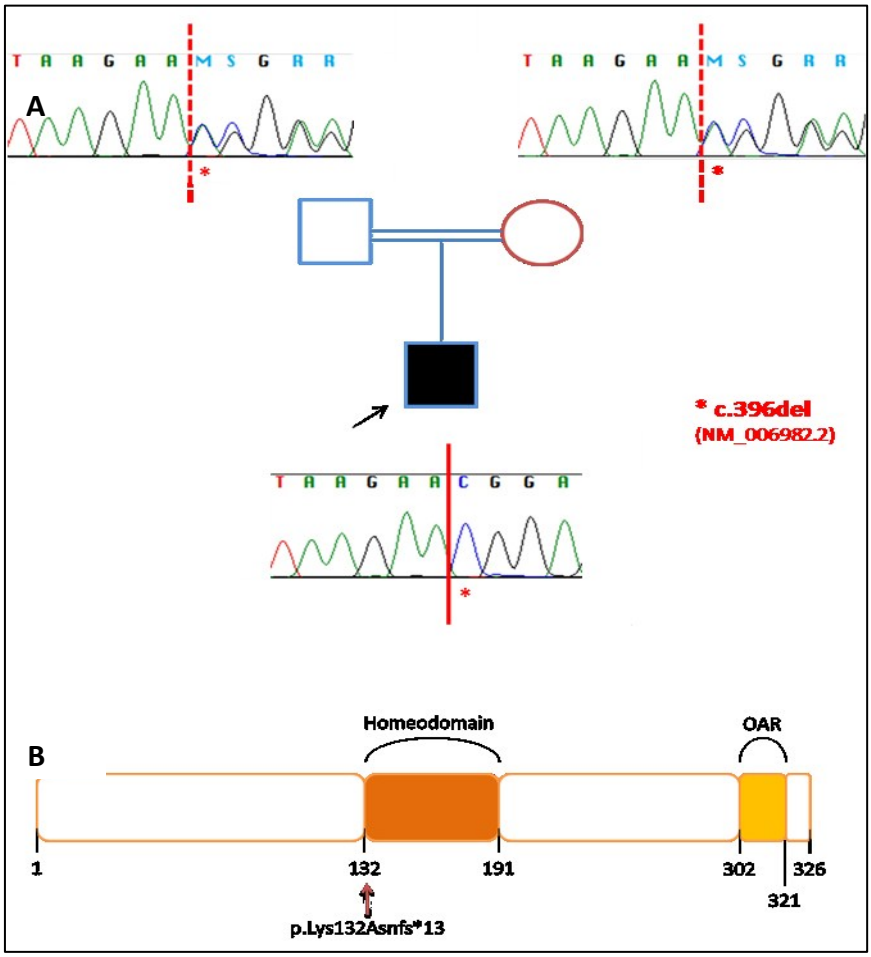

Figure 2. A) Family pedigree: Observe that the proband is homozygous and his parents are heterozygous for the frameshift mutation in *ALX1*. B) ALX1 protein scheme; arrow shows the localizations of the mutation (p.Lys132Asnfs*13).

Discussion

We are here describing a patient with severe microphtalmia and facial clefting very similar clinically to the two *ALX1*-related FND cases of Turkish ancestry [Uz et al., 2010], except by the lack of

developmental delay. The patient here reported shows normal neuropsychological and motor development, as well as normal speech ability. The putative diagnosis of *ALX1*-related FND was confirmed by the finding of a homozygous frameshift mutation. This mutation, located in the second of the four exons of *ALX1,* is predicted to lead to a premature stop codon in position 432 of coding sequence, while in wild type it occurs in position 981. The altered RNA is predicted to be degraded by nonsense mediated decay (NMD), with consequent loss of *ALX1* function. This mutation represents the third *ALX1*-related FND case after the two described by Uz et al. [2010], where patients from one family harbored a large deletion encompassing *ALX1*, and the other patient, an affected girl, carried a homozygous mutation (c.531+1G>A). Therefore, all the mutations so far identified in *ALX1* are predicted to lead to loss of its gene function.

Mouse *Alx1* null mutant mice show severe defects of the cranial skeleton, but apparently as a secondary consequence of a neural tube closure defect, which is not found in human cases [Zhao et al., 1996]. Gene functions of *Alx1, Alx3* and *Alx4* appear to be partially redundant in mouse [Zhao et al., 1996; Beverdam et al., 2001; McGonnell, 2011], and phenotypes of mutated mice do not show much correspondence with the human cases. Recently, Dee et al. [2013] showed that morpholino knock-down of zebrafish *Alx1* expression leads to a severe craniofacial phenotype, including loss of the facial cartilages and defective ocular development, therefore being comparable to the defects seen on *ALX1*-related FND. They demonstrated for the first time that *Alx1* is required for normal migration of the cranial neural crest cells into the frontonasal primordial. As this function showed to be specific to *Alx1*, they proposed that its nonredundant role likely explains the marked clinical severity of *ALX1* mutations in humans in comparison to mutations in *ALX3* or *ALX4*.

To our knowledge, this is the first *ALX1*-related FND patient with normal neurodevelopment. Craniofacial findings of our patient are very similar to the two first reported cases, thus corroborating a crucial, specific and non-redundant role of *ALX1* in early human craniofacial development. The fact that our patient does not present any kind of developmental delay can be important to delineate *ALX1* functions, besides adding new insights into clinical consequences of its mutations.

Acknowledgements

We would like to thank the patient and his family for their participation in this study. We also thank CEPID/FAPESP, CNPq and Capes for the financial support.

Conflict of Interest: Authors declare to have no conflicts of interest.

References

Bertola DR, Rodrigues MG, Quaio CR, Kim CA, Passos-Bueno MR. Vertical transmission of a frontonasal phenotype caused by a novel ALX4 mutation.Am J Med Genet A. 2013 Mar;161(3):600-4. doi: 10.1002/ajmg.a.35762.

Beverdam A, Brouwer A, Reijnen M, Korving J, Meijlink F. Severe nasal clefting and abnormal embryonic apoptosis in Alx3/Alx4 double mutant mice. Development. 2001 Oct;128(20):3975-86.

Dee CT, Szymoniuk CR, Mills PE, Takahashi T. Defective neural crest migration revealed by a Zebrafish model of Alx1-related frontonasal dysplasia. Hum Mol Genet. 2013 Jan 15;22(2):239-51. doi: 10.1093/hmg/dds423.

Kayserili H, Altunoglu U, Ozgur H, Basaran S, Uyguner ZO. Mild nasal malformations and parietal foramina caused by homozygous ALX4 mutations. Am J Med Genet A. 2012 Jan;158A(1):236-44.

Kayserili H, Uz E, Niessen C, Vargel I, Alanay Y, Tuncbilek G, Yigit G, Uyguner O, Candan S, Okur H, Kaygin S, Balci S, Mavili E, Alikasifoglu M, Haase I, Wollnik B, Akarsu NA. ALX4 dysfunction disrupts craniofacial and epidermal development. Hum Mol Genet. 2009 Nov; 18(22):4357–66.

McGonnell IM, Graham A, Richardson J, Fish JL, Depew MJ, Dee CT, Holland PW, Takahashi T. Evolution of the Alx homeobox gene family: parallel retention and independent loss of the vertebrate Alx3 gene. Evol Dev. 2011 Jul-Aug;13(4):343-51. doi: 10.1111/j.1525-142X.2011.00489.x.

Sedano HO, Gorlin RJ. 1988. Frontonasal malformation as a field defect and in syndromic associations. Oral Surg Oral Med Oral Pathol 65:704–710.

Twigg SRF, Versnel SL, Nürnberg G, Lees MM, Bhat M, Hammond P, Hennekam RCM, Hoogeboom AJM, Hurst JA, Johnson D, Robinson AA, Scambler PJ, Gerrelli D, Nürnberg P, Mathijssen IMJ, Wilkie AOM. Frontorhiny, a Distinctive Presentation of Frontonasal Dysplasia Caused by Recessive Mutations in the ALX3 Homeobox Gene. The American Journal of Human Genetics. 2009 May; 84:698–705.

Uz E, Alanay Y, Aktas D, Vargel I, Gucer S, Tuncbilek G, Eggeling FV, Yilmaz E, Deren O, Posorski N, Ozdag H, Liehr T, Balci S, Alikasifoglu M, Wollnik B, Akarsu NA. Disruption of ALX1 Causes Extreme Microphthalmia and Severe Facial Clefting: Expanding the Spectrum of Autosomal-Recessive ALX-Related Frontonasal Dysplasia. AmJ Hum Genet. 2010 May; 86:789–96.

Wieland I, Jakubiczka S, Muschke P, Cohen M, Thiele H, Gerlach KL, Adams RH, Wieacker P. Mutations of the ephrin-B1 gene cause craniofrontonasal syndrome. Am J Hum Genet. 2004 Jun; 74(6):1209-15.

Zhao Q, Behringer RR, de Crombrugghe B. Prenatal folic acid treatment suppresses acrania and meroanencephaly in mice mutant for the Cart1 homeobox gene. Nat Genet. 1996 Jul;13(3):275-83.

V. Caso de Displasia Frontonasal e Outras Anomalias em um Menino com ins(12;4) *De Novo* Aparentemente Balanceada

---

A case of frontonasal dysplasia with other anomalies in a boy with an apparently balanced *de novo* ins(12;4)

Rodrigues MG[1], Zechi-Ceide RM[2], Fonseca AC[1], Vianna-Morgante AM[1], Richieri-Costa A[2], Guion-Almeida ML[2], Passos-Bueno MR[1]

[1] Departamento de Genética e Biologia Evolutiva, Instituto de Biociências, Universidade de São Paulo, São Paulo, Brazil.
[2] Departamento de Genética Clínica, Hospital de Reabilitação de Anomalias Craniofaciais (HRAC), Universidade de São Paulo, Bauru, Brazil.

Resumo

Displasia frontonasal (DFN) é um defeito de campo de desenvolvimento caracterizado pela presença de dois ou mais dos seguintes sinais clínicos: hipertelorismo ocular, base nasal larga, fissura facial mediana afetando o nariz e/ou lábio superior e palato, fissura uni ou bilateral da asa nasal, ausência de formação de ponta nasal, crânio anterior bífido oculto e implantação em "V" dos cabelos na fronte. Foi demonstrado que mutações em *EFNB1, ALX1, ALX3 e ALX4* são causadoras de alguns fenótipos com DFN; no entanto, a etiologia da maioria dos casos de DFN permanece desconhecida. A identificação de pacientes com rearranjos cromossômicos balanceados *de novo* pode trazer novos conhecimentos quanto aos mecanismos causativos de desordens clínicas, uma vez que os pontos de quebra podem romper regiões codificadoras ou elementos regulatórios de genes que podem contribuir com o fenótipo. Aqui, nós descrevemos o caso de um menino com DFN, atraso de desenvolvimento e outras alterações craniofaciais e genitais que apresenta um rearranjo cromossômico *de novo* aparentemente balanceado envolvendo os cromossomos 4 e 12. A análise dos pontos de quebra revelou o possível rompimento de três genes: *DTHD1*, *ARAP2* e *CAND1*. Nós acreditamos que *ARAP2* e especialmente *CAND1* são candidatos plausíveis para explicar a clínica do

paciente. Entretanto, outros estudos são necessários para investigar o possível envolvimento desses genes na embriogênese humana, assim como suas implicações em fenótipos de DFN.

Abstract

Frontonasal dysplasia (FND) is a developmental field defect characterized by the presence of two or more of the following clinical features: true ocular hypertelorism, broadening of the nasal root, median facial cleft affecting the nose and/or upper lip and palate, unilateral or bilateral clefting of the alae nasi, lack of formation of the nasal tip, anterior cranium bifidum occultum, and a V-shaped or widow's peak frontal. It has been demonstrated that mutations in *EFNB1, ALX1, ALX3* and *ALX4* are causative of some phenotypes with FND; however, the etiology of most FND cases remains unknown. Identification of patients with balanced *de novo* chromosome rearrangements can bring new insights to the causative mechanisms of disorders, as the breakpoints can disrupt coding regions or regulatory elements of genes that might contribute to the phenotype. Here we report on a boy with FND, developmental delay, and other craniofacial and genital signs who carries an apparently balanced *de novo* chromosomal rearrangement involving chromosomes 4 and 12. Analysis of the breakpoints revealed the possible disruption of three genes: *DTHD1*, *ARAP2* and *CAND1.* We believe that *ARAP2* and especially *CAND1* are plausible candidate genes to explain the findings presented by the patient. Nonetheless, other studies are necessary to investigate the possible involvement of these genes on human embryogenesis, as well as their implication on phenotypes with FND.

Introduction

Frontonasal dysplasia (FND) is a developmental field defect characterized by the presence of two or more of the following clinical features: true ocular hypertelorism, broadening of the nasal root, median facial cleft affecting the nose and/or upper lip and palate, unilateral or bilateral clefting of the alae nasi, lack of formation of the nasal tip, anterior cranium bifidum occultum, and a V-shaped or widow's peak frontal [Sedano and Gorlin, 1988]. FND is believed to result from the abnormal development of the frontonasal prominence during craniofacial embryogenesis, leading to expanded facial midline, and can occur alone or with other clinical findings [Cohen, 1979; Wu et al., 2007; Guion-Almeida and Richieri-Costa, 2009]. Although there are some familial cases, most of the reported cases are sporadic. The degree of genetic contribution to FND has been argued by the lack of concordance among monozygotic twins [Mohammed et al., 2004], a finding that could actually be explained by different genetic and epigenetic mechanisms, such as somatic mosaicism in early embryogenesis (e.g. due to chromosomal mosaicism or post-zygotic gene mutation), differential DNA methylation or genomic imprinting, among others [Silva et al., 2010]. Most recently, it has been demonstrated that mutations in *EFNB1, ALX1 (CART1), ALX3* and *ALX4* are causative of X-linked (*EFNB1*), autosomal recessive (ALX1, 3 and 4) and autosomal dominant (ALX4) phenotypes of FND [Wieland et al., 2004; Twigg et al., 2004; Twigg et al., 2009; Kayserili et al., 2009; Uz et al., 2010; Bertola et al., 2013]. Despite these advances, the causative mechanism of most FND cases remains unknown.

Identification of patients with balanced *de novo* chromosomal rearrangements can bring new insights to the etiology of disorders, as the breakpoints can disrupt coding regions or regulatory elements of genes that might contribute to the phenotype. Here we report on a boy with FND, developmental delay, and other craniofacial and genital signs who carries an apparently balanced *de novo* chromosomal rearrangement involving chromosomes 4 and 12. Several genomic molecular

analysis have been performed in order to investigate the underlying genetic mechanisms leading to his phenotype.

Patient and Methods

The Ethics Committee at the Hospital de Reabilitação de Anomalias Craniofaciais (HRAC), Universidade de São Paulo, approved this study, and patient's family signed written informed consent.

Patient

The patient, a male, was the 2nd child of a healthy 17-year-old G3P3 mother and a nonconsanguineous 20-year-old healthy father. His two sisters are healthy, and no familial history has been observed. Pregnancy was uneventful with no exposure to toxic, traumatic, infectious agents or radiation. Delivery was by cesarean section at term. Birthweight was 3,000g (10th centile). He was first evaluated by the Clinical Genetics Department at HRAC at the age of 2-year-old, and showed ocular hypertelorism, telecanthus, downslanting palpebral fissures, low-set and posteriorly angulated ears, broad nasal root, encephalocele, motor and speech delay, coronal hypospadia, and ascending testis. Clinical examination at 8.5 years showed a weight of 24.2 kg (25th centile), height of 129 cm (>50th centile), OFC of 54.5 cm (50th centile), inner canthal distance of 5.6 cm (>97th centile), and outer canthal distance of 10.8 cm (>97th centile). Neuropsychological development was delayed. Speech therapist evaluation revealed velopharyngeal dysfunction. A CT scan of the cranium disclosed hypertelorism, pseudo-encephalocele and vertical skull base.

Methods

GTG-banding analysis was performed on metaphases from cultured peripheral blood lymphocytes. Direct sequencing of coding and splicing regions of *EFNB1*, *ALX1*, *ALX3* and *AXL4* genes were performed using ABI PRISM® BigDye® Terminator v3.1 Cycle Sequencing Kit, on ABI 3730 DNA Analyser (both from Applied Biosystems, Foster City, CA). Primer sequences and PCR conditions are described elsewhere [Twigg et al., 2004; Twigg et al., 2009]. Fluorescent in situ hybridization (FISH) was performed with BACs selected on the large insert clones set provided by the Wellcome Trust Sanger Institute (UK), and information regarding the full set is available at the Sanger Institute mapping database site, Ensembl Genome Browser (Ensembl - http://www.ensembl.org/ - hg19 - *1Mb clone set*). Probes were labeled with biotin-14-dATP or digoxigenin-11-dUTP by nick translation (Bio/Dig-Nick Translation kits; Roche, Mannheim, Germany) and visualized with fluorescein isothiocyanate- (FITC) or rhodamine-conjugated antibodies; chromosomes were counterstained with 4,6-diamidine-2-phenylindole.

For CNV analysis, we performed two independent experiments: an array-based comparative genomic hybridization (array-CGH) and a single nucleotide polymorphism array (SNP-array). For a-CGH experiment, we used Agilent SurePrint G3 Human CGH Microarrays 4×180K (Agilent Technologies Inc., Santa Clara, CA), according to the manufacturer's protocol. Microarray images were processed by Feature Extraction 9.5, and data were analyzed with Agilent Genomic Workbench 7.0 (both from Agilent). Identification of aberrant copy number segments was based on the ADM-2 algorithm, with default settings (threshold log2 ratio of 0.2 or 1.14 was used for gain or high copy gain, and −0.23 and −1.14 used for loss and homozygous loss, respectively); significance threshold was set on 7 and we considered at least three consecutive probes for calling a segment. For SNP-array experiment, we used Affymetrix GeneChip Human Mapping 500K Array Set (Affymetrix, Santa Clara, CA), according to the standard protocol. Microarray images were processed by GeneChip Command Console Software (Affymetrix, Santa Clara, CA), and the minimum quality of hybridization

accepted, measured by QC Call Rate, was 95.0. For analysis, we used the softwares: Genotyping Console (Affymetrix , Santa Clara, CA), PennCNV [Wang et al., 2007; Wang and Bucan, 2008] and dChip [Li and Wong, 2001; Lin et al., 2004], with default settings. We only considered CNVs detected by at least two different softwares.

Results

As can be seen on figure 1, G-banded chromosome analysis showed an apparently balanced rearrangement: 46, XY ins(12;4)(q14.3;p15.33p14). Parents had normal G-banded karyotypes. Sequencing analysis of *EFNB1*, *ALX1*, *ALX3* and *ALX4* genes did not reveal any pathogenic change, thus excluding mutations in the genes already related to FND as causative of patient's phenotype.

Array-CGH and SNP-array analysis revealed only CNVs already seen in apparently health people (Table 1), according to the Database of Genomic Variants (DGV - http://projects.tcag.ca/variation/). No CNV was observed on chromosomes 4 and 12, suggesting that there might be no large deletion at the breakpoint regions. We have therefore put an effort to characterize the breakpoints at these two chromosomes.

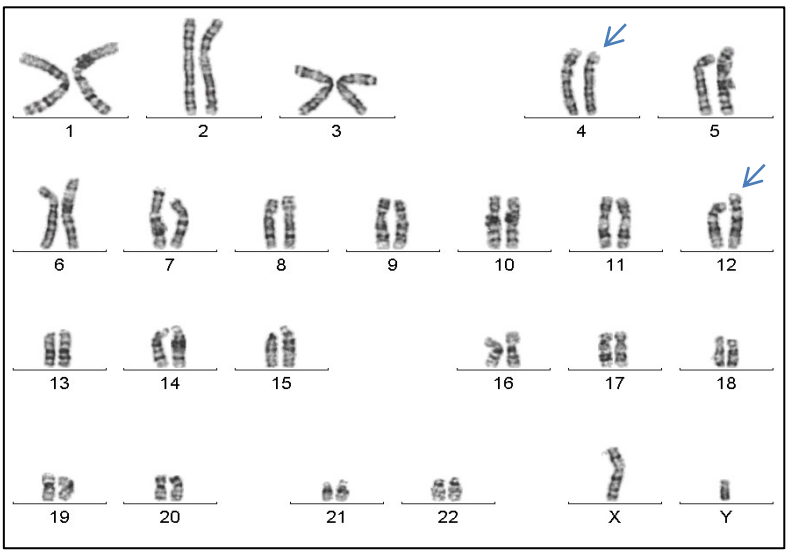

Figure 1 – Karyotype of the patient showing an apparently balanced 46, XY ins(12;4)(q14.3;p15.33p14). Arrows indicate the derivative chromosomes.

Table 1. Copy number variations (CNVs) detected on patient's genome. All were seen on healthy individuals of the Database of Genomic Variants (DGV - http://projects.tcag.ca/variation/). SNP-array detected three CNVs while array-CGH detected six, including the ones revealed by the former (highlighted in gray).

Chromosome	Chromosome Location	Type	~Size (Kb)	Linear Position Start – End (hg18)	Platform of Detection
1	p21.1	Loss	193	102,429,242-102,622,370	Array-CGH SNP-array
2	q37.3	Loss	162,5	242,514,593-242,677,125	Array-CGH
3	q14.12	Loss	44	45,702,380-45,746,729	Array-CGH
10	q26.3	Loss	123,5	135,104,029-135,227,522	Array-CGH SNP-array
15	q13.3	Loss	423	29,559,689-29,982,899	Array-CGH SNP-array
16	p11.2	Loss	1269	32,379,126-33,647,915	Array-CGH

FISH probes RP11-168E17 (chr4: 11,821,680-11,981,455) and RP11-103J17 (chr4: 36999471-37160744), highlighted in red on scheme of figure 2B, produced signals on the normal chromosome 4 and on the derivative chromosome der(4) (Fig. 2C and 2D). FISH probes RP11-22A3 (chr4: 12,802,254-12,976,581) and RP11-135M12 (chr4: 35,531,424-35,722,887), highlighted in green on the same scheme, hybridized to the normal chromosome 4 and to the derivative chromosome der(12) (Fig. 2C, 2D and 2E). Altogether, these results indicated that the region between the two latter probes was deleted on the derivative chromosome der(4) and inserted on the derivative chromosome der(12), and that the breakpoints on chromosome 4 were localized between probes RP11-168E17 and RP11-22A3 and between probes RP11-135M12 and RP11-103J17 (blue arrows on scheme of figure 2B). FISH probes RP11-328H16 (chr12: 67,223,818-67,406,659) and RP11-542B15 (chr12: 67,791,847-67,963,496), highlighted in green on scheme of figure 3A, hybridized to the normal chromosome 12 and to both sides of the region of chromosome 4 inserted on the derivative chromosome der(12) (Fig. 3B and 3C), indicating that the breakpoint on chromosome 12 was mapped between them (blue arrow on scheme of figure 3A). As can be concluded by observing FISH hybridization images on figures 2 and 3, the region of chromosome 4 inserted on the derivative

chromosome der(12) is inverted. In summary, FISH analysis revealed that the breakpoint on chromosome 12 was mapped to an approximately 0.7-Mb interval (chr12:67,223,818-67,963,496); and on chromosome 4, the proximal breakpoint was mapped to an approximately 1.6-Mb interval (chr4:35,531,424-37,160,744), and the distal breakpoint to an approximately 1.1-Mb segment (chr4:11,821,680-12,976,581) (arrows on schemes of figures 2A, 2B and 3A).

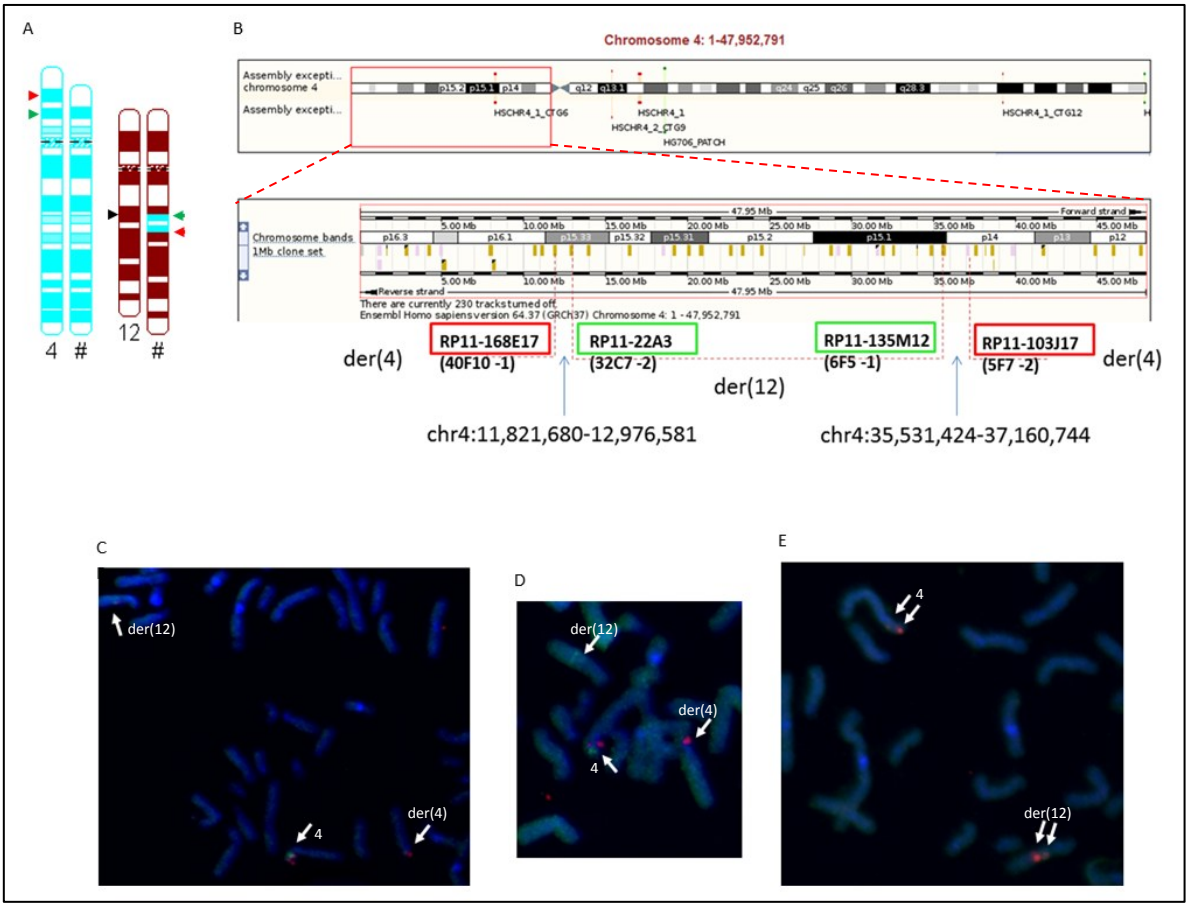

Figure 2 - A: Scheme of the rearrangement involving chromosomes 4 and 12 (adapted from CyDAS site, http://www.cydas.org/OnlineAnalysis/). B: Scheme of chromosome 4; zoom in the 4p arm showing the approximate regions of breakpoints (blue arrows). Highlighted, probes that define such regions (adapted from the Ensembl site, link: http://www.ensembl.org/Homo_sapiens/Location/Overview?r=4:1-47,952,791). C: Image of FISH with probe RP11-168E17 in red and RP11-135M12 green. D: Image of FISH with probe RP11-22A3 in green and probe RP11-103J17 in red. E: Image of FISH with the probe RP11-135M12 green (seen as a weaker signal) and probe RP11-22A3 in red. Together, C, D and E corroborate schemes shown in A and B.

Based on FISH results, we investigated the mapped regions *in silico* (University of California, Santa Cruz, UCSC Genome Browser - http://genome.ucsc.edu/ - GRCh37/hg19). The distal breakpoint region on chromosome 4 does not encompass any known gene, while the proximal breakpoint region on this chromosome encompasses *DTHD1* and *ARAP2* genes, and the breakpoint region on chromosome 12 encompasses *CAND1* gene.

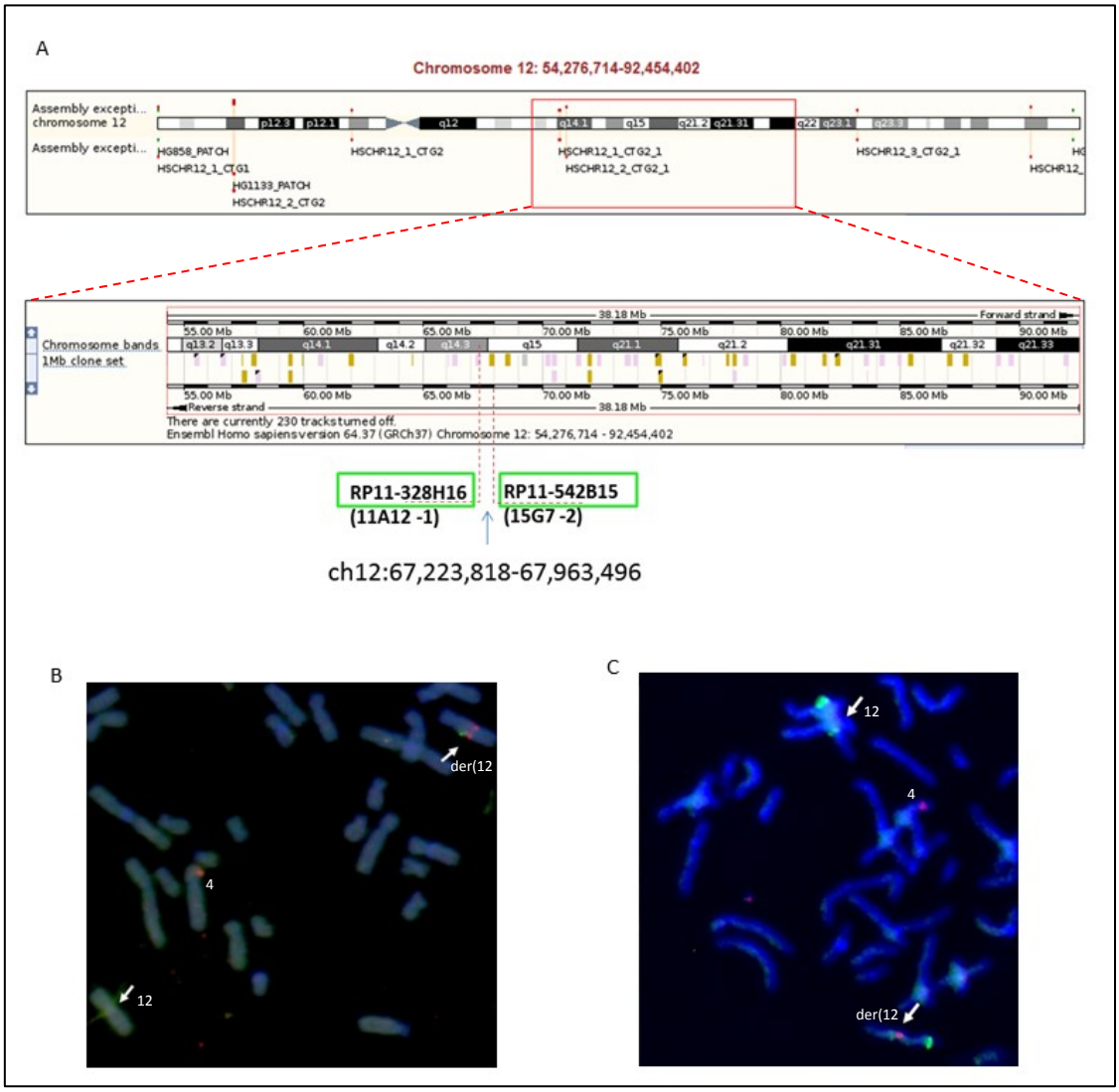

Figure 2 - A: Scheme of chromosome 12; zoom in the region highlighted in 12q arm, showing the approximate area of the breakpoint (blue arrow). Highlighted, probes that delimit this region (adapted from the Ensembl site, link: http://www.ensembl.org/Homo_sapiens/Location/Overview?r=12:54276714-92454402). B: Image of FISH with probe RP11-328H16 in green and a probe of chromosome 4 in red. C: Image of FISH with probe RP11-542B15 in green (lower signal), a probe of subtelomeric region of the short arm of chromosome 12 also in green (larger signal) and a probe of chromosome 4 in red. Together, B and C confirm the scheme shown in A.

Discussion

Clinical examination revealed that the patient described here has FND as part of his phenotype, as he shows ocular hypertelorism and a broad nasal root. His other findings were not suggestive of any of the syndromes with FND with known etiology (i.e. craniofrontonasal dysplasia and ALXs-related FNDs), what was confirmed by normal sequencing results of the *EFNB1, ALX1, ALX3* and *ALX4* genes. The genital anomalies and developmental delay showed by the patient made Opitz GBBB syndrome (OMIM #300000) to be considered as a possible diagnosis. This midline malformation syndrome is characterized by hypertelorism, hypospadias, cleft lip/palate, laryngotracheoesophageal abnormalities, imperforate anus, developmental delay, and cardiac defects [So et al., 2005]. As many clinical features of the syndrome are not present in our patient, we opted to clinically classify him as FND-like. To our knowledge, the chromosomal rearrangement found in the patient, involving chromosomes 4 and 12, has never been previously reported. Besides, as this rearrangement is *de novo*, it is very likely that it contributes to his phenotype, even though we cannot rule out other mechanisms, including environmental causes.

As CNV analysis did not show any gain or loss on chromosomes 4 and 12, the rearrangement involving them are very likely to be balanced, even though we cannot discard the possibility that the translocation is associated to small deletions or duplications under the resolution of our SNP-array and array-CGH. Anyhow, our molecular analysis of the breakpoints, revealed the possible disruption of three genes: *DTHD1*, *ARAP2* and *CAND1.*

Although virtually nothing is known about the protein encoded by DTHD1 (death domain-containing protein 1), Abu-Safieh et al. [2013] identified by exome sequencing a single nucleotide substitution that abolished the first methionine residue of *DTHD1* full segregating with the phenotype in a family with four affected individuals with autosomal recessive Leber congenital amaurosis (congenital or early-infantile severe retinal dystrophy) and a mild-moderate form of nonspecific muscle dystrophy. Considering the lack of clinical overlap among Leber congenital

amaurosis and the present patient, we believe that disruption of *DTHD1* is unlikely to contribute to the clinical signals observed in our patient.

ARAP2 (ArfGAP with RhoGAP domain, ankyrin repeat and PH domain 2) encodes a protein that is thought to mediate RhoA effects on actin stress fibers and focal adhesions (FAs), affecting the trafficking and/or organization of FA component proteins [Yoon et al., 2006]. FAs are a type of integrin-mediated cell adhesion located at the ends of actin stress fibers, typically generated by interaction with a flat, rigid surface, stimulated by the small GTPase RhoA [Wolfenson et al., 2009; Geiger and Yamada, 2011]. Cell–matrix adhesions are essential for cell migration, tissue organization, and differentiation; as a result, they play central roles in embryonic development, among other biological processes [Berrier and Yamada, 2007; Wolfenson et al., 2009; Geiger and Yamada, 2011]. Thomas et al. [2010] demonstrated that mouse embryos lacking Rac1 in neural crest cells (Rac1/Wnt1-Cre) showed, besides cardiovascular malformations, abnormal craniofacial development culminating in cleft face at E12. Rac1 is a small GTP-binding protein member of the Rho family of small GTPases, and data presented by Chen et al. [2013] support a model where ARAP2 regulates Arf6·GTP and consequently, Rac1·GTP levels to control FAs. They concluded that changes in Arf6 and Rac1 activities are necessary but not sufficient for ARAP2 to promote the growth of FAs, and speculated that ARAP2 has additional functions that are effector in nature to promote or stabilize FAs. Because of the importance of cell–matrix adhesions during embryonic development and the involvement of ARAP2 on FA dynamics, we speculate that *ARAP2* can be a candidate to explain, at least partially, our patient's phenotype.

CAND1 gene encodes cullin-associated and neddylation-dissociated 1 protein. Recent studies indicate that its main function is to catalyze the exchange of substrate receptors of Cullin-RING ubiquitin ligases (CRLs) [Pierce et al., 2013]. CRLs are the largest group of enzyme class that attach ubiquitin specifically to the intended proteins. This modification can be temporarily, as a signaling event, but also can work as a destruction signal preceding their degradation [Olma and Dikic, 2013].

Wu et al. [2013] and Zemla et al. [2013] concluded that yeast Cand1 also has the same exchange functionality as in mammalian cells. Bosu et al. [2010] showed that *Caenorhabditis elegans* cand-1(tm1683) mutant homozygotes exhibit a range of non-penetrant phenotypes, including: arrested late-stage embryos and L2-stage larvae, protruding vulva, slower postembryonic development, reduced numbers of progeny, and defective tail and vulva morphogenesis. Although no disorder has been specifically related to *CAND1* mutations, many human genetic disorders have been found to be caused by errors in protein ubiquitination, e.g. Angelman syndrome, Fanconi anemia, Juvenile recessive Parkinson, among others [Jiang and Beaudet, 2004; Zou et al, 2007]. However, it was the implication of an impairment of the E3 ubiquitin ligase activity of the MID1 protein in Opitz GBBB syndrome that called our attention, since it was considered as a differential diagnosis for our patient. Based on the fact that patient's phenotype described here has overlapping features with Opitz GBBB syndrome, and the disease-causing gene of the X-linked form of this syndrome encodes a protein also involved in ubiquitination, we speculate that disruption of *CAND1* can explain our patient's features, therefore playing a role during human midline embryological development.

Because of not having access to new blood samples from the patient, we were unable to either map the exact locations of the breakpoints or verify possible effects of the chromosomal rearrangement on gene expression or protein function. Despite a-CGH and SNP-array normal results, we are aware of the resolution limit imposed by the methodologies used, and do not discard the existence of a pathogenic gain or loss not detected influencing the phenotype, as well as other types of genetic alterations not possible to be visualized by these methodologies. Although our findings are not conclusive, we believe that *ARAP2* and especially *CAND1* are plausible candidate genes to explain the findings presented by our patient. Nonetheless, other studies are necessary to investigate the possible involvement of these genes on human embryogenesis, as well as their implication on phenotypes with FND.

Acknowledgments

We thank the patient and his family for their precious participation. We thank PhD Carla Rosenberg for gifts of reagents and for opening their lab for part of the experiments. We thank Lygia S. S. Vieira and PhD Simone G. Ferreira for technical support. We thank PhD Cintia M. Ribeiro for helpful assistance with a-CGH analysis. This study was supported by CEPID/FAPESP, CNPq and Capes.

Conflict of Interest: Authors declare to have no conflicts of interest.

References

Abu-Safieh L, Alrashed M, Anazi S, Alkuraya H, Khan AO, Al-Owain M, Al-Zahrani J, Al-Abdi L, Hashem M, Al-Tarimi S, Sebai MA, Shamia A, Ray-Zack MD, Nassan M, Al-Hassnan ZN, Rahbeeni Z, Waheeb S, Alkharashi A, Abboud E, Al-Hazzaa SAF, Alkuraya FS. Autozygome-guided exome sequencing in retinal dystrophy patients reveals pathogenetic mutations and novel candidate disease genes. Genome Res 2013; 23:236–47.

Berrier AL, Yamada KM. Cell-matrix adhesion. J Cell Physiol. 2007 Dec;213(3):565-73.

Bertola DR, Rodrigues MG, Quaio CR, Kim CA, Passos-Bueno MR. Vertical transmission of a frontonasal phenotype caused by a novel ALX4 mutation.Am J Med Genet A. 2013 Mar;161(3):600-4. doi: 10.1002/ajmg.a.35762.

Bosu DR, Feng H, Min K, Kim Y, Wallenfang MR, Kipreos ET. C. elegans CAND-1 regulates cullin neddylation, cell proliferation and morphogenesis in specific tissues. Dev Biol. 2010 Oct 1;346(1):113-26. doi: 10.1016/j.ydbio.2010.07.020.

Chen PW, Jian X, Yoon HY, Randazzo PA. ARAP2 signals through Arf6 and Rac1 to control focal adhesion morphology. J Biol Chem. 2013 Feb 22; 288(8):5849-60. doi: 10.1074/jbc.M112.415778.

Cohen MMJr. 1979. Craniofrontonasal dysplasia. Birth Defects 15:85–89.

Geiger B, Yamada KM. Molecular architecture and function of matrix adhesions. Cold Spring Harb Perspect Biol. 2011 May 1;3(5). doi: 10.1101/cshperspect.a005033.

Guion-Almeida ML, Richieri-Costa A. Frontonasal dysplasia, severe neuropsychological delay, and midline central nervous system anomalies: Report of 10 Brazilian male patients. Am J Med Genet. 2009 May; 149A(5): 1006-11.

Jiang YH, Beaudet AL. Human disorders of ubiquitination and proteasomal degradation. Curr Opin Pediatr. 2004 Aug;16(4):419-26.

Kayserili H, Uz E, Niessen C, Vargel I, Alanay Y, Tuncbilek G, Yigit G, Uyguner O, Candan S, Okur H, Kaygin S, Balci S, Mavili E, Alikasifoglu M, Haase I, Wollnik B, Akarsu NA. ALX4 dysfunction disrupts craniofacial and epidermal development. Hum Mol Genet. 2009 Nov; 18(22):4357–66.

Li C, Wong WH. Model-based analysis of oligonucleotide arrays: Expression index computation and outlier detection, Proc. Natl. Acad. Sci. 2001.98:a31-36.

Lin M, Wei LJ, Sellers WR, Lieberfarb M, Wong WH, Li C. dChipSNP: Significance Curve and Clustering of SNP-Array-Based Loss-of-Heterozygosity Data. Bioinformatics. 2004. 20: 1233-1240.

Mohammed SN, Swan MC, Wall SA, Wilkie AO. Monozygotic twins discordant for frontonasal malformation. Am J Med Genet A. 2004 Nov 1;130A(4):384-8.

Olma MH, Dikic I. Cullins getting undressed by the protein exchange factor cand1. Cell. 2013 Mar 28;153(1):14-6. doi: 10.1016/j.cell.2013.03.014.

Pierce NW, Lee JE, Liu X, Sweredoski MJ, Graham RL, Larimore EA, Rome M, Zheng N, Clurman BE, Hess S, Shan SO, Deshaies RJ. Cand1 Promotes Assembly of New SCF Complexes through Dynamic Exchange of F Box Proteins. Cell. 2013 Mar 28;153(1):206-15. doi: 10.1016/j.cell.2013.02.024.

Sedano HO, Gorlin RJ. 1988. Frontonasal malformation as a field defect and in syndromic associations. Oral Surg Oral Med Oral Pathol 65:704–710.

Silva S, Martins Y, Matias A, Blickstein I. Why are monozygotic twins different? J Perinat Med. 2011 Mar;39(2):195-202.

So J, Suckow V, Kijas Z, Kalscheuer V, Moser B, Winter J, Baars M, Firth H, Lunt P, Hamel B, Meinecke P, Moraine C, Odent S, Schinzel A, van der Smagt JJ, Devriendt K, Albrecht B, Gillessen-Kaesbach G, van der Burgt I, Petrij F, Faivre L, McGaughran J, McKenzie F, Opitz JM, Cox T, Schweiger S. Mild phenotypes in a series of patients with Opitz GBBB syndrome with MID1 mutations. Am J Med Genet A. 2005 Jan 1;132A(1):1-7.

Thomas PS, Kim J, Nunez S, Glogauer M, Kaartinen V. Neural crest cell-specific deletion of Rac1 results in defective cell-matrix interactions and severe craniofacial and cardiovascular malformations. Dev Biol. 2010 Apr 15;340(2):613-25. doi: 10.1016/j.ydbio.2010.02.021.

Twigg SRF, Kan B, Babbs C, Bochukova EG, Robertson SP, Wall SA, Morriss-Kay GM, Wilkie AOM. Mutations of ephrine B1 (EFNB1), a marker of tissue boundary formation, cause craniofrontonasal syndrome. Proc Natl Acad Sci USA. 2004 Jun; 101:8652–7.

Twigg SRF, Versnel SL, Nürnberg G, Lees MM, Bhat M, Hammond P, Hennekam RCM, Hoogeboom AJM, Hurst JA, Johnson D, Robinson AA, Scambler PJ, Gerrelli D, Nürnberg P, Mathijssen IMJ, Wilkie AOM. Frontorhiny, a Distinctive Presentation of Frontonasal Dysplasia Caused by Recessive Mutations in the ALX3 Homeobox Gene. The American Journal of Human Genetics. 2009 May; 84:698–705.

Uz E, Alanay Y, Aktas D, Vargel I, Gucer S, Tuncbilek G, Eggeling FV, Yilmaz E, Deren O, Posorski N, Ozdag H, Liehr T, Balci S, Alikasifoglu M, Wollnik B, Akarsu NA. Disruption of ALX1 Causes Extreme Microphthalmia and Severe Facial Clefting: Expanding the Spectrum of Autosomal-Recessive ALX-Related Frontonasal Dysplasia. AmJ Hum Genet. 2010 May; 86:789–96.

Wang K, Bucan M. Copy Number Variation Detection via High-Density SNP Genotyping. Cold Spring Harb. Protoc. 2008; DOI:10.1101/pdb.top46.

Wang K, Li M, Hadley D, Liu R, Glessner J, Grant SFA, Hakonarson H, Bucan M. PennCNV: An integrated hidden Markov model designed for high-resolution copy number variation detection in whole-genome SNP genotyping data. Genome Res. 2007 Nov; 17(11):1665-74.

Wieland I, Jakubiczka S, Muschke P, Cohen M, Thiele H, Gerlach KL, Adams RH, Wieacker P. Mutations of the ephrin-B1 gene cause craniofrontonasal syndrome. Am J Hum Genet. 2004 Jun; 74(6):1209-15.

Wolfenson H, Lubelski A, Regev T, Klafter J, Henis YI, et al. A Role for the Juxtamembrane Cytoplasm in the Molecular Dynamics of Focal Adhesions. PLoS ONE. 2009. 4(1): e4304. doi:10.1371/journal.pone.0004304

Wu E, Vargevik K, Slavotinek AM. Subtypes of frontonasal dysplasia are useful in determining clinical prognosis. Am J Med Genet Part A. 2007. 143A:3069–3078.

Wu S, Zhu W, Nhan T, Toth JI, Petroski MD, Wolf DA. CAND1 controls in vivo dynamics of the cullin 1-RING ubiquitin ligase repertoire. Nat Commun. 2013 Mar 27;4:1642. doi: 10.1038/ncomms2636.

Yoon HY, Miura K, Cuthbert EJ, Davis KK, Ahvazi B, Casanova JE, Randazzo, PA. ARAP2 effects on the actin cytoskeleton are dependent on Arf6-specific GTPase-activating protein activity and binding to RhoA-GTP. J. Cell Sci. 2006. 119, 4650–4666

Zemla A, Thomas Y, Kedziora S, Knebel A, Wood NT, Rabut G, Kurz T. CSN- and CAND1-dependent remodelling of the budding yeast SCF complex. Nat Commun. 2013 Mar 27;4:1641. doi: 10.1038/ncomms2628.

Zou Y, Liu Q, Chen B, Zhang X, Guo C, Zhou H, Li J, Gao G, Guo Y, Yan C, Wei J, Shao C, Gong Y. Mutation in CUL4B, which encodes a member of cullin-RING ubiquitin ligase complex, causes X-linked mental retardation. Am J Hum Genet. 2007 Mar;80(3):561-6.

VI. Análise de Variações de Número de Cópias em Pacientes com Displasia Frontonasal e Atraso de Desenvolvimento

---

Copy number variation analysis in patients with frontonasal dysplasia and developmental delay

Rodrigues MG[1], Zechi-Ceide RM[2], Souza J[3,4], Silva-Freitas R[3,5], Richieri-Costa A[2], Guion-Almeida ML[2], Passos-Bueno MR[1]

[1] Departamento de Genética e Biologia Evolutiva, Instituto de Biociências, Universidade de São Paulo, São Paulo, Brazil.
[2] Departamento de Genética Clínica, Hospital de Reabilitação de Anomalias Craniofaciais (HRAC), Universidade de São Paulo, Bauru, Brazil.
[3] Centro de Atendimento Integral ao Fissurado Labiopalatal, Curitiba, Paraná, Brazil.
[4] Pontifícia Universidade Católica do Paraná (PUCPR), Paraná, Brazil.
[5] Divisão de Cirurgia Plástica e Reconstrutiva, Universidade Federal do Paraná (UFPR), Paraná, Brazil.

Resumo

Displasia frontonasal (DFN) pode ser considerada como uma forma de expansão de linha média e é caracterizada por dois ou mais dos seguintes sinais clínicos: hipertelorismo ocular, base nasal larga, fissura facial mediana, ausência de formação de ponta nasal, crânio anterior bífido oculto, implantação em "V" dos cabelos na fronte e fissura da asa nasal. Mutações em quatro genes foram descritas como causadoras de fenótipos de DFN com diferentes padrões de heranças, mas, na maioria dos casos de DFN, o mecanismo causal não foi identificado. Aqui, nós investigamos a presença de variações de número de cópias (CNVs) potencialmente patogênicas em sete casos com DFN e atraso de desenvolvimento, entre outros sinais, negativos para mutações nos genes já relacionados à DFN. Um total de 11 CNVs foram detectadas entre os pacientes, mas somente duas foram consideradas como possivelmente patogênicas, levando à identificação de dois prováveis genes candidatos: *DNAJB12* e, em especial, *ENOX2*. No entanto, estudos adicionais são necessários para melhor entender seus supostos efeitos no desenvolvimento humano e em fenótipos de DFN.

Abstract

Frontonasal dysplasia (FND) can be considered a form of midline expansion, and is characterized as two or more of the following clinical features: true ocular hypertelorism, broadening of nasal root, median facial cleft, lack of formation of nasal tip, cranium bifidum occultum, V-shaped frontal hairline, and alar cleft. Mutations in four genes have been described as causing FND phenotypes with different inheritance patterns, but in the majority of cases, no causative mechanism has been identified. Here we investigate the presence of potentially pathogenic copy number variations (CNVs) on seven cases with FND and developmental delay, among other signals, negative for mutations in the genes already related to FND. A total of 11 CNVs were detected among the patients, but only two were considered as being possible pathogenic, involving *DNAJB12* and *ENOX2* genes. However, additional studies are necessary to better understand their supposed effects on human development and FND phenotypes.

Introduction

Craniofacial midline defects comprise a wide spectrum of phenotypes ranging from the ones associated with reduced facial midline, such as holoprosencephaly, to ones associated with expanded facial midline, being craniofacial duplication the most extreme case [Brugmann et al., 2010]. Although also including a broad range of clinical presentations, frontonasal dysplasia (FND) can be considered as a form of midline expansion, and is characterized as two or more of the following clinical features: true ocular hypertelorism, broadening of nasal root, median facial cleft, lack of formation of nasal tip, cranium bifidum occultum, V-shaped frontal hairline, and alar cleft [Sedano and Gorlin, 1988].

Believed to result from the abnormal development of the frontonasal prominence during craniofacial embryogenesis, FND is rare, etiologically heterogeneous and can occur with or without other findings [Cohen, 1979; Wu et al., 2007; Guion-Almeida and Richieri-Costa, 2009]. Although

most cases are sporadic, a few familial cases have been reported in the literature. Some of the syndromes that include FND as part of their clinical presentation are: craniofrontonasal dysplasia (CFND) [OMIM 304110], oculoauriculofrontonasal dysplasia [OMIM 601452], acrofrontofacionasal dysostosis types 1 and 2 [OMIM 201180 and 239710, respectively], Sener syndrome [OMIM 606156], Teebi hypertelorism [OMIM 145420], cerebrofrontofacial syndrome [OMIM 608578].

No genetic causative mechanism has been identified in the majority of cases, but mutations in four genes have already been described as causing FND phenotypes with different inheritance patterns: *EFNB1*, in X-linked CFND [Wieland et al., 2004]; *ALX1*, in autosomal recessive extreme microphthalmia and severe facial clefting [Uz et al., 2010]; *ALX3*, in autosomal recessive Frontorhiny [Twigg et al., 2009]; and *ALX4,* in both autosomal dominant and recessive FND associated with a wide spectrum of clinical variability [Kayserili et al., 2009; Kayserili et al., 2012; Bertola et al, 2013].

In the past decade, the advances in genomic research techniques made it possible to associate pathogenic copy number variants (CNVs) with numerous congenital anomalies, as well as with developmental delay, intellectual disability, and autism spectrum disorders [Miller et al., 2012; Girirajan et al., 2012; Girirajan et al., 2013]. CNVs are defined as segments of DNA at least 1Kb in size that differs in copy number compared with a reference genome [Lee et al., 2007; Vermeesch et al., 2007; Kearney et al., 2011; Southard et al., 2012]. Although not always being easy to conclude the pathogenicity of a CNV, the strategy of CNVs analysis can help explaining the clinical findings in sporadic cases of congenital malformations with developmental delay not indicative of syndromes with defined causes.

In order to try to better understand the causes of FND phenotypes, here we investigate the presence of potentially pathogenic CNVs on seven cases with FND and developmental delay, among other signals, negative for mutations in *EFNB1*, *ALX1*, *ALX3* and *ALX4* genes.

Patients and methods

The Ethics Committee at the Hospital de Reabilitação de Anomalias Craniofaciais (HRAC), Universidade de São Paulo, São Paulo, Brazil, approved this study. Patients' families signed written informed consent.

Patients

Table 1 summarizes the clinical findings of the patients included in this study, and figure 1 shows facial pictures for the ones whose families authorized divulgation. The minimum criteria used were clinical geneticists' diagnosis of FND and developmental delay, and normal sequencing results for *EFNB1, ALX1, ALX3* and *ALX*4 genes. All of the seven cases are male patients born to apparently non-consanguineous parents and with no familial history of similar signals. Four of them were evaluated by the Clinical Genetics Department at HRAC, and were diagnosed (patients 2 and 3) or interrogated (patients 1 and 4) as having FND, severe neuropsychological delay, lack of language acquisition, and midline CNS anomalies [Guion-Almeida and Richieri-Costa, 2009]. The remaining three patients were evaluated by the Clinical Genetics Department at the Centro de Atendimento Integral ao Fissurado Labiopalatal (CAIF), Paraná, Brazil. Patients 1, 2, 3, 4 and 7 have normal G-banded karyotypes.

Table 1. Clinical features of the patients. Ages of the last evaluation by clinical geneticists are indicated in parentheses. '+' indicates presence and '-' indicates absence of a signal; '?' indicates lack of information or a signal that could not be inferred at the moment of evaluation.

CLINICAL FEATURE	PATIENT						
	1 (2 years)	2 (2 years)	3 (19 years)	4 (29 years)	5 (2 years)	6 (1 year)	7 (11 years)
Developmental delay	+	+	+	+	+	+	+
Intellectual disability	?	+	+	+	?	?	+
Speech delay	+	+	+	+	?	?	-
Hypotony (infancy)	-	+	+	?	+	-	?
Encephalocele	-	occipital	midline parietal	etmoidal	-	frontal	-
Macrocephaly	-	+	+	-	-	-	-
Agenesis of the corpus callosum	?	+	+	+	?	?	-
Other SNC anomalies	?	+	+	+	?	?	?
Prominent forehead	+	+	+	-	+	-	-
Widow's peak	-	-	-	+	-	-	-
Ocular hypertelorism	+	+	+	+	+	+	+
Epicanthus	-	-	-	-	+	-	-
Divergent strabismus	-	+	-	-	-	-	-
Iris coloboma	-		+	-	-	-	-
Ptosis of the eyelids	-	+	-	-	-	-	-
Broad nasal root	+	+	+	+	+	+	+
Broad nasal tip	-	+	+	-	-	-	+
Bifid nose	-	-	-	+	+	-	-
Low-set posteriorly angulated ears	-	+	+	-	+	+	-
Malar hypoplasia	-	-	+	+	-	-	-
Micrognathia	-	+	-	-	-	-	-
Cleft palate	+	+	-	+	+	+	-
Cleft lip	+	+	+	+	+	+	+
Genital hypoplasia	-	-	+	-	-	-	-
Cryptorchidism	-	-	-	-	+	-	-
Lack of secondary sex characteristics	?	?	-	+	?	?	?
Postaxial polydactyly of 4th digit	-	-	-	-	+	-	-
Clinodactyly of 5th digit	-	-	-	+	-	-	-

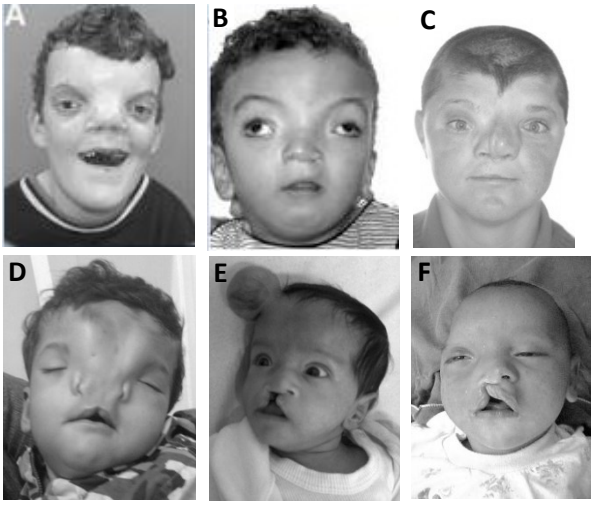

Figure 1. Facial features of patients. A) Patient 3 at the age of 10 years; B) Patient 2 at the age of 1 year and 9 months; C) Patient 4 at the age of 23 years; D) Patient 5 at the age of 2 years; E) Patient 6 at the age of 1 year; F) Patient 7 at the age of 6 months.

Methods

For CNV analysis, we used Affymetrix GeneChip Human Mapping 500K Array Set (Affymetrix, Santa Clara, CA), a single nucleotide polymorphism (SNP) array (SNP-array) platform comprised of two arrays, each capable of genotyping 250,000 SNPs on average (approximately 262,000 for *Nsp* arrays and 238,000 for *Sty* arrays). The assay was performed according to the manufacturer's protocol. Microarray images were processed by GeneChip Command Console Software (Affymetrix, Santa Clara, CA), and the minimum quality of hybridization accepted, measured by QC Call Rate, was 95.0.

This SNP-array platform provides genome-wide coverage of SNPs, and has been successfully used for detection of chromosomal imbalances at a much higher resolution than a conventional cytogenetic analysis [Hester et al.; 2009; McMullan et al., 2009]. However, because it was not originally designed for this purpose, some important considerations may be taken into account when using it to CNV analysis. One of them is that the density and distribution of markers are uneven, since

it typically avoided regions where non-Mendelian alleles and duplication or repetitive sequences were known to exist [Grayton et al., 2012]. Another consideration is that CNV detection algorithms still need substantial improvement , as different algorithms not necessarily detect the same set of putative CNVs [Zhang et al., 2011; Kim et al., 2012]. To try avoiding false positives, we chose to use three analysis programs and considerer only overlapping CNVs over at least two of them. The softwares used for CNV calling were: Genotyping Console (Affymetrix , Santa Clara, CA), PennCNV [Wang et al., 2007; Wang and Bucan, 2008] and dChip [Li and Wong, 2001; Lin et al., 2004], with default settings.

Results

Of FND characteristics, all the 7 patients showed ocular hypertelorism, broad nasal root and cleft lip, while 5 showed cleft palate, 5 showed altered nasal tip (3 broad nasal tip and 2 bifid nose) and 4 showed prominent forehead. Most other frequent associated findings were: low-set and posteriorly angulated ears (4/7), encephalocele (4/7), speech delay (4/7), and intellectual disability (4/7).

A total of 11 CNVs were detected among the patients (shown in table 2). Most of the identified variations were already seen in apparently healthy people, according to the Database of Genomic Variants (DGV - http://projects.tcag.ca/variation/). All CNVs that showed complete overlapping with those at DGV of the same type of variation (loss or gain) were considered as unlikely to be pathogenic. Based on this criterion, only three CNV remained to be evaluated about pathogenicity (highlighted in gray in table 2). The CNV found in patient 1 (chromosome 4) does not encompass any known gene, while the one seen in patient 5 (chromosome X) encompasses exons 3 to 5 of *ENOX2* gene (NM_006375.2, 15 exons), and the one found in patient 7 (chromosome 10) encompasses the first exon of *DNAJB12* gene (NM_017626.4, 9 exons), and exons 2 to 12 of *MICU1* gene (NM_006077.3, 12 exons).

Table 2. Copy number variations (CNVs) detected by at least two different software of analysis. Highlighted in gray are the CNVs not seen on apparently healthy individuals, according to the Database of Genomic Variants (http://projects.tcag.ca/variation/). GC= Genotyping Console software (Affymetrix , Santa Clara, CA).

Patient	Chromosome	Chromosome Location	Type	~ Size (Kb)	Linear position Start – End (hg18)	Software of detection
1	4	q32.3	Gain	405	167365625 - 167770809	GC, dChip
5	17	q12	Gain	105	31396119 - 31501499	GC, PennCNV
	22	q11.23	Loss	280	24012780 - 24292988	GC, PennCNV
	X	q25	Loss	124	129643359 - 129767033	GC, PennCNV
6	7	p14.1	Loss	224	38204644 - 38428678	GC, PennCNV
	11	p11.12-q11	Gain	3383	51231886 - 54614884	GC, dChip
	14	q11.2	Loss	584	21474514 - 22058411	GC, PennCNV
	17	q21.31	Gain	228	41491663 - 41719833	GC, dChip
7	10	q22.1	Loss	221	73783339 - 74004764	GC, PennCNV
	12	p11.1	Gain	618	34034066 - 34651598	GC, PennCNV
	X	p22.33	Gain	349	617088 - 966564	GC, PennCNV

Discussion

Although some genetic alterations were identified as causing different FND phenotypes, the fact that the etiology of the majority of the cases remains unknown makes it difficult to perform adequate genetic counseling for families with affected individuals. All patients included in this study show FND and developmental delay. Besides, several different clinical features are found among them. None of the patients showed a phenotype typical of ALXs-related FND and CFND, what explain their previous negative results for mutation in *ALX1, ALX3, ALX4* and *EFNB1* genes. Although four of these patients seem to share more similar phenotypes (1-4), we did not expect that they would necessarily share the same genetic alteration.

Chromosomal microalterations are known to respond for approximately 15% of cases with developmental delay and/or multiple congenital anomalies [Edelmann and Hirschhorn, 2009; Hanemaaijer et al., 2012]. As all of the cases studied here are sporadic and have developmental delay occurring within the phenotype, we questioned if they could be caused by this type of genetic

alteration. In general, the gain-of-function effect of genes is less often known than their loss-of-function effect, and it is thought that microduplications are better tolerated in the genome than deletions [Lee et al., 2007; Hanemaaijer et al., 2012]. However, CNVs of both gain (duplication) and loss (deletion) were already found as leading to altered phenotypes, including craniofacial malformations and developmental delay. Thus, the clinical significance of a specific CNV has to be careful and individually analyzed, and, not rare, its phenotypic effect is not possible to be determined.

CNV analysis of the patients 2, 3 and 4 did not reveal any CNV, and analysis of patient 6 revealed only variation seen on DGV. Although we chose to only consider for further investigation the CNVs detected by at least two different software to decrease the probability of identifying false positives, we are aware that a possible consequence of this criterion is an increase of false negatives. Therefore, we do not discard the possibility of existence of pathogenic CNVs in these patients that were not identified.

Considering that most part of our genome is non-coding but possibly involved in regulation, we cannot rule out that the duplication detected in patient 1 does not contribute to his phenotype. Even though this CNV is most likely benign, we rather preferred to classify it as of uncertain clinical significance.

DNAJB12, one of the genes within the CNV detected in patient 7, encodes a type II transmembrane J-protein localized at the endoplasmic reticulum (ER) that has its J-domain in the cytosol and cooperates to promote the ER-associated degradation (ERAD) of misfolded membrane proteins [Yamamoto et al., 2010; Grove et al., 2011]. On the other hand, *MICU1*, the other gene within this CNV, encodes the mitochondrial calcium uptake 1 protein, a mitochondrial regulator of uniporter-mediated calcium uptake [Perocchi et al., 2010]. Genomic analysis of populations residing in Ethiopia produced several candidates for involvement in their high-altitude physiology adaption, one of which was *MICU1* due to its involvement in mitochondrial metabolism [Scheinfeldt et al.,

2012]. Taking into account these data and the existence of copy number losses on DGV that also partially include *MICU1, DNAJB12* is more likely to be a candidate to the phenotype of patient 7 than *MICU1.*

The deletion found on X chromosome of patient 5 partially encompasses *ENOX2* gene, which encodes the ecto-nox disulfide-thiol exchanger 2 protein, a tumor-associated NADH oxidase [Chueh et al., 2004]. In studies with cultured cells, ENOX2 activity resulted in larger cells and accelerated rate of cell enlargement [Chueh et al., 2004; Yagiz et al., 2008], and it was also established an essential role for this protein in cell migration and survival [Su et al., 2012]. Full length mRNA to *ENOX2* is present in both non-cancer and cancer cells. Cho and Morré [2009] used chicken embryos to investigate the developmental expression of this gene and revealed its translation in early embryogenesis similar to that seen in cancer, suggesting an early function in undifferentiated normal cells requiring the presence of the *ENOX2*. The CNV reported here deletes exons 3-5 of *ENOX2* (NM_006375.2). All three exons are present at the two RefSeq isoforms, while exons 4 and 5 are present and protein coding in all five splice variants at Ensembl. Exon 4 is the first translated exon of three of these five variants, and the second of the other two. Besides, exon 5 appear to codify part of a RNA-binding domain (SSF54928; according to Superfamily 1.75). Possible effects of the loss of these exons are a loss or gain of function of *ENOX2*, e.g., by mRNA degradation, lack of initiation of translation or the translation of an altered protein that can be or not degraded. Thus, as it is the only copy in the male genome, we speculate that *ENOX2* can be a candidate gene to explain the findings of patient 5. However, more studies are necessary to investigate this hypothesis and the possible role of *ENOX2* in human early development.

In summary, analysis of CNVs in patients with FND, developmental delay and other signals led to the identification of two putative candidate genes, *DNAJB12* and specially *ENOX2*. Additional studies are necessary to better understand their supposed effects on the phenotype. Because of limitations of the technique used, we do not discard the possibility of existence of pathogenic CNVs

not identified or other mutational mechanisms, such as point mutations, indels, and many other genetic factors not detectable by the methodology used in the present study. Yet, non-genetic etiology cannot be discarded.

Acknowledgments

We thank the patients and their families for their precious participation in this study. We thank Simone Ferreira for technical support. This study was supported by CEPID/FAPESP, CNPq and Capes.

Conflict of Interest: We declare to have no conflicts of interest.

References

Bertola DR, Rodrigues MG, Quaio CR, Kim CA, Passos-Bueno MR. Vertical transmission of a frontonasal phenotype caused by a novel ALX4 mutation.Am J Med Genet A. 2013 Mar;161(3):600-4. doi: 10.1002/ajmg.a.35762.

Brugmann SA, Allen NC, James AW, Mekonnen Z, Madan E, Helms JA. A primary cilia-dependent etiology for midline facial disorders. Hum Mol Genet. 2010 Apr; 19(8):1577-92.

Chueh PJ, Wu LY, Morré DM, Morré DJ. tNOX is both necessary and sufficient as a cellular target for the anticancer actions of capsaicin and the green tea catechin (-)-epigallocatechin-3-gallate. Biofactors. 2004;20(4):235-49.

Cho N, Morré DJ. Early developmental expression of a normally tumor-associated and drug-inhibited cell surface-located NADH oxidase (ENOX2) in non-cancer cells. Cancer Immunol Immunother. 2009 Apr;58(4):547-52. doi: 10.1007/s00262-008-0577-3.

Cohen MMJr. 1979. Craniofrontonasal dysplasia. Birth Defects 15:85–89.

Edelmann L, Hirschhorn K. Clinical utility of array CGH for the detection of chromosomal imbalances associated with mental retardation and multiple congenital anomalies. Ann N Y Acad Sci. 2009 Jan;1151:157-66. doi: 10.1111/j.1749-6632.2008.03610.x.

Girirajan S, Johnson RL, Tassone F, Balciuniene J, Katiyar N, Fox K, Baker C, Srikanth A, Yeoh KH, Khoo SJ, Nauth TB, Hansen R, Ritchie M, Hertz-Picciotto I, Eichler EE, Pessah IN, Selleck SB. Global increases in both common and rare copy number load associated with autism. Hum Mol Genet. 2013 Apr 19. [Epub ahead of print]

Girirajan S, Rosenfeld JA, Coe BP, Parikh S, Friedman N, Goldstein A, Filipink RA, McConnell JS, Angle B, Meschino WS, Nezarati MM, Asamoah A, Jackson KE, Gowans GC, Martin JA, Carmany EP, Stockton DW, Schnur RE, Penney LS, Martin DM, Raskin S, Leppig K, Thiese H, Smith R, Aberg E, Niyazov DM, Escobar LF, El-Khechen D, Johnson KD, Lebel RR, Siefkas K, Ball S, Shur N, McGuire M, Brasington CK, Spence JE, Martin LS, Clericuzio C, Ballif BC, Shaffer LG, Eichler EE. Phenotypic heterogeneity of genomic disorders and rare copy-number variants.N Engl J Med. 2012 Oct 4;367(14):1321-31. doi: 10.1056/NEJMoa1200395.

Grayton HM, Fernandes C, Rujescu D, Collier DA. Copy number variations in neurodevelopmental disorders. Prog Neurobiol. 2012 Oct;99(1):81-91. doi: 10.1016/j.pneurobio.2012.07.005.

Grove DE, Fan CY, Ren HY, Cyr DM. The endoplasmic reticulum-associated Hsp40 DNAJB12 and Hsc70 cooperate to facilitate RMA1 E3-dependent degradation of nascent CFTRDeltaF508. Mol Biol Cell. 2011 Feb 1;22(3):301-14. doi: 10.1091/mbc.E10-09-0760.

Guion-Almeida ML, Richieri-Costa A. Frontonasal dysplasia, severe neuropsychological delay, and midline central nervous system anomalies: Report of 10 Brazilian male patients. Am J Med Genet. 2009 May; 149A(5): 1006-11.

Hanemaaijer NM, Sikkema-Raddatz B, van der Vries G, Dijkhuizen T, Hordijk R, van Essen AJ, Veenstra-Knol HE, Kerstjens-Frederikse WS, Herkert JC, Gerkes EH, Leegte LK, Kok K, Sinke RJ, van Ravenswaaij-Arts CM. Practical guidelines for interpreting copy number gains detected by high-resolution array in routine diagnostics. Eur J Hum Genet. 2012 Feb;20(2):161-5. doi: 10.1038/ejhg.2011.174.

Hester SD, Reid L, Nowak N, Jones WD, Parker JS, Knudtson K, Ward W, Tiesman J, Denslow ND. Comparison of comparative genomic hybridization technologies across microarray platforms. J Biomol Tech. 2009 Apr;20(2):135-51.

Kayserili H, Altunoglu U, Ozgur H, Basaran S, Uyguner ZO. Mild nasal malformations and parietal foramina caused by homozygous ALX4 mutations. Am J Med Genet A. 2012 Jan;158A(1):236-44.

Kayserili H, Uz E, Niessen C, Vargel I, Alanay Y, Tuncbilek G, Yigit G, Uyguner O, Candan S, Okur H, Kaygin S, Balci S, Mavili E, Alikasifoglu M, Haase I, Wollnik B, Akarsu NA. ALX4 dysfunction disrupts craniofacial and epidermal development. Hum Mol Genet. 2009 Nov; 18(22):4357–66.

Kearney HM, Thorland EC, Brown KK, Quintero-Rivera F, South ST; Working Group of the American College of Medical Genetics Laboratory Quality Assurance Committee. American College of Medical Genetics standards and guidelines for interpretation and reporting of postnatal constitutional copy number variants.Genet Med. 2011 Jul;13(7):680-5. doi: 10.1097/GIM.0b013e3182217a3a.

Kim SY, Kim JH, Chung YJ. Effect of Combining Multiple CNV Defining Algorithms on the Reliability of CNV Calls from SNP Genotyping Data. Genomics Inform. 2012 Sep;10(3):194-9. doi: 10.5808/GI.2012.10.3.194.

Lee C, Iafrate AJ, Brothman AR. Copy number variations and clinical cytogenetic diagnosis of constitutional disorders. Nat Genet. 2007 Jul;39(7 Suppl):S48-54.

Li C, Wong WH. Model-based analysis of oligonucleotide arrays: Expression index computation and outlier detection, Proc. Natl. Acad. Sci. 2001.98:a31-36.

Lin M, Wei LJ, Sellers WR, Lieberfarb M, Wong WH, Li C. dChipSNP: Significance Curve and Clustering of SNP-Array-Based Loss-of-Heterozygosity Data. Bioinformatics. 2004. 20: 1233-1240.

McMullan DJ, Bonin M, Hehir-Kwa JY, de Vries BB, Dufke A, Rattenberry E, Steehouwer M, Moruz L, Pfundt R, de Leeuw N, Riess A, Altug-Teber O, Enders H, Singer S, Grasshoff U, Walter M, Walker JM, Lamb CV, Davison EV, Brueton L, Riess O, Veltman JA. Molecular karyotyping of patients with unexplained mental retardation by SNP arrays: a multicenter study. Hum Mutat. 2009 Jul;30(7):1082-92. doi: 10.1002/humu.21015.

Miller DT, Shen Y, Wu BL. Oligonucleotide microarrays for clinical diagnosis of copy number variation and zygosity status.Curr Protoc Hum Genet. 2012 Jul;Chapter 8:Unit8.12. doi: 10.1002/0471142905.

Perocchi F, Gohil VM, Girgis HS, Bao XR, McCombs JE, Palmer AE, Mootha VK. MICU1 encodes a mitochondrial EF hand protein required for Ca(2+) uptake. Nature. 2010 Sep 16;467(7313):291-6. doi: 10.1038/nature09358.

Sedano HO, Gorlin RJ. 1988. Frontonasal malformation as a field defect and in syndromic associations. Oral Surg Oral Med Oral Pathol 65:704–710.

Scheinfeldt LB, Soi S, Thompson S, Ranciaro A, Woldemeskel D, Beggs W, Lambert C, Jarvis JP, Abate D, Belay G, Tishkoff SA. Genetic adaptation to high altitude in the Ethiopian highlands.Genome Biol. 2012 Jan 20;13(1):R1. doi: 10.1186/gb-2012-13-1-r1.

Southard AE, Edelmann LJ, Gelb BD. Role of copy number variants in structural birth defects. Pediatrics. 2012 Apr;129(4):755-63. doi: 10.1542/peds.2011-2337.

Su YC, Lin YH, Zeng ZM, Shao KN, Chueh PJ. Chemotherapeutic agents enhance cell migration and epithelial-to-mesenchymal transition through transient up-regulation of tNOX (ENOX2) protein. Biochim Biophys Acta. 2012 Nov;1820(11):1744-52. doi: 10.1016/j.bbagen.2012.07.009.

Twigg SRF, Versnel SL, Nürnberg G, Lees MM, Bhat M, Hammond P, Hennekam RCM, Hoogeboom AJM, Hurst JA, Johnson D, Robinson AA, Scambler PJ, Gerrelli D, Nürnberg P, Mathijssen IMJ, Wilkie AOM. Frontorhiny, a Distinctive Presentation of Frontonasal Dysplasia Caused by Recessive Mutations in the ALX3 Homeobox Gene. The American Journal of Human Genetics. 2009 May; 84:698–705.

Uz E, Alanay Y, Aktas D, Vargel I, Gucer S, Tuncbilek G, Eggeling FV, Yilmaz E, Deren O, Posorski N, Ozdag H, Liehr T, Balci S, Alikasifoglu M, Wollnik B, Akarsu NA. Disruption of ALX1 Causes Extreme Microphthalmia and Severe Facial Clefting: Expanding the Spectrum of Autosomal-Recessive ALX-Related Frontonasal Dysplasia. AmJ Hum Genet. 2010 May; 86:789–96.

Vermeesch JR, Fiegler H, de Leeuw N, Szuhai K, Schoumans J, Ciccone R, Speleman F, Rauch A, Clayton-Smith J, Van Ravenswaaij C, Sanlaville D, Patsalis PC, Firth H, Devriendt K, Zuffardi O.Guidelines for molecular karyotyping in constitutional genetic diagnosis.Eur J Hum Genet. 2007 Nov;15(11):1105-14.

Wang K, Bucan M. Copy Number Variation Detection via High-Density SNP Genotyping. Cold Spring Harb. Protoc. 2008; DOI:10.1101/pdb.top46.

Wang K, Li M, Hadley D, Liu R, Glessner J, Grant SFA, Hakonarson H, Bucan M. PennCNV: An integrated hidden Markov model designed for high-resolution copy number variation detection in whole-genome SNP genotyping data. Genome Res. 2007 Nov; 17(11):1665-74.

Wieland I, Jakubiczka S, Muschke P, Cohen M, Thiele H, Gerlach KL, Adams RH, Wieacker P. Mutations of the ephrin-B1 gene cause craniofrontonasal syndrome. Am J Hum Genet. 2004 Jun; 74(6):1209-15.

Wu E, Vargevik K, Slavotinek AM. Subtypes of frontonasal dysplasia are useful in determining clinical prognosis. Am J Med Genet Part A. 2007. 143A:3069–3078.

Yagiz K, Snyder PW, Morré DJ, Morré DM. Cell size increased in tissues from transgenic mice overexpressing a cell surface growth-related and cancer-specific hydroquinone oxidase, tNOX, with protein disulfide-thiol interchange activity. J Cell Biochem. 2008 Dec 15;105(6):1437-42. doi: 10.1002/jcb.21962.

Yamamoto YH, Kimura T, Momohara S, Takeuchi M, Tani T, Kimata Y, Kadokura H, Kohno K. A novel ER J-protein DNAJB12 accelerates ER-associated degradation of membrane proteins including CFTR. Cell Struct Funct. 2010;35(2):107-16.

Zhang D, Qian Y, Akula N, Alliey-Rodriguez N, Tang J; Bipolar Genome Study, Gershon ES, Liu C. Accuracy of CNV Detection from GWAS Data. PLoS One. 2011 Jan 13;6(1):e14511. doi: 10.1371/journal.pone.0014511.

VII. Discussão Geral e Conclusões

Este trabalho visa à investigação de possíveis causas genéticas relacionadas à DFN. Embora mutações nos genes *EFNB1, ALX1, ALX3* e *ALX4* já tenham sido associadas a quadros com DFN, o fato de a maioria dos casos ser esporádica e não ter etiologia definida dificulta o aconselhamento genético às famílias com indivíduos afetados, assim como inferências sobre o prognóstico desses pacientes. Uma melhor compreensão da etiologia da DFN pode também contribuir para a identificação de vias de sinalização importantes para o desenvolvimento craniofacial humano.

A observação neste estudo de uma mutação em heterozigose no gene *ALX4* co-segregando com um fenótipo em um caso familial de DFN leve representa a primeira descrição de mutação neste gene causando uma forma de DFN com herança dominante. Mutações em homozigose em *ALX4* foram associadas tanto a quadros mais graves como a um caso mais leve de DFN; embora não haja estudos funcionais, essa diferença fenotípica aparentemente depende do tipo de consequência da mutação na atividade da proteína. Por outro lado, mutações em heterozigose no *ALX4* haviam sido relacionadas até então apenas a forame parietal alargado. O fenótipo apresentado pelo paciente e sua mãe é, portanto, intermediário neste espectro de variabilidade clínica relacionada a *ALX4.* Enquanto as mutações de mudança de fase de leitura levando a códon de parada prematuro descritas até o momento nos casos com apenas forame parietal alargado ocorrem antes do último *intron* do gene, a mutação encontrada neste estudo se localiza em seu último *exon*. Este fato faz com que o alelo alterado do paciente e sua mãe escape ao mecanismo de degradação de mRNA com códons de parada prematuro, denominado *non-sense mediated mRNA decay* (NMD), o que a princípio não ocorre nos casos sem DFN. Sendo assim, acreditamos que a maior gravidade do quadro estudado em relação aos demais casos de mutação em heterozigose no *ALX4* possa ser explicada por um mecanismo de dominância negativa, havendo uma provável interação entre os alelos selvagem e alterado, mas com manutenção parcial das funções do gene.

O fato de termos identificado mutação em homozigose no gene *ALX1* num quadro de DFN grave com microftalmia corrobora os achados de Uz et al. (2010). O paciente com mutação em *ALX1* do presente estudo não apresenta, contudo, nenhum tipo de atraso de desenvolvimento e nenhuma outra anomalia associada, o que corrobora ainda a importância e especificidade da função do gene *ALX1* para o correto desenvolvimento craniofacial no início do desenvolvimento embriológico humano. Neste contexto, nosso estudo, que consiste do 3º caso da literatura mundial, contribuiu para uma melhor definição do espectro clinico da DFN relacionada a *ALX1*.

Como é bem estabelecido na literatura, estudos de rearranjos cromossômicos equilibrados e de CNVs podem contribuir para a identificação de genes associados a um determinado fenótipo, uma vez que os pontos de quebra do rearranjo ou que delimitam a região de CNV podem romper um ou mais genes ou regiões regulatórias, além de CNVs poderem englobar genes cujas funções sejam sensíveis à dosagem gênica. Foi identificado um paciente com DFN, atraso de desenvolvimento e outras anomalias que apresenta rearranjo aparentemente balanceado envolvendo os cromossomos 4 e 12. O fato de seu rearranjo cromossômico ser *de novo,* ou seja, não estar presente em seus pais, favorece a hipótese de que possa estar envolvido com a etiologia do fenótipo do indivíduo. Os estudos citogenéticos e moleculares dos pontos de quebra do rearranjo sugeriram os genes *ARAP2* e *CAND1* como possíveis responsáveis pelo quadro clínico do paciente, uma vez que o primeiro parece ter importante papel no desenvolvimento embriológico e o segundo tem função no processo de ubiquitinação, um processo celular que quando comprometido pode levar a alterações fenotípicas, como é o caso das mutações no gene *MID1* associadas à síndrome Optiz GBBB de herança ligada ao X, com a qual o paciente compartilha determinadas características. Por sua vez, o estudo de CNVs em sete indivíduos com DFN associada a atraso de desenvolvimento apontou os genes *DNAJB12* e em especial *ENOX2* como possíveis candidatos para explicar o fenótipo de dois dos pacientes. Enquanto o primeiro está envolvido no processo de degradação de proteínas alteradas, o segundo está relacionado aos processos de crescimento, migração e sobrevivência celulares. No entanto, uma vez que não foi possível mapear precisamente o ponto de quebra do paciente com o rearranjo nem

comparar a expressão dos genes identificados nos indivíduos afetados com controles, é preciso que novos estudos sejam realizados a fim de melhor compreender o significado de tais achados e a real contribuição de cada gene para o desenvolvimento craniofacial humano. Pelo limite de resolução imposto pelas técnicas realizadas, não descartamos a existência de CNVs patogênicas influenciando o fenótipo dos pacientes que não tenham sido detectadas neste estudo. Embora todos os casos deste estudo com DFN e atraso de desenvolvimento sejam do sexo masculino, o baixo tamanho amostral decorrente da raridade do fenótipo e um viés de seleção da amostra, onde inicialmente priorizou-se o grupo de meninos publicados por Guion-Almeida e Richieri-Costa (2009), não permitem inferências quanto à proporção de ocorrência desta condição entre os sexos.

Um recente modelo animal para DFN foi proposto por Brugmann et al. (2010) em virtude do quadro clínico de camundongos com deleção em homozigose do gene *Kif3a* (que codifica uma proteína de transporte intraflagelar) especificamente em células da crista neural. Uma vez que camundongos com deficiência total deste gene em homozigose são inviáveis, e considerando ainda os achados de Twigg et al. (2013) de mosaicismo somático em todos os casos estudados de DCFN grave em meninos, acreditamos que ao menos uma parcela dos pacientes com DFN pode apresentar mutações também somente em determinadas linhagens celulares, ou seja, que representem casos de mosaicismo somático. Sendo assim, consideramos importante que no futuro sejam realizados estudos para investigar também esta hipótese, que explicaria ainda parte dos resultados de discordância entre gêmeos monozigóticos.

Embora causas ambientais possam também estar envolvidas na etiologia da DFN, a existência de mutações de ponto, indels e vários outros fatores genéticos e epigenéticos não detectáveis pelas metodologias utilizadas no presente estudo precisa também ser investigada, uma vez que podem ser responsáveis pelo quadro clínico desses indivíduos.

Com este trabalho podemos concluir que:

- Mutações em heterozigose no gene *ALX4* podem também levar a quadros com DFN.

- O gene *ALX1* parece ter função bastante importante e específica para o correto desenvolvimento craniofacial em humanos, uma vez que o quadro clínico consequente de mutações em homozigose neste gene é bastante grave e restrito à região da face. Mutações neste gene não levam necessariamente a alteração de desenvolvimento congnitivo.

- Alteração na função dos genes *ARAP2*, *CAND1, DNAJB12* e *ENOX2* são possíveis candidatas para quadros com DFN.

Resumo

A displasia frontonasal (DFN) compreende quadros de aparência facial variável, sendo clinicamente caracterizada por dois ou mais dos seguintes sinais: hipertelorismo ocular com consequente alargamento da base nasal; fissura facial mediana afetando o nariz ou o nariz e lábio superior e, por vezes, o palato; fissura alar (uni ou bilateral); ponta nasal ausente; crânio anterior bífido oculto, e implantação em "V" dos cabelos na fronte. A DFN pode ser vista como um defeito de desenvolvimento que pode ocorrer por si só ou como parte do quadro clínico de várias síndromes. A maioria dos casos de DFN é esporádica, e em raras circunstâncias foram observadas alterações cromossômicas em alguns indivíduos. Até o momento, quatro genes foram relacionados à patogênese molecular de algumas das síndromes com DFN, *EFNB1*, associado a uma forma de DFN ligada ao X e os genes *ALX1*, *ALX3* e *ALX4*, todos associados a formas de DFN com herança autossômica recessiva. Embora esteja claro haver heterogeneidade etiológica, na maioria dos casos de DFN a causa não é conhecida, dificultando o adequado aconselhamento genético aos pacientes e seus familiares. Sendo assim, realizamos estudos com diferentes estratégias metodológicas buscando melhor compreender as possíveis causas genéticas da DFN. Ao todo foram analisados 10 pacientes: um caso familial de DFN leve com herança aparentemente autossômica dominante, um caso clinicamente sugestivo de mutação em *ALX1*, e oito casos de DFN associada a atraso de desenvolvimento com ou sem outras anomalias, dos quais um apresentava um rearranjo *de novo* aparentemente balanceado entre os cromossomos 4 e 12. Optamos por realizar sequenciamento dos genes previamente relacionados a fenótipos com DFN em todos os casos; para aqueles em que não foram detectadas mutações patogênicas, realizamos análise de variações de número de cópias (CNV) por *microarray* de polimorfismos de base única e, para o paciente com rearranjo cromossômico, realizamos o mapeamento do ponto de quebra por hibridação *in situ* fluorescente. Constatamos uma mutação em heterozigose no gene *ALX4* co-segregando com o fenótipo do caso familial, sendo esta a primeira descrição de alteração em tal gene causando uma forma de DFN com herança dominante, e sugerimos pela primeira vez um mecanismo de dominância negativa. No caso sugestivo de mutação em *ALX1*, o diagnóstico foi confirmado através da identificação de uma mutação em homozigose neste gene do paciente; este caso consiste no 3º da literatura mundial e evidencia pela primeira vez que mutações em *ALX1* não necessariamente levam a atraso de desenvolvimento ou deficiência intelectual. Os estudos citogenéticos e moleculares dos pontos de quebra do paciente com rearranjo cromossômico sugeriram os genes *ARAP2* e *CAND1* como possíveis responsáveis por seu quadro clínico, enquanto o estudo de CNVs nos indivíduos com DFN associada a atraso de

desenvolvimento apontou os genes *DNAJB12* e *ENOX2* como possíveis candidatos para explicar o fenótipo de dois dos pacientes. É preciso que novos estudos sejam realizados a fim de melhor compreender o significado de tais achados e a real contribuição de cada gene para o desenvolvimento craniofacial humano e para a etiologia da DFN. Para os casos em que não foram identificadas alterações conclusivas no presente estudo, embora causas ambientais não possam ser descartadas, é preciso que seja investigada também a existência de fatores genéticos e epigenéticos não detectáveis pelas metodologias utilizadas, bem como a hipótese de mosaicismo somático. Nossos resultados, além de corroborarem o envolvimento dos genes *ALX1* e *ALX4* em fenótipos com DFN, sugerem também novos genes candidatos: *ARAP2*, *CAND1, DNAJB12* e *ENOX2.*

Palavras-chave: displasia frontonasal; CNV; genes candidatos; rearranjos cromossômicos estruturais; *ALX1; ALX4*.

Abstract

Frontonasal dysplasia (FND) is a rare group of disorders that comprises cases with a variety of facial appearances, and is clinically characterized by two or more of the following signs: ocular hypertelorism with consequent broadening of the nasal root; median facial cleft affecting the nose and/or upper lip and palate; clefting of the alae nasi (uni or bilateral); lack of formation of the nasal tip; anterior cranium bifidum occultum; and a V-shaped frontal hairline. FND is a developmental defect that can occur alone or as part of several syndromes. Most cases of FND are sporadic, and in rare circumstances chromosomal alterations were observed in affected individuals. To date, four genes have been related to the molecular pathogenesis of some syndromes with DFN, one (*EFNB1*) is associated with an X-linked form while the 3 others (*ALX1, ALX3 and ALX4*) are associated with autosomal recessive forms. Although it is clear that FND is etiologic heterogeneous, the causative mechanism is unknown in most cases which makes it hard to give proper genetic counseling to patients and their families. In order to get new insights into the genetic mechanisms leading to FND, we performed studies with different methodologies. Altogether, 10 patients were analyzed: a familial case of a mild form of FND with an apparently autosomal dominant inheritance pattern, a case clinically suggestive of mutation in *ALX1*, and eight cases of FND associated with developmental delay with or without other anomalies, one of which with an apparently balanced *de novo* rearrangement between chromosomes 4 and 12. We chose to sequence the genes previously associated with FND phenotypes in all cases; for those in which pathogenic mutations were not detected, we conducted an analysis of copy number variations (CNV) by single nucleotide polymorphisms microarrays; for the patient with chromosomal rearrangement, we also mapped the breakpoints by using fluorescence in situ hybridization. We found a heterozygous mutation in *ALX4* co-segregating with the phenotype of the familial case; this is the first description of mutation in this gene causing a form of FND with dominant inheritance pattern, and we suggested for the first time a dominant negative mechanism. In the case suggestive of mutation in *ALX1*, the diagnosis was confirmed by the identification of a homozygous mutation in this gene; this is the third case of the literature and shows for the first time that mutations in *ALX1* are not necessarily related to developmental delay or intellectual disability. Breakpoints cytogenetic and molecular studies done with the patient with chromosomal rearrangement suggested *ARAP2* and *CAND1* genes as causative candidates for his condition, while the study of CNVs in individuals with FND associated with developmental delay pointed *DNAJB12* and *ENOX2* genes as possible candidates to explain the phenotypes of two of the patients. Further studies are necessary to better understand the significance of such findings and the actual

contribution of each of these genes to human craniofacial development and the etiology of FND. Although environmental causes cannot be ruled out, it should also be investigated the existence of genetic and epigenetic factors as well as the possibility of somatic mosaicism, among the cases negative for the molecular approaches used in our study. Our results corroborate the involvement of *ALX1* and *ALX4* in FND phenotypes, and suggest new candidate genes: *ARAP2*, *CAND1*, *DNAJB12* and *ENOX2*.

Keywords: frontonasal dysplasia; CNV; candidate genes; structural chromosomal rearrangements; *ALX1; ALX4*.

Referências Bibliográficas

Antoneli MZ, Giacheti CM, Genaro KF, Zorzetto NL, Richieri-Costa A. Frontonasal dysplasia: clinical evaluation on audiological and brainstem electrophysiological profiles. Braz J Otorhinolaryngol. 2011 Sep-Oct;77(5):611-5.

Brugmann SA, Allen NC, James AW, Mekonnen Z, Madan E, Helms JA. A primary cilia-dependent etiology for midline facial disorders. Hum Mol Genet. 2010 Apr; 19(8):1577-92.

Compagni A, Logan M, Klein R, Adams RH. Control of skeletal patterning by ephrinB1-EphB interactions. Dev Cell. 2003 Aug;5(2):217-30.

Evers C, Jungwirth M, Morgenthaler J, Hinderhofer K, Maas B, Janssen J, Jauch A, Hehr U, Steinbeisser H, Moog U. Craniofrontonasal syndrome in a male due to chromosomal mosaicism involving EFNB1: further insights into a genetic paradox. Clin Genet. 2013 Apr 24. doi: 10.1111/cge.12171. [Epub ahead of print]

Francis-West P, Ladher R, Barlow A, Graveson A. Signalling interactions during facial development. Mech Dev. 1998 Jul;75(1-2):3-28.

Freitas ÉL, Gribble SM, Simioni M, Vieira TP, Prigmore E, Krepischi AC, Rosenberg C, Pearson PL, Melo DG, Gil-da-Silva-Lopes VL. A familial case with interstitial 2q36 deletion: variable phenotypic expression in full and mosaic state. Eur J Med Genet. 2012 Nov;55(11):660-5.

Guion-Almeida ML. Hipertelorismo e defeitos de linha média facial. Estudo genético clínico de uma amostra de pacientes. [tese] Campinas: Faculdade de Ciências Médicas da Universidade Estadual de Campinas. 2000.

Guion-Almeida ML, Mellado C, Beltrán C, Richieri-Costa A. Pai Syndrome: Report of Seven South American Patients. Am J Med Genet. 2007 Dec; 143A: 3273–9.

Guion-Almeida ML, Richieri-Costa A. Acrofrontofacionasal dysostosis: report of the third Brazilian family. Am J Med Genet. 2003 Jun; 119A: 238-41.

Guion-Almeida ML, Richieri-Costa A. Frontonasal dysplasia, macroblepharon, eyelid colobomas, ear anomalies, macrostomia, mental retardation and CNS structural anomalies: defining the phenotype. Clin. Dysmorphol. 2001 Apr; 10(2): 79-80.

Guion-Almeida ML, Richieri-Costa A. Frontonasal dysplasia, severe neuropsychological delay, and midline central nervous system anomalies: Report of 10 Brazilian male patients. Am J Med Genet. 2009 May; 149A(5): 1006-11.

Guion-Almeida ML, Richieri-Costa A, Jehee FS, Passos-Bueno MR, Zechi-Ceide RM. Frontonasal dysplasia, callosal agenesis, basal encephalocele, and eye anomalies syndrome with a partial 21q22.3 deletion. Am J Med Genet A. 2012 Jul;158A(7):1676-9.

Guion-Almeida ML, Richieri-Costa A, Saavedra D, Cohen MM Jr. Frontonasal dysplasia: analysis of 21 cases and literature review. Int. J. Oral. Maxillofac. Surg. 1996 Apr; 25(2): 91-7.

Handrigan GR, Buchtová M, Richman JM. Gene discovery in craniofacial development and disease - cashing in your chips. Clin Genet. 2007 Feb;71(2):109-19.

Hester SD, Reid L, Nowak N, Jones WD, Parker JS, Knudtson K, Ward W, Tiesman J, Denslow ND. Comparison of comparative genomic hybridization technologies across microarray platforms. J Biomol Tech. 2009 Apr;20(2):135-51.

Jehee FS, Burin BA, Rocha KM, Zechi-Ceide R, Bueno DF, Brito L, Souza J, Leal GF, Richieri-Costa A, Alonso N, Otto PA, Passos-Bueno MR. Novel mutations in IRF6 in nonsyndromic cleft lip with or without cleft palate: when should IRF6 mutational screening be done? Am J Med Genet. 2009 Jun; 149A(6):1319-22.

Jiang R, Bush JO, Lidral AC. Development of the upper lip: morphogenetic and molecular mechanisms. Dev Dyn. 2006 May;235(5):1152-66.

Kayserili H, Altunoglu U, Ozgur H, Basaran S, Uyguner ZO. Mild nasal malformations and parietal foramina caused by homozygous ALX4 mutations. Am J Med Genet A. 2012 Jan;158A(1):236-44.

Kayserili H, Uz E, Niessen C, Vargel I, Alanay Y, Tuncbilek G, Yigit G, Uyguner O, Candan S, Okur H, Kaygin S, Balci S, Mavili E, Alikasifoglu M, Haase I, Wollnik B, Akarsu NA. ALX4 dysfunction disrupts craniofacial and epidermal development. Hum Mol Genet. 2009 Nov; 18(22):4357–66.

Krepischi-Santos ACV, Vianna-Morgante AM, Jehee FS, Passos-Bueno MR, Knijnenburg J, Szuhai K, Sloos W, Mazzeu JF, Kok F, Cheroki C, Otto PA, Mingroni-Netto RC, Varela M, Koiffmann C, Kim CA, Bertola DR, Pearson PL, Rosenberg C. Whole-genome array-CGH screening in undiagnosed syndromic patients: old syndromes revisited and new alterations. Cytogenet Genome Res. 2006; 115:254–61.

Kim HG, Kishikawa S, Higgins AW, Seong IS, Donovan DJ, Shen Y, Lally E, Weiss LA, Najm J, Kutsche K, Descartes M, Holt L, Braddock S, Troxell R, Kaplan L, Volkmar F, Klin A, Tsatsanis K, Harris DJ, Noens I, Pauls DL, Daly MJ, MacDonald ME, Morton CC, Quade BJ, Gusella JF. Disruption of neurexin 1 associated with autism spectrum disorder. Am J Hum Genet. 2008 Jan;82(1):199-207.

Kim SY, Kim JH, Chung YJ. Effect of Combining Multiple CNV Defining Algorithms on the Reliability of CNV Calls from SNP Genotyping Data. Genomics Inform. 2012 Sep;10(3):194-9.

Li C, Wong WH. Model-based analysis of oligonucleotide arrays: Expression index computation and outlier detection, Proc. Natl. Acad. Sci. 2001.98:a31-36.

Lin M, Wei LJ, Sellers WR, Lieberfarb M, Wong WH, Li C. dChipSNP: Significance Curve and Clustering of SNP-Array-Based Loss-of-Heterozygosity Data. Bioinformatics. 2004. 20: 1233-1240.

Marshall CR, Noor A, Vincent JB, Lionel AC, Feuk L, Skaug J, Shago M, Moessner R, Pinto D, Ren Y, Thiruvahindrapduram B, Fiebig A, Schreiber S, Friedman J, Ketelaars, CE, Vos YJ, Ficicioglu C, Kirkpatrick S, Nicolson R, Sloman L, Summers A, Gibbons CA, Teebi A, Chitayat D, Weksberg R, Thompson A, Vardy C, Crosbie V, Luscombe S, Baatjes R, Zwaigenbaum L, Roberts W, Fernandez B, Szatmari P, Scherer SW. Structural variation of chromosomes in autism spectrum disorder. Am. J. Hum. Genet. 2008 Feb; 82:477– 88.

Mavrogiannis LA, Taylor IB, Davies SJ, Ramos FJ, Olivares JL,Wilkie AO. Enlarged parietal foramina caused by mutations in the homeobox genes ALX4 andMS X2: from genotype to phenotype. Eur J Hum Genet. 2006 14:151–158.

Nie X, Luukko K, Kettunen P. BMP signalling in craniofacial development. Int J Dev Biol. 2006; 50(6):511-21.

Petek E, Windpassinger C, Vincent JB, Cheung J, Boright AP, Scherer SW, Kroisel PM, Wagner K. Disruption of a novel gene (IMMP2L) by a breakpoint in 7q31 associated with Tourette syndrome. Am J Hum Genet. 2001 Apr;68(4):848-58.

Pham NS, Rafii A, Liu J, Boyadjiev SA, Tollefson TT. Clinical and genetic characterization of frontorhiny: report of 3 novel cases and discussion of the surgical management. Arch Facial Plast Surg. 2011 Nov-Dec;13(6):415-20.

Poot M, Beyer V, Schwaab I, Damatova N, Van't Slot R, Prothero J, Holder SE, Haaf T. Disruption of CNTNAP2 and additional structural genome changes in a boy with speech delay and autism spectrum disorder. Neurogenetics. 2010 Feb;11(1):81-9.

Rizvi M, Lypka MA, Kovacev T, Agris J. Median facial cleft dysmorphism in three siblings: case report and review of the literature. Cleft Palate Craniof J. 2010;47(1):104-6.

Rossi MR, DiMaio MS, Xiang B, Lu K, Kaymakcalan H, Seashore M, Mahoney MJ, Li P. Clinical and Genomic Characterization of Distal Duplications and Deletions of Chromosome 4q: Study of Two Cases and Review of the Literature. Am J Med Genet. 2009 Dec; 149(A):2788–94.

Seabright M. A rapid banding technique for human chromosomes. Lancet. 1971 Oct 30;2(7731):971-2.

Sebat J, Lakshmi B, Malhotra D, Troge J, Lese-Martin C, Walsh T, Yamrom B, Yoon S, Krasnitz A, Kendall J, Leotta A, Pai D, Zhang R, Lee YH, Hicks J, Spence SJ, Lee AT, Puura K, Lehtimäki T, Ledbetter D, Gregersen PK, Bregman J, Sutcliffe JS, Jobanputra V, Chung W, Warburton D, King MC, Skuse D, Geschwind DH, Gilliam TC, Wigler M. Strong association of de novo copy number mutations with autism. Science. 2007 Apr; 316:445–9.

Shinawi M, Cheung SW. The array CGH and its clinical applications. Drug Discovery Today. 2008 Sep; 13(17-18):760-70.

Silva S, Martins Y, Matias A, Blickstein I. Why are monozygotic twins different? J Perinat Med. 2011 Mar;39(2):195-202.

Sun M, Li N, Dong W, Chen Z, Liu Q, Xu Y, He G, Shi Y, Li X, Hao J, Luo Y, Shang D, Lv D, Ma F, Zhang D, Hua R, Lu C, Wen Y, Cao L, Irvine AD, McLean WHI, Dong Q, Wang MR, Yu J, He L, Lo WHY, Zhang X. Copy-Number Mutations on Chromosome 17q24.2-q24.3 in Congenital Generalized Hypertrichosis Terminalis with or without Gingival Hyperplasia. Am J Hum Genet. 2009 Jun; 84(6):807–13.

Sutrala SR, Norton N, Williams NM, Buckland PR. Gene Copy Number Variation in Schizophrenia. Am J Med Genet. 2008 Jul; 147B(5):606–11.

Trainor PA, Krumlauf R. Patterning the cranial neural crest: Hindbrain segmentation and Hox gene plasticity. Nat Rev Neurosci. 2000; 1:116-24.

Twigg SR, Babbs C, van den Elzen ME, Goriely A, Taylor S, McGowan SJ, Giannoulatou E, Lonie L, Ragoussis J, Sadighi Akha E, Knight SJ, Zechi-Ceide RM, Hoogeboom JA, Pober BR, Toriello HV, Wall SA, Rita Passos-Bueno M, Brunner HG, Mathijssen IM, Wilkie AO. Cellular interference in craniofrontonasal syndrome: males mosaic for mutations in the X-linked EFNB1 gene are more severely affected than true hemizygotes. Hum Mol Genet. 2013 Apr 15;22(8):1654-62.

Twigg SR, Kan R, Babbs C, Bochukova EG, Robertson SP, Wall SA, Morriss-Kay GM, Wilkie AO. Mutations of ephrin-B1 (EFNB1), a marker of tissue boundary formation, cause craniofrontonasal syndrome. Proc Natl Acad Sci U S A. 2004 Jun 8;101(23):8652-7.

Twigg SR, Matsumoto K, Kidd AM, Goriely A, Taylor IB, Fisher RB, Hoogeboom AJ, Mathijssen IM, Lourenco MT, Morton JE, Sweeney E, Wilson LC, Brunner HG, Mulliken JB, Wall SA, Wilkie AO. The origin of EFNB1 mutations in craniofrontonasal syndrome: frequent somatic mosaicism and explanation of the paucity of carrier males. Am J Hum Genet. 2006 Jun; 78(6):999-1010.

Twigg SRF, Versnel SL, Nürnberg G, Lees MM, Bhat M, Hammond P, Hennekam RCM, Hoogeboom AJM, Hurst JA, Johnson D, Robinson AA, Scambler PJ, Gerrelli D, Nürnberg P, Mathijssen IMJ, Wilkie AOM. Frontorhiny, a Distinctive Presentation of Frontonasal Dysplasia Caused by Recessive Mutations in the ALX3 Homeobox Gene. The American Journal of Human Genetics. 2009 May; 84:698–705.

Uz E, Alanay Y, Aktas D, Vargel I, Gucer S, Tuncbilek G, Eggeling FV, Yilmaz E, Deren O, Posorski N, Ozdag H, Liehr T, Balci S, Alikasifoglu M, Wollnik B, Akarsu NA. Disruption of ALX1 Causes Extreme Microphthalmia and Severe Facial Clefting: Expanding the Spectrum of Autosomal-Recessive ALX-Related Frontonasal Dysplasia. AmJ Hum Genet. 2010 May; 86:789–96.

Wallis D, Lacbawan F, Jain M, Der Kaloustian VM, Steiner CE, Moeschler JB, Losken HW, Kaitila II, Cantrell S, Proud VK, Carey JC, Day DW, Lev D, Teebi AS, Robinson LK, Hoyme HE, Al-Torki N, Siegel-Bartelt J, Mulliken JB, Robin NH, Saavedra D, Zackai EH, Muenke M. Additional EFNB1 mutations in craniofrontonasal syndrome. Am J Med Genet. 2008 Aug; 146A(15):2008-12.

Wang K, Bucan M. Copy Number Variation Detection via High-Density SNP Genotyping. Cold Spring Harb. Protoc. 2008; doi: 10.1101/pdb.top46.

Wang K, Li M, Hadley D, Liu R, Glessner J, Grant SFA, Hakonarson H, Bucan M. PennCNV: An integrated hidden Markov model designed for high-resolution copy number variation detection in whole-genome SNP genotyping data. Genome Res. 2007 Nov; 17(11):1665-74.

Wieacker P, Wieland I. Clinical and genetic aspects of craniofrontonasal syndrome: towards resolving a genetic paradox. Mol Genet Metab. 2005 Sep-Oct;86(1-2):110-6.

Wieland I, Jakubiczka S, Muschke P, Cohen M, Thiele H, Gerlach KL, Adams RH, Wieacker P. Mutations of the ephrin-B1 gene cause craniofrontonasal syndrome. Am J Hum Genet. 2004 Jun; 74(6):1209-15.

Wieland I, Makarov R, Reardon W, Tinschert S, Goldenberg A, Thierry P, Wieacker P. Dissecting the molecular mechanisms in craniofrontonasal syndrome: differential mRNA expression of mutant EFNB1 and the cellular mosaic. Eur J Hum Genet. 2008 Feb;16(2):184-91.

Wilkie AO, Morriss-Kay GM. Genetics of craniofacial development and malformation. Nat Rev Genet. 2001 Jun;2(6):458-68.

Wu E, Vargevik K, Slavotinek AM. Subtypes of frontonasal dysplasia are useful in determining clinical prognosis. Am J Med Genet Part A. 2007. 143A:3069–3078.

Xu B, Woodroffec A, Rodriguez-Murilloa L, Roosd JL, Rensburge EJV, Abecasisf GR, Gogosb JA, Karayiorgoua M. Elucidating the genetic architecture of familial schizophrenia using rare copy number variant and linkage scans. Proc Natl Acad Sci USA. 2009 Sep; 106(39):16746–51.

Zhang F, Gu W, Hurles ME, Lupski JR. Copy Number Variation in Human Health, Disease, and Evolution. Annu. Rev. Genomics Hum. Genet. 2009; 10:451–81.